

SARCINA VENTRICULI AS THE POTENTIAL CAUSE OF ABOMASAL BLOAT

T. J. Schemm, T. G. Nagaraja, and B. M. DeBey

Summary

Sarcina-like bacteria, possibly *Sarcina ventriculi*, have been seen upon histopathologic examination of the abomasums of calves that died of abomasal bloat. The ability of the organism to grow at a low pH and produce large amounts of gas suggests that it may be the cause of abomasal bloat.

(Key Words: Abomasal Bloat, Calves, *Sarcina ventriculi*.)

Introduction

Abomasal bloat affects newborn calves, sheep, and goats, usually at less than 2 months of age. It has been observed in calves and lambs fed milk replacer diets ad libitum and in nursing calves. It is life threatening because of the extreme abdominal distension. The syndrome may be associated with proliferation of gas-producing bacteria in the abomasum.

A previous report described abomasal bloat with high mortality in kids up to 10 weeks of age at a goat dairy. The kids were found dead within 2 hours of the initial clinical signs of lethargy, reluctance to stand, distended abdomen, and a hollow sound upon ballottement. Histopathological examination of the abomasum revealed large, spherical cells in packets of 4 to 20, similar to *Sarcina ventriculi*. Those authors postulated that *S. ventriculi* may have a role in the development and pathogenesis of abomasal bloat in goat kids. Similar association of *Sarcina*-like bacteria with abomasal bloat in calves has been reported.

Experimental Procedures

At the Kansas State University Veterinary Diagnostic Laboratory, 20 to 30 cases of abomasal bloat in calves have been examined during the past 2 years. Calves were necropsied, and abomasal tissue was collected for histopathological examination. The abomasal contents of three calves were collected for bacteriological examination. The contents were inoculated into a preenrichment medium at pH 3.0 in an attempt to isolate *S. ventriculi*.

Results and Discussion

Necropsy revealed abomasal distension with free gas and occasionally abomasal rupture with perforated ulcers. Histopathological examination of the abomasal wall showed spherical bacteria (Figure 1) in packets of 4 to over 20 in 80-90% of the cases. In calves with ruptured abomasums, bacteria were observed on the peritoneal surface. One of the abomasal content samples for which isolation was attempted exhibited *Sarcina*-type cells in the preenrichment medium. However, attempts to isolate the cells in pure culture have not succeeded.

Sarcina ventriculi is a gram-positive, nonmotile bacterium, generally occurring as spherical shaped cells, 1.8 to 3.0 μm in diameter, in packets of 4 to 20. The organism is anaerobic, somewhat aerotolerant, and capable of growth at a wide range of pH (1.0 to 9.8). It ferments sugars and produces ethanol, acetate, CO_2 , and H_2 . It has been isolated from soil, mud, cases of human gastritis, rabbit and guinea pig stomach

contents, elephant dung, human feces, and cereal seeds.

We propose that this *Sarcina*-like organism may be a cause of abomasal bloat in calves because, it can survive and grow at acidic pH (2 to 3) and it produces large amounts of gas from the fermentation of sugars. However, conclusive evidence to declare that *S. ventriculi* is the causitive agent of abomasal bloat is lacking.

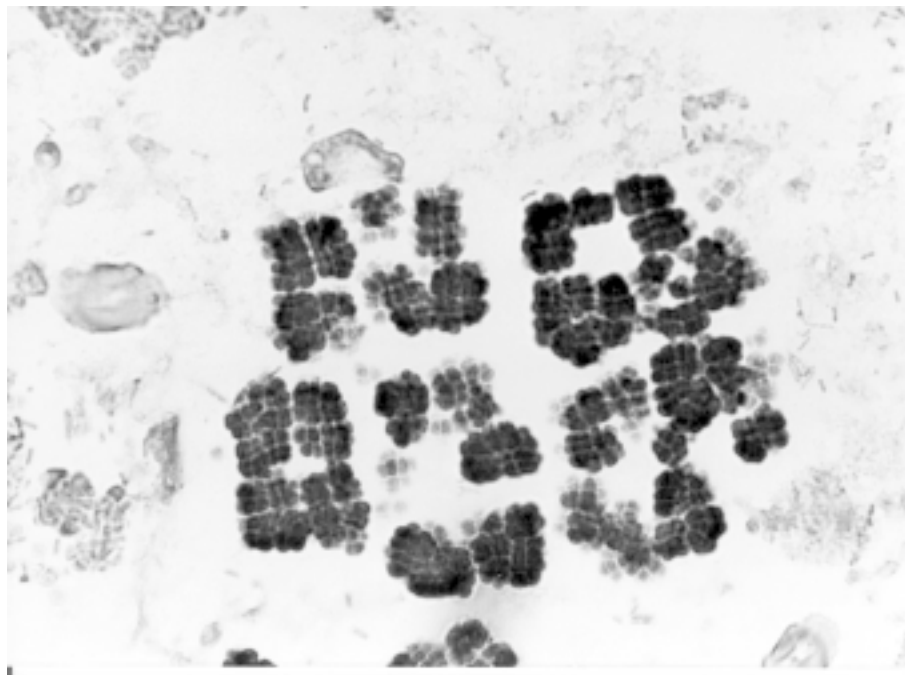


Figure 1. Photomicrograph Showing Spherical Cells on the Mucus Layer Adherent to the Surface of the Abomasum from a Calf that Died of Abomasal Bloat.