

HEREDITARY BOVINE SYNDACTYLY IN ANGUS AND CROSSBRED CATTLE

by

GARRET L. SCHMIDT

B.S., Kansas State University, 1983

D.V.M., Kansas State University, 1985

A MASTER'S THESIS

submitted in partial fulfillment of the

requirements for the degree

MASTER OF SCIENCE


Department of Pathology

KANSAS STATE UNIVERSITY

Manhattan, Kansas

1985

Approved by:



Major professor

LD
2668
T4
1985
S336
C.9

A11202 985087

DEDICATION

This Thesis is dedicated to my loving
parents and family whose continual support
and encouragement made this possible

TABLE OF CONTENTS

	Page
ACKNOWLEDGEMENTS	ii
INTRODUCTION	1
REVIEW OF LITERATURE	2
 HEREDITARY BOVINE SYNDACTYLY IN ANGUS AND CROSSBRED CATTLE	
Introduction	9
Review of Literature	9
Materials and Methods	11
Results	12
Discussion	29
Abstract	32
References	34
Appendix and Tables	36

ACKNOWLEDGEMENTS

I wish to record my sincere respect for and gratitude towards my major professor, Dr. Horst W. Leipold, for his tremendous support and guidance. My thanks also to the other members of my supervisory committee: Drs. James E. Cook, Sam Kruckenberg, and Robert R. Schalles.

Others contributing to the successful completion of this study are: Sherri Kraus (typing), Duane Kerr and Dave Adams (photography), Dr. Glenn Hartke (anatomical guidance), and the entire staff and faculty of the Department of Pathology at Kansas State University College of Veterinary Medicine.

We also thank the American Angus Association, 3201 Fredricks Boulevard, St. Joseph, Missouri 64501, for their support of this study.

This research was part of the Regional Project NC-2.

INTRODUCTION

The bovine limb is a structure essential in providing locomotion enabling the animal to obtain food and water as well as being a necessary part of the breeding process. When its structure and soundness falls prey to a heritable defect, this adversely affects the entire individual's well-being. Should the affected animal be an important part of the herd's reproduction, such as the herd bull; the entire population would suffer from a decrease in calf number as well as a continual transference of an undesirable trait to future reproductive members of the herd. Therefore, either the phenotypic or genotypic presence of syndactylism (syndactyly, syndactylia) in a population is obviously of prime economic importance to the livestock owner-producer.

Syndactyly has been well-studied in the Holstein-Friesian breed, however, no descriptions have yet been produced concerning the similar condition in Angus cattle. The purpose of this study, therefore, is to describe anatomical changes in affected animals, and draw from these the nature and cause of hereditary bovine syndactyly in Angus cattle.

REVIEW OF LITERATURE

Syndactyly (syndactylism, syndactylia) is the partial or complete fusion of functional digits involving one or more feet noted in many breeds of cattle including: Holstein-Friesian, Aberdeen-Angus, Simmental, German Red Pied, Indian Hiriana, and the Chianina breed. The condition in the Holstein-Friesian breed is attributed to an autosomal recessive gene exhibiting incomplete penetrance, thus allowing some phenotypically normal "escapers" (7,9). In Simmentals, the inheritance of the trait is sex-linked (11), while Singh and Tandon (23), and Singh and Bhattacharya (22), reported syndactyly in Hiriana cattle to be an autosomal recessive trait. Current methods used to identify heterozygous bulls include: matings to heterozygous animals, own daughters, daughters of heterozygotes, or to syndactylous cows. Testing of heifers utilizes superovulation, insemination with semen from a syndactylous bull, embryo transfer, and early fetal recovery at 60 days (5,6,10,12,13). Embryological developmental characteristics have been studied by Gruneberg (8) yet will not be included in this study.

Syndactylism dates back to the day of Aristotle but serious study of the condition was pioneered by Steiner (24) who proposed a classification system based on degree of fusion and number of proximal sesamoid bones of the affected limb following his study of 12 cases of bovine syndactyly. Adrian (2,3) carried the study of syndactylia one step further as he described not only skeletal changes but also the adaptations of muscles, tendons, and vascularity to the affected limb. Later, the study of 55 genetically syndactylous Holstein-Friesian cattle by Leipold and coworkers (18,19) divided the animals into four distinct groups based on the degree of fusion of the hooves including:

(1) normal hooves of "escaper" animals, (2) partially syndactylous hooves, (3) intermediate syndactylous hooves, and (4) completely syndactylous hooves.

The following descriptions are drawn from the findings of Steiner, Adrian, and Leopold, through their study of syndactylism in the Holstein-Friesian breed.

Syndactyly is most readily recognized in its most characteristic form -- a single digit covered with a hoof the shape of a bilaterally compressed, truncated, inverted cone (14,15,17,18,21). The dewclaws of a syndactylous limb were often moderately or even greatly enlarged and occasionally attached at different levels with the lateral often larger than the medial. This enlargement, although present in calves, was more pronounced in older cattle. Adrian (1) continued by describing a "dewclaw plate" of deep fascia which held the dewclaws on place, and stated that there were "no abnormal ligaments of the dewclaws".

Concerning skeletal anomalies, the most proximal synostosis involved the proximal row of carpal bones including fusion of Ulnar and Intermediate as well as the formation of a single bone by synostosis of all three (Radial, Ulnar, and Intermediate). The scarce mention of fusion patterns present in the tarsus was explained by Adrian (1), "The small number of pelvic syndactylous limbs were not informative...". The metacarpals revealed a variety of forms from the presence of a narrowed intertrochlear notch to the complete absence of it resulting in a lone trochlea with two sagittal ridges which were often found fused. The most severe consequence of this pattern was a single trochlea with one sagittal ridge centered on the distal articular surface of the large metacarpal bone (1). The small metacarpal bones

were often present in abnormal size and shape which seemed to be correlated with the degree of syndactylism present in that limb. The same was found to be true of the phalanges of the rudimentary second and fifth digits which in a few cases formed true joints between each other. The greater the fusion, the better developed were these bones. The number of proximal sesamoid bones, as Steiner (24) indicated, varied and was used as an indicator of the degree of fusion present in the entire limb. The group with slight fusion had four proximal sesamoids, those with moderate fusion, three, and if severe fusion was present, two were found (the finding of a single proximal sesamoid, however, was not mentioned). Leipold and coworkers (17) concluded that, "the degree of fusion in animals with more than one affected limb was always more advanced in the right forelimb, and more severe in the forelegs if a hindleg was affected. In the hind legs the malformation again followed a right to left pattern." Metatarsals were then reported to always have two distal trochlea and never fewer than three proximal sesamoid bones (17).

Synostosis of the digits commonly develops via one of two variations: horizontal fusion (phalanges of different digits but of same number) and verticle fusion (phalanges of the same digit). Of these two the horizontal is most widely reported, especially concerning the Holstein-Friesian breed in which this condition is the most significant. However, the second form of syndactyly was noted in an Angus calf (20,16) which resulted from a synostosis of second to third phalanges of all four digits of the two front feet.

The adaptation of muscles and tendons to the syndactylous limbs was reported as follows: the three digital extensor tendons all joined at fetlock level to form an aponeurotic plate which inserted on the second and third phalanges; the flexor tendons (SDF and DDF) remained separate and inserted as they would on a normal limb; while the SDF commonly and the DDF rarely sent a branch to the lateral dewclaw (1,2,14). The nervous and vascular supply also adapted to the skeletal malformation either by fusion or termination (1,3,4).

REFERENCES

1. Adrian, R.W. (1961). Anatomical studies on bovine syndactylism. Thesis, Kansas State University.
2. Adrian, R.W., H.W. Leipold, K. Huston, D.M. Trotter, and S.M. Dennis. (1969a). Anatomy of hereditary bovine syndactylism. II. Muscles, tendons, ligaments. *J. Dairy Sci.*, 52: 1432-1435.
3. Adrian, R.W., D.M. Trotter, H.W. Leipold, and K. Huston. (1969b). Anatomy of hereditary bovine syndactylism. III. Angiology. *J. Dairy Sci.*, 52: 1436-1440.
4. Adrian, R.W., D.M. Trotter, H.W. Leipold, and K. Huston. (1969c). Anatomy of bovine hereditary syndactylism. IV. Neurology. *J. Dairy Sci.*, 52: 1441-1444.
5. Baker, R.D., G.W. Snider, H.W. Leipold, and J.L. Johnson. (1980). Embryo transfer tests for bovine syndactyly. *Theriogen.*, 13: 87.
6. Castleberry, S., J. Johnson, H.W. Leipold, G. Peeples, and R. Schalles. (1981). Embryo transfer and its effect on genetic research. *Theriogen.*, 19: 130.
7. Eldridge, F.E., W.H. Smith, and W.M. McLeod. (1951). Syndactylism in Holstein-Friesian cattle. Its inheritance, description and occurrence. *J. Hered.*, 42: 241-250.
8. Gruneberg, H. and K. Huston. (1965). The development of bovine syndactylism. *J. Embryol. and Exp. Morph.*, 19: 251-259.
9. Huston, K., F.E. Eldridge, and J.W. Mudge. (1961). Genetics of syndactylism in cattle. *J. Dairy Sci.*, 44: 1197.
10. Johnson, J.L., H.W. Leipold, G.W. Snider, and R.D. Baker. (1980). Progeny testing for bovine syndactyly. *J.A.V.M.A.*, 176: 549-550.

11. Krolling, O. (1956). Beitrag zur morphogenetischen und erbbiologischen Beurteilung der Syndaktylie beim Rinde. Wien. tierarztl. Mschr., 43: 129-139.
12. Leipold, H.W. and J.S. Peeples. (1981). Progeny testing for bovine syndactyly. J. Am. Vet. Med. Assoc., 179: 69-70.
13. Leipold, H.W., S.M. Dennis, and K. Huston. (1973). Syndactyly in cattle. Vet. Bull., 43: 399-403.
14. Leipold, H.W., M.M. Guffy, and J.E. Cook. (1977). Syndactyly in cattle. Comp. Pathol. Bull., 8: 305-307.
15. Leipold, H.W., K. Huston, and S.M. Dennis. (1983). Bovine congenital defects. Adv. Vet. Sci. Comp. Med., 27: 197-271.
16. Leipold, H.W., K. Huston, M.M. Guffy, and S.M. Dennis. (1969b). Syndactyly in an Aberdeen-Angus calf. Am. J. Vet. Res., 30: 1685-1687.
17. Leipold, H.W., R.W. Adrian, K. Huston, D.M. Trotter, and S.M. Dennis. (1969a). Anatomy of hereditary bovine syndactylism. I. Osteology. J. Dairy Sci., 57: 1422.
18. Leipold, H.W., S.M. Dennis, K. Huston, D.M. Trotter, and R.W. Adrian. (1971). Anatomy of hereditary bovine syndactyly. V. External description. Geissener Beitr. Erbpath. Zuchthyg., 3: 6.
19. Leipold, H.W., K. Huston, S.M. Dennis, R.F. Cooper, and A. Dayton. (1973). Hereditary bovine syndactyly. I. Clinical-pathological observations. Geissener Beitr. Erbpath. Zuchthyg., 5: 139-157.
20. Ojo, S.A., H.W. Leipold, and C.M. Hibbs. (1975). Bovine congenital defects: Syndactyly in cattle. J.A.V.M.A., 166: 607-610.

21. Rieck, G.W. (1972). Syndactylie beim Deutschen Rotbunten Rind. Giessener Beitr. Erbpath. Zuchthyg., 4: 1-13.
22. Singh, S. and P. Bhattacharya. (1949). Inheritance of syndactylism in Hiriana cattle. Indian J. Vet. Sci., 19: 153-159.
23. Singh, S. and R.K. Tandon. (1942). A short notice on calves with unbifurcated hooves. Indian J. Vet. Sci., 12: 61.
24. Steiner, A. (1945). Uber Syndactylie beim Rind. Vet. Med. Diss., Zurich.

HEREDITARY BOVINE SYNDACTYLY IN ANGUS AND CROSSBRED CATTLE

INTRODUCTION

Syndactyly, fusion or nondivision of functional digits, is a common hereditary, regional skeletal defect of Holstein cattle, first reported in the U.S. in 1951.⁶ Shortly thereafter, a small herd of Holstein syndactylous cattle was assembled at Kansas State University to test genetic hypotheses and provide information concerning embryology and anatomic, physiologic, and economic consequences of the defect. Reports of progress and results of anatomic and embryologic studies have been issued (1-4, 7-9, 11-18). Later, syndactyly was reported in Chianina and crossbred cattle.¹⁹ Methods were devised to test prospective breeding animals, male or females, for presence or absence of the syndactyly gene.^{4,5,9,11} These methods use superovulation of syndactylous cows or use of semen from syndactylous bulls, embryo transfer, and early gestation cesarean sections.^{4,5,9,11} Syndactyly has also been reported in Europe in Simmental cattle and Red Pied.^{10,20} Now we report investigations seeking to identify the nature and cause of syndactyly in purebred Angus and crossbred cattle.

REVIEW OF LITERATURE

The study of hereditary bovine syndactyly has been extensive and a classification system has been devised based on number of proximal sesamoids on the affected limb.¹⁶ Muscles, tendons, and vascular and neurologic changes in affected limbs have been described.¹⁻³

Bovine hereditary syndactyly in Holstein cattle was most readily recognized in its characteristic form, a single digit covered with a hoof the shape of a bilaterally compressed, truncated, inverted cone. The dewclaws often were greatly enlarged, with the lateral commonly larger than the medial. The most proximal synostosis involved the proximal row of carpal bones, including fusion of ulnar and intermediate, as well as the combination of all three into a single bony structure. The metacarpals and metatarsals revealed a variety of forms from the presence of a narrowed intertrochlear notch to the complete absence of it. The small metacarpal bones (Mc II and V) were often present in abnormal size and shape, as were the phalanges of the rudimentary second and fifth digits, which in a few cases may form actual joints between each other. The number of proximal sesamoids varied from four to two, while there has been no mention of a singular proximal sesamoid bone. Synostosis of the syndactylous digits in Holstein cattle has been reported as horizontal (phalanges of different digits but of same number). The degree of fusion in syndactylous cattle with more than one affected limb always was more advanced in the right forelimb and more severe in the forelegs, if a hind leg was affected. In the hind legs the malformation again followed a right over left pattern.^{16,17}

The adaptation of muscles and tendons to the syndactylous limb was as follows: the three digital extensor tendons join at the fetlock level to form an aponeurotic plate, which inserts on the second and third phalanges; the flexors remained separate and in normal position to insert normally with the superficial digital flexor commonly, and the deep digital flexor rarely, sending a tendinous branch to the lateral dewclaw.¹

MATERIALS AND METHODS

Cattle affected with syndactyly and normal cattle heterozygous for syndactyly were used in this study. The material was collected as outlined previously.¹³ Origin, identification, sex, and breed are listed in Table 1 in the appendix.

Seven Angus or Angus/Holstein cross cattle (five syndactylous and two normal), ranging in age from several days to years were studied under the Regional Breeding Project NC-2. The cattle were housed, fed, and managed similar to their contemporaries at the Animal Resources Facility, Kansas State University. Some intact animals were received from other institutions or from breeders and processed immediately. Frozen legs from syndactylous calves were sent to the Congenital Defects Laboratory, Department of Pathology, Kansas State University. Fetuses from cattle being tested for heterozygosity by methods outlined previously were collected and sent to Kansas State University for further studies.^{4,5,9,11} Breeding experiments were carried out at the Animal Resources Facilities of the College of Veterinary Medicine, Kansas State University.

All limbs were radiographed, photographed, and examined externally for evidence of tendon contracture, angulation or deviation, pressure sores or crusts, and abnormal dewclaws or hooves. The limbs then were frozen until dissection could be accomplished.

A detailed dissection following the thawing of the limbs was accomplished, beginning proximally with the carpus-tarsus and proceeding in a distal direction (with the exception of #915 which was submitted without the carpal or tarsal bones). Primary emphasis was

placed on discerning any and all skeletal changes, with secondary goals of recording tendon or ligament anomalies. All abnormalities were immediately recorded in writing accompanied by a brief diagrammatic sketch. The most relevant structures then were photographed.

RESULTS

Origin of cattle, breed, sex, and other relevant dates are summarized in Table 1. Radiologic findings are listed in Tables 2-3. Thirty-five figures document some of the anatomical changes.

82-955 (fig 22)

RF Externally, the limb had the appearance of a normal limb except for both dewclaws being enlarged with a fusion of the two claws to form a conical, single hoof tapering to a rounded end distally. All six carpal bones were normal. Metacarpals II and V were enlarged; and while II inserted into the medial dewclaw via a tendinous band, V had developed three rudimentary osseous structures (phalanges) that continued from the metacarpal (in a straight row) to articulate with the lateral dewclaw. The two dewclaws then were conjoined by a band of connective tissue similar to an interdigital ligament. There were three proximal sesamoids. The axial sesamoids of each digit (III and IV) were the ones joined. The two distal sesamoids formed a single bone and all phalanges of the third and fourth digits were fused horizontally, leaving a rough end but functional joint between

each, as well as between the fused first phalanges and the distal articulation of metacarpals III and IV, which lacked an intertrochlear notch. The two extensor tendons fused at the level of the metacarpal-phalangeal joint and inserted on the proximal portions of P-1 and P-2. The superficial digital flexor (SDF) and deep digital flexor (DDF) were in normal positions but were joined at various points by several fibrous bands that prevented a smooth, "gliding" action. The two inserted at a common point on the third phalanx, while the SDF inserted solely on P-1 and P-2, not the normal pattern for insertion of the flexors.

LF Externally this limb was a mirror-image of the right front, with the medial dewclaw being slightly larger and the carpus wider. Again the carpal bones were all within normal limits, but metacarpals (MC) II and V were not as large and extended distally no further than the midshaft of metacarpals III and IV, only to insert into their respective dewclaws via a ligamentous structure. The two axial proximal sesamoids of each digit were fused to exhibit three proximals again and all phalanges of the third and fourth digits showed horizontal fusion patterns. There was one distal sesamoid present and all three distal joints were again functional yet uneven in their cartilaginous surfaces. The intertrochlear notch of the distal end of metacarpals III and IV was present, however it was reduced in depth and width. An interdigital-like ligament again had conjoined the two dewclaws firmly. Phalanges I, II, and III were all sites of insertion for the fused extensor tendons, which began as two and jointed at the

fetlock level. The DDF inserted only on phalanges III, while the SDF inserted on all three phalanges only after having received a large thick band from the interosseous muscle at 2 inches above the proximal sesamoids.

RH This limb had normal external muscle and bone structures.

LH This limb seemed externally normal but the cleft between the claws was incomplete. The sagittal notch between the claws extended to the area of the metatarsal-phalangeal joint, rendering an illusion of a normal foot. No abnormalities were noted concerning the tarsal bones or joints. The metatarsals (Mt) were enlarged, however, and each extended distally to a level of midshaft of metatarsals III and IV, where they both widened and sent a tendon distally to insert in their respective dewclaws. Within the medial tendon was an osseous structure of $\frac{1}{4}$ inch diameter and present at $\frac{1}{2}$ inch prior to the tendon's insertion. Four proximal sesamoids were present and no fusion of any of the phalanges or distal sesamoids was seen. The intertrochlear notch at the distal end of metatarsals of III and IV was slightly reduced but basically normal, as were both extensors and flexors despite a few fibrous adhesions between the SDF and DDF 1 inch distal to the tarsus.

82-1017

RF This limb was short and thick upon external inspection and at the knee a large (1½ inch diameter) scab was present, which revealed the difficulty the animal must have experienced when trying to walk on "mule feet". The truncated hoof was elongated and narrowed to a point as it deviated laterally. Both dewclaws were larger and set more dorsally on the limb. The carpus had developed in a slightly flexed position (about 135° angle from radius to the large metacarpals). All carpals were found to be normal, except for the nonfusion of the second and third of the distal row. Both metatarsals II and V had developed to a much greater degree than normal and had shown a "mushrooming" enlargement both proximally and distally. Two phalanges connected the most medial metacarpal to the medial dewclaw, while three were present following metacarpal V into the lateral dewclaw. A small synovial joint had been formed between these small phalanges. The number of proximal sesamoids was two, due to a fusion of each pair (lateral and medial), while horizontal fusion of each of the phalanges of digits three and four had occurred. One large, irregularly shaped distal sesamoid was present and it had several fracture lines present within. Both extensor tendons remained independent throughout their course distally to insert each on all three fused phalanges, while only the lateral tendon sent a slip to the lateral dewclaw. Although both flexor tendons were found normally located, the DDF inserted on phalanges II and III, while the SDF inserted on phalanges I and II.

LF The left forelimb was very similar to the right fore, including the posteriorly angulated carpus, dorsally-located crust, and laterally deviated syndactylous hoof. In addition, the limb had developed an extra lateral dewclaw which, while not being as large as the normal pair, was somewhat enlarged itself. The irregularly-shaped radio-carpal joint contained many cavitations and clefts, especially on the distal radius. Fusion of the radial and intermediate of the proximal row of carpals, as well as the nonfusion of 2 and 3 characterized the carpus. The enlarged MC V was divided at its distal extent to coordinate with the extra lateral dewclaw. Upon having divided, each division formed two phalanges (the second of which resided within the horn of the dewclaw). The most medial metacarpal did not fork but did seemingly form two "sets" of phalanges for an extra medial digit, as well as what could be described as a rudimentary proximal sesamoid for the second digit. Each "set" of phalanges contained two osseous structures, which both led to the horny segment of the lone medial dewclaw. The large MC bone had no intertrochlear notch present as it articulated with P-1. Only two proximal sesamoids were noted and all phalanges were again horizontally fused between digits 3 and 4. Again, the two extensors inserted on all three fused phalanges and the lateral of the two sent a branch to the extra lateral dewclaw, while the SDF inserted on P-1 and P-2 and the DDF inserted on P-2 and P-3.

RH A single, laterally deviated hoof and enlarged dewclaws described the external appearance of this limb. The enlarged lateral malleolus then was discovered to have been fused with the centroquartal (fourth and central) and fibular tarsal bones (Ft). This pattern of vertical fusion was followed by the distal row of tarsals, of which the first, second and third were all fused together and with the proximal extremity of the large Mt bones (III and IV). Mt II was entirely tendinous and contained an osseous segment at midshaft of Mt's III and IV, while Mt V was osseous and enlarged, forming two phalanges distally. While all phalanges of the third and fourth digits showed the common pattern of horizontal fusion and joint formation, there was only one proximal and one distal sesamoid present. The two extensor tendons remained separate along their routes and each sent fibers to its respective dewclaw and continued distally to insert on phalanges I, II, and III. The two flexors imitated the extensors by laying side by side (medial/lateral) instead of in the normal position. They then sent branches to the dewclaw on their side before continuing distally to fuse near fetlock level and insert on all phalanges.

LH This limb was externally similar to all others of this animal, even though the toe showed slightly greater curvature dorsally than the others. Fusion patterns were identical to the right hind, with the lateral malleolus, fibular tarsal, central and fourth tarsals all fused solidly together, as well as the 2nd and 3rd tarsals fused to the proximal articulation of the large Mt.

The second Mt was entirely tendinous with a bony segment within it at a level 1 inch above the proximal sesamoid (which was single). The most lateral Mt was not markedly abnormal. The phalanges were fused in the normal fashion, as was the distal sesamoid. A tendinous structure was found to connect the medial dewclaw with the deep fascia of the fetlock joint. The extensor and flexor tendons copied those of the right hind limb and thus will not be described again.

82-994 (fig 15-19)

RF Upon external evaluation of this limb, a rigid flexion was noted, as well as an extra horned growth near the medial dewclaw and a single truncated hoof. The radial, intermediate, and ulnar carpals were all fused and showed cartilaginous attachments to the distal row of fused carpals (thus horizontal and vertical fusion both being present). Both MC II and V were larger than normal (with MC II being so large that it articulated with the fused distal carpals). Two phalanges followed MC V and joined the lateral dewclaw, while MC II sent two phalanges into one of the medial dewclaws and ended as a ligament inserting on the other medial dewclaw, which contained an osseous segment within. Fused proximal sesamoids of the third and fourth digits resulted in the presence of two proximal sesamoids for this limb. The truncated hoof contained the syndactylous elements of digits 3 and 4, as well as a single distal sesamoid. An interdigital "band" originated at the two medial dewclaws and continued distally to

join the syndactylous digits, as did a similar structure from the lateral dewclaw. The two extensors fused near the fetlock and inserted both on MC V and on P-1 of the fused digits. Flexors were found to be normal.

LF The left fore showed similar contracture to the right fore and also the additional medial dewclaw. The carpals also were identical to the right foreleg, with the exception of the absence of vertical fusion patterns between single proximal and distal rows. Mt II was elongated and larger than normal, extending almost to the fetlock joint. A large first phalanx articulated with the distal end of the long MC II and entered the most proximal of the medial dewclaws, which contained a small boney P-2. An identical articulation occurred 1 inch proximal to the previous and these phalanges entered the remaining medial dewclaw. The most lateral MC, however, inserted into the lateral dewclaw, which contained two small boney segments via a ligament, which was approximately 1 3/4 inches in length. Two proximal sesamoids were noted and an interdigital ligament connected the dual medial dewclaws with the syndactylous digits. The extensor tendons were identical to those of the right foreleg and thus will not be described again. Flexor tendons were seen to fuse at midshaft of the large MC and inserted on P-2 and P-3 of the fused digits, as well as on each rudimentary phalanx articulating with the large second MC.

RH This limb again was flexed and syndactylous, with the presence of two dewclaws and an extra large medial claw equal in size to the horn of the fused third and fourth digits. All tarsal bones were found to be normal, with the exception of the joined central and fibular tarsal bones. Mt II was enlarged and extended distally into the extra claw, while MC V was absent. The third and fourth digits showed fusion of their first and second phalanges, yet the two P-3's were not fused and layed side by side and only slightly divided by a single distal sesamoid. The fused extensor tendons sent branches to both the medial and lateral dewclaws but not the extra medial claw. A poorly developed SDF tendon sent a slip of tendon to the extra claw, as well as to the lateral dewclaw but none to the medial dewclaw.

LH This limb was not as contracted as previous limbs but did show flexion of the fetlock joint, as well as medial deviation of the limb below the same joint. Each dewclaw was joined to the single hoof wall of the fused claws of digits three and four. The tarsus was normally formed, but the large Mt was extremely short and was without trochlea. Metacarpals II and V were each moderately enlarged and extended halfway to the fetlock joint where they ended as tendinous bands entering their respective dewclaws. Two proximal sesamoids were found to articulate normally. The distal phalanges of the third and fourth digits were not fused, while the proximals and middles were, and one distal sesamoid was present. Two extensors were noted and found to insert normally. The SDF

tendon, however, sent a slip to the lateral dewclaw, while the DDF tendon sent a branch to the interosseus ligament and the two then inserted on the lateral proximal sesamoid.

82-915 (Note: All limbs were submitted without carpus/tarsus)

RF This limb had the common appearance of that of an older syndactylous animal, having an elongated hoof drawing to a point, which deviates laterally at its distal apex. The enlarged lateral and medial metacarpals were even distinguishable externally. The radiocarpal joint was again irregular, uneven, and contained cavitations, especially on the distal aspect of the radius. While MC V extended into the lateral dewclaw via a tendinous band, MC II developed two phalanges, which corresponded with the medial dewclaw and developed synovial joints between each. Two proximal sesamoids were found and each sent a connective band to the dewclaw on that side. Each phalanx was horizontally fused to that of the corresponding digit within the horn surrounding digits three and four.

LF The external appearance of this limb was that of a syndactylous limb with dewclaws of greater size than normal and a lateral deviation distally. Metacarpals II and V were a copy of those of the right foreleg and thus are not described again. A fibrous band extended from each of the two proximal sesamoids to the corresponding dewclaw. Hemarthrosis was presented upon having opened the fetlock joint accompanied by irritated, inflamed

synovial linings of the joint. Contained within the single hoof were the fused phalanges of digits three and four and a single distal sesamoid. Extensors and flexors of this limb were all within normal limits.

RH This limb was syndactylous with the toe deviated laterally. MT's II and V were both slightly larger than normal, yet neither was large enough to articulate with, or extend to, its respective dewclaw. Two proximal sesamoids were present and each had irregular articular surfaces. An interdigital ligament connected each dewclaw to the deep fascia near the fetlock joint below which were the three synostotic phalanges of the third and fourth digits and a single distal sesamoid. The fetlock joint surfaces showed evidence of osteochondritis and a large (3/4" across, 1/2" deep) cartilaginous joint mouse was present within. The extensor and flexor tendons were found to be basically normal in distribution and insertion.

LH The left hind was also syndactylous, with a laterally deviated toe. The two small MT's were absent, yet there was a small osseous structure within each dewclaw. The two proximal sesamoids present (due to a fusion of each pair for digits 3 and 4) also showed signs of partial fusion along with multiple fracture lines within, which signified the structural inadequacies of such a situation. These conformational problems caused an osteochondrosis of the fetlock joint, which resulted in a roughening of the distal articular surface of the large metatarsal bone, as well

as an absence of any sagittal groove. Again there was a horizontal fusion of all phalanges, as well as the presence of a single distal sesamoid. The extensor and flexor tendons again were found to be within normal parameters.

82-1022

RF This syndactylous limb had enlarged dewclaws and a conical hoof that showed little deviation from the midline. The distal articular surface of the radius revealed many irregular, cavernous areas over the entire surface. Fusion of the ulnar and intermediate carpals then was noted, along with a normal distal row of carpals. Metacarpals II and V were both enlarged and each articulated with a first phalanx, which entered the respective dewclaw containing an osseous second phalanx for each digit. Then, exiting from each dewclaw was an interdigital ligament, which extended distally to fuse with the hoof wall of the synostatic phalanges of digits three and four. There were four proximal sesamoids present (a new finding for a syndactylous limb!) and the distal sesamoid was single. The dual extensor tendons conjoined at fetlock level to insert only on the fused P-1, while flexors were normally developed and inserted.

LF This limb was normal upon external inspection, with the only exception being the slightly enlarged dewclaws. The proximal row of carpals showed fusion of the ulnar and intermediate carpal bones, while the first, second, and third carpals were fused

(normal) in the distal row. Metacarpals II and V were only slightly enlarged (with the lateral of the two being more developed) and, while the 2nd metacarpal inserted into its dewclaw via a ligament, the 5th metacarpal articulated with a first phalanx followed by two more osseous segments of that digit, which were contained within the horn of the lateral dewclaw. The four proximal sesamoids present were all normal, as was the distal extent of the large metacarpal. All phalanges were normal, as were the two distal sesamoids (one present for each digit). The extensors were all found to be normal but the SDF sent a branch, which joined both the lateral dewclaw and the interdigital ligament present on that digit.

RH This limb was externally normal, aside from partial fusion of the 2nd and 3rd carpals to the proximal portion of the large MT and osteochondrosis of the tibial-tarsal joint. All other aspects of this limb were normal.

LH All aspects of this limb were found to be within normal limits.

82-1023 (fig 20, 36)

RF This limb was externally syndactylous, with the dewclaws moderately enlarged. Upon dissection, the ulnar and intermediate carpal bones were found to be fused and all others were normally formed. With the most medial MC ending proximal to the fetlock to

continue as a ligamentous structure to the medial dewclaw, the most lateral MC split at the same level into two similar structures. The medial formed two phalanges, which entered the lateral dewclaw, while the lateral formed just one phalanx which entered the same dewclaw containing a large, roughened piece of bone. The fusion of the medial proximal sesamoid of the third and fourth digits resulted in the formation of three proximal sesamoids. As expected, there was no intertrochlear incision present on the distal articular surface of the large MC bone and all phalanges were horizontally fused to each other. There was a single distal sesamoid. All extensors and flexors were found to be within normal limits for a syndactylous limb.

LF Externally this limb showed a partial fusion of the hoof walls of the two claws. The ulnar and intermediate carpals were also found fused together, with all other carpal bones normally formed. There was no enlargement of either the fifth or second MC and dewclaws were of normal proportions, also. The distal end of the large MC bone showed a narrowing of the sagittal notch, combined with a reduction in size of the sagittal ridges. Three proximal sesamoids were present and similar to those of the right foreleg, with the center being larger than the other two. From that level distally, all aspects of the limb were normal with the exception of the partial fusion of the hoof wall.

RH This limb was normal not only externally but upon observation of dissected tarsals as well. Metatarsal V entered the lateral

dewclaw (containing an osseous segment) via a ligament. Metatarsal II, however, first articulated with a single phalanx, then continued as a ligament into the lateral dewclaw and its boney center. From this lateral dewclaw exited an interdigital ligament, which connected the former to the latero-caudal aspect of the second digit. These were the only variations from normal that were noted.

LH Again, as with the right rear, this limb was found normal upon external inspection. The fused second and third tarsals were partially joined via cartilage to the proximal surface of the large MT. Both Mt II and V inserted into their respective dewclaws by use of a tendinous bond but the lateral of the two interrupted its tendon with an osseous segment half way between origin and insertion. The medial dewclaw was also joined by a slip of tendon from both SDF and DDF but the lateral dewclaw was not. Hemarthrosis was found to be present in the tibial-tarsal joint along with slight osteochondrosis.

82-1024 (fig 21)

RF This limb had developed a single hoof which narrowed to a rounded end with moderate lateral deviation of the portion distal to the carpus. The carpus was normally formed, although all articular surfaces were noted to have been roughened, with some degree of osteochondrosis present therein. A thin tendinous-structure had replaced MC II and inserted into the medial dewclaw

(it also contained a small osseous segment one quarter inch prior to insertion). Metacarpal V was, however, osseous and connected to the lateral dewclaw via a ligament. Just palmar and medial to this metacarpal was another ligamentous structure, which continued down the large MC and attached to a bony structure that articulated with two other such structures within the lateral dewclaw. The fusion of each pair of proximal sesamoids for digits three and four resulted in two proximal sesamoids larger in size than normal. The phalanges and distal sesamoid were fused in the normal manner of a syndactylous limb. The two extensor tendons present fused near the fetlock to insert on proximal portion of phalanges I only. Several fibrous adhesions between the SDF and DDF, as well as from the interosseous ligament and DDF, were noted to have decreased the mobility of these structures. The SDF, meanwhile, sent a slip of tendon to each dewclaw, inserted distally on phalanges I and the proximal area of phalanges II, while the DDF inserted only on P-3.

LF This syndactylous limb was deviated laterally below the fetlock joint, which was covered by a large pressure sore (crust and thickening). The radial articulation of the radio-carpal joint was wavy with several cavitations. A fusion of radial and intermediate carpals was present along with a normal distal row of carpal bones. MC V was enlarged and forked at midshaft of the large metacarpal to send dual tendons to the lateral dewclaw, which contained several osseous structures. The second MC also inserted into its dewclaw via a tendon, yet it was single and the

dewclaw contained only a single bone. Both dewclaws, however, sent an interdigital ligament to the horizontally-fused phalanges of the third and fourth digits. Also found were two proximal sesamoids and a single distal. Both extensor tendons reached the fetlock level, united and inserted on the proximal portion (extensor process) of the fused phalanges I only. Similarly, the flexors (DDF and SDF) were joined at various levels. The SDF inserted only on phalanges II, while the DDF inserted on phalanges III.

RH This limb was externally normal. The tarsal-metatarsal joint showed osteochondrosis (especially on the distal tibial surface) and the distal row of tarsals (centroquartal and fused 2 and 3) were cartilaginously joined to the proximal aspect of the large metatarsal. The lateral dewclaw sent an interdigital ligament, which attached to the lateral aspect of the fourth digit, and the medial dewclaw did the same to the medial aspect of the third digit. Aside from these abnormalities, all else was found to be within normal limits.

LH This limb also was externally normal and also showed a vertical fusion pattern within its tarsus via a partial joining of the fused second and third tarsus with the proximal large metatarsal bone. Three proximal sesamoids resulted from the fusion of each of the axial sesamoids of digits three and four. All other aspects of this limb were normal.

DISCUSSION

Most studies of the anatomy and genetics of syndactyly have involved the Holstein breed. Many cases, however, have been observed recently in black Angus. This study was designed to reveal possible differences of syndactyly as it occurs in the two breeds.

The most obvious difference was the pattern of morphological affliction. At first glance of either the syndactylous limb grossly or the following tables the external appearance would seem to have followed the right to left, front to back pattern previously described.^{16,17} However, if one closely examines the tables, the pattern is not present in the following case. Case #1017 had all four limbs involved, but when studying in detail the skeletal abnormalities it is noted that the right and left hind limbs had marked changes in the tarsal bones, while the carpals were only mildly deviant from normal. The tendons of the rear limbs also deviated greatly from accepted norms for position and insertion, while those of the front limb had slight changes only. This individual did not follow the pattern of expressivity of which there have been no exceptions in studies of the Holstein breed of cattle to date.

When comparing skeletal changes of the Aberdeen-Angus to the Holstein-Friesian breed, many similarities are observed, such as the enlarged metacarpals and metatarsals, extra dewclaws, and fusion of phalanges of same number but different digits (i.e. horizontal fusion). One extremely important difference was the fusion pattern, as evidenced by cases #1017 and #994, which had a vertical type of synostosis

involving the carpal/tarsal bones. This variation had been reported only once previously, where an Angus calf was found to have vertical synostosis of the second to third phalanges on all four digits of the front feet.¹⁵ Case #1017 was the best example of this pattern, as indicated by a synostosis of the fibular tarsal, lateral malleolus, and centroquartal bones, as well as the first, second, and third tarsals joined to the proximal aspect of the large metatarsal (conjoined Mt III and IV) on both rear limbs. Case #994 was not affected as severely nor did it involve the rear limbs; but the front right as both carpal rows formed a single bony structure as they fused both vertically and horizontally.

Vertical synostosis was not the only new finding through the study of syndactylia in Aberdeen-Angus cattle. Case #994 was affected on all four limbs, with the common horizontal fusion of phalanges on all but the two rear limbs, which varied from this pattern. The first and second phalanges of each digit were fused horizontally, yet the third phalanges were found unjoined and laid side by side within the single hoof only slightly divided from each other by a single distal sesamoid. Adrian reported finding at least three proximal sesamoids present in the hindlimb, no matter how great the severity of affliction.¹⁻³ In addition, he failed to report ever finding only a single proximal sesamoid. In our results, however, there were two such instances, which varied from those of the Holstein-Friesian breed. Case #1017 developed a single proximal sesamoid on both rear limbs, not previously reported. This is followed by cases #994 and #915, which both contained two proximal sesamoids in each of their rear limbs.

Certain tendon abnormalities were also observed. The first and most frequent change noticed was the presence of an "interdigital ligament" not previously reported in literature. Adrian, following his studies, mentioned only a "dewclaw plate" of deep fascia, which held the dewclaws in place, and stated that there were "no abnormal ligaments of the dewclaws."¹⁻³ This tendinous structure or interdigital ligament was present in half of the limbs studied and most often extended from the deep fascia near the dewclaw dorsally and distally to enter the soft inner tissues of the hoof wall. The structure was always singular and unattached to other ligamentous structures, but often extended from each dewclaw, especially in the more severely affected limbs. A variation in flexor tendons was also observed in case #1017, where flexors were found laying side by side on the palmar aspect of both hind legs. Each tendon remained separate from the other and extended distally, while having sent a branch to the dewclaw on its respective side only to continue to fetlock level where they fused together and inserted on all three phalanges.

Thus far, only the unique anomalies found in three of the seven animals studied have been described (all of which were purebred Angus cattle). The four remaining calves were all Angus/Holstein crosses and showed a semblance to both patterns of syndactylism previously mentioned. Case #955 had changes that were fundamentally similar to that of the Holstein-Friesian breed, including enlarged metacarpals and metatarsals, absence of the intertrochlear notch, and slight changes in flexor tendons, as well as all normal carpal and tarsal bones. Case #1022, however, while having developed all of the same abnormalities as #955, also presented a slight degree of vertical fusion through the

synostosis of the intermediate, ulnar, and first carpal bones of the right forelimb, as well as a moderate degree of vertical fusion via the joining of the fused second and third tarsals to the proximal aspect of the large metatarsal, as described in Angus cattle previously. Case #1023 had both varieties of synostosis in almost the same fashion as did the previous animal (#1022). The final specimen (#1024) supported earlier findings, as it also developed the previously described mixture of fusion patterns common to the Angus cross.

This study indicates that the most familiar form of synostosis (the horizontal form found predominantly in the Holstein-Friesian breed) is present in both the Angus and Angus cross cattle. However, a new pattern of fusion is now known to involve the Angus breed and, whereas the horizontal pattern seems to dominate the fusion of the phalanges, the vertical pattern controls fusion patterns within the carpus and tarsus.

ABSTRACT

Twenty-eight limbs from seven animals (three Angus and four Angus/Holstein-Friesian cross) were studied grossly, microscopically and radiographically to discover any changes from the known forms of syndactylism (primarily horizontal fusion) through previous studies of the Holstein-Friesian breed. Twenty of the limbs were affected and thus syndactylous with the remaining eight externally normal. Many similarities between the Angus specimens and previously described changes were noted, as well as several striking differences, including pattern of affliction, fusion pattern, number of proximal sesamoids, and tendon

abnormalities. The Angus-cross calves showed a combination of both patterns, with horizontal fusion the dominant finding concerning the phalanges and vertical synostosis more commonly occurring in the carpus and tarsus of the mixed-breed calves.

Syndactyly (syndactylism, syndactylia) is the partial or complete fusion of functional digits involving one or more feet noted in many breeds including Holstein-Friesian, Angus, Simmental, German Red Pied, Indian Hiriana cattle, and the Chianina breed. The condition is attributed to an autosomal recessive gene in Holstein-Friesian, Hiriana, and Chianina cattle while sex-linked transmission of the trait has been reported in the Simmental breed. The inheritance pattern of syndactylism in Angus cattle has yet to be studied. Following our studies, however, it must be mentioned that the condition is definitely familial and the great similarity in synostotic pattern, as well as tendon anomalies, to the Holstein-Friesian breed suggests that the same allele may be involved in both breeds.

REFERENCES

1. Adrian, R.W., H.W. Leipold, K. Huston, D.M. Trotter, and S.M. Dennis. (1969). Anatomy of hereditary bovine syndactylism. II. Muscles, tendons, ligaments. *J. Dairy Sci.*, 52: 1432-1435.
2. Adrian, R.W., D.M. Trotter, H.W. Leipold, and K. Huston. (1969). Anatomy of hereditary bovine syndactylism. III. Angiology. *J. Dairy Sci.*, 52: 1436-1440.
3. Adrian, R.W., D.M. Trotter, H.W. Leipold, and K. Huston. (1969). Anatomy of bovine hereditary syndactylism. IV. Neurology. *J. Dairy Sci.*, 52: 1441-1444.
4. Baker, R.D., G.W. Snider, H.W. Leipold, and J.L. Johnson. (1980). Embryo transfer tests for bovine syndactyly. *Theriogen.*, 13: 87.
5. Castleberry, S., J. Johnson, H.W. Leipold, G. Peeples, and R. Schalles. (1981). Embryo transfer and its effect on genetic research. *Theriogen.*, 19: 130.
6. Eldridge, F.E., W.H. Smith, and W.M. McLeod. (1951). Syndactylism in Holstein-Friesian cattle. Its inheritance, description and occurrence. *J. Hered.*, 42: 241-250.
7. Gruneberg, H. and K. Huston. (1965). The development of bovine syndactylism. *J. Embryol. and Exp. Morph.*, 19: 251-259.
8. Huston, K., F.E. Eldridge, and J.W. Mudge. (1961). Genetics of syndactylism in cattle. *J. Dairy Sci.*, 44: 1197.
9. Johnson, J.L., H.W. Leipold, G.W. Snider, and R.D. Baker. (1980). Progeny testing for bovine syndactyly. *J.A.V.M.A.*, 176: 549-550.
10. Krölling, O. (1956). Beitrag zur morphogenetischen und erbbiologischen Beurteilung der Syndaktylie beim Rinde. *Wien. tierarztl. Mschr.*, 43: 129-139.

11. Leipold, H.W. and J.S. Peeples. (1981). Progeny testing for bovine syndactyly. *J. Am. Vet. Med. Assoc.*, 179: 69-70.
12. Leipold, H.W., S.M. Dennis, and K. Huston. (1973). Syndactyly in cattle. *Vet. Bull.*, 43: 399-403.
13. Leipold, H.W., M.M. Guffy, and J.E. Cook. (1977). Syndactyly in cattle. *Comp. Pathol. Bull.*, 8: 305-307.
14. Leipold, H.W., K. Huston, and S.M. Dennis. (1983). Bovine congenital defects. *Adv. Vet. Sci. Comp. Med.*, 27: 197-271.
15. Leipold, H.W., K. Huston, M.M. Guffy, and S.M. Dennis. (1969). Syndactyly in an Aberdeen-Angus calf. *Am. J. Vet. Res.*, 30: 1685-1687.
16. Leipold, H.W., R.W. Adrian, K. Huston, D.M. Trotter, and S.M. Dennis. (1969). Anatomy of hereditary bovine syndactylism. I. Osteology. *J. Dairy Sci.*, 57: 1422.
17. Leipold, H.W., S.M. Dennis, K. Huston, D.M. Trotter, and R.W. Adrian. (1971). Anatomy of hereditary bovine syndactyly. V. External description. *Giessener Beitr. Erbp. Zuchthyg.*, 3: 6.
18. Leipold, H.W., K. Huston, S.M. Dennis, R.F. Cooper, and A. Dayton. (1973). Hereditary bovine syndactyly. I. Clinical-pathological observations. *Giessener Beitr. Erbp. Zuchthyg.*, 5: 139-157.
19. Ojo, S.A., H.W. Leipold, and C.M. Hibbs. (1975). Bovine congenital defects: Syndactyly in cattle. *J.A.V.M.A.*, 166: 607-610.
20. Rieck, G.W. (1972). Syndactylie beim Deutschen Rotbunten Rind. *Giessener Beitr. Erbp. Zuchthyg.*, 4: 1-13.

APPENDIX

Table 1: Animal Identification Number, Sex, Breed, Number of Feet Affected and State of Origin of 31 Syndactylous Cattle

Numerical Number	Identification	Sex	Breed	Feet Affected				State of Origin	Remarks
				RF	LF	RR	LR		
1	IV-1	male	Angus	sy	sy	sy	sy	California	-
2	IV-12	female	Angus	sy	sy	sy	sy	Oregon	-
3	IV-13	female	Angus	sy	sy	sy	sy	Oregon	-
4	IV-47	female	Angus	sy	sy	sy	sy	Minnesota	-
5	IV-48	male	Angus	sy	+	sy	sy	Minnesota	-
6	IV-49	female	Angus	sy	sy	sy	sy	Minnesota	-
7	IV-50	female	Angus	sy	sy	sy	sy	Minnesota	-
8	III-31	female	Angus	sy	+	sy	sy	Ohio	-
9	IV-133	female	Angus	sy	sy	sy	sy	Minnesota	-
10	IV-134	male	Angus	sy	sy	sy	sy	Minnesota	-
11	IV-135	male	Angus	sy	sy	sy	sy	Minnesota	-
12	IV-136	male	Angus	sy	sy	sy	sy	Iowa	-
13	VI-6	male	Angus	sy	sy	sy	+	Minnesota	-
14	VI-7	male	Angus/Holstein	sy	sy	sy	+	Illinois	fetus
15	IV-21	male	Angus/Holstein	sy	sy	sy	sy	Illinois	fetus
16	IV-9	male	Angus	sy	sy	sy	sy	Illinois	fetus
17	-	male	Angus/cross	sy	sy	sy	sy	Illinois	fetus
18	IV-160	male	Angus	sy	sy	+	+	Kansas	-
19	IV-159	female	Holstein/Angus	sy	sy	+	+	Illinois	fetus
20	IV-163	male	Holstein/Angus	sy	sy	+	+	Illinois	fetus
21	V-1	female	Holstein/Angus	sy	sy	+	+	Illinois	fetus
22	V-2	female	Holstein	sy	+	+	+	Illinois	fetus
23	V-3	female	Holstein	sy	+	+	+	Wisconsin	hyperthermia
24	V-4	female	Holstein	sy	+	+	+	Ohio	-
25	II-1	male	Holstein	sy	+	+	+	New York	-
26	VI-2	male	Angus	sy	sy	+	+	Kansas	-
27	VI-3	male	Angus/Holstein	sy	+	+	+	Kansas	-
28	VI-4	female	Angus/Holstein	sy	+	+	+	Kansas	-
29	VI-5	female	Angus/Holstein	sy	sy	+	+	Kansas	-
30	-	male	Angus/Holstein	sy	sy	+	+	Kansas	-
31	IV-176	female	Angus	sy	sy	+	+	Illinois	-
		female	Holstein/Chianina	sy	+	+	+	Illinois	-

sy = syndactylous

TABLE 2. Radiologic Findings in Forefeet of 17 Syndactylous Cattle

CALF #	METACARPUS		SMALL METACARPALS		PROXIMAL SESAMOIDS		PHALANGES					
	RF	LF	RF	LF	RF	LF	I		II		III	
							RF	LF	RF	LF	RF	LF
1	1T	1T	E	E	3	3	F	F	F	F	F	F
2	2T	2T	N	N	4	4	S	S	S	S	S	S
5	1T	2T	E	E	2	4	F	S	F	S	F	S
8	2T	2T	E	N	3	4	F	S	F	S	F	S
9	1T	1T	E	E	3	3	F	F	F	F	F	F
10	1T	1T	E	E	3	3	F	F	F	F	F	F
11	1T	1T	E	E	2	2	F	F	F	F	F	F
12	1T	1T	E	E	2	2	F	F	F	F	F	F
17	2T	2T	E	E	3	3	F	S	F	F	F	S
21	2T	2T	N	N	4	4	S	S	S	S	S	S
22	1T	1T	E	E	2	2	F	F	F	F	F	F
25	1T	1T	E	E	2	2	F	F	F	F	F	F
26	1T	2T	E	E	3	4	F	S	F	S	F	S
27	1T	2T	E	E	3	4	F	S	F	S	F	S
28	2T	2T	E	E	3	4	F	F	F	F	F	F
29	1T	1T	E	E	2	3	F	F	F	F	F	F
30	1T	2T	E	E	3	4	F	S	F	S	F	S

1T = one trochlea; 2T = two trochleas; N = normal; E = enlarged;
F = fused; S = separated; RF = right front limb; LF = left front limb

TABLE 3. Radiologic Findings in Hindfeet of 17 Syndactylous Cattle

CALF #	METACARPUS		SMALL METACARPALS		PROXIMAL SESAMOIDS		PHALANGES					
	RR	LR	RR	LR	RR	LR	<u>I</u>		<u>II</u>		<u>III</u>	
							RR	LR	RR	LR	RR	LR
1	1T	1T	E	E	3	3	F	F	F	F	F	F
2	2T	2T	N	N	4	4	S	S	F	F	F	F
5	2T	2T	E	E	4	3	F	F	S	F	S	F
8	1T	1T	E	E	3	3	F	F	F	F	F	F
9	1T	1T	E	E	3	3	F	F	F	F	S	S
10	1T	1T	E	E	3	3	F	F	F	F	S	F
11	1T	1T	E	E	2	2	F	F	F	F	F	F
12	1T	1T	E	E	1	1	F	F	F	F	F	F
17	2T	2T	N	N	4	4	F	F	F	F	S	S
21	2T	2T	E	N	3	4	S	S	F	S	F	S
22	2T	2T	N	N	4	4	S	S	S	S	S	S
25	1T	1T	E	E	2	2	F	F	F	F	S	S
26	2T	2T	N	N	4	4	S	S	S	S	S	S
27	2T	2T	N	N	4	4	S	S	S	S	S	S
28	2T	2T	N	N	4	4	S	S	S	S	S	S
29	2T	2T	N	N	4	4	S	S	S	S	S	S
30	1T	1T	E	E	2	3	F	F	F	F	F	S

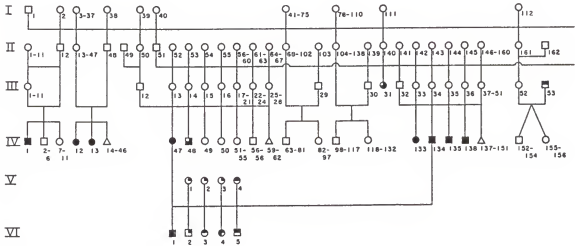
1T = one trochlea; 2T = two trochleas; N = normal; E = enlarged;
F = fused; S = separated; RR = right rear; LR = left rear

TABLE 4. Breeding Records for Syndactylous Cattle

Identification in figure 1		Mating type		Offspring			
SIRE	DAM	SIRE	DAM	Expected		Observed	
				Nrm1.	Syn.	Nrm1.	Syn.
II-12 x III-1 to III-11		father x daughter		9.5	1.5	10	1
II-48 x III-13 to III-47		halfsib matings		30	5	33	2
III-12 x III-13 to III-28		halfsib matings		13.7	2.3	12	4
III-29 x II-68 to II-102		suspected heterozygote x daughter of known heterozygote		30	5	35	0
III-30 x II-104 to II-138		suspected heterozygote x daughter of known heterozygote		30	5	35	0
III-32 x III-33 to III-51		halfsib matings		13.7	2.3	12	4
III-53 x III-52		syndactylous x suspected heterozygote		4	4	8	0
III-57 x III-54		syndactylous x suspected heterozygote		1.5	1.5	1	2
III-57 x III-56		syndactylous x suspected heterozygote		1	1	1	1
III-57 x III-62		syndactylous x syndactylous		0	1	0	1
IV-175 x IV-176 to IV-179		suspected heterozygote x syndactylous		3	3	5	1
IV-134 x IV-47; and V-1 to V-4		syndactylous x syndactylous		0	5	0	5
IV-162 x V-5		suspected heterozygote x syndactylous		0.5	0.5	0	1
V-6 x V-5		suspected heterozygote x syndactylous		1.5	1.5	2	1
V-8 x V-7		suspected heterozygote x syndactylous		3.5	3.5	7	0

TABLE 5. Genealogy of Syndactyly in Angus Cattle

Notice that all affected cattle trace to bull I-1 on maternal and paternal side



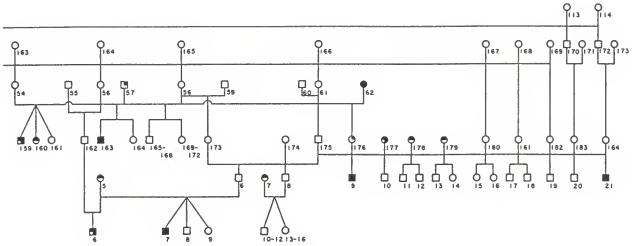


Figure 1

Figure 2

Figure 1 Male Angus calf affected with syndactyly of all four legs (case 1 in Table 1, necropsy 81-880). Right front foot (A), left front foot (B), right rear (C), and left rear (D). Notice single toe on each foot.

Figure 2 Volar view of feet depicted in Figure 1.

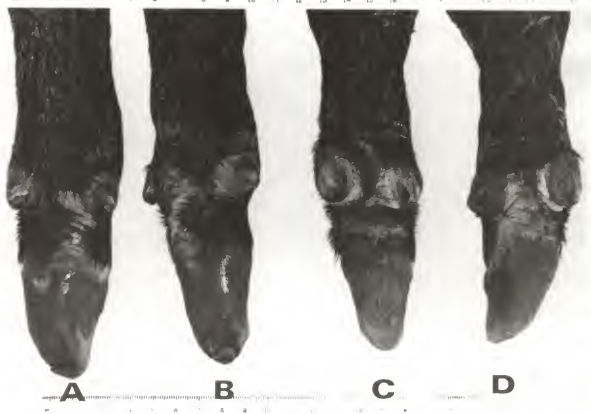
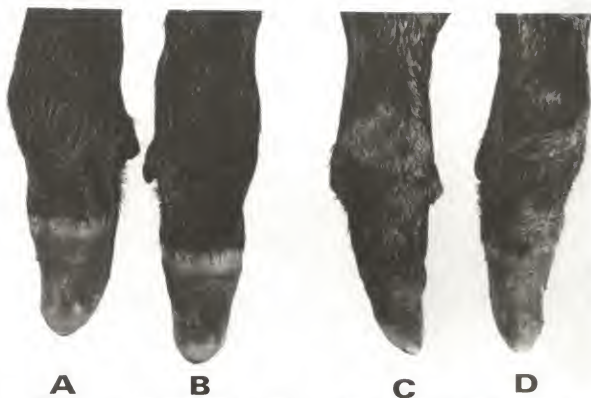

Figure 3 Figure 4

Figure 5 Figure 6

Figure 3 Calf 2 in Table 1, (necropsy 80-2173) Angus, affected with hereditary bovine syndactyly. Right (a) and left (b) front feet, dorsal view. Notice notch in single toe (arrow) indicating partial fusion.

Figure 4 Volar view of right (e) and left (f) front feet. Notice notch (arrow) in syndactylous hooves.

Figure 5 Hind feet of calf 2, right hind (m) and left hind (n) dorsal view. Notice completely fused hooves (arrow).

Figure 6 Planter view of hind feet, right (o) and left (q). Notice completely syndactylous hooves (arrow).

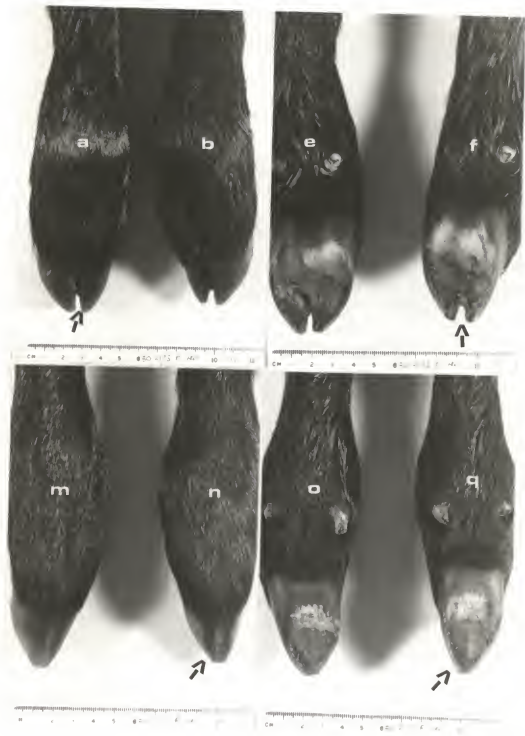


Figure 7

Figure 8

Figure 9

Figure 10

Figure 7 Right front foot of Angus calf affected with syndactyly
 on all four feet (male, case 10, necropsy 80-1298).

Figure 8 Left front foot.

Figure 9 Right hind foot.

Figure 10 Left hind foot.

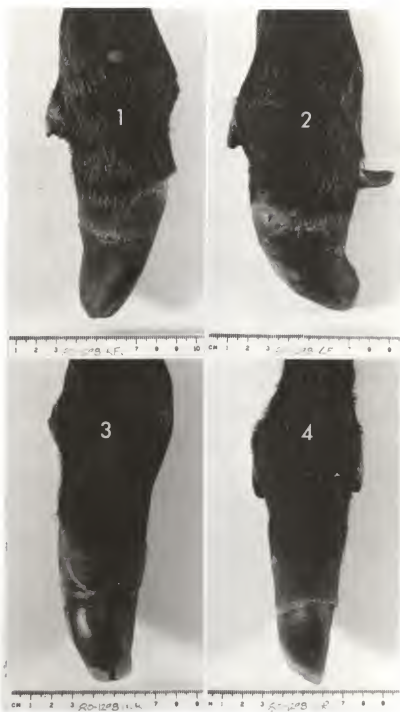


Figure 11 Figure 12

Figure 13 Figure 14

Figure 11 This Angus calf had three syndactylous feet (case 5, necropsy 80-1037). Notice syndactyly of right front.

Figure 12 This calf had a normal left front foot.

Figure 13 Right hind foot.

Figure 14 Left hind foot. Notice longitudinal groove on this hoof (left rear) indicating dual origin of this toe.



Figure 15 Figure 16

Figure 17 Figure 18

Figure 15 Right front foot of Angus calf case 25 with four feet syndactylous. Notice contracture of this digit (arrow).

Figure 16 Left front foot.

Figure 17 Right hind foot.

Figure 18 Left hind foot.

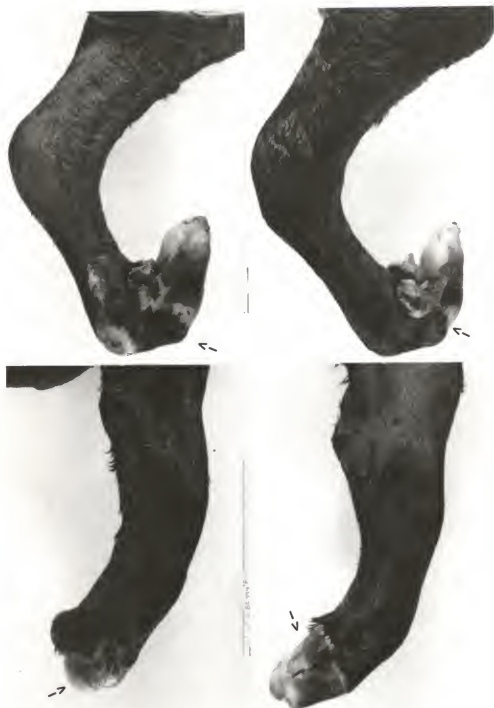


Figure 19 Figure 20

Figure 21 Figure 22

Figure 19 Angus calf affected with syndactyly of all four legs. Please refer to figure 15 to 18. Notice contractures of all four legs.

Figure 20 Angus/Holstein cross calf affected with complete syndactylous of the right front foot (a), partial syndactyly of the left front foot (b). Both hind feet were normal.

Figure 21 Angus/Holstein crossbred calf affected with complete syndactyly on both front feet (right, a; left, b). Hind feet were normal. (Case 27, necropsy 87-1024).

Figure 22 Angus/Holstein crossbred calf (case 26, necropsy 82-955) affected with syndactyly on 3 legs (RF, LF, RR). Left rear (d) is normal.

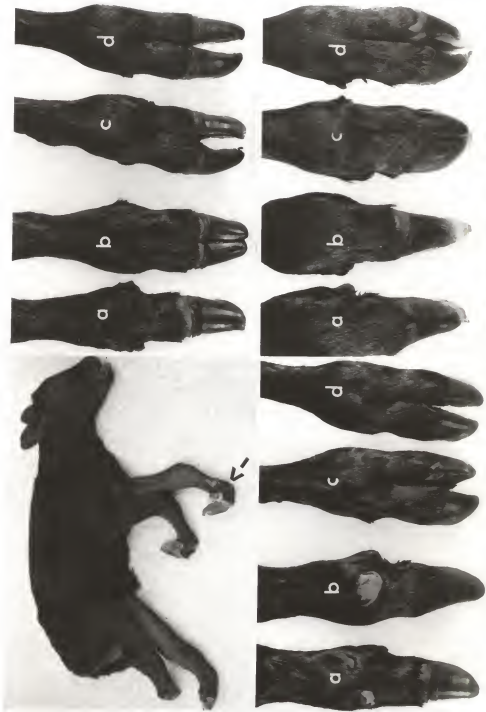


Figure 23

Figure 24

Figure 23 Angus fetus of 60 days gestation (case 13, necropsy 81-99) affected with syndactyly. Notice affected front feet (arrows).

Figure 24 Normal control fetus (81-101). Notice cloven hooves (arrow).

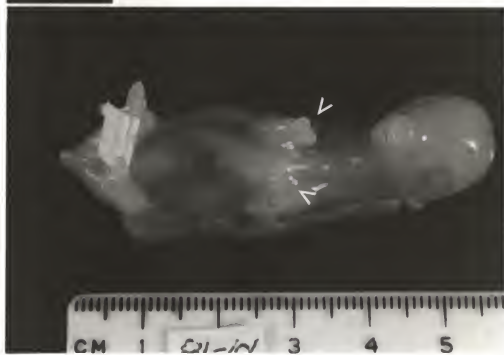
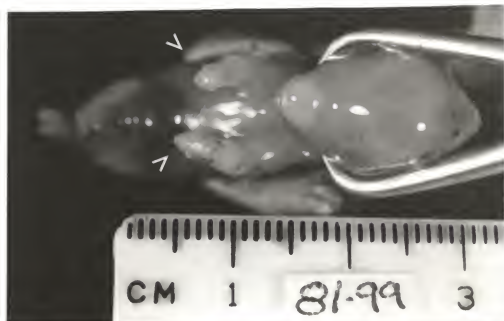


Figure 25

Figure 26

Figure 25 Radiograph of four legs affected with syndactyly (Angus calf 1, figure 1, necropsy 81-880). Notice that all four canon bones have only one distal trochlea. Phalanges I, II, and III are fused horizontally.

Figure 26 Radiographs (case 2, necropsy 80-2173) of Angus calf affected with partial external syndactyly on both front feet and complete external syndactyly on both hind feet. Notice this right front (a) and left front (b) have no fusion of phalanges. Notice distal trochlea on right rear (c) is normal and phalanges II and III are fused horizontally. Notice that the distal trochlea of the left rear (d) has only a notch and phalanges II and III are fused.

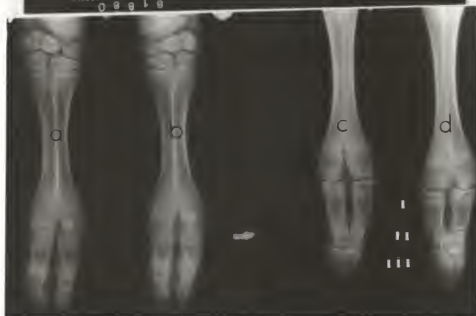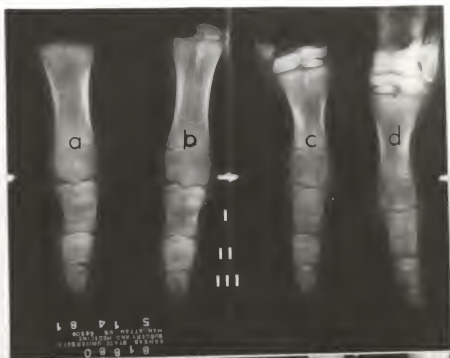


Figure 27

Figure 28

Figure 29

Figure 30

Figures 27 to 30 depict right front foot (A), left front foot (B), and right hind foot (C) and left hind foot (D) of Angus calf (case 10, necropsy 80-1298) affected with syndactyly of all four feet.

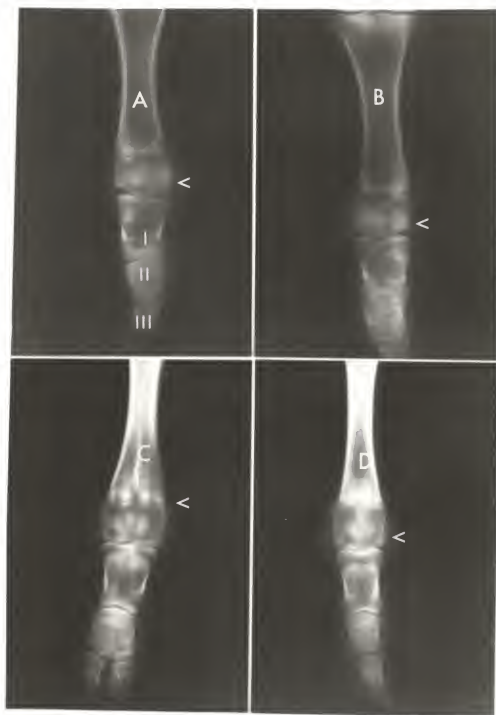


Figure 31

Figure 32

Figure 33

Figure 34

Figures 31 to 34 depict radiographs of an Angus calf (case 5, necropsy 80-103) with syndactyly of right front, right rear and left rear.

The left front foot is normal (Figure 32).

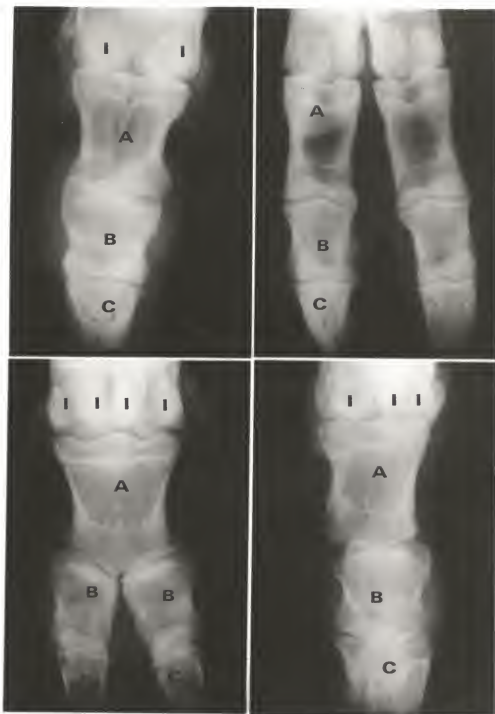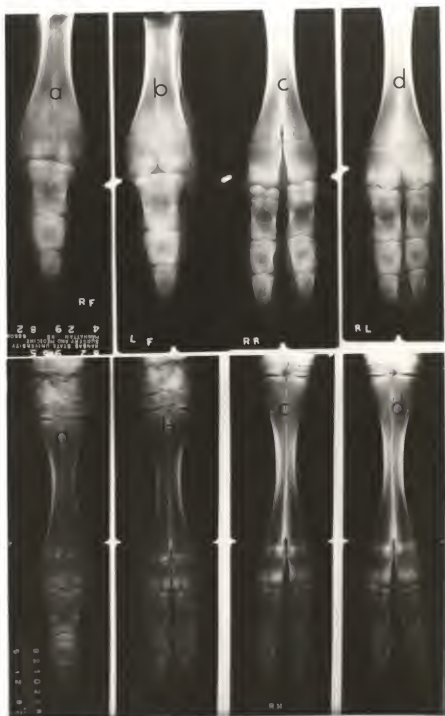


Figure 35

Figure 36

Figure 35 Radiograph of all four feet of Angus/Holstein crossbred calf (case 28, necropsy 82-955). Notice fusion of phalanges on front feet (right, a; left, b). The right rear had externally a syndactylous hoof but has no osteologic changes (right rear, c).

Figure 36 Radiograph of all four feet of Angus/Holstein crossbred calf (case 29, necropsy 82-1023). Both front feet were syndactylous upon external examination.



82-955 (fig 22, 35)

RF Externally, the limb had the appearance of a normal limb except for both dewclaws being enlarged with a fusion of the two claws to form a conical, single hoof tapering to a rounded end distally. All six carpal bones were normal. Metacarpals II and V were enlarged; and while II inserted into the medial dewclaw via a tendinous band, V had developed three rudimentary osseous structures (phalanges) that continued from the metacarpal (in a straight row) to articulate with the lateral dewclaw. The two dewclaws then were conjoined by a band of connective tissue similar to an interdigital ligament. There were three proximal sesamoids. The axial sesamoids of each digit (III and IV) were the ones joined. The two distal sesamoids formed a single bone and all phalanges of the third and fourth digits were fused horizontally, leaving a rough end but functional joint between each, as well as between the fused first phalanges and the distal articulation of metacarpals III and IV, which lacked an intertrochlear notch. The two extensor tendons fused at the level of the metacarpal-phalangeal joint and inserted on the proximal portions of P-1 and P-2. The superficial digital flexor (SDF) and deep digital flexor (DDF) were in normal positions but were joined at various points by several fibrous bands that prevented a smooth, "gliding" action. The two inserted at a common point on the third phalanx, while the SDF inserted solely on P-1 and P-2, not the normal pattern for insertion of the flexors.

LF Externally this limb was a mirror-image of the right front, with the medial dewclaw being slightly larger and the carpus wider. Again the carpal bones were all within normal limits, but metacarpals (MC) II and V were not as large and extended distally no further than the midshaft of metacarpals III and IV, only to insert into their respective dewclaws via a ligamentous structure. The two axial proximal sesamoids of each digit were fused to exhibit three proximals again and all phalanges of the third and fourth digits showed horizontal fusion patterns. There was one distal sesamoid present and all three distal joints were again functional yet uneven in their cartilaginous surfaces. The intertrochlear notch of the distal end of metacarpals III and IV was present, however it was reduced in depth and width. An interdigital-like ligament again had conjoined the two dewclaws firmly. Phalanges I, II, and III were all sites of insertion for the fused extensor tendons, which began as two and jointed at the fetlock level. The DDF inserted only on phalanges III, while the SDF inserted on all three phalanges only after having received a large thick band from the interosseous muscle at 2 inches above the proximal sesamoids.

RH This limb had normal external muscle and bone structures.

LH This limb seemed externally normal but the cleft between the claws was incomplete. The sagittal notch between the claws extended to the area of the metatarsal-phalangeal joint, rendering an illusion of a normal foot. No abnormalities were noted

concerning the tarsal bones or joints. The metatarsals (Mt) were enlarged, however, and each extended distally to a level of midshaft of metatarsals III and IV, where they both widened and sent a tendon distally to insert in their respective dewclaws. Within the medial tendon was an osseous structure of $\frac{1}{2}$ inch diameter and present at $\frac{1}{2}$ inch prior to the tendon's insertion. Four proximal sesamoids were present and no fusion of any of the phalanges or distal sesamoids was seen. The intertrochlear notch at the distal end of metatarsals of III and IV was slightly reduced but basically normal, as were both extensors and flexors despite a few fibrous adhesions between the SDF and DDF 1 inch distal to the tarsus.

82-1017

RF This limb was short and thick upon external inspection and at the knee a large ($1\frac{1}{2}$ inch diameter) scab was present, which revealed the difficulty the animal must have experienced when trying to walk on "mule feet". The truncated hoof was elongated and narrowed to a point as it deviated laterally. Both dewclaws were larger and set more dorsally on the limb. The carpus had developed in a slightly flexed position (about 135° angle from radius to the large metacarpals). All carpals were found to be normal, except for the nonfusion of the second and third of the distal row. Both metatarsals II and V had developed to a much greater degree than normal and had shown a "mushrooming" enlargement both proximally and distally. Two phalanges connected the

most medial metacarpal to the medial dewclaw, while three were present following metacarpal V into the lateral dewclaw. A small synovial joint had been formed between these small phalanges. The number of proximal sesamoids was two, due to a fusion of each pair (lateral and medial), while horizontal fusion of each of the phalanges of digits three and four had occurred. One large, irregularly shaped distal sesamoid was present and it had several fracture lines present within. Both extensor tendons remained independent throughout their course distally to insert each on all three fused phalanges, while only the lateral tendon sent a slip to the lateral dewclaw. Although both flexor tendons were found normally located, the DDF inserted on phalanges II and III, while the SDF inserted on phalanges I and II.

LF The left forelimb was very similar to the right fore, including the posteriorly angulated carpus, dorsally-located crust, and laterally deviated syndactylous hoof. In addition, the limb had developed an extra lateral dewclaw which, while not being as large as the normal pair, was somewhat enlarged itself. The irregularly-shaped radio-carpal joint contained many cavitations and clefts, especially on the distal radius. Fusion of the radial and intermediate of the proximal row of carpals, as well as the nonfusion of 2 and 3 characterized the carpus. The enlarged MC V was divided at its distal extent to coordinate with the extra lateral dewclaw. Upon having divided, each division formed two phalanges (the second of which resided within the horn of the dewclaw). The most medial metacarpal did not fork but did

seemingly form two "sets" of phalanges for an extra medial digit, as well as what could be described as a rudimentary proximal sesamoid for the second digit. Each "set" of phalanges contained two osseous structures, which both led to the horny segment of the lone medial dewclaw. The large MC bone had no intertrochlear notch present as it articulated with P-1. Only two proximal sesamoids were noted and all phalanges were again horizontally fused between digits 3 and 4. Again, the two extensors inserted on all three fused phalanges and the lateral of the two sent a branch to the extra lateral dewclaw, while the SDF inserted on P-1 and P-2 and the DDF inserted on P-2 and P-3.

RH A single, laterally deviated hoof and enlarged dewclaws described the external appearance of this limb. The enlarged lateral malleolus then was discovered to have been fused with the centroquartal (fourth and central) and fibular tarsal bones (Ft). This pattern of vertical fusion was followed by the distal row of tarsals, of which the first, second and third were all fused together and with the proximal extremity of the large Mt bones (III and IV). Mt II was entirely tendinous and contained an osseous segment at midshaft of Mt's III and IV, while Mt V was osseous and enlarged, forming two phalanges distally. While all phalanges of the third and fourth digits showed the common pattern of horizontal fusion and joint formation, there was only one proximal and one distal sesamoid present. The two extensor tendons remained separate along their routes and each sent fibers to its respective dewclaw and continued distally to insert on

phalanges I, II, and III. The two flexors imitated the extensors by laying side by side (medial/lateral) instead of in the normal position. They then sent branches to the dewclaw on their side before continuing distally to fuse near fetlock level and insert on all phalanges.

LH This limb was externally similar to all others of this animal, even though the toe showed slightly greater curvature dorsally than the others. Fusion patterns were identical to the right hind, with the lateral malleolus, fibular tarsal, central and fourth tarsals all fused solidly together, as well as the 2nd and 3rd tarsals fused to the proximal articulation of the large Mt. The second Mt was entirely tendinous with a bony segment within it at a level 1 inch above the proximal sesamoid (which was single). The most lateral Mt was not markedly abnormal. The phalanges were fused in the normal fashion, as was the distal sesamoid. A tendinous structure was found to connect the medial dewclaw with the deep fascia of the fetlock joint. The extensor and flexor tendons copied those of the right hind limb and thus will not be described again.

82-994 (fig 15-19)

RF Upon external evaluation of this limb, a rigid flexion was noted, as well as an extra horned growth near the medial dewclaw and a single truncated hoof. The radial, intermediate, and ulnar carpals were all fused and showed cartilaginous attachments to the

distal row of fused carpals (thus horizontal and vertical fusion both being present). Both MC II and V were larger than normal (with MC II being so large that it is articulated with the fused distal carpals). Two phalanges followed MC V and joined the lateral dewclaw, while MC II sent two phalanges into one of the medial dewclaws and ended as a ligament inserting on the other medial dewclaw, which contained an osseous segment within. Fused proximal sesamoids of the third and fourth digits resulted in the presence of two proximal sesamoids for this limb. The truncated hoof contained the syndactylous elements of digits 3 and 4, as well as a single distal sesamoid. An interdigital "band" originated at the two medial dewclaws and continued distally to join the syndactylous digits, as did a similar structure from the lateral dewclaw. The two extensors fused near the fetlock and inserted both on MC V and on P-1 of the fused digits. Flexors were found to be normal.

LF The left fore showed similar contracture to the right fore and also the additional medial dewclaw. The carpals also were identical to the right foreleg, with the exception of the absence of vertical fusion patterns between single proximal and distal rows. Mt II was elongated and larger than normal, extending almost to the fetlock joint. A large first phalanx articulated with the distal end of the long MC II and entered the most proximal of the medial dewclaws, which contained a small bony P-2. An identical articulation occurred 1 inch proximal to the previous and these phalanges entered the remaining medial dewclaw.

The most lateral MC, however, inserted into the lateral dewclaw, which contained two small bony segments via a ligament, which was approximately 1 3/4 inches in length. Two proximal sesamoids were noted and an interdigital ligament connected the dual medial dewclaws with the syndactylous digits. The extensor tendons were identical to those of the right foreleg and thus will not be described again. Flexor tendons were seen to fuse at midshaft of the large MC and inserted on P-2 and P-3 of the fused digits, as well as on each rudimentary phalanx articulating with the large second MC.

RH This limb again was flexed and syndactylous, with the presence of two dewclaws and an extra large medial claw equal in size to the horn of the fused third and fourth digits. All tarsal bones were found to be normal, with the exception of the joined central and fibular tarsal bones. Mt II was enlarged and extended distally into the extra claw, while MC V was absent. The third and fourth digits showed fusion of their first and second phalanges, yet the two P-3's were not fused and layed side by side and only slightly divided by a single distal sesamoid. The fused extensor tendons sent branches to both the medial and lateral dewclaws but not the extra medial claw. A poorly developed SDF tendon sent a slip of tendon to the extra claw, as well as to the lateral dewclaw but none to the medial dewclaw.

LH This limb was not as contracted as previous limbs but did show flexion of the fetlock joint, as well as medial deviation of the limb below the same joint. Each dewclaw was joined to the single hoof wall of the fused claws of digits three and four. The tarsus was normally formed, but the large Mt was extremely short and was without trochlea. Metacarpals II and V were each moderately enlarged and extended halfway to the fetlock joint where they ended as tendinous bands entering their respective dewclaws. Two proximal sesamoids were found to articulate normally. The distal phalanges of the third and fourth digits were not fused, while the proximals and middles were, and one distal sesamoid was present. Two extensors were noted and found to insert normally. The SDF tendon, however, sent a slip to the lateral dewclaw, while the DDF tendon sent a branch to the interosseus ligament and the two then inserted on the lateral proximal sesamoid.

82-915 (Note: All limbs were submitted without carpus/tarsus)

RF This limb had the common appearance of that of an older syndactylous animal, having an elongated hoof drawing to a point, which deviates laterally at its distal apex. The enlarged lateral and medial metacarpals were even distinguishable externally. The radiocarpal joint was again irregular, uneven, and contained cavitations, especially on the distal aspect of the radius. While MC V extended into the lateral dewclaw via a tendinous band, MC II developed two phalanges, which corresponded with the medial dewclaw and developed synovial joints between each. Two proximal

sesamoids were found and each sent a connective band to the dewclaw on that side. Each phalanx was horizontally fused to that of the corresponding digit within the horn surrounding digits three and four.

LF The external appearance of this limb was that of a syndactylous limb with dewclaws of greater size than normal and a lateral deviation distally. Metacarpals II and V were a copy of those of the right foreleg and thus are not described again. A fibrous band extended from each of the two proximal sesamoids to the corresponding dewclaw. Hemarthrosis was presented upon having opened the fetlock joint accompanied by irritated, inflamed synovial linings of the joint. Contained within the single hoof were the fused phalanges of digits three and four and a single distal sesamoid. Extensors and flexors of this limb were all within normal limits.

RH This limb was syndactylous with the toe deviated laterally. MT's II and V were both slightly larger than normal, yet neither was large enough to articulate with, or extend to, its respective dewclaw. Two proximal sesamoids were present and each had irregular articular surfaces. An interdigital ligament connected each dewclaw to the deep fascia near the fetlock joint below which were the three synostotic phalanges of the third and fourth digits and a single distal sesamoid. The fetlock joint surfaces showed evidence of osteochondritis and a large ($3/4$ " across, $1/2$ " deep)

cartilaginous joint mouse was present within. The extensor and flexor tendons were found to be basically normal in distribution and insertion.

LH The left hind was also syndactylous, with a laterally deviated toe. The two small MT's were absent, yet there was a small osseous structure within each dewclaw. The two proximal sesamoids present (due to a fusion of each pair for digits 3 and 4) also showed signs of partial fusion along with multiple fracture lines within, which signified the structural inadequacies of such a situation. These conformational problems caused an osteochondrosis of the fetlock joint, which resulted in a roughening of the distal articular surface of the large metatarsal bone, as well as an absence of any sagittal groove. Again there was a horizontal fusion of all phalanges, as well as the presence of a single distal sesamoid. The extensor and flexor tendons again were found to be within normal parameters.

82-1022

RF This syndactylous limb had enlarged dewclaws and a conical hoof that showed little deviation from the midline. The distal articular surface of the radius revealed many irregular, cavernous areas over the entire surface. Fusion of the ulnar and intermediate carpals then was noted, along with a normal distal row of carpals. Metacarpals II and V were both enlarged and each articulated with a first phalanx, which entered the respective

dewclaw containing an osseous second phalanx for each digit. Then, exiting from each dewclaw was an interdigital ligament, which extended distally to fuse with the hoof wall of the synostatic phalanges of digits three and four. There were four proximal sesamoids present (a new finding for a syndactylous limb!) and the distal sesamoid was single. The dual extensor tendons conjoined at fetlock level to insert only on the fused P-1, while flexors were normally developed and inserted.

LF This limb was normal upon external inspection, with the only exception being the slightly enlarged dewclaws. The proximal row of carpals showed fusion of the ulnar and intermediate carpal bones, while the first, second, and third carpals were fused (normal) in the distal row. Metacarpals II and V were only slightly enlarged (with the lateral of the two being more developed) and, while the 2nd metacarpal inserted into its dewclaw via a ligament, the 5th metacarpal articulated with a first phalanx followed by two more osseous segments of that digit, which were contained within the horn of the lateral dewclaw. The four proximal sesamoids present were all normal, as was the distal extent of the large metacarpal. All phalanges were normal, as were the two distal sesamoids (one present for each digit). The extensors were all found to be normal but the SDF sent a branch, which joined both the lateral dewclaw and the interdigital ligament present on that digit.

RH This limb was externally normal, aside from partial fusion of the 2nd and 3rd carpals to the proximal portion of the large MT and osteochondrosis of the tibial-tarsal joint. All other aspects of this limb were normal.

LH All aspects of this limb were found to be within normal limits.

82-1023 (fig 20, 36)

RF This limb was externally syndactylous, with the dewclaws moderately enlarged. Upon dissection, the ulnar and intermediate carpal bones were found to be fused and all others were normally formed. With the most medial MC ending proximal to the fetlock to continue as a ligamentous structure to the medial dewclaw, the most lateral MC split at the same level into two similar structures. The medial formed two phalanges, which entered the lateral dewclaw, while the lateral formed just one phalanx which entered the same dewclaw containing a large, roughened piece of bone. The fusion of the medial proximal sesamoid of the third and fourth digits resulted in the formation of three proximal sesamoids. As expected, there was no intertrochlear incision present on the distal articular surface of the large MC bone and all phalanges were horizontally fused to each other. There was a single distal sesamoid. All extensors and flexors were found to be within normal limits for a syndactylous limb.

LF Externally this limb showed a partial fusion of the hoof walls of the two claws. The ulnar and intermediate carpals were also found fused together, with all other carpal bones normally formed. There was no enlargement of either the fifth or second MC and dewclaws were of normal proportions, also. The distal end of the large MC bone showed a narrowing of the sagittal notch, combined with a reduction in size of the sagittal ridges. Three proximal sesamoids were present and similar to those of the right foreleg, with the center being larger than the other two. From that level distally, all aspects of the limb were normal with the exception of the partial fusion of the hoof wall.

RH This limb was normal not only externally but upon observation of dissected tarsals as well. Metatarsal V entered the lateral dewclaw (containing an osseous segment) via a ligament. Metatarsal II, however, first articulated with a single phalanx, then continued as a ligament into the lateral dewclaw and its bony center. From this lateral dewclaw exited an interdigital ligament, which connected the former to the latero-caudal aspect of the second digit. These were the only variations from normal that were noted.

LH Again, as with the right rear, this limb was found normal upon external inspection. The fused second and third tarsals were partially joined via cartilage to the proximal surface of the large MT. Both Mt II and V inserted into their respective dewclaws by use of a tendinous bond but the lateral of the two

interrupted its tendon with an osseous segment half way between origin and insertion. The medial dewclaw was also joined by a slip of tendon from both SDF and DDF but the lateral dewclaw was not. Hemarthrosis was found to be present in the tibial-tarsal joint along with slight osteochondrosis.

82-1024 (fig 21)

RF This limb had developed a single hoof which narrowed to a rounded end with moderate lateral deviation of the portion distal to the carpus. The carpus was normally formed, although all articular surfaces were noted to have been roughened, with some degree of osteochondrosis present therein. A thin tendinous-structure had replaced MC II and inserted into the medial dewclaw (it also contained a small osseous segment one quarter inch prior to insertion). Metacarpal V was, however, osseous and connected to the lateral dewclaw via a ligament. Just palmar and medial to this metacarpal was another ligamentous structure, which continued down the large MC and attached to a bony structure that articulated with two other such structures within the lateral dewclaw. The fusion of each pair of proximal sesamoids for digits three and four resulted in two proximal sesamoids larger in size than normal. The phalanges and distal sesamoid were fused in the normal manner of a syndactylous limb. The two extensor tendons present fused near the fetlock to insert on proximal portion of phalanges I only. Several fibrous adhesions between the SDF and DDF, as well as from the interosseous ligament and DDF, were noted

to have decreased the mobility of these structures. The SDF, meanwhile, sent a slip of tendon to each dewclaw, inserted distally on phalanges I and the proximal area of phalanges II, while the DDF inserted only on P-3.

LF This syndactylous limb was deviated laterally below the fetlock joint, which was covered by a large pressure sore (crust and thickening). The radial articulation of the radio-carpal joint was wavy with several cavitations. A fusion of radial and intermediate carpals was present along with a normal distal row of carpal bones. MC V was enlarged and forked at midshaft of the large metacarpal to send dual tendons to the lateral dewclaw, which contained several osseous structures. The second MC also inserted into its dewclaw via a tendon, yet it was single and the dewclaw contained only a single bone. Both dewclaws, however, sent an interdigital ligament to the horizontally-fused phalanges of the third and fourth digits. Also found were two proximal sesamoids and a single distal. Both extensor tendons reached the fetlock level, united and inserted on the proximal portion (extensor process) of the fused phalanges I only. Similarly, the flexors (DDF and SDF) were joined at various levels. The SDF inserted only on phalanges II, while the DDF inserted on phalanges III.

RH This limb was externally normal. The tarsal-metatarsal joint showed osteochondrosis (especially on the distal tibial surface) and the distal row of tarsals (centroquartal and fused 2 and 3)

were cartilaginously joined to the proximal aspect of the large metatarsal. The lateral dewclaw sent an interdigital ligament, which attached to the lateral aspect of the fourth digit, and the medial dewclaw did the same to the medial aspect of the third digit. Aside from these abnormalities, all else was found to be within normal limits.

LH This limb also was externally normal and also showed a vertical fusion pattern within its tarsus via a partial joining of the fused second and third tarsus with the proximal large metatarsal bone. Three proximal sesamoids resulted from the fusion of each of the axial sesamoids of digits three and four. All other aspects of this limb were normal.

HEREDITARY BOVINE SYNDACTYLY IN ANGUS AND CROSSBRED CATTLE

by

GARRET L. SCHMIDT

B.S., Kansas State University, 1983

D.V.M., Kansas State University, 1985

AN ABSTRACT OF A MASTER'S THESIS

submitted in partial fulfillment of the

requirements for the degree

MASTER OF SCIENCE

Department of Pathology

KANSAS STATE UNIVERSITY

Manhattan, Kansas

1985

Twenty-eight limbs from seven animals (three Angus and four Angus/Holstein-Friesian cross) were studied grossly, microscopically and radiographically to discover any changes from the known forms of syndactylism (primarily horizontal fusion) through previous studies of the Holstein-Friesian breed. Twenty of the limbs were affected and thus syndactylous with the remaining eight externally normal. Many similarities between the Angus specimens and previously described changes were noted, as well as several striking differences, including pattern of affliction, fusion pattern, number of proximal sesamoids, and tendon abnormalities. The Angus-cross calves showed a combination of both patterns, with horizontal fusion the dominant finding concerning the phalanges and vertical synostosis more commonly occurring in the carpus and tarsus of the mixed-breed calves.

Syndactyly (syndactylism, syndactylia) is the partial or complete fusion of functional digits involving one or more feet noted in many breeds including Holstein-Friesian, Angus, Simmental, German Red Pied, Indian Hiriana cattle, and the Chianina breed. The condition is attributed to an autosomal recessive gene in Holstein-Friesian, Hiriana, and Chianina cattle while sex-linked transmission of the trait has been reported in the Simmental breed. The inheritance pattern of syndactylism in Angus cattle has not been studied. Following our studies, however, it must be mentioned that the condition is definitely familial and the great similarity in synostotic pattern, as well as tendon anomalies, to the Holstein-Friesian breed suggests that the same allele may be involved in both breeds.