

ATTEMPTED TRANSMISSION OF BOVINE LYMPHOSARCOMA  
TO EX-AXENIC MICE

by

445

WAYNE MERLE GROVER

B.S., Kansas State University, 1963  
D.V.M., Kansas State University, 1965

---

A MASTER'S THESIS

submitted in partial fulfillment of the

requirements for the degree

MASTER OF SCIENCE

Department of Pathology,  
Parasitology, and Public Health

KANSAS STATE UNIVERSITY  
Manhattan, Kansas

1966

Approved by:

*Harry D. Anthony*  
Major Professor

LD  
2668  
T4  
1966  
G 883  
C. 2  
Document

TABLE OF CONTENTS

INTRODUCTION ..... 1

LITERATURE REVIEW ..... 2

MATERIALS AND METHODS ..... 9

    Donors ..... 9

    Specimens ..... 14

    Laboratory Animals ..... 16

RESULTS ..... 21

    Lymphosarcomatous Cow - Lymph Node Homogenate ..... 22

    Lymphosarcomatous Cow - Whole Blood ..... 24

    Lymphosarcomatous Cow - Milk ..... 26

    H.I. Herd Positive Cow - Lymph Node Homogenate ..... 26

    H.I. Herd Positive Cow - Whole Blood ..... 26

    H.I. Herd Positive Cow - Milk ..... 27

    H.I. Herd Normal Cow - Whole Blood ..... 28

    H.I. Herd Normal Cow - Milk ..... 29

    Normal Cow - Lymph Node Homogenate ..... 29

    Normal Cow - Whole Blood ..... 30

    Normal Cow - Milk ..... 31

    Noninoculated Controls ..... 31

DISCUSSION ..... 33

CONCLUSIONS ..... 38

ACKNOWLEDGMENTS ..... 39

LITERATURE CITED ..... 41

APPENDIX ..... 45

## INTRODUCTION

Bovine lymphosarcoma is the subject of many intensive research investigations at the present time. This neoplastic disease of the lymphoreticular system, also referred to as malignant lymphoma, leukemia, leukosis, lymphocytoma, and lymphoblastoma, has been designated as the most commonly encountered neoplasm of American cattle by Monlux et al. (1956), Smith and Jones (1961), and Squire (1964). The economic loss to the livestock industry because of bovine lymphosarcoma is significant, as emphasized by Moulton (1963).

Marshak et al. (1962) have characterized the disease with regard to clinical manifestations, pathological alterations, and the familial distribution of cases in high-incidence herds and state "... it is evident that, in many respects the cattle disease resembles lymphosarcoma in man." The clinical and pathological similarities of the lymphoreticular neoplasms of man and large domestic animals were observed also by Squire (1964).

The possibility of the same or similar factor(s) being responsible for bovine lymphosarcoma and human lymphosarcoma, as suggested by Marshak and Dutcher (1965) and Squire (1964), has intensified the research interest and activity on this disease. Dutcher (1964) suggested that knowledge gained about the basic nature, etiology, and transmission of bovine lymphosarcoma may provide insight into the factors responsible for human lymphosarcoma.

It was the intent of this investigation to attempt to produce a leukemia in ex-axenic mice by inoculating them with specimens obtained from (1) cattle with lymphosarcoma and (2) cattle from a herd with a high incidence of lymphosarcoma. Further studies on the leukemogenic factor(s) or agent(s) in these specimens were contingent to the production of leukemia in the ex-axenic mice.

#### LITERATURE REVIEW

A complete review of the literature dealing with bovine lymphosarcoma would be voluminous and was beyond the scope of this paper. A comprehensive monograph on hematopoietic tumors, including bovine lymphosarcoma, has been presented by Squire (1964). Dutcher (1965) and Marshak and Dutcher (1965) have reviewed the current status of bovine lymphosarcoma and cited numerous references with their work. This literature review was designed to summarize the numerous techniques applied to this problem, and emphasize the transmission studies attempted.

Genetic susceptibility to this disease has been suggested by Thielen et al. (1963). Because of the aggregation of animals with lymphosarcoma in sire groups and cow families, as determined by pedigree analysis, within certain high incidence herds, Marshak et al. (1962) and Croshaw et al. (1963) also postulated that these animals were genetically susceptible to lymphosarcoma. Both groups of authors stated, however, that the data are also compatible with vertical transmission of an infectious agent.

Viruses have been incriminated convincingly as the causative agents for similar lymphoreticular neoplastic disorders in the murine and avian species. Viral etiology for bovine lymphosarcoma has been proposed by many investigators. The epizootiology of the disease would indicate that it is a contagious condition with a long latent period, according to Bendixen (1963). Bendixen (1961) and Ritter (1964) also described the transmission of the disease to healthy cattle in previously unaffected herds by introducing cattle originating in herds with a high incidence of lymphosarcoma.

The long incubation period in cattle, if indeed this condition is infectious, and the economics of attempting to house large numbers of cattle for long periods of time encouraged investigators to utilize methods other than direct homologous transmission studies in an attempt to elicit the leukemogenic factor(s).

Hatziolos and Chang (1963) observed cellular elements resembling primitive reticular or lymphoid cells which contained numerous cytoplasmic inclusions in lymph node tissue from a lymphosarcomatous cow and grown in a cell culture system. When they inoculated normal lymph node cell cultures with lymphosarcomatous tissue extract, the sequence of cellular changes suggested the presence of a cytopathogenic agent. Gard (1963) observed changes in cell cultures of lymphosarcomatous lymph nodes that he attributed to the effect of a cytopathogenic agent. Gard also observed the formation of giant cells and syncytia, as did Dutcher *et al.* (1964), and postulated this

phenomenon was due to an oncogenic virus present in the cell culture.

Normal lymph node cell cultures are susceptible to the cytopathogenic effect of vesicular stomatitis virus, according to Dutcher et al. (1964a) and Kalk and Hetrick (1965). Dutcher (1964) observed that lymph node cell cultures from lymphosarcomatous cattle were resistant to the cytopathogenic effect of this virus. He also conferred protection on previously susceptible lymph node and kidney cell cultures by using undiluted supernatant fluid collected from resistant lymph node cell cultures. His explanation for this phenomenon was that a virus already present in the neoplastic cells would interfere with the cytopathogenic effect of the vesicular stomatitis virus.

Electron microscopy has revealed particles that morphologically resemble viruses in biopsied lymph nodes from cattle with lymphosarcoma. These observations were made by Sorensen and Thielen (1963), Uberschar (1963), and Dutcher (1965). Dutcher (1964) also described virus-like particles in the milk of cattle from a herd with a high incidence of lymphosarcoma, as well as in milk from cattle in a lymphosarcoma-free herd. To date, biologic activity has not been demonstrated for the particles described.

In addition to those previously mentioned, other approaches and techniques, such as attempted culture in embryonating chicken eggs, immunofluorescent studies, karyotyping, and transmission studies in laboratory animals have been used in an

attempt to provide additional knowledge about the etiology of bovine lymphosarcoma. Although much indirect and some direct evidence to support the theory of viral etiology for this condition has been presented, the actual isolation of an agent capable of reproducing the disease syndrome in cattle or other animals has yet to be reported.

Many attempts have been made to transmit the disease to susceptible cattle, but only Götze et al. (1956), Rosenberger (1961), and Trapp et al. (1966) have reported causing the tumorous syndrome in cattle by inoculating them with material obtained from cattle affected with lymphosarcoma. Other authors, such as Winqvist (1961), Papparella et al. (1963), Bederke and Toll (1964), and Hatzios et al. (1966) have recorded the development of a persistent lymphocytosis, lymphoid hyperplasia, or other lesions some investigators consider "preleukemic" in cattle inoculated with specimens from lymphosarcomatous cattle. Negative results in the attempted horizontal homologous transmission of bovine lymphosarcoma have been reported by Creech and Bunyea (1929), Dutcher et al. (1963), and McKercher et al. (1963), as well as other authors.

The ability of an agent(s) to reproduce similar diseases in other species has not been proven, although Schwartz et al. (1957), DeLong (1960), Nielson et al. (1965), and Chapman et al. (1966a), as well as other investigators have reported the development of leukemia in mice inoculated with material from human leukemic patients.

The initiation of lymphosarcoma or leukemia in laboratory animals, primarily mice, exposed to materials from cattle with lymphosarcoma has been attempted many times. In 1929, Creech and Bunyea (1929) reported on their observations of rabbits inoculated intravenously and guinea pigs inoculated intraperitoneally with blood and tumor-tissue suspensions from a cow with leukemia. A postmortem examination was performed on the experimental animals that died and those euthanatized one year postinoculation. None of the rabbits or guinea pigs developed signs or lesions characteristic of leukemia.

A virus isolated from a calf with lymphatic leukemia and cultured in embryonating chicken eggs was harvested from the 32nd egg passage and inoculated intraperitoneally into 20 young and 20 adult guinea pigs by Papparella (1959). Heat-inactivated virus was inoculated into 10 young and 10 adult guinea pigs for controls. Subsequent examination of the blood of the experimental animals revealed a lymphocytosis with an occasional lymphoblast and an anemia. Young guinea pigs were more susceptible, but there was a low mortality. The virus was recovered from the dead guinea pigs by chicken embryo inoculation. Papparella (1960) subsequently reported on the development of progressive and extensive alopecia, with ultimate death, in five of the 19 guinea pigs that had lived more than two months postinoculation.

Dutcher et al. (1963) made repeated attempts to propagate bovine lymphosarcoma tissue-culture cells in the cheek pouch of hamsters with no success. Dutcher et al. (1963) also inoculated



800 newborn or 3-week-old C<sub>3</sub>H or Swiss mice intraperitoneally or intracranially with blood, serum, or tumor extracts from cattle with bovine lymphosarcoma, as well as tumor tissue culture supernatant fluid or cell suspensions. These mice, and appropriate control mice, were observed for 16-20 months. Any mice that died were necropsied, as were the remaining mice that were euthanized at the end of the observation period. Neoplasms had developed in less than 1% of the mice.

Tolle et al. (1962) reported on the inoculation of NMRI mice with "bovine leucotic tissue." A "tumor" developed which was subsequently passed serially 19 times before intercurrent infection terminated the experiment. In further experiments, "murine tumor tissue" that had been stored 4-9 months at -39 C., or "fresh bovine leucotic material" was inoculated into 5,800 newborn mice. Nephrosis was found in the male mice killed 8-18 weeks postinoculation, but was absent in female and control mice. Hemangioendothelioma and reticulum-cell neoplasms developed at the site of inoculation 5-6 months postinoculation, but "there was no evidence of leucosis."

McKercher et al. (1963) reported on the results of inoculating one-day-old mice intraperitoneally or intracranially with a virus isolated from a cow with leukemia and propagated in tissue culture. Although the virus survived, as determined by tissue culture inoculation, two serial passages using the intracranial route in mice in one attempt, and four serial passages using the same route of inoculation in another attempt, there was no clinical illness and no gross or histopathologic lesions

suggestive of neoplasia. Attempts to adapt the virus to mice by intraperitoneal inoculation also were unsuccessful.

Three presumably identical agents were isolated by Lange (1965) from lymph nodes of cattle with lymphosarcoma and subsequently from a mouse inoculated with material from these cattle. These agents had a cytopathogenic effect in tissue culture systems, could be inactivated by freezing and thawing, as well as by heat, and would pass through bacteria-tight Seitz filters. He did not state if the mouse from which the agent was isolated had lesions, although in a previous publication Lange (1964) described lesions in mice inoculated with cell-free extracts from cattle with bovine lymphosarcoma. These lesions in the kidney, liver, spleen, and lymph node developed 2-6 months post-inoculation and the percentage of lesions increased in serial passages.

In 1963, Papparella et al. (1963) reported on 107 newborn Swiss mice receiving intraperitoneally a virus which had been isolated from a calf with lymphatic leukemia and cultivated in tissue culture cells. Controls consisted of 102 newborn mice similarly exposed to heat-inactivated virus from the same source and 222 noninoculated mice. After observing the mice for 3-12 months, 20% of the mice receiving active virus, 5% of the mice receiving inactive virus, and 1% of the noninoculated mice had mammary tumors which were morphologically similar in all groups. Attempted recovery of the virus from the mammary tumors was unsuccessful.

Hatziolos et al. (1966) were the first American investigators to report on the development of leukemia in mice inoculated with specimens obtained from animals with bovine lymphosarcoma. They described lesions that developed in the mice which were related to the inocula as lymphoid leukemia, leukemoid disease, splenomegaly, and/or mammary gland tumors. Attempted serial transmission of the leukemia in mice was unsuccessful.

## MATERIALS AND METHODS

### Donors

Specimens obtained from four categories of cattle were used for mouse inoculation: (1) field cases of bovine lymphosarcoma, (2) animals from a high-incidence herd that were classified positive by applying the criteria established by Bendixen (1963) to their hemograms, (3) animals from this same herd that were hematologically normal according to the Bendixen key, and (4) clinically normal cattle.

Field cases of suspected bovine lymphosarcoma were referred by Kansas veterinarians. Specimens were obtained from these animals if the clinical evaluation warranted a diagnosis of lymphosarcoma. Hematologic and histopathologic evaluations were correlated with the clinical evaluation to confirm the diagnosis. The hemograms (Table 1) of the donor animals were prepared at the time the specimens were collected.

LB-2 was a 5-year-old Hereford female with progressive posterior weakness for one week. At the time of biopsy of the

Table 1. Clinical and Hematologic Data of Animals Which were Sources of Specimens for Mouse Inoculation

| Number                                 | Breed                 | Age<br>Years | Temp.* | %<br>FCV* | %<br>WBC* | %<br>Band* | %<br>Seg.* | %<br>Eos.* | %<br>Mono.* | %<br>Lymph.* | Total*<br>Lymph. |
|--|-----------------------|--------------|--------|-----------|-----------|------------|------------|------------|-------------|--------------|------------------|
| LB-2                                   | Hereford              | 5            | 38.0   | 21        | 7,700     | 0          | 28         | 7          | 2           | 63           | 4,851            |
| LB-3                                   | Shorthorn             | 10           | 38.8   | 27        | 8,350     | 0          | 31         | 3          | 4           | 62           | 5,177            |
| LB-4                                   | Aberdeen<br>Angus     | 9            | 38.5   | 36        | 17,300    | 0          | 26         | 2          | 6           | 66           | 11,418           |
| LB-5                                   | Holstein-<br>Friesian | 4            | 39.4   | 33        | 14,600    | 9          | 51         | 1          | 3           | 36           | 5,256            |
| LB-6                                   | Holstein-<br>Friesian | 6            | 38.3   | 30        | 14,200    | 1          | 23         | 1          | 2           | 73**         | 10,366           |
| LB-7                                   | Holstein-<br>Friesian | 6            | 38.9   | 37        | 13,250    | 5          | 41         | 1          | 1           | 53           | 6,890            |
| <u>Cattle from high-incidence herd</u> |                       |              |        |           |           |            |            |            |             |              |                  |
| #1596<br>Annie                         | Holstein-<br>Friesian | 5            | ....   | 27        | 6,250     | 0          | 46         | 3          | 2           | 49           | 3,063            |
| #025<br>Mary                           | Holstein-<br>Friesian | 9            | ....   | 39        | 30,950    | 0          | 4          | 1          | 2           | 93           | 28,754           |
| #6035<br>Ruth                          | Holstein-<br>Friesian | 4            | ....   | 40        | 17,700    | 0          | 14         | 3          | 2           | 81+          | 14,377           |
| #2784<br>Bobbie                        | Holstein-<br>Friesian | 3            | 38.6   | 38        | 101,250   | 0          | 1          | 0          | 1           | 98†          | 99,225           |
| <u>Normal cattle</u>                   |                       |              |        |           |           |            |            |            |             |              |                  |
| LB-9                                   | Holstein-<br>Friesian | 2            | 38.8   | 35        | 7,050     | 0          | 31         | 6          | 3           | 60           | 4,230            |
| LB-10                                  | Holstein-<br>Friesian | 2            | 38.6   | 38        | 8,750     | 0          | 32         | 2          | 0           | 66           | 5,775            |

\* Column headings represent: Temp., Temperature in degrees Celsius; PCV, Packed cell volume; WBC, Leukocytes/cmm.; Band, Immature neutrophil; Seg., Mature neutrophil; Eos., Eosinophil; Mono., Monocyte; Lymph, Lymphocyte; and Total Lymph., Total lymphocytes/cmm.

\*\* Eight atypical lymphocytes

† Two atypical lymphocytes

‡ Majority of lymphocytes atypical

right prefemoral lymph node she was unable to rise, emaciated and had a generalized lymphadenopathy of all palpable lymph nodes.

LB-3 was a 10-year-old Shorthorn female which also had a history of progressive posterior weakness. There was no anorexia or cachexia, and none of the external palpable lymph nodes were enlarged. However, the rectal, internal inguinal, and internal iliac lymph nodes were markedly enlarged. The left internal iliac node was approximately 15 cm. by 25 cm. A biopsy was not taken, as the owner was unwilling to submit the animal for euthanasia. However, the clinical observations warranted the presumptive diagnosis of lymphosarcoma.

Tachycardia and ventral subcutaneous edema were prominent signs of disease in LB-4. This 9-year-old Aberdeen Angus cow was ambulatory, but had difficulty in rising and walking, as she was weak and emaciated. There was a generalized lymphadenopathy of the subcutaneous lymph nodes, as well as those nodes palpable per rectum. The right prescapular lymph node was selected for biopsy because it was extensively enlarged, measuring approximately 10 cm. by 15 cm. This enlargement was found to be quite vascular at biopsy, and many vascular spaces as well as an abundance of lymphocytes were observed on histopathologic examination. Subsequent microscopic examination, after necropsy, of other involved nodes revealed lesions histopathologically consistent with those expected of bovine lymphosarcoma.

A concurrent uterine infection complicated the diagnosis of lymphosarcoma in cow LB-5. This 4-year-old Holstein-Friesian female was one month postpartum and had decreased milk production. Anorexia, pyrexia, emaciation, fetid mucopurulent vaginal discharge, and an enlarged uterus that was firm and "doughy" on palpation established a diagnosis of pyometra. However, there was a generalized enlargement of the palpable lymph nodes, and the nodes palpable per rectum were especially prominent. Subsequent histopathologic examination of the left prescapular lymph node obtained by biopsy and other internal nodes obtained at necropsy confirmed the diagnosis of lymphosarcoma.

LB-6 was a 6-year-old Holstein-Friesian female that had an onset of progressive posterior weakness starting two weeks after a normal parturition. At the time of examination, one month postpartum, she was not ambulatory, had a generalized lymphadenopathy and a firm, greatly thickened uterine wall. After obtaining a biopsy specimen from the right prescapular lymph node, the animal was euthanatized and a postmortem examination was performed. Enlargement of the internal lymph nodes was generalized, hepatic and renal infiltration was observed, and the uterine wall was up to 7 cm. thick in some areas.

A 6-year-old Holstein-Friesian female, LB-7, had anorexia, decreased milk production, and was "not doing well" according to the owner. Clinical examination revealed a generalized lymphadenopathy of the subcutaneous lymph nodes, with the right parotid node being especially prominent. None of the nodes palpable per rectum were enlarged to any extent. A tissue

specimen was obtained by biopsy of the right prefemoral lymph node (Appendix, Plate I, Figs. 1 and 2).

A dairy herd with a high incidence of lymphosarcoma was purchased by Kansas State University for investigational purposes. Animals in this herd were made available for this study. According to Mussman (1965), this herd of 30-35 mature Holstein-Friesian cows had three animals which were confirmed histopathologically as being affected with lymphosarcoma in the years 1964-1965 and four additional animals that had the gross pathologic lesions characteristic of the disease in the years 1961-1965. Animals from this herd have been grouped as positive, suspect, or normal by applying the Bendixen (1963) key to their hemograms. On October 1, 1965, 8 cows were classified as positive, 6 as suspect, and 25 as normal. Specimens (Appendix, Plate II, Figs. 1 and 2) obtained from animals in this herd classified as normal, as well as some classified positive, were utilized in this investigation.

Specimens (Appendix, Plate III, Figs. 1 and 2) were obtained from clinically normal cattle for control purposes. The criteria used to define "normal" cattle were those established by Dutcher et al. (1963). These "normal" animals did not exhibit clinical signs of lymphosarcoma and originated in a herd that did not have a history of this disease. None of the cattle in this herd had a lymphocytosis, nor did the donor animals have a lymphocytosis on repeated sampling. From the herd history available, there were no animals in this herd that had a close familial relationship to cattle having lymphosarcoma.

## Specimens

The specimens collected from each donor animal were a lymph node and whole blood. Milk also was obtained if the animal was lactating. Enlarged lymph nodes were excised by surgical biopsy, employing sterile surgical procedure. The surgical site was shaved, washed thoroughly, and a surgical disinfectant\* was applied for 3 minutes. Infiltration with a local anesthetic, 2% lidocaine\*\*, and head restraint were the primary means of controlling the animal. After removal of an involved node, or a portion of it, the incision was sutured with one-eighth inch umbilical tape.

The excised tissue was divided into two portions. One portion was placed immediately in tissue culture medium, Basal Medium, Eagles (BME), containing 100 units of crystalline potassium penicillin G and 0.1 mg. of crystalline dihydrostreptomycin sulfate per ml. of medium. This tissue was minced with scissors into pieces approximately 3 mm. in diameter. If the trip to the laboratory was in excess of 3 hours, the tissue was refrigerated at 4 C. until it could be processed. It was not refrigerated if the specimen was collected close to the laboratory, but was kept at approximately 25 C.

In the laboratory, the lymph node tissue in BME was prepared for mouse inoculation by washing in phosphate-buffered

---

\* Nolvosan, Fort Dodge Laboratories, Fort Dodge, Iowa.

\*\* Xylocaine, Astra Pharmaceutical Products, Inc., Worcester, Mass.



saline until it was free of blood. Two gm. of tissue were then homogenized in a ground glass homogenizer, resuspended in 10 ml. of BME, and placed in a screw-cap tube until it was inoculated. Inoculation was always performed within 30 minutes, and usually within 10 minutes, of the time the inoculum was prepared.

Formalin fixation was accomplished by placing lymph node specimens, cut 5 mm. thick, in at least ten times the volume of 10% buffered formalin. After sectioning the tissue at 5 microns and staining it with hematoxylin and eosin, it was studied histopathologically.

Whole blood was collected by jugular venipuncture. The collection site was shaved, scrubbed, and disinfected as previously described. Sterile equipment and technique were used for obtaining the blood specimens. Blood was drawn into a 10-ml. syringe through a 16-gauge,  $1\frac{1}{4}$ -inch needle, and 10 ml. were transferred immediately to each of three screw-cap tubes, which contained three drops of a 10% solution of the sodium salt of ethylenediaminetetraacetate (EDTA). One specimen was for mouse inoculation, one for doing a complete blood count (Table 1), and one was held as a reserve. The blood specimens collected in EDTA were refrigerated at 4 C. if the estimated arrival time at the laboratory was in excess of 3 hours. For shorter periods, the specimens were maintained at 25 C.

Milk specimens were collected from lactating cows that had no clinical evidence of acute or chronic mastitis. The mammary gland was cleaned, the teat and teat orifice disinfected with a

disinfectant solution,\* and after discarding approximately 2 ml. of the foremilk, a 10-ml. sample was obtained in a sterile screw-cap tube. One hundred units of crystalline potassium penicillin G and 0.1 mg. of crystalline dihydrostreptomycin sulfate were added per ml. of milk. This milk was used for mouse inoculation.

#### Laboratory Animals

The laboratory animals for these studies were ex-axenic mice of the Carworth Farm White (CFW) strain and CFW<sub>w</sub> substrain as described by Werder et al. (1966). A colony of the CFW mice has been maintained as a closed colony since 1958 and is designated as the CFW<sub>w</sub> substrain. In 1962, some of these CFW<sub>w</sub> mice were used to establish a gnotobiotic colony of mice.

Mice were divided into groups of four to eight animals, depending upon the size of the litters available. Grouping was random on the basis of sex. All of the animals inoculated were less than 14 days of age at the time of inoculation, and most were 3-10 days old. An adult female ex-axenic mouse also was included in each group to nurse the experimental animals. She was removed when the young mice were 21-28 days old. All of the mice in a group received the same inoculum and they were inoculated the same day they were removed from the Trexler-Reynolds (1957) plastic germ-free isolators.

---

\* Nolvosan. Ft. Dodge Laboratories, Ft. Dodge, Iowa.

The number, age, sex, and strain of mice in each group, as well as the inoculum received, are presented in Table 2. A summary of the number of groups that received each type of inoculum can be found in Table 3.

These animals were placed in a sterile cage containing bedding\* immediately after removal from the germ-free isolator. Sterilization was accomplished by autoclaving for 20 minutes at 15 pounds pressure. Sterile tap water for animal consumption was placed in previously sterilized bottles. The mice were provided a sterile ration,\*\* formulated to provide the minimum murine nutritional requirements after sterilization by autoclave. A cardboard top with vented areas covered by an absolute cambridge filter,† previously sterilized by spraying with an aerosol of peracetic acid, was taped over the top of the cage to prevent air contamination.

A procedure was established whereby the mice were inoculated without coming in contact with any contaminated objects. A hood was utilized to negate the possibility of air contamination. All of the inocula were 0.1 ml. in volume and all were administered intraperitoneally. After inoculating the mice, the remaining inoculum was cultured in thioglycollate broth.‡

---

\* Deodor grade San-I-Cell, Laurel Farms, White House Station, New Jersey.

\*\* Special Formula 5010, Ralston-Purina Company, St. Louis, Missouri.

† Jayhawk Box, Lawrence Paper Company, Lawrence, Kansas.

‡ Difco Laboratories, Detroit, Michigan.

Table 2. Data on Each Group of Mice and Inoculum Administered to Each Group

| Group | Inoculum  | Strain of mice   | Age at inoc. (days) | No. of mice |
|-------|---|------------------|---------------------|-------------|
| 1     | Blood - Nor.* cow #1596 from H.I.** herd        | CFW              | 12-14               | 7           |
| 2     | Milk - Nor. cow #1596 from H.I. herd            | CFW              | 5-12                | 7           |
| 3     | Blood - Pos.* cow #025 from H.I. herd           | CFW <sub>w</sub> | 1-10                | 7           |
| 4     | Blood - Pos. cow #6835 from H.I. herd           | CFW <sub>w</sub> | 1-10                | 6           |
| 5     | Noninoculated controls                          | CFW <sub>w</sub> | 1-10 <sup>†</sup>   | 6           |
| 7     | Blood - Lymphosarcomatous cow LB-2              | CFW <sub>w</sub> | 5                   | 4           |
| 8     | Node - Lymphosarcomatous cow LB-2               | CFW <sub>w</sub> | 5                   | 5           |
| 9     | Milk - Lymphosarcomatous cow LB-2               | CFW <sub>w</sub> | 5                   | 3           |
| 10    | Blood - Lymphosarcomatous cow LB-3 <sup>+</sup> | CFW <sub>w</sub> | 14                  | 6           |
| 11    | Noninoculated controls                          | CFW <sub>w</sub> | 14 <sup>+</sup>     | 6           |
| 12    | Node - Lymphosarcomatous cow LB-4               | CFW <sub>w</sub> | 14                  | 6           |
| 13    | Blood - Lymphosarcomatous cow LB-4              | CFW              | 14                  | 5           |
| 14    | Node - Lymphosarcomatous cow LB-5               | CFW              | 7                   | 7           |
| 15    | Blood - Lymphosarcomatous cow LB-5              | CFW              | 7                   | 6           |
| 16    | Node - Lymphosarcomatous cow LB-6               | CFW <sub>w</sub> | 14                  | 5           |
| 17    | Blood - Lymphosarcomatous cow LB-6              | CFW <sub>w</sub> | 14                  | 5           |
| 18    | Node - Lymphosarcomatous cow LB-7               | CFW <sub>w</sub> | 5                   | 8           |
| 19    | Blood - Lymphosarcomatous cow LB-7              | CFW <sub>w</sub> | 5                   | 8           |
| 20    | Node - Pos. cow #2784 from H.I. herd            | CFW <sub>w</sub> | 3                   | 8           |
| 21    | Blood - Pos. cow #2784 from H.I. herd           | CFW <sub>w</sub> | 3                   | 8           |
| 22    | Milk - Pos. cow #2784 from H.I. herd            | CFW <sub>w</sub> | 3                   | 8           |
| 23    | Node - Normal cow LB-9                          | CFW <sub>w</sub> | 5                   | 6           |
| 24    | Blood - Normal cow LB-9                         | CFW <sub>w</sub> | 5                   | 5           |
| 25    | Node - Normal cow LB-10                         | CFW              | 3                   | 6           |
| 26    | Blood - Normal cow LB-10                        | CFW              | 3                   | 6           |
| 27    | Milk - Normal cow LB-10                         | CFW              | 3                   | 4           |
| 32    | Noninoculated controls                          | CFW              | 7 <sup>‡</sup>      | 6           |

\* Normal and Positive refer to hematologic rating on the Bendixon key.

\*\* H.I. herd is high-incidence herd owned by Kansas State University.

<sup>+</sup> No histopathologic confirmation available on this cow.

<sup>‡</sup> Age at which animals were removed from germ-free isolators.

Table 3. A Summary of Groups of Mice by Inocula Administered

| Donor animals                          | Inoculum | Number of groups | Number of mice |
|--|----------|------------------|----------------|
| Lymphosarcomatous cows                 | Node*    | 5                | 31             |
|  | Blood    | 6                | 34             |
|  | Milk     | 1                | 3              |
| H.I. herd** positive <sup>+</sup> cows | Node     | 1                | 8              |
|  | Blood    | 3                | 21             |
|  | Milk     | 1                | 8              |
| H.I. herd normal <sup>+</sup> cows     | Blood    | 1                | 7              |
|  | Milk     | 1                | 7              |
| Normal cows                            | Node     | 2                | 12             |
|  | Blood    | 2                | 11             |
|  | Milk     | 1                | 4              |
| Noninoculated controls                 | .....    | 3                | 18             |

\* 20% lymph node homogenate.

\*\* H.I. herd is high-incidence herd owned by Kansas State University.

<sup>+</sup> Positive and normal refer to hematologic rating on the Bendixen key.

The mice were maintained on sterile feed and water, in the units described, for the duration of the experiment. They were moved to clean cages and bedding as required, about every five to seven days. This change was made by untapeing the cardboard top, adding fresh feed and water, and moving the mice, water bottle, and feeding lid to a clean sterile cage with clean, sterile bedding. Infant mice were removed and euthanatized. The water bottle, feeding lid, and cardboard top were replaced with clean sterile equipment as necessary. All of this was performed in a hood, and although the outside of the unit was

handled, care was taken to avoid contamination of any of the parts of the unit with which the mice would have contact.

The mice were kept in a room that had been thoroughly cleaned and disinfected prior to the initiation of this experiment. Only ex-axenic mice in similar sterilized units were maintained in this room. Air was filtered prior to entering the room, and the door was locked at all times to discourage people who had contact with other laboratory mice from entering the room.

These mice were observed daily for clinical signs of illness. Any that were moribund were removed from their cage, euthanatized, and a postmortem examination was performed. Any mouse that died was also necropsied. Tissue specimens were saved for histopathologic examination.

Observation continued for a 6-month period following inoculation. At that time, at least one half of the mice living to maturity were euthanatized. The remaining mice were maintained for observation for an extended period of time to allow a longer latent period for the manifestation of leukemia. Observations of those animals sampled 6 months postinoculation were the basis for this thesis.

Mice removed from the groups at 6 months postinoculation were caudectomized at the terminal one third of the tail. Blood smears were made from this source, and the animal was euthanatized immediately by cervical disarticulation.

Sterile instruments were used to remove the ventral walls of the abdominal and thoracic cavities, after the skin had been

disinfected and reflected. A gross evaluation was made of the lymphatic organs, primarily the spleen, thymus, and lymph nodes. If these organs were enlarged, or there were other lesions suggestive of leukemia, portions of the involved organ(s) were removed and placed in tissue culture medium 199 containing 5% equine serum. This was subsequently homogenized and used for mouse inoculation, using the procedure previously described for bovine lymph node.

Sections of the spleen, thymus, lymph node, liver, kidney, lung, heart, sternum, salivary gland, and adrenal gland were saved from all animals euthanatized and placed in 10% buffered formalin for histopathologic evaluation.

When the microscopic lesions indicated additional information was needed, blood smears and organ imprints obtained at necropsy were stained with Wright's stains and examined. Bacteriologic culture samples in thioglycollate broth were obtained at necropsy from a cut liver surface and intestinal contents.

## RESULTS

Of the 172 mice inoculated or maintained as noninoculated controls, 8 died within the first two days postinoculation as a result of maternal agalactia and/or cannibalism. One male mouse was killed by other male mice in the cage during severe fighting. A total of 163 mice survived the 6-month observation period.

The following mice were subjected to postmortem examination: (1) the 87 mice euthanatized six months (181-183 days)

postinoculation, (2) one mouse with a mammary tumor euthanatized at 199 days postinoculation, and (3) one mouse killed by fighting at 104 days postinoculation. The technique of examining the mice for lesions has been outlined previously.

During the evaluation and description of the pathologic alterations, emphasis was placed on the abnormal changes in the cells of the chief organs of the lymphoreticular system: spleen, thymus, representative lymph nodes, and bone marrow. A few inflammatory processes were observed. A classification of the number of animals necropsied from each group is presented in Table 4.

#### Lymphosarcomatous Cow - Lymph Node Homogenate

Of the 31 mice inoculated with lymph node homogenate from lymphosarcomatous cattle, 18 were examined for gross and histopathologic lesions. An enlarged spleen, two times normal size, was observed in one nonpregnant lactating female mouse (12A). The right kidney of this mouse was about one-half normal size. A mammary tumor was observed in the left axillary area of mouse 16D at 198 days postinoculation and she was euthanatized the next day. No other gross lesions were observed in these mice.

The lymphoid structure of the spleen of mouse 12A was unremarkable when examined microscopically. The most striking change was the abundance of granulopoietic elements present in the spleen (Appendix, Plate VI, Fig. 1). The granulocytes and their precursors were most prevalent adjacent to the capsule



Table 4. Pathologic Observations and Classification of Microscopic Lesions of Mice Inoculated with Specimens from Lymphosarcomatous and Nonlymphosarcomatous cattle

| Inoculum               | No. of mice necropsied | No. of mice with gross lesions | No. of mice with microscopic lesions | No. of mice with lymphoid hyperplasia | % of mice necropsied with lymphoid hyperplasia |     |
|------------------------|------------------------|--------------------------------|--------------------------------------|---------------------------------------|--|-----|
| Bovine lymphosarcoma   | lymph node             | 18                             | 2                                    | 6                                     | 2  | 11  |
|                        | blood                  | 18                             | 4                                    | 7                                     | 6  | 33  |
|                        | milk                   | 2                              | 0                                    | 1                                     | 0  | 0   |
| H.I. herd* positive**  | node                   | 4                              | 0                                    | 1                                     | 0  | 0   |
|                        | cow blood              | 12                             | 1                                    | 4                                     | 4  | 33  |
|                        | milk                   | 4                              | 1                                    | 1                                     | 0  | 0   |
| H.I. herd* normal† cow | blood                  | 4                              | 1                                    | 1                                     | 1  | 25  |
|                        | milk                   | 4                              | 0                                    | 1                                     | 1  | 25  |
|                        | lymph node             | 6                              | 3                                    | 4                                     | 2  | 33  |
| Normal cow             | blood                  | 6                              | 1                                    | 4                                     | 4  | 66  |
|                        | milk                   | 2                              | 0                                    | 2                                     | 2  | 100 |
| Noninoculated controls |                        | 9                              | 2                                    | 4                                     | 4  | 44  |

\* High-incidence lymphosarcoma herd.

\*\* Hemogram positive on Bendixen key.

† Hemogram normal on Bendixen key.

and the trabeculae. The small right kidney had some hypoplastic epithelial tubules and some that appeared normal microscopically. A mammary adenocarcinoma was the only lesion seen in mouse 16D. There was no evidence of metastasis.

Other microscopic changes seen in these animals were a focus of coagulation necrosis in each of the liver sections of mouse 14D and mouse 18B, a small accumulation of mature lymphocytes in the kidney of mouse 18C and reaction centers in several of the lymphoid nodules, or malpighian bodies, in the spleen of mouse 14C. The reticular cells in these reaction centers had round nuclei that were larger and less basophilic than those of a lymphocyte. The nuclei had a loose chromatin network, frequently had one or more prominent nucleoli, and were surrounded by a moderate amount of light blue cytoplasm.

#### Lymphosarcomatous Cow - Whole Blood

Eighteen of the 34 mice inoculated with whole blood from cattle with lymphosarcoma were euthanatized and necropsied. Enlarged spleens, in the magnitude of one and one-half to three times normal size, were observed in four female mice, two (7B and 17B) of which were in the second trimester of pregnancy and two (13A and 13C) of which were not pregnant, but were lactating. No other gross lesions were observed in these 18 mice.

The spleens of mice 7A, 7B, 13C, and 17B were sufficiently similar histopathologically to describe collectively as hyperplastic spleens. The most prominent alterations were the increased number of lymphocytes and plasma cells in the red pulp,

the apparent increase in number and size of the lymphoid nodules, some with reactive centers (Appendix, Plate V, Fig. 1), and the increased number of hematopoietic elements. The plasma cells were characteristic cells with round, usually compact, basophilic nuclei eccentrically located in a moderate amount of pale blue cytoplasm. A perinuclear halo could be discerned in many of these cells. The abundant hematopoietic elements in most of these spleens were granulocytic, erythrocytic (Appendix, Plate VI, Fig. 2), and megakaryocytic, with the erythropoietic cells and megakaryocytes liberally dispersed throughout the red pulp. The immature granulocytes were found chiefly in a sub-capsular location and adjacent to the trabeculae. The spleen of mouse 13A closely resembled those just described, with the exception that the erythropoietic elements were scarce.

A lymph node of mouse 13C contained many plasma cells, located almost exclusively in the medullary portion of the node. Several mast cells also were observed in the medulla of this same node. A suppurative reaction in the medulla of a lymph node from mouse 13A was quite striking. Changes were not observed in the other lymph nodes or thymuses of mice inoculated with blood from lymphosarcomatous cattle. Miscellaneous lesions present in these mice included a focus of mature lymphocytes in each of the kidney sections of mice 7A, 7B, 13C, and 15A. Extramedullary hematopoiesis was observed in the liver of mice 7B and 13A.

### Lymphosarcomatous Cow - Milk

Gross or microscopic alterations of the lymphoreticular system were not observed in the two mice necropsied that had been inoculated with milk from a lymphosarcomatous cow. The only lesions observed were widely scattered, small foci of renal epithelial necrosis with subsequent dystrophic calcification in mouse 9A.

### H.I. Herd Positive Cow - Lymph Node Homogenate

Four of the eight mice inoculated with lymph node homogenate from a Bendixen-key-positive cow from a high-lymphosarcoma-incidence herd were euthanatized. Gross lesions were observed in mouse 20B. The cortex of the thymus was relatively small in relation to the medulla. An abundance of hematopoietic tissue was observed in the spleen, and consisted primarily of granulocytes and their precursors with the granulopoietic cells located chiefly adjacent to the capsule and trabeculae. No other microscopic changes were found.

### H.I. Herd Positive Cow - Whole Blood

Whole blood was obtained from cattle from a herd with a high incidence of lymphosarcoma. Twenty-one mice were inoculated with blood from cows that were classified positive on the Bendixen key, and 12 of these mice were necropsied. Only one of the mice, 21A, had lesions that could be detected grossly. The spleen of this pregnant female mouse was enlarged about one and

one-half times normal size. No other gross lesions were observed in these 12 mice.

The spleen of mouse 21A was unremarkable microscopically, except for several large lymphoid nodules, some of which contained reactive centers. The architecture of the organ and the morphology of the cells appeared normal otherwise. The medulla of the thymus of mouse 21C was large in relation to the cortex, but no irregularities in cellular morphology were observed. A lymph node from this same mouse, 21C, contained a few plasma cells, and a few neutrophils, in the medulla. Foci of mature lymphocytes were seen in the kidneys of mice 3D and 21B. A similar aggregation of lymphocytes was located adjacent to a bronchiole in the lung of mouse 3D.

#### H.I. Herd Positive Cow - Milk

Eight mice were inoculated with milk from a cow originating in a high-incidence herd. This cow was classified positive on the Bendixen key. Only one of the four mice necropsied had grossly visible internal lesions, although the male mouse, 22, that was killed by fighting had numerous skin lesions, some of which were healing scars and others which were areas of active inflammation. The gross internal lesion was observed in pregnant female mouse 22C, as her spleen was approximately one and one-half times larger than normal.

The enlargement of the spleen of mouse 22C was found to be the result of a large healing abscess, which had a center of necrotic tissue. The periphery of young proliferating

fibroblasts contained many neutrophils mixed throughout the fibroblasts and collagen. Mouse 22, which was killed by fighting, had many foci of coagulation necrosis scattered throughout the liver, kidney, and spleen. Many of these foci had elicited a suppurative response, and fibroplasia was present around a few. No other microscopic lesions were observed in these four mice.

#### H.I. Herd Normal Cow - Whole Blood

Seven mice were inoculated with whole blood from a high-incidence-herd cow that was classified normal on the Bendixen key, and four of these mice were examined for lesions. Gross and microscopic abnormalities were found in a pregnant female mouse, 1C. Her spleen was approximately three times normal size, and her thymus was approximately two times normal size. No other gross lesions were observed in these four mice.

Microscopically, the lesions in mouse 1C were characterized by hyperplasia of the lymphatic organs (Appendix, Plate VII, Figs. 1 and 2). The thymus was unremarkable, but there was an increase in the size and number of lymphoid nodules with reactive centers composed of reticular cells in the spleen. Lymphocytes were quite abundant throughout the red pulp of the spleen. The spleen was also a hyperactive hematopoietic organ, with an increase of both erythropoietic and granulopoietic elements.

All five of the lymph nodes examined of mouse 1C had a paucity of lymphocytes and an abundance of plasma cells and histocytes intermixed (Appendix, Plate VII, Figs. 1 and 2). Cortical and medullary arrangement of the lymph nodes was poorly defined in two of the nodes. Foci of mature lymphocytes also were observed at two locations in the kidney, two locations in the lung, and at the junction of two central veins in the liver.

#### H.I. Herd Normal Cow - Milk

Seven mice were inoculated with milk from a normal cow from a herd with a high incidence of lymphosarcoma. None of the four mice euthanatized had gross lesions, and histopathology was observed in only one. Mouse 2A had a small focus of lymphocytes adjacent to a duct in the salivary gland. No other microscopic lesions were found.

#### Normal Cow - Lymph Node Homogenate

Of the 12 mice inoculated with lymph node homogenate from normal cattle, six were examined for lesions. One pregnant female mouse (25A) and one nonpregnant female mouse (25B) had spleens and thymuses that were approximately one and one-half times normal size. All three mice from cage 25 (25A, 25B, and 25C) had discreet, small (less than 1 mm. diameter), white foci scattered throughout their livers. When examined microscopically, the small white foci visible grossly on the livers were

found to be areas of coagulative necrosis with a suppurative and fibrotic response. No other lesions were observed in the livers of these mice.

The spleen of mouse 25A contained a hyperplastic red pulp area, with the most prominent change being the increased number of erythropoietic cells. A few of these cells also were observed in the spleen of mouse 25B, although the most striking change there was the increased white pulp. This was primarily the result of many lymphoid nodules, some with large reactive centers. The spleens of both animals had an abundance of megakaryocytes.

The thymuses of both 25A and 25B appeared normal histologically. Both of the lymph nodes examined from mouse 25B had a few foci of reticular cells in the reactive centers in the cortex. Plasma cells were quite prominent in the medulla of one of the nodes, but not the other. A small focus of histiocytes and lymphocytes was seen adjacent to a duct in the salivary gland of mouse 25B, and similar foci consisting predominantly of lymphocytes were observed in the kidney of mouse 25A.

#### Normal Cow - Whole Blood

Six of the 12 mice inoculated with whole blood from normal cattle were euthanatized and examined for lesions. The thymus and spleen of one pregnant female, 26B, were enlarged about one and one-half times normal size. No other gross lesions were observed in any of these mice.



Megakaryocytes were abundant in the spleen of mouse 26B. Few of the lymphoid nodules had reactive centers, although there was a large amount of white pulp. No microscopic explanation could be found for the gross enlargement of the thymus. Both of the lymph nodes examined from mouse 26B had several reactive centers in the cortex. Plasma cells were quite prominent in the medulla of one of the nodes, but not the other. A number of reactive centers in the cortex of a lymph node of mouse 26A contained cells with round nuclei of varying size. A small focus of mature lymphocytes was present in the renal cortex of mouse 24C, and another adjacent to an arteriole in the lung of mouse 26C.

#### Normal Cow - Milk

Four mice were inoculated with milk from a normal cow, and two of these were examined for pathological alterations. None were observed grossly. Several of the lymphoid nodules in the spleen of mouse 27B had reactive centers of reticular cells around the central arteriole, with mature lymphocytes at the periphery of the nodules. A moderate number of plasma cells were seen in the lymph node of mouse 27A. No other lesions were observed.

#### Noninoculated Controls

Eighteen mice were maintained as noninoculated controls, and nine of these were evaluated for gross and histopathologic

lesions. Two of the female mice, one pregnant (5A) and one lactating (5C) had moderately enlarged (about two times normal size) spleens and thymuses.

Both mouse 5A and mouse 5C had microscopic lesions which could be characterized best as hyperplasia of the involved lymphatic organs. The lymphoid nodules in the spleen apparently were increased in number and definitely increased in average size. Several of the nodules had large (one-fourth to one-half the diameter of the nodule) reactive centers composed of reticular cells. The periphery of these nodules, and other entire nodules, was composed of mature lymphocytes. The increase in the size of the thymus was primarily the result of an increase in the thickness of the cortex, which contained mature thymocytes almost exclusively.

In addition to those mice which had gross lesions, two mice (11E and 11F) had hyperplastic lymph nodes. The nodes appeared enlarged and there was evidence that lymphocyte production was active and the maturation process was normal, as attested to by the number of mature lymphocytes present in the nodes. One lymph node of mouse 11F also had a moderate number of plasma cells and neutrophils in the medulla. The liver and spleen of both animals contained active areas of hematopoiesis, both erythrocytic and granulocytic. Two foci of mature lymphocytes also were observed adjacent to an artery and a vein in the renal cortex of mouse 11E.

The number of mice in each group that had hyperplasia of the lymphoid structures, and the percentage of the animals

necropsied the mice with hyperplastic lesions represented, were presented in Table 4. No definite trend or clear pattern could be established, as hyperplasia was observed in all the major groups.

#### DISCUSSION

Ex-axenic mice were inoculated with specimens obtained from cattle that had lymphosarcoma, cattle from a high-incidence herd, and normal cattle in an attempt to induce leukemia in these mice. Lesions of leukemia were not present in any of the inoculated mice which were necropsied, nor in any of the non-inoculated control mice. The explanation of this fact may be approached from several directions, none, one, or all of which may be partially or entirely correct.

Although bovine lymphosarcoma has been transmitted from affected cattle to susceptible cattle, as reported by Götze et al. (1956) and Rosenberger (1961), the factors responsible for this transmission remain unknown. Papparella et al. (1963), McKercher et al. (1963), and Lange (1965) have reported on the isolation of viruses from lymphosarcomatous cattle. However, the viruses isolated by these investigators have not been capable of inciting the disease syndrome in cattle. The theory of viral etiology for bovine lymphosarcoma has many proponents, but the isolation of a virus from an animal with the disease that has the ability to reproduce the disease in other cattle has yet to be reported.

The attempt to reproduce a similar disease syndrome in another species of animals (mice) by inoculation with or exposure to specimens obtained from the species (cattle) naturally manifesting the disease is fraught with hazards: (1) there may not be a specific agent(s) or factor(s) responsible for bovine lymphosarcoma, (2) an agent leukemogenic for cattle may not be leukemogenic for mice, (3) an agent obtained from lymphosarcomatous cattle that is leukemogenic for mice may not be the factor originally responsible for the disease in cattle, (4) leukemia developing in mice inoculated with specimens from lymphosarcomatous cattle may actually be a spontaneous murine leukemia or the activation of a latent murine leukemogenic agent. Despite these hazards, and probably others, this approach was selected in an attempt to detect, isolate, propagate, and concentrate an agent from cattle with bovine lymphosarcoma that was leukemogenic for mice. Had this been possible, subsequent testing in the homologous species (cattle) would have been warranted.

In an attempt to alleviate some of the hazards mentioned, CFW<sub>w</sub> ex-axenic mice were chosen as the experimental animals. The absence of natural leukemia in over 4,000 CFW<sub>w</sub> mice has been reported by Nielsen et al. (1965) and Werder et al. (1966). However, leukemia in CFW<sub>w</sub> axenic and ex-axenic mice has been produced by the inoculation of: (1) bone marrow specimens obtained from leukemic people (Nielsen et al., 1965), (2) a virus isolated from a cell culture of neoplastic cells from a dog with reticulum cell leukemia (Chapman et al., 1966), (3) bone marrow specimens from people free of clinical illness (Werder, 1966),

and (4) exposure of these mice to a sub-lethal dose of X-irradiation (Werder, 1966). By utilizing axenic mice, and maintaining them as ex-axenic animals under strict sanitary conditions, an attempt was made to eliminate, or at least minimize, the exposure to leukemogenic factors except any present in the inocula.

Heterologous leukemia transmission attempts to mice have been reported as successful in a few attempts. Leukemia has been produced by inoculating mice with specimens from leukemic people (Schwartz et al., 1957; DeLong, 1960; Nielson et al., 1965; and Chapman et al., 1966a), a leukemic dog (Werder, 1966), and lymphosarcomatous cattle (Hatzioios et al., 1966).

A longer observation period might have been advantageous if a leukemia in mice caused by a bovine lymphosarcoma agent required a latent period longer than 6 months. However, other authors have reported the heterologous transmission of leukemia to mice in less than 6 months. When inoculating this same strain of mice (CFW<sub>w</sub>) with human leukemic bone marrow specimens, the mice developed leukemia at an average of 8-9 months post-inoculation, according to Werder (1966). However, he reported that the first animals to develop leukemia did so 4½-5 months postinoculation. Schwartz et al. (1957) observed leukemia in mice 2-12 weeks after inoculating them with brain tissue of human leukemic victims. The mice that DeLong (1960) inoculated with filtered supernatant fluids from tissue cultures inoculated with bone marrow specimens from leukemic people developed leukemia with average latent periods of 88, 155, 158, and 160

days for four different groups. Hatziolos et al. (1966) had mice develop leukemia 75-522 days after inoculating them with bovine lymphosarcoma specimens. Seven of the 12 leukemic mice developed lesions of the disease 147-183 days postinoculation.

The major pathologic alteration observed in the mice in this experiment was hyperplasia of the various lymphoid organs. An occasional inflammatory lesion was observed in these organs. Except for one mammary adenocarcinoma, there was no evidence of neoplastic changes in these mice. The increased number of cells in the hyperplastic organs had a proper distribution of mature cells and immature cells, indicating that cellular maturation was proceeding at a normal rate.

It can not be assumed that an agent in the inocula from the cattle with lymphosarcoma was responsible for the lymphoid hyperplasia, as 8 of the 38 mice (21%) so treated had lymphoid hyperplasia (Table 4). Eight of 14 mice (57%) that received inocula prepared from specimens obtained from normal cattle had lymphoid hyperplasia, as did 4 of 9 mice (44%) held as non-inoculated controls.

Of the 89 mice necropsied, 44 were males and 45 were females. Thirteen of these mice, all females, were found to have grossly enlarged lymphoreticular organs, primarily the spleen. Eight of the 13 females with gross lesions were pregnant, four were not pregnant but were lactating, and one was neither pregnant nor nursing young at the time of necropsy. Six pregnant females did not have gross lesions. The number of lactating females without lesions was not recorded.

The possibility that the hyperplastic lesions were precancerous or preleukemic was considered. A precancerous lesion is one that predisposes to a malignant neoplasm, according to Moulton (1961). It usually assumes the form of a benign tumor or a regenerative or hyperplastic process and only occasionally becomes cancerous. Whether any of the hyperplastic lesions observed in these mice would have become malignancies is a matter of pure speculation. The mice that were allowed to live for a longer period of time may resolve that question.

The procedure of mouse inoculation, as accomplished in these experiments, appears to have deficiencies that must be eliminated if heterologous leukemia transmission studies are to provide additional information about the etiology of bovine lymphosarcoma.

An approach that could be more productive would be the initiation of lymphosarcomatous tumor cell cultures, or the inoculation of established cell cultures with lymphosarcomatous specimens. An agent(s) or factor(s) isolated from these cell cultures could then be concentrated so that a greater quantity of potentially leukemogenic agents could be administered to mice. This technique worked well for Werder (1966) as he consistently produced leukemia in ex-axenic CPW<sub>w</sub> mice by inoculating them with filtered concentrated supernatant fluid from cell cultures. These cell cultures were originally from a dog with reticulum cell leukemia.

## CONCLUSIONS

Ex-axenic mice inoculated with specimens obtained from lymphosarcomatous cattle, cattle from a herd with a high incidence of lymphosarcoma, or normal cattle were observed for 6 months after inoculation. One-half of the inoculated mice surviving to maturity and one-half of the 18 noninoculated control mice were euthanatized and necropsied at the end of the 6-month observation period. Gross or microscopic lesions characteristic of leukemia were not observed in these mice.

Hyperplasia of the lymphoid organs, primarily the spleen, was observed in several mice. However, this lesion was seen in all of the major experimental groups, including the noninoculated control animals, and was not thought to be a result of the inocula administered to the mice. Mouse inoculation as performed in these experiments does not appear to be the ideal procedure for obtaining additional information about the causative factor(s) of bovine lymphosarcoma.



## ACKNOWLEDGMENTS

The author wishes to express his gratitude to the members of his advisory committee, Drs. H. D. Anthony, E. H. Coles, and H. C. Mussman of the Department of Pathology, Parasitology, and Public Health, Kansas State University, Manhattan, Kansas, and Dr. A. A. Werder of the Department of Microbiology, University of Kansas Medical Center (KUMC), Kansas City, Kansas. They were always available for advice, assistance, and information, and their patience and understanding were sustaining factors in this endeavor.

Mrs. Anne Nielsen, Department of Microbiology, KUMC, Kansas City, Kansas, provided the ex-axenic mice utilized for experimentation, and was a frequent source of valuable information and consistent encouragement. Her efforts were appreciated.

Appreciation is expressed to Dr. H. Cohen, Department of Pathology, Menorah Medical Center, Kansas City, Missouri, for his wise counsel and constructive criticism of the evaluation and description of the histopathologic lesions. Both he and the author attest to the excellence of the tissue sections prepared by Evelyn Gates and Katherine Wintle, Medical Technologists (ASCP), Department of Pathology, KUMC, Kansas City, Kansas.

Dr. A. L. Chapman of the Department of Anatomy, KUMC, Kansas City, Kansas, graciously provided the equipment, supplies, and assistance for preparing the photomicrographs. These photomicrographs were developed and printed by Mr. Wm. Bopp of the

Department of Anatomy, KUMC, Kansas City, Kansas. His cooperation was appreciated.

This work would not have been possible without the financial assistance provided by the National Cancer Institute of the National Institutes of Health in the form of Post-Doctoral Fellowship No. 1-F2-CA-29, 501-06. The author is grateful to his fellow taxpayers of the United States of America for providing this opportunity.

## LITERATURE CITED

Bederke, G., and Toll, A.: Zur Übertragbarkeit der Rinderleukose durch das Blut den Kontakt mit Experimentell Behandelten Tieren. Zentralblatt für Veterinärmedizin, Reihe B, 11 (1964): 433-455. Berlin, Germany.

Bendixen, H. J.: Bovine Leucosis. IV. Herd Leucosis is Caused by an Infectious Agent. Mod. Vet. Practice, 42 (June 1, 1961): 33-36.

Bendixen, H. J.: Preventive Measures in Cattle Leukemia: Leukosis Enzootica Bovis. Ann. New York Acad. Sci., 108 (Nov., 1963): 1241-1267.

Chapman, A. L., Bopp, W. J., Brightwell, A. S., Cohen, H., Nielsen, A. H., Gravelle, C. R., and Werder, A. A.: Preliminary Report on Virus-like Particles in Canine Leukemia and Derived Cell Cultures. Unpublished Data. Submitted to Cancer Res. (1966).

Chapman, A. L., Nielsen, A., Cohen, H., Larsen, W. E., and Werder, A.: Electron Microscopic Quantitation of Viral Particles in Tissues of Leukemic Mice. Proc. Soc. Exptl. Biol. & Med., accepted for publication (1966a).

Creech, G. T., and Bunyea, H.: Experimental Studies of Bovine Leukemia. J. Agric. Res., 28 (April, 1929): 395-404.

Croshaw, J. E., Jr., Abt, D. A., Marshak, R. R., Hare, W. C. D., Switzer, J., Ipsen, J., and Dutcher, R. M.: Pedigree Studies in Bovine Lymphosarcoma. Ann. New York Acad. Sci., 108 (Nov., 1963): 1193-1202.

DeLong, R.: Production of Leukemia In Mice with Cell-Free Filtrates from Human Leukemias. J. Lab. & Clin. Med., 56 (Dec., 1960): 891-893.

Dutcher, R. M.: Etiologic Investigations on Bovine Leukemia May Contribute Knowledge to Human Leukemia. Nord. Vet.-med., 18 (1964): 573-591.

Dutcher, R. M.: Bovine Leukemia. Growth, 29 (March, 1965): 1-5.

Dutcher, R. M., Larkin, E. P., and Marshak, R. R.: Virus-like Particles in Cows Milk from a Herd with a High Incidence of Lymphosarcoma. J. Nat. Cancer Inst., 33 (Dec., 1964): 1055-1064.

Dutcher, R. M., Szekely, I. E., Bartie, B. W., and Switzer, J. W.: Attempts to Demonstrate a Virus for Bovine Lymphosarcoma. *Am. J. Vet. Res.*, 25 (May, 1964a): 668-678.

Dutcher, R. M., Szekely, I. E., Larkin, E. P., Coriell, L. L., and Marshak, R. R.: Etiological Studies on Bovine Lymphosarcoma. *Ann. New York Acad. Sci.*, 108 (Nov., 1963): 1149-1162.

Gard, S. (Discussant): Viruses, Nucleic Acids, and Cancer. Williams & Wilkins Co., Baltimore, Md. (1963): 575-577.

Götze, R., Rosenberger, G., and Ziegenhagen, G.: Ueber Ursachen und Bekämpfung der Rinderleukose. IV. Uebertragbarkeit. *Deutsche tierärztl. Wchnschr.*, 63 (March, 1956): 105-121. Hannover, Germany.

Hatzios, B. C., and Chang, S. C.: A Preliminary Study on Tissue Cultures of Bovine Lymphosarcoma. *Ann. New York Acad. Sci.*, 108 (Nov., 1963): 1214-1230.

Hatzios, B. C., Chang, S. C., Stevenson, M. C., and Mohanty, S. B.: Bovine Lymphosarcoma: The Effect of Inoculations on Newborn Calves and Mice. First Year of Observation. *Am. J. Vet. Res.*, 27 (March, 1966): 489-502.

Kalk, C., and Hetrick, F.: Establishment and Characterization of Bovine Lymph Node Cell Cultures. *Am. J. Vet. Res.*, 26 (July, 1965): 865-872.

Lange, W.: Versuche zur Übertragung der Rinderleukose auf die Albinomaus. *Zentralblatt für Veterinärmedizin, Reihe B*, 11 (1964): 446-454. Berlin, Germany.

Lange, W.: Gewebekulturen nach Inokulation mit zellfreien Rinderleukose-Extrakten. *Zentralblatt für Bakteriologie, Parasitenkunde, Infektionskrankheiten und Hygiene*, 197 (Sept., 1965): 299-306. Jena, Germany.

Marshak, R. R., Coriell, L. L., Lawrence, W. C., Croshaw, J. E., Jr., Schryver, H. P., Altera, K. P., and Nichols, W. W.: Studies on Bovine Lymphosarcoma. I. Clinical Aspects, Pathological Alterations, and Herd Studies. *Cancer Res.*, 22 (Feb., 1962): 202-217.

Marshak, R. R., and Dutcher, R. M.: Comparative Aspects of Bovine Leukemia. *Postgrad. Med.*, 38 (Nov., 1965): 490-498.

McKercher, D. G., Wada, E. M., Straub, O. C., and Theilen, G. H.: Possible Viral Etiology of Bovine and Equine Leukemia. *Ann. New York Acad. Sci.*, 108 (Nov., 1963): 1163-1172.

Monlux, A. W., Anderson, W. A., and Davis, C. L.: A Study of Tumors Occurring in Cattle, Sheep, and Swine. *Am. J. Vet. Res.*, 17 (Oct., 1956): 646-677.

Moulton, J. E.: Tumors in Domestic Animals. University of California Press, Berkeley, Calif. (1961): 7-8.

Moulton, J. E.: Occurrence and Types of Tumors in Large Domestic Animals. *Ann. New York Acad. Sci.*, 108 (Nov., 1963): 620-632.

Mussman, H. C.: Unpublished data (1965). Dykstra Veterinary Hospital, Kansas State University, Manhattan, Kansas.

Nielsen, A., Chapman, A., Cohen, H., Larsen, W., and Werder, A.: Development of Leukemia in Axenic Mice Inoculated with Human Leukemic Tissue. *Fed. Proc.*, 24 (March-April, 1965): 685. Abstract No. 3075.

Papparella, V.: Sensitivity of Guinea Pigs to the Causal Agent of Bovine Leukosis. *Acta Medica Veterinaria*, 5 (1959): 157-176. Original not seen. Information obtained from Veterinary Bulletin, 30 (March, 1960): 137. Abstract #781.

Papparella, V.: Alopecia in Guinea Pigs Experimentally Infected with the Virus of Bovine Leukosis. *Acta Medica Veterinaria*, 6 (1960): 147-153. Original not seen. Information obtained from Veterinary Bulletin, 31 (Jan., 1961): 29. Abstract #172.

Papparella, V., Cali, A., Rossi, G. B., and Iacobelli, A.: Reserches on a Virus Isolated from a Calf Affected with Lymphatic Leukemia. *Ann. New York Acad. Sci.*, 108 (Nov., 1963): 1173-1192.

Ritter, V. H.: Beobachtungen über epidemische und endemische Ausbreitung der enzootischen Rinderleukose. *Deutsche tierärztl. Wchnschr.*, 71 (Oct., 1964): 518-522.

Rosenberger, G.: Studies on Bovine Leukosis in Germany. III. Transmission Experiments. Documents 19-20, WHO Conference on Comparative Studies in Leukemia. Philadelphia, Pa., Feb. 27-March 3, 1961.

Schwartz, S. O., Schoolman, H. M., Szanto, P. B., and Spurrier, W.: Studies in Leukemia. VI. The Induction of Leukemia in AKR Mice by Means of Cell-Free Brain Filtrates of Humans Who Died of Leukemia. *Cancer Res.*, 17 (April, 1957): 218-221.

Smith, H. A., and Jones, T. C.: *Veterinary Pathology*. 2nd ed. Lea & Febiger, Philadelphia (1961).

Sorenson, G. D., and Theilen, G. H.: Electron Microscopic Observations of Bovine Lymphosarcoma. *Ann. New York Acad. Sci.*, 108 (Nov., 1963): 1231-1240.

Squire, R. A.: Hematopoietic Tumors of Domestic Animals. *Cornell Vet.*, 14 (Jan., 1964): 97-150.

Theilen, G. H., Appleman, R. D., and Wixom, H. G.: Epidemiology of Lymphosarcoma in California Cattle. *Ann. New York Acad. Sci.*, 108 (Nov., 1963): 1203-1213.

Tolle, A., Eger, W., and Schreier, C.: Transmissible Kidney Lesions in Male Mice after Injection of Bovine Leucosis Material. *Deutsche tierärzt. Wchnschr.*, 69 (1962): 609-612 and 680-685. Original not seen. Information obtained from *Veterinary Bulletin*, 33 (Sept., 1963): 511. Abstract #3230.

Trapp, A. L., Weide, K. D., Sanger, V. L., and Gilmore, L. O.: Probable Cell-Free Transmission of Malignant Bovine Lymphoma. *Am. J. Vet. Res.*, 27 (March, 1966): 588-590.

Trexler, P. C., and Reynolds, L. I.: Flexible Film Apparatus for the Rearing and Use of Germfree Animals. *Applied Micro.*, 5 (Nov., 1957): 406-412.

Überschär, S.: Elektronenoptische Untersuchungen an den Zellen der tumorösen Form der Leukose des Rindes. *Deutsche tierärzt. Wchnschr.*, 70 (Aug., 1963): 417-422. Hanover, Germany.

Werder, A. A.: Unpublished data (1966). Department of Microbiology, University of Kansas Medical Center, 39th and Rainbow Blvd., Kansas City, Kansas.

Werder, A. A., Nielsen, A. H., Chapman, A. L., Cohen, H., McCullough, L., and Chapheka, P. M.: Observations on the Incidence and Transmission of Murine Leukemia in Conventional and Axenic Mice of the CFW<sub>w</sub> Substrain. Unpublished data. Submitted to *Proc. Soc. Exptl. Biol. & Med.* (1966).

Winqvist, G.: A Transferrable Lymphocytosis in Cattle. Document 7, WHO Conference on Comparative Studies in Leukemia. Philadelphia, Pa., Feb. 27-March 3, 1961.

## APPENDIX

EXPLANATION OF PLATE I

Fig. 1. A prefemoral lymph node from lymphosarcomatous cow LB-7. A monotonous mass of neoplastic cells has replaced normal node structure. The anaplastic cells have a large pale-staining nuclei with abundant cytoplasm. Many nuclei have bizarre forms, and mitotic figures are not uncommon. Hematoxylin and eosin X125.

Fig. 2. A higher magnification of Fig. 1. Note the variation in size and shape of the nuclei. A mitotic figure can be seen (arrow). Hematoxylin and eosin X400.



## PLATE I



Fig. 1

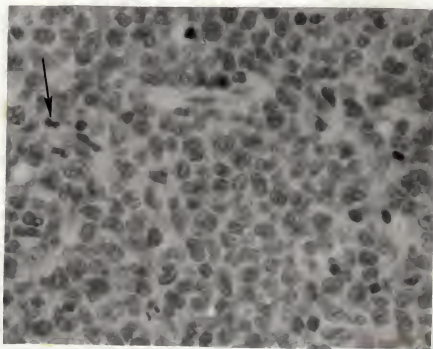


Fig. 2

EXPLANATION OF PLATE II

Fig. 1. A prefemoral lymph node from cow #2784. This cow was classified positive on the Bendixen key, and had originated in a herd with a high incidence of lymphosarcoma. An enlarged reactive center (left) was compressing the adjacent tissue (center) of the cortex. Cellular morphology appears normal. Hematoxylin and eosin X250.

Fig. 2. A representative area of a peripheral blood smear from cow #2784. See Fig. 1. This cow's total leukocyte count was 101,250/cmm. with 98% lymphocytes, most of which were atypical. These cells had large nuclei containing a delicate, loose chromatin structure. Giemsa stain X125.

## PLATE II

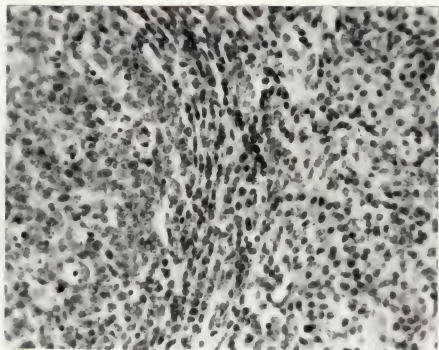


Fig. 1

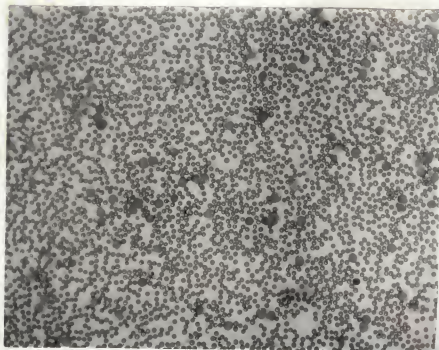


Fig. 2

EXPLANATION OF PLATE III

Fig. 1. A prefemoral lymph node from a normal cow, LB-10. The cortex of the node contains numerous follicles. Trabeculae can be seen. Hematoxylin and eosin X40.

Fig. 2. A higher magnification of Fig. 1. The edge of a follicle can be seen. Hematoxylin and eosin X250.

## PLATE III

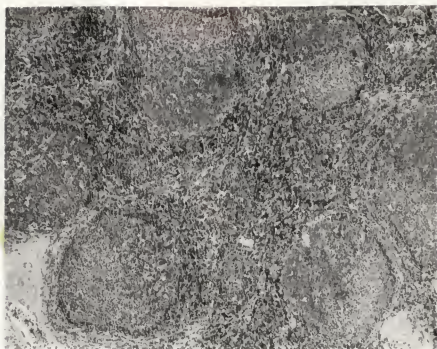


Fig. 1

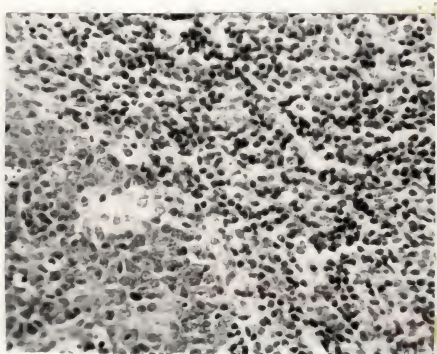


Fig. 2

EXPLANATION OF PLATE IV

Fig. 1. A normal spleen from mouse 8B, which had received lymphosarcomatous lymph node homogenate. The lymphoid nodules vary in size, but are well defined and do not have reactive centers. Megakaryocytes are seen in the red pulp. Hematoxylin and eosin X40.

Fig. 2. A higher magnification of Fig. 1. The lymphoid follicles are small, round, and uniform in cellular content. The adjacent red pulp contains lymphocytes and some reticuloendothelial cells. A focus of granulopoietic cells (arrow) are seen in the red pulp. Hematoxylin and eosin X125.

## PLATE IV

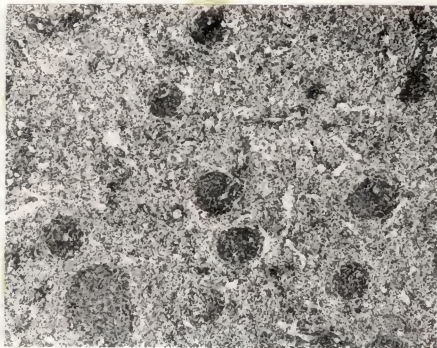


Fig. 1

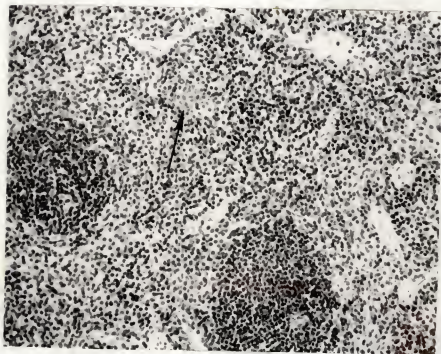

Fig. 2

EXPLANATION OF PLATE V

Fig. 1. A section of a spleen from mouse 13C, which had been inoculated with blood from a lymphosarcomatous cow. This section is representative of the lesions designated lymphoid hyperplasia in this thesis. The lymphoid nodules are enlarged and increased in number. Many have reactive centers (B). In addition to the lymphoid hyperplasia, areas of erythropoiesis (arrow) can be seen in the red pulp. Hematoxylin and eosin X40.

Fig. 2. A section of the spleen of mouse 12A which had lymphoid hyperplasia. This mouse had been inoculated with whole blood from a cow with lymphosarcoma. Two adjacent nodules can be seen, both with reactive centers. Hematoxylin and eosin X125.



## PLATE V

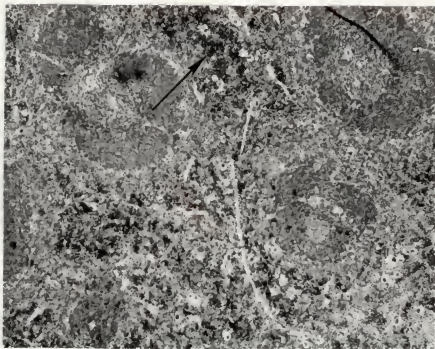


Fig. 1

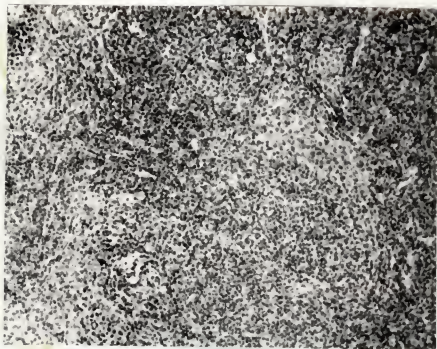


Fig. 2

EXPLANATION OF PLATE VI

Fig. 1. A section of the spleen of a mouse (12A) which had been inoculated with whole blood from a lymphosarcomatous cow. This spleen contained an abundance of granulopoietic cells. The granulopoietic cells are adjacent to a trabecula. Hematoxylin and eosin X400.

Fig. 2. A section of the spleen of mouse 13C containing many nucleated erythrocytes in the red pulp. These cells have darker nuclei that are more variable in size and shape than the adjacent lymphocytes (arrows). A megakaryocyte can be seen. Hematoxylin and eosin X400.

## PLATE VI

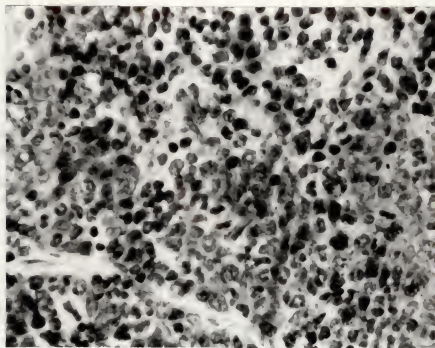


Fig. 1

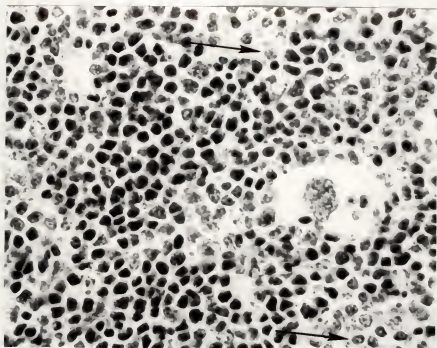


Fig. 2

EXPLANATION OF PLATE VII

Fig. 1. Lymphoid nodules in a lymph node from mouse 1C, which had been inoculated with whole blood from a cow classified normal on the Bendixen key. A reactive center can be seen in each nodule. Hematoxylin and eosin X125.

Fig. 2. A higher magnification of Fig. 1. The reticular cells on the reactive center (B) can be seen with the adjacent mature lymphocytes of the lymphoid nodule (A). Plasma cells (arrows) are present in the medulla. Hematoxylin and eosin X400.

## PLATE VII

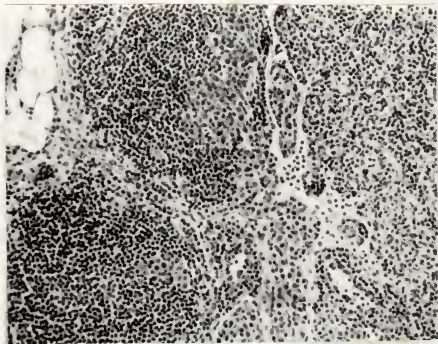


Fig. 1

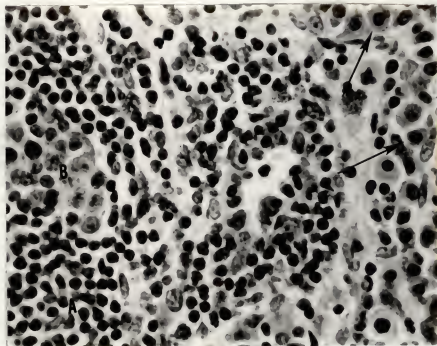


Fig. 2

ATTEMPTED TRANSMISSION OF BOVINE LYMPHOSARCOMA  
TO EX-AXENIC MICE

by

WAYNE MERLE GROVER

B.S., Kansas State University, 1963  
D.V.M., Kansas State University, 1965

---

AN ABSTRACT OF A MASTER'S THESIS

submitted in partial fulfillment of the

requirements for the degree

MASTER OF SCIENCE

Department of Pathology,  
Parasitology, and Public Health

KANSAS STATE UNIVERSITY  
Manhattan, Kansas

1966

The search for the etiology of bovine lymphosarcoma has been a project for many investigators. This disease entity constitutes a continuous insidious loss to the livestock industry. Because of the clinical and pathologic similarities of bovine lymphosarcoma and human lymphosarcoma, the disease in cattle may be a source of valuable comparative knowledge.

Viruses have been convincingly incriminated as the etiologic agents of certain avian and murine lymphoreticular neoplasms. Bovine lymphosarcoma has a high incidence of occurrence in certain areas and in certain herds, but is uncommon in other areas and unknown in other herds. An infectious agent could be responsible for this epizootiologic pattern, and some investigators have reported on the spread of the disease to lymphosarcoma-free herds by introducing animals from herds with a high incidence of the disease.

Various research techniques have been applied to this etiological problem, and many investigators have reported information which would indirectly support the theory of viral etiology. The intent of this investigation was to attempt to produce a leukemia in ex-axenic mice by inoculating them with specimens obtained from cattle with lymphosarcoma. Subsequent isolation of the leukemogenic agent was contingent upon the development of leukemia in the mice.

Specimens utilized for mouse inoculation included a 20% lymph node homogenate, whole blood, and/or milk. These specimens were obtained from live cattle that were (1) clinically and histopathologically confirmed lymphosarcomatous, (2) classified

positive on the Bendixen key and from a herd with a high incidence of lymphosarcoma, or (3) classified normal on the Bendixen key and from a herd with a high incidence of lymphosarcoma. For control purposes, mice were inoculated with similar specimens from clinically normal cattle. A total of 164 ex-axenic mice were utilized in this experiment, of which 68 received inocula from 6 lymphosarcomatous cows, 37 received inocula from 3 Bendixen-key positive cows, 14 received inocula from 1 Bendixen-key normal cow, 27 received inocula from 2 clinically normal cows, and 18 were maintained as noninoculated controls.

The experimental animals were 1-14-day-old mice of the Carworth Farm White (CPW) strain and CPW<sub>w</sub> substrain. They received 0.1 ml. of the inocula intraperitoneally, and were inoculated the same day they were removed from the germ-free isolators. They were maintained as ex-axenic mice on sterile bedding, feed, and water for a 6-month observation period. At the end of this observation period, one-half of the mice in each group were euthanatized and necropsied. The remaining mice were allowed to live to see if leukemia will develop.

The mice that were necropsied were studied for gross and histopathologic lesions, with emphasis on the organs and cells of the lymphoreticular system. No leukemia was observed. The most consistent lesion was lymphoid hyperplasia, and this was found in 21% of the mice inoculated with lymphosarcomatous specimens, 20% of the mice inoculated with Bendixen-key positive specimens, 25% of the mice inoculated with Bendixen-key normal specimens, 57% of the mice inoculated with clinically normal



specimens, and 44% of the noninoculated mice. Few inflammatory lesions were observed.

Because of the ubiquitous distribution of the lesions in all experimental groups, the lymphoid hyperplasia was of no significance. Leukemia did not develop in any of the experimental groups. Mouse inoculation, as performed in these experiments, did not appear to be the ideal method by which to obtain additional information about the etiology of bovine lymphosarcoma.