

A STUDY OF INCIDENCE OF THE NEOPLASMS  
WITH PARTICULAR REFERENCE TO  
THE FEMALE GENITAL TRACT OF ANIMALS

by

OM PARKASH MALHOTRA

B.V.Sc. University of East Punjab, Solan, India, 1949

---

A MASTER'S REPORT

submitted in partial fulfillment of the

requirements for the degree

MASTER OF SCIENCE

Department of Surgery and Medicine

KANSAS STATE COLLEGE  
OF AGRICULTURE AND APPLIED SCIENCE

1957

L V  
2668  
R4  
1957  
M1249  
C.2  
Docu-  
ments

TABLE OF CONTENTS

INTRODUCTION. . . . . 1

HISTORICAL. . . . . 2

    The Lymph Theory. . . . . 5

    Histological Period . . . . . 6

INCIDENCE OF NEOPLASMS IN GENERAL . . . . . 12

    Cattle. . . . . 16

    Horses. . . . . 18

    Sheep . . . . . 18

    Swine . . . . . 19

    Dogs. . . . . 19

FIBROBLASTOMA . . . . . 21

MYXOBLASTOMA. . . . . 24

CHONDROBLASTOMAS. . . . . 24

OSTEOBLASTOMA . . . . . 24

LIPOBLASTOMA. . . . . 25

LEIOMYOBlastoma . . . . . 26

RHABDOBLASTOMA. . . . . 29

MESOTHELIOBLASTOMA. . . . . 30

LYMPHOBLASTOMA. . . . . 30

MYELOBLASTOMA . . . . . 36

MELANOBlastoma. . . . . 37

ENDOTHELIOBLASTOMA. . . . . 37

EPITHELIOBLASTOMA . . . . . 37

    Papilloma . . . . . 38

    Adenoma-glandular Tumor . . . . . 39

Carcinoma . . . . .	.40
SARCOMA . . . . .	.51
Alveolar Sarcoma. . . . .	.51
Tumors of the Adrenal-gland . . . . .	.53
TUMORS OF THE GENITAL TRACT . . . . .	.53
Secondary Tumors. . . . .	.54
Granulosa Cell Tumors . . . . .	.56
Theca Cells Tumor (Thecoma) . . . . .	.57
Cysts. . . . .	.57
Parovarian Tumors . . . . .	.60
Angiosarcoma. . . . .	.62
Infectious or Transmissible Lymphosarcoma . . . . .	.72
Chorionepithelioma. . . . .	.73
Choriohemangioma. . . . .	.75
Embryonal Nephroma. . . . .	.75
SUMMARY . . . . .	.76
ACKNOWLEDGMENTS . . . . .	.78
BIBLIOGRAPHY. . . . .	.79

## INTRODUCTION

Who does not know the value of reproduction? Dr. Oberst (1957a) was 100 percent correct when he once commented on the importance of reproduction and its diseases.... "It is not that I teach this subject, but you can well imagine, what would be our fate if there was no reproduction". Roberts (1956) cited Asdell who estimated that the loss due to sterility and reproduction troubles in dairy cattle amounts to \$250,000,000 annually in the U.S.A. In spite of the fact of its great importance and economic significance the subject has long been ignored.

Willett (1956) cited Casida who has shown that 85-90 percent of ova shed are fertilized, 21 percent of the fertilized ova die of embryonic death, and 40 percent of all potential young (ova shed in dairy cattle) are lost by 60-90 days after breeding. Of these last 40 percent, 3 percent are due to anatomical abnormalities in the cow, 9 percent are due to defective ova, 12 percent are the result of failure of fertilization from undetermined causes and 16 percent are due to embryonal death.

Complete elimination of this potential loss can probably never be accomplished, but we can work with greater success if we explore this important problem thoroughly.

Amongst the various general causes of infertility, infectious diseases with both specific or miscellaneous pathological lesions, hereditary or congenital anatomical defects, genetic defects, nutritional or deficiency diseases, we cannot in any case forget the importance or significance of the tumors of

the female genital tract.

The subject of tumors, even up to now, is not getting the proper attention it well deserves. A proper and complete study of neoplasms of the genital tract must be made to really reach this goal. The tumors of this tract are important on account of the frequent occurrence of carcinoma (Adeno-carcinoma) and lymphocytoma of the uterus with subsequent early death. All tumors whether benign or malignant will, depending upon their size and development, interfere with normal conception, predispose abortion, cause weakness, cause posterior paresis, or paralysis or interfere with normal birth. This is not all. Certain tumors of the ovary (granulosa cell tumors) may secrete oestrogen substances. This causes nymphomania, relaxation of pelvic ligaments, and other symptoms. Sometime an erroneous diagnosis of pregnancy is made when a large mass is palpated and large pulsating uterine arteries are felt. This results from a lack of an awareness of the probability of tumors of the reproductive tract.

With these things in mind the author was prompted to write this report.

#### HISTORICAL

Cancer is mentioned in the Papyrus Ebers (B.C. 15 A.D.)

---

For references see

- I Ewing. 1942
- II Lombard, C.M. and Lombard, L.S. 1955
- III Cotchin. 1956

and in the oldest remnants of the literature of India and Persia.

Hippocrates (B.C. to 460 to 375) employed the terms "KAPKIVOS" for all indolent ulcers and "KAPKIVAMA" for progressive malignant tumors. Herodotus mentions that Democedes (B.C. 520) cured Attosa of breast cancer. Attosa suffered from a "ovma" which means any chronic growth or swelling.

Celus (B.C. 30 to A.D. 38) distinguished several gross varieties of cancer. Galen (A.D. 131 to 203) presented the humoral doctrine of atra bilis. Swellings were secundum naturam (gravid uterus), supra naturam (callus formations), or praeter naturam (true tumors). The pneuma, composed of solid parts and four fluids, blood, mucus, yellow and black bile, ruled the processes of the body. Cancer developed from the concentration of black bile.

Suppression of menses and hemorrhoids, preventing the discharge of black bile, were chiefly responsible for cancer. For internal cancer, of which little was known, a diet chiefly vegetable was recommended. Walnuts were forbidden.

Leonides of Alexandria (A.D. 180) dissected out breast cancer with procedures closely resembling the modern excision technique.

In the Byzantine period (475-1500) considerable progress was made in the description of various tumors. Paulus of Aegina (625 to 690) separated chronic metritis from uterine cancer. In Arabia, Avicenna (980 to 1037) introduced the internal use of arsenic, and Avenzoar (1070 to 1162) employed the esophageal

sound and the nutrient enema. At the council of Tours (1162), and later at the Fourth Lateran conference, the ban of the church was laid upon the free pursuit of surgery. In fact, the 13th to 15th centuries were the dark ages for medicine but especially for surgery.

Lanfranchi, of Lyons, an exile from Mailland, established surgery in France (1190). He strongly urged the radical operation for cancer with free bleeding of the affected part. Henri de Mandeville and Gy de Chauliac (1300 to 1368), physician to Clement VII, excised cancer with the knife and developed to a high degree of proficiency extirpation by caustic arsenic.

The Renaissance (1500-1700), bringing the discovery of the printing press, greatly facilitated the spread of knowledge. This aided more accurate diagnosis and better treatment of cancer but threw little light on the etiology. Andreas Vesalius (1514 to 1564) began the attack on many of the concepts of Galen. He identified deep seated with ulcerating cancer. Fabricius (1537-1619) differentiated many inflammatory swellings from cancer and warned against incomplete removal.

Marcus Aurelius Severinus (1580-1686) described myxosarcoma and separated cancer from benign tumors of the breast.

In Prague, Sennert (1572-1637), and in Lisbon, Lusitanus (1642) first claimed that cancer was contagious. Paracelsus (1493-1541) stands out as the first successful opponent of Galen's theory of "atona bilis" as the cause of cancer. He claimed that the disease was due to mineral salts in the blood and later developed many fantastic theories regarding the nature of cancer.

## The Lymph Theory

In the 17th century Galen's doctrine was completely demolished by the discovery of the circulation by Harvey of the lymph-vessels by Olaus (1652), (Haeser) and of red blood cells by Malpighi (1661).

Malpighi used a microscope and did not find black bile but everywhere found blood and lymph. Lymph coagulated and foamed on boiling, hence cancer was thought to be composed of lymph varying in density, alkalinity or acidity. In malignant tumors it was thought to be fermenting and degenerating. Louis (1723-1792) distinguished gelatinous lymph (goiter) and albuminous lymph (Scirrhus). Le Drau (1685-1770) emphasized the local nature of cancer of the skin and the internal origin of breast cancer. He conceived that if a drop of cancer lymph passed the adjacent nodes it contaminated the entire system.

Astruc (1684-1766) separated cysts from true tumors and showed that scirrhus and soft cancer were of the same nature. He pointed out important differences in prognosis of different types of carcinomas, and by incineration proved that cancer and muscle tissue contained the same salts.

Margagni (1682-1772) established the importance of the pathological anatomy of cancer, and separated gumma, struma, exostosis, and lipoma from cancer.

The essay of Peyrilhe (1735-1804) submitted to the Academy of Lyons in answer to the question, "qu' est ce que le cancer?", deals systematically with the cancer toxin, the nature of the



disease, the manner of growth, and the treatment. He spoke of local origin, the production of specific virus from degeneration of the tumor, and the development of cachexia from this source.

Hoffmann held that life and health depended on normal movements of the tissues; cancer and other diseases resulted from atony, stasis, and abnormal fermentation of blood and lymph.

In 1802 the Society for Investigating the Nature and Cause of Cancer was formed in London. This organization formulated the problems of the disease as they stand today. The Society dissolved in 1906.

An English author, Hey (1736-1819), described in detail the structure of certain vascular tumors which he found to be composed of organized blood fluid and a large proportion of lymph. For this he employed the term "fungus hem-todes". Wardrop (1809) described in great detail miscellaneous tumors of this gross type thereby attempting to separate them from cancer.

Bayle and Cayol pointed out the difference between chronic mastitis and cancer.

Leipsic (1837) divided cancer into four types: Hard, soft, pigmented and blood cancer.

#### Histological Period.

With the construction of the achromatic microscope in Paris, 1824, a new era opened in cancer research. In 1838, J. Muller published this classical study of malignant tumors. He found them composed of groups of cells with each cell containing a nucleus and nucleolus. Certain elongated or racquet-shaped cells,

"geschwanzten Kopperchen," he regarded as on the way to fiber formation but not as specific cancer elements which he was unable to detect anywhere. His diagnosis rested on clinical signs and the anatomical grouping of the cells. He held the view that cancer developed not from normal tissue but from germ cells which as a "seminium morbi" lay scattered between the tissue elements.

It was held that most of the cells developed from the elastic lymph or blastema by a process of budding. Others resulted from division of the nucleus and cell body or by the transformation of intracellular blastema lying in spaces within the cell body (Virchow's Brutraume). The originating tumor-cells were not derivatives of the normal tissue cells but came from the *seminium morbi*. Lebert especially described such specific cells and designated as pseudo-cancer all tumors, such as rodent ulcer, which failed to contain them. Hannover described the group of tumors arising from stratified squamous epithelium and separated them from cancer under the term "epithelioma".

Hannover believed that cancer cells circulated in the blood and produced metastases as pus produces pyemia.

Fuchrer distinguished albuminous, chondrinous and glutinous varieties, each of which gave suitable colour reactions with nitric acid. These were suggested as sources of the corresponding tumors.

By 1860 most tumors were being rather accurately described and classified according to their microscopic anatomy. The description of the benign tumors was well known. The existence of various types of carcinomas and the separate position of

sarcomas were generally accepted facts.

Thiersch introduced the modern era of our knowledge of the nature of the disease. Waldeyer extended Thiersch's observations to the internal organs and traced the origin of cancer of the stomach, liver, and kidney to the epithelial cells of these organs. He first described the isolation of these cells by indurated connective tissue and held that tumors developed from these isolated cells. The formation of secondary tumors were demonstrated by him to be the result of continuous growth through blood and lymph-vessels as well as by cell embolism. Waldeyer eventually succeeded in demonstrating the epithelial origin of cancer. Recklinghausen and Koester thought that many cancers arose from the endothelium of lymph spaces and outcome of theory was the establishment of the group of endothelioma.

In 1877 Cohnheim suggested that tumors arise not from normal cells but mainly from isolated and generally embryonal cells and tissue rests. This greatly clarified the knowledge of the genesis of tumors by separating them from all other processes. The theory of cancerous dyscrasia necessarily lost ground with the demonstration that the disease has a local origin and that secondary tumors arise from transported cells.

Leblanc (1858) cited Ruelle as the first veterinarian to define cancer in modern times. Ruelle gave a definition in Latin which described vaguely some of its general symptoms. Garsault made specific reference to equine cancer. According to Leblanc, Doctor Lafosse designated cancer as thick indurated areas, cold deep abscesses, and swelling of the sublingual

lymph glands of horses affected with chronic glanders. He recommended only partial excision of cancerous tissue when topical medication failed.

Camper (1783) concluded that animals were apparently not subject to cancer because their life span is shorter than man.

Hurtrel d' Arboval, one of the Leblanc's contemporaries, in 1826 analyzed cancer on the basis of comparative medicine by drawing several analogies between various phases of disease in man and their counterparts in animals. Leblanc stated that this was the first accurate description of cancerous tissue in animals. He did, however, reject the opinion that excision of a malignant tumor should be delayed until the final stages. Vatel (1828) had also recommended surgical removal only after antiphlogistic medication had failed.

Doctors Trousseau and Leblanc began research in 1827 and recorded what are probably the first descriptions of internal cancerous lesions in animals. They advanced the hypothesis that cancer was traceable to general blood infection. Later they recognized that different types of homologous tumors could develop and mixed tumors could form. They observed that cancer could occur in soft pulpy areas as well as in indurated tissues.

Leblanc mentioned that 60 cases of cancer were recorded by fifty-two veterinarians between 1826 and 1843 in both French and foreign publications. These were observed in horses, mules, donkeys, cows, dogs, and pigs. After analyzing these statistics Leblanc listed the following organs according to the frequency of their involvement with cancer: mammary gland; lymph nodes, in

particular those of the inguinal region, axillae and mesentry; uterus; vagina; stomach; intestines; bladder; penis; prostate gland; spleen; heart; eye; tongue; and bone. In his publication in 1843 he stated that the dog and cat are much more susceptible to cancer than the herbivores species. Leblanc in 1858 displayed his foresight by stressing the importance of comparative study of diseases common to both man and animal.

Ewing stated that the 20th century opened as the experimental era with the systematic study of tumors throughout the animal kingdom really getting under way. It appears that this period may be noteworthy as the period of specific etiological investigation. This may differentiate many neoplastic diseases which were formerly thought to be closely related. It may thereby prove to be the era of successful diagnosis, prophylaxis and treatment.

Sticker, Folger (1917) and Teutschlaender (1920) as quoted by Feldman, 1932 reviewed the literature in a classical manner. Reference to important early papers by Joest and others are found in early volumes of *Fahresbericht Veterinary Medicine*. Many other references to tumors in domesticated mammals are found in standard texts of *Veterinary Pathology* such as those of Joest, Kitt and Nieberle and Cohrs.

Since the classical publication entitled "Tumors of Domestic Animals", was written by Feldman more interest is being shown. Courteau (Cotchin, 1956) reviewed the literature and described the tumors of the horse, sheep, ox, goat, and pig. Jackson (1936) described histopathology and his critical comment on the specimens

make this article one of importance in Veterinary anology. Fontaine (1938) reviewed literature. Mulligan (1949) described 1000 dog tumors. Dobberstein (Monlux, et al. 1956b) gave an interesting broad survey of the comparative pathology of tumors and stated that while all tumors that occur in man may occur in animals, some are still unrecorded, eg. chorion carcinoma. He pointed out that this is peculiar to man and is of a special type of placentation. He questioned whether it occurs in animals and wrote of the incidence of tumors in different species. Tomaschke (Cotchin, 1956) pointed out the unreliable nature of the earlier literature. He collected records of 5245 tumors in 8 species. More recently Cotchin (1956) has classically reviewed the entire literature on the subject.

## INCIDENCE OF NEOPLASMS IN GENERAL

From the recorded data, it is difficult to determine positively the true incidence of neoplasms in domestic animals. There apparently has been increased interest in this subject since the classic publication, "Neoplasms of the Domesticated Animals", by Feldman in 1932. He stated that this lack of knowledge was due partly to a lack of interest by veterinarians and partly to the lack of a central agency for analyzing the causes of spontaneous deaths in animals. Cotchin (1956) observed that in spite of important contributions by certain observers animal tumors are still not being given the attention they deserve.

In human medicine data pertaining to neoplasms is more complete. In referring to this in 1952 Steiner said "\_\_\_ that cancer mortality is over 200,000 per year and that it is increasing at the rate of approximately 3% or 5,000 per year \_\_\_". He estimated that reported figures may be lower than the true incidence in humans. This may be because of erroneous reports and of unreported cases that have been cured. Cotchin (1956) indicated that even though neoplasia in the large animals was not of major economic importance, its study was of importance as a facet of cancer research in general.

Many neoplastic diseases are not recognized or positively diagnosed except by necropsy examination. Steiner and Bengston (1951) pointed out that the meat inspection service of the United States is the largest animal necropsy service in the world. In 1949, for example, more than 83,000,000 ante and post mortem

examinations were made. These were largely on young animals not dying from disease and before the age that tumors commonly develop. Ten thousand entire animals were condemned for malignant generalized tumors. In addition, 911,409 parts of carcasses were condemned for "tumor abscesses". It was estimated that about 10 percent of the total were actually tumorous. They also commented on the large size of many animal tumors. This might be helpful in research.

The reporting of all swelling, whether neoplastic or inflammatory in nature, as tumors or "tumor abscesses" has created confusion. Table 1 cited by Feldman was compiled by the Chief of the Bureau of Animal Industry in 1930. From this report it is difficult if not impossible to determine the incidence of neoplasms.

Table 1. Data compiled by the Chief of the Bureau of Animal Industry in 1930 as cited by Feldman.

Animal	Carcasses Examined	Condemned for Tumors	
		Carcasses	Parts
Cattle	8,221,293	3,186	8,527
Calves*	4,482,129	82	3,229
Sheep & Lambs	15,283,989	430	203
Swine	46,553,938	2,852	422,871
Horses	135,989	152	2

\*Bovine animals aged one year or less.

Table 2 indicates that more recently accurate differentiation gives available data truer significance. In this table Monlux, et al. (1956) showed the occurrence of tumors in three species of animals slaughtered at all federally inspected abattoirs in 1953



as recorded in the annual report of the Chief of the Bureau of Animal Industry.

They concluded that adenocarcinoma of the uterus and lymphosarcoma in cattle were economically important because of their frequent occurrence and their predictable early death. Among other things they did not find as many granulosa cell tumors of the ovary as had been anticipated. Neoplastic diseases in slaughtered swine and sheep were found to be much less important than in cattle.

Cotchin (1956) presented data indicating the types of neoplasms which appear most commonly in different parts of the body in different species. This is shown in Table 3.

Table 2. Occurrence of tumors in three species of animals slaughtered reported in the annual report of the Chief of the Bureau of Animal Industry as cited by Monlux et al.

Name of Animals Inspected:	Series	Number of Carcasses : Condemned at Ante or : Post Mortem Inspection.			Leukemia: : or : Lymphoma:			Sarc:			Misc:			Number of Parts of Carcasses Condemned by Post Mortem Inspection		
		Carcin:	Epith:	Epith:	Carcin:	Epith:	Epith:	Carcin:	Epith:	Epith:	Carcin:	Epith:	Epith:	Carcin:	Epith:	Misc:
Cattle	15,208,023	1,538	4,402	1,518	540	2,247	40	25,608	87							
Calves	6,027,449	14	2	100	15	89	--	64	5							
Sheep & Lambs	13,623,394	51	4	34	26	131	--	--	2							
Swine	56,395,484	241	-	529	234	624	--	3	13							

Table 3. Data indicating types of Neoplasms as cited by Cotchin.

Species Differences in Occurance of Neoplasm  
 Species in which the tumours named are important

	System of origin:	Horse	Cattle	Sheep	Pig	Dog	Cat
Skin	Papilloma		Papilloma	x	x	Basal cell & Basal cell Glandular & Glandular tumors	tumors x
Mammary Gland	Melanoma		Melanoma	x	x	Melanoma	x
		x	x	x	x	"mixed & Carcinoma	Carcinoma
Skeletal		x	x	x	x	Bone- sarcoma	Bone- sarcoma
Respiratory		x	x	x	x		x
Cardiovascular		x	x	x	x	Congenital Rhabdomyoma of heart	x
Lymphatic		x	Leukosis	x	Leukosis	Leukosis	Leukosis
Alimentary		x	Papilloma of esophagus	x	x	Carcinoma of tonsil	Visceral lympho- sarcoma
		x	Liver carcinoma	same as cattle	x	Intestinal lymphosarcoma	Carcinoma of tongue and esophagus
Urinary		x	x	x	Nephro- blastoma	Lympho- sarcoma of kidney	Lympho- sarcoma of kidney
Male genital		Carcinoma of penis	Fibro-papilloma of ext. genital organs	x	x	Testis tumors	x
Female genital		x	Fibro-leiomyoma	x	x	Fibro- leiomyoma	x
Endocrine		x	Adrenal tumors	x	x	Thyroid tumour	x
Nervous system							
Eye		Carcinoma	Carcinoma	x	x		
Ear		x	x	x	x		Ceruminous carcinoma

## Cattle

Trotter reported over 300 cases of malignant tumors in cattle. Table 4 shows the distribution of 305 primary tumors in various organs and tissues of the body. Of these 279 (91.47%) were carcinomas and 26 (8.52%) were sarcomas.

Table 4. Distribution of tumors  
Various organs and tissue of the body.

Organ or tissue Affected	Number	Percent
Liver	222	74.0
Rumen	25	8.3
Thymus	16	5.3
Intestines	10	3.3
Lung	8	2.6
Ovary	5	1.6
Eye	4	1.3
Vulva	3	1.0
Lymph node	3	1.0
Kidney	1	0.3
Gall Bladder	1	0.3
Uterus	1	0.3
Bones	1	0.3
Skin	1	0.3
Fascia	1	0.3
Salivary gland	1	0.3
Undetermined	2	0.6

Mulligan (1949), in analyzing the age susceptibility in 809

tumors of dogs, came to the conclusion that the beginning of the cancer age was about six years. Trotter (1911) found 75 percent of malignant tumors were among old cattle aged 15 to 20 years. Kenny (1944) found that 80 percent of 214 tumors collected were from dairy cows that were from 3 to 16 years old. The average age was seven years. Runnels and Benbrook (1942) found that more of the tumors in horses occur at an age of 7 to 12 years. Most meat animals are slaughtered before this age of susceptibility is reached. From this it is clear that in order to determine the true incidence susceptibility of different species of animals to neoplasms, it would be necessary to allow all animals to live to old age. A necropsy examination would then be essential to make certain that no tumor was overlooked. This is impossible and impractical.

Trotter (A.M.) 1911 reported 131 cases of malignant tumors among 47,362 cattle including 1,549 calves in 1903. Had cattle under two or three years of age been excluded, the incidence would have been much higher. Wadsworth (1952) cited Detroge who compiled records on 77 tumors of cattle. Of these 73 occurred in adults and four in calves. He estimated the incidence at 1 : 1000 in mature cattle and 1 : 6000 in calves. Davis et al. (1933), Jackson (1936), Kinsley (1917), Plummer (1948, 1951), Tamaschke (1951/52/55), Wadsworth (1952), Kenny (1944), and Nair and Sastry (1954) have also reported on the occurrence of neoplasms in cattle.

## Horses

In horses Kust (Feldman, 1932) noticed 36 tumors of the vagina, clitoris and vulva (0.019%) while studying the tumors of the external genitalia of 195,239 mares. Twenty-one were in the vagina; eleven were of the clitoris, and 4 involved the vulva. These observations were made in a period of 22 years. In the Berlin surgical clinic there were four tumors of the external genitalia (0.018%) among 20,226 animals presented during the same period of time.

Cesari (Cotchin, 1956) found 189 epithelial tumors among 40,000 horses inspected at horse meat abattoirs at Decroix. He stated that tumors were three and one half times more frequent in stallions than in mares; moreover they were 6 times more frequent in stallion than in geldings. Most of the cancerous growths were of the testis and mammary gland. Courteau (Cotchin, 1956) stated that from specimens received in Peyron's laboratory in Paris that neoplasms occur more frequently in horses than in cattle. This is contrary to the opinion of Feldman (1932). Goffinet (1945) commented that tumors in horses had less grave effect than those seen in man. Runnels and Benbrook (1941 and 1942) also made interesting and important observations of tumors found in horses.

## Sheep

Feldman (1932) stated that sheep possess marked racial insusceptibility to the newgrowths. He reported five tumors were found amongst 52 sheep examined in the surgical and ambulatory clinic of the New York State Veterinary College at Cornell

University during 1929 and 1930. He stressed that this incidence should be regarded as very unusual. He also commented that sheep were immune to tumors. Davis et al. (1933) noticed that tumors were encountered less frequently in sheep than in cattle. Monlux et al. (1956b) reported that neoplasms in sheep were less important than in cattle.

#### Swine

Feldman (1932) stated, that with the exception of embryonal nephroma of the kidney, tumors are not commonly seen in swine. Sticker (Feldman 1932, Cotchin 1956) found only 12 carcinomas from hogs among 1,200 carcinomas of animals. Folger (Feldman 1932) cited the observation of Gaylord and Zine who noted 4 (0.2%) malignant growths among 2,000 swine slaughtered at Buffalo. Davis et al. (1933) and Steiner and Bengston (1951) reported a low incidence of tumors in swine. Monlux et al. (1956b) concluded that neoplastic diseases in slaughtered swine were of much less importance than in slaughtered cattle.

#### Dogs

Since dogs are allowed to live to old age, more information about the neoplasms common to them is available than for any other of the domestic animals. It has been observed that two or more primary tumors may be encountered in one patient. Cadiot (Feldman, 1932) observed that the occurrence of neoplasms in dogs was two to three times that in herbivora. Feldman (1932) reported that dogs were the most susceptible amongst domestic

mammals to neoplasms. Goodpasture and Wislocki (Feldman 1932) reported 228 tumors in the series of 50 dogs. Of these 13 were malignant and 215 were benign. Ortschild quoted Semmer's figures that 354 (8%) tumors were observed amongst 3525 dogs. Feldman (1932) reported that four dogs (7.6%) had tumors in a series of 52 necropsy examinations of dogs in the course of one year at the New York State Veterinary College. Frohner (Feldman 1932) observed 2,871 dogs with tumors (4.7 percent) at the Berlin Veterinary High School among 60,471 canine patients in an 8 year period. He stated that the actual incidence was higher than recorded since these figures did not include the internal neoplasms. Amongst 8,897 dogs examined at the Hospital Clinic in Berlin (1886-1894) 643 dogs were operated for some form of neoplasms. Mulligan (1949) found in 1,000 neoplasms collected from 809 dogs that nearly 45% were cancerous. Amongst these there were 6 ovarian carcinomas and 1 vaginal carcinoma. Amongst non-cancerous tumors, only in one instance was the ovary affected. It was a cystadenoma.

Auler and Wernicke (Cotchin, 1956) reported a series of 525 tumors from dogs in a period of four years. Of these 326 were malignant. Antoine et al. (Cotchin, 1956) examined neoplasms from 214 dogs. Seventy three of these were in males and 133 were in females. The highest incidence of tumors occurred between 8 and 10 years of age. Of this series 78 were benign and 163 were malignant. Klarenbeck and Bussemaker (Cotchin, 1956) gave an account of 612 tumors seen from 1925 to 1932. Three hundred two were malignant. Twice as many of these tumors occurred in females



as in males. In examining 5,643 dogs Lasserre et al. Cotchin, 1954) found that 402 had tumors. Of the affected animals 279 were females and 123 were males. This number included 103 transmissible venereal tumors. They are not considered to be malignant. McClelland (1940), Knight and Douglas (1943), Stunzi, Whitney, and Krook (as quoted by Cotchin, 1956) also reported on the occurrence of tumors in dogs.

From the reports of Morrill, Lasserre et al., and Mulligan also quoted by Cotchin (1956) and it appears that tumors are more common among female than among male cats. Cotchin (1956) reported on 226 tumors from cats. Seventy percent of these masses were from cats between 6 and 12 years of age. Of this group 22 were involving the female genitalia.

#### FIBROBLASTOMA

Fibromas are benign connective tissue neoplasms. According to Williams (1939) fibromas frequently occur on the vulva. Fibroid vaginal tumors are not rare and are usually pedunculated. These are usually attached to the hymenal ring and protrude from the vulva when the animal is recumbent. They may tear at the time of parturition. Bloom (1954) noticed that fibromas were the commonest primary neoplasms of the labia of the dogs vestibule. He further stated that next to leiomyomas they occur in the vagina more commonly than other benign vaginal tumors. He was of the opinion that it is exceedingly rare in the uterus and in the ovaries of dogs and cats. Jakeson (1936) said that its occurrence

on the reproductive tract is uncommon. Mulligan (1949) indicated that complete excision of fibromas is necessary since these may become malignant.

Fuch (Folger and Feldman, 1932) found fibromas of the uterus on two occasions amongst 5,000 cattle. One of these was in an eight year old cow and was undoubtedly a true fibroma. The other may have been the result of a tuberculous process. Folger (Feldman, 1932) cited a case of a polyp-like fibroma of the cervix. It weighed 7.8 kg. and was removed surgically. From older literature, Casper (Feldman, 1932) noted a fibroma of the uterus of a cow weighing 100 kg.. Williams (1939) wrote of a fibroma from the uterus of a cow weighing 11 pounds. The cow had shown no previous symptoms, but exhibited severe pain with violent expulsive efforts. This forced the tumor out through the vulva. In another case he recognized a large fibroid uterine mass clinically. This cow had produced several calves from the other uterine horn. She then became sterile. He was not certain whether or not this tumor had some relationship with the sterility. Nair and Sastry (1954) found a fibroma of the uterus and two of the vulva among 72 tumors in cows. Lagerlof and Boyd (1950) reported seven fibromas of 52 tumors of the reproductive organs amongst 6,286 head of the Swedish Highlander breed. Lombard and Bodin, Eyer, and Breuer as cited by Cotchin (1956) described vaginal fibromas.

Parker removed a fibroma from the cervix of a mare. It weighed 1.4 kg.. Mahony (Cotchin, 1956) described the uterus of a mare in which there were a number of lesions. One of these

was examined and was found to be a fibroma. He stated that he had noticed 50 such cases in a period of two years. All had been bred to the same stallion. Every filly was affected with these uterine lesions between one and three years of age.

In dogs Feldman (1932) reported that fibromas have been observed in the vagina, mammary gland and in the mouth. Mulligan (1949) wrote that fibromas may weigh from 2 to 10 kg. in dogs. Bloom (1954) observed one fibroma in the ovary of an aged dog. It involved only one ovary and measured 9 cm. in diameter. Cotchin (1956) found 14 fibromas amongst 26 vaginal tumors of dogs.

Casper quoted Kitt (Feldman, 1932) as having observed a fibroma of the uterus of a sow weighing 15 kg..

Bloom (1954) found that after leiomyomas and fibromas, neurofibromas occur next in importance in the vagina of the dog. They may also occur on the vulvar vestibule. Regressive changes are frequent.

Hewetson and Carter (1955) found a neurofibrosarcoma of the uterus of a 16 year old cow. She aborted a seven month fetus. After that she did not conceive in spite of apparently normal estrum. It was noticed on examination that the cervix was drawn forward to the rim of the pelvis. The uterus was large, soft, and fluctuating. It hung low in the abdominal cavity. A diagnosis of pyometra was made on necropsy examination, and the cervix was found to merge with the uterus which was 36 inches long and 18 inches wide. The uterus was filled with a somewhat rubbery solid white mass containing many pale yellow areas throughout. The

regional lymph glands and the other organs were not involved.

They concluded that neoplasms arising from the fibrous tissue elements of peripheral nerves are not rare in animals, but such neoplasms in the uterus of a cow do not appear to have been recorded before.

#### MYXOMABLASTOMA

Bloom (1954) observed that myxomas are exceedingly rare in the ovaries of the dog and cat.

Plummer (1951) found one myxoma among thirty-seven cattle tumors. The myxoma was attached to the floor of the pelvic cavity where it might have interfered with parturition.

Hebrant and Antonie (Feldman, 1932) reported one large myxosarcoma of the ovary of a dog.

#### CHONDROBLASTOMA

Chondromas and chondrosarcomas may occur in the testes, ovaries, and mammary glands. Here they are called teratomas since they originate from embryonic cells.

A fibro-chondroma affecting the ovary of a sheep has been very well illustrated in Kitt's Textbook of Pathology (1906).

Bloom (1954) stated that chondrosarcomas occur exceedingly rarely in the ovaries of the dog and cat.

#### OSTEOBLASTOMA

Osteomas or osteosarcomas apparently do not invade the reproductive organs since no reports of these were found.

## LIPOBLASTOMA

In the dog Bloom (1954) found primary benign lipomas were most common in the vulvar labia. They are rare in the vagina and the vestibule and exceedingly rare in the uterus of the dog. He had occasionally seen pedunculated areas of fat necrosis in the broad ligament. These are enclosed in thin fibrous capsules. Cotchin (1956) found three lipomas amongst the twenty-seven vaginal tumors of dogs.

Joest (Feldman, 1932) described a lipoma weighing 8.7 kg. in the pelvic cavity of a cow. It interfered with normal parturition and resulted in the cow's death. Kitt (Feldman, 1932) said that Lund observed a lipoma of the submucosa of the uterus (weight 75 kg.). Nair and Sastry (1954) observed three lipomas (0.115 percent) amongst 2003 tumors of cattle. Of these one was in the uterine cervix. Edgson (1952) described seven cases of Bovine Lipomatosis. In one case the mass was 20 X 10 cm. in size and occurred below the rectum superior to the uterus in the retroperitoneal region. In another case the uterus, vagina, and part of the rectum was involved. There was diffuse fat in the broad ligaments. In another case there was deposited pedunculated fat in the ovarian tissue and in the ovarian bursae. He also described a case of long standing infertility. A lipoma 5 cm. in diameter was in the right dorsal aspect of the posterior retroperitoneal region. The cow had a low grade chronic metritis.

## LEIOMYOBLASTOMA

A leiomyoma may attain large size without any untoward effect, but when it narrows the lumen of the uterus or intestine, it seriously interferes with their normal functions. Pregnancy may be complicated. Unless malignant its presence in the uterus or intestine is not likely to cause symptoms that would disclose its presence. In Bloom's (1954) opinion leiomyomas are amongst the commonest benign tumors of the vestibule. They are the commonest tumors seen in the vagina and uterus. Degenerative changes may occur causing pyometra, pressure urinary disturbances and uterine bleeding. When there are extensive degenerative changes, there may be pain, soreness on abdominal palpation, vomiting, dullness and slight leucocytosis. When in the vagina they may sometime cause mechanical obstruction of the urinary meatus hence interference with urination. Pressure on the rectum predisposes to constipation. They interfere with coition and parturition.

Feldman (1932) collected 28 tumors and their distribution was as follows: oviduct, one; uterus, eight; cervix, one; broad ligament, two; bladder, two; caecum, two; small intestine, two; spleen, three. The sites were not determined in two cases.

Lavis, et al. (1933) found one Leiomyoma of the uterus of an ewe amongst 34 tumors of sheep.

Feldman (1932) noted one leiomyoma (28x13 cm) weighing approximately 5.2 kg. was described in old literature. Its presence was only noticed when it was forced out through the vulva by the strenuous exertions of the animal. The animal died after

the tumor was surgically removed from rupture of the uterine artery by traction on the expelled growth.

Cattle. Leiomyomas occur mostly in the smooth musculature of the genital tract. They usually contain a large amount of fibrous connective tissue. These are often termed fibromyomas or fibroids. The uterus seems to have a predilection for these tumors. Amongst the 10 tumors of the genital tract, Feldman noticed six in the uterus.

Casper quoted Spreule as cited by Feldman, (1932) who found 15 large tumors and many smaller ones in the uterus of a cow. Their total weight was 80 kg. In one case the interior of the uterus had large numbers of nodular growths from 3 to 20 cm. in diameter. Amaducci (Feldman, 1932) observed a leiomyoma weighing 4860 gm. in the cervix. Goring (Feldman, 1932) found five leiomyomas in the vagina of a slaughtered cow. The largest was 14 cm. in diameter. Feldman (1932) mentioned that Jones, Albrecht, Kohlhepp and Barbier have all reported leiomyomas of the vagina. Bidault described a fibromyoma from the uterus of a cow. Hopkirk (1926) described a leiomyoma of the uterus of a cow weighing 52 lbs. It was egg shaped (15" x 18") on the anterior surface of the cervix.

Feldman (1932) in his series found leiomyosarcoma in two cows. Bidault (Feldman, 1932) found one of these involving the uterus of a cow. Davis et al. (1933) found two leiomyosarcomas of the uteri of cows amongst a total number of 90 tumors of cattle.

Monlux, et al. (1956b) noticed eight leiomyomas and four of these were in the uterus. The largest leiomyoma of the uterus

found was from an old cow. It measured 28 x 18 x 7 cm. One was a solid, oval encapsulated mass (14 x 14 x 12 cm.) in the uterus. The mucosa and serosa were also involved. In some areas it was fibrous. It was firm and grey with yellow necrotic areas. One ovary had a large cyst in its parenchyma. One of the other two uterine leiomyomas measured 11 x 10 x 6 cm. and was involving the gravid horn. The other was 13 cm. in diameter. Three of these four affected cows had cysts in their ovaries.

Amaducci (Feldman, 1932) reported an enormous leiomyoma in the cervix of a cow. Wilmas (1935) described a leiomyoma of the uterus of the mare. Feldman (1932) found leiomyomas of the uterus in two old ewes slaughtered for food. One tumor weighed 15 kg. and the other 2.5 kg. Davis, et al. (1933) observed one uterine leiomyoma in a sheep. In another sheep they found many tumor masses in the uterus.

Joest observed two cases of leiomyomas in swine. One weighed 9 kg. and was in the left horn of a nongravid uterus of a sow that had farrowed a number of times. The other weighed 8.5 kg. and was in the left uterine horn of a pregnant sow. In the latter case the uterus contained four macerated fetuses and was suffering from purulent meteritis. Johne reported four leiomyomas of the uterus. Beis (Feldman, 1932) also found one weighing 35 kg. in the uterus. Zietzschaann (Feldman, 1932) found a leiomyoma in each uterine horn of a sow. Czapalla (Cotchin, 1956) described a leiomyoma weighing 19 kg. in the left uterine horn of a sow.

Folger (Feldman, 1932) quoted Maggi, who, on necropsy examination found in the right cornua of the uterus of a 12 year



old St. Bernard bitch. This mass was designated Lipofibromyoma because it contained smooth muscle, connective tissue and fat. Its weight was 980 grammes and its greatest diameter was 40 cm.

Hobbs (Feldman, 1932) found a fibromyoma (3 cm. in diameter) in the uterus of a bitch on necropsy examination. The bitch had been infertile for the last 12 years. In another case a smaller tumor of the vulva recurred a few months of its removal. Auger (Feldman, 1932) removed a cystic fibromyoma weighing 150 gms from the cervix of a dog. Johne (Casper and Feldman, 1932) found two leiomyomas in the vagina. Casper quoted Leisering who observed a large number of variable sized tumors, fibromyomas, in the vaginal mucosa. Cotchin (1954) found three leiomyomas amongst 27 vaginal tumors of dog.

Petit (Feldman, 1932) found a leiomyoma of the uterus of a cat. Richard (Feldman, 1932) found a cystic fibromyoma (6 x 15 cm.) of the left uterine cornua of a nine year old cat. Mulligan (Cotchin, 1956) found one leiomyoma of the uterus of cat. This was the only one amongst the 70 tumors of cats examined by him.

Leiomyomas of the genital tract or lateral ligament have been described in a lion, a 50 year old elephant, an Indian elephant, and a muskrat by Mulvicini, Joest, Fox and Hilgendorf and Paulicki respectively. This was cited by Cotchin (1956).

#### RHABDOBLASTOMA

Bloom (1954) stated that rhabdomas and various types of sarcomas in the vulva and vagina are extremely rare in bitches. He further stated that rhabdosarcomas of the uterus and various

types of sarcomas in the vulva and vagina are also rare. As a rule malignant tumors in the domesticated animals occur rarely in comparison to their occurrence in women.

#### MESOTHELIOBLASTOMA

No report has been recorded that this type can involve the female reproductive tract.

Monlux et al. (1956b) stated, "There is hesitancy in diagnosing a primary mesothelioma of either the pleural, pericardial, or peritoneal cavities because of the similarity of lesions of some inflammatory processes and metastatic or primary tumors of various membranes. In some peritoneal metastases of ovarian, uterine, bile duct, and intestinal carcinomas individual histological sections could easily be mistaken for mesotheliomas."

#### LYMPHOBLASTOMA

A large number of cattle are condemned by the meat inspection service of the Animal Research Service in the United States because of lymphoid tumors. Feldman (1932) cited the data in Table 5 from the report of the Chief of the Bureau of Animal Industry for the four years prior to June 30, 1930, which showed the number of animals condemned because of leukemia (lymphoblastoma).

Davis and others (1933) noted that this form of tumor is second in frequency to the carcinomas in cattle and sheep and more prevalent than carcinomas in swine.

Cotchin (1956) reported that lymphoid tumors occur most

Table 5. Condemnation for Leukemia by Federal Meat Inspection Service of the Bureau of Animal Industry.\*

Animals	Necropsy	Condemned for so-called Leukemia	Ratio
Cattle	35,654,719	4,183	1 in approx. 8,500
Calves**	18,872,047	126	1 " " 149,000
Swine	204,870,269	924	1 " " 220,000
Sheep	54,953,621	32	1 " " 1,714,000
Horses	402,714	2	1 " " 201,000

\* During the period over which these statistics were gathered necropsies were also performed on 94,000 goat carcasses, in none of which was there gross demonstrable evidence of leukemia.

\*\* Aged one year or less.

frequently in Germany and to a lesser extent in America. In certain areas the incidence is relatively high while in other places cases are few in number and are sporadic.

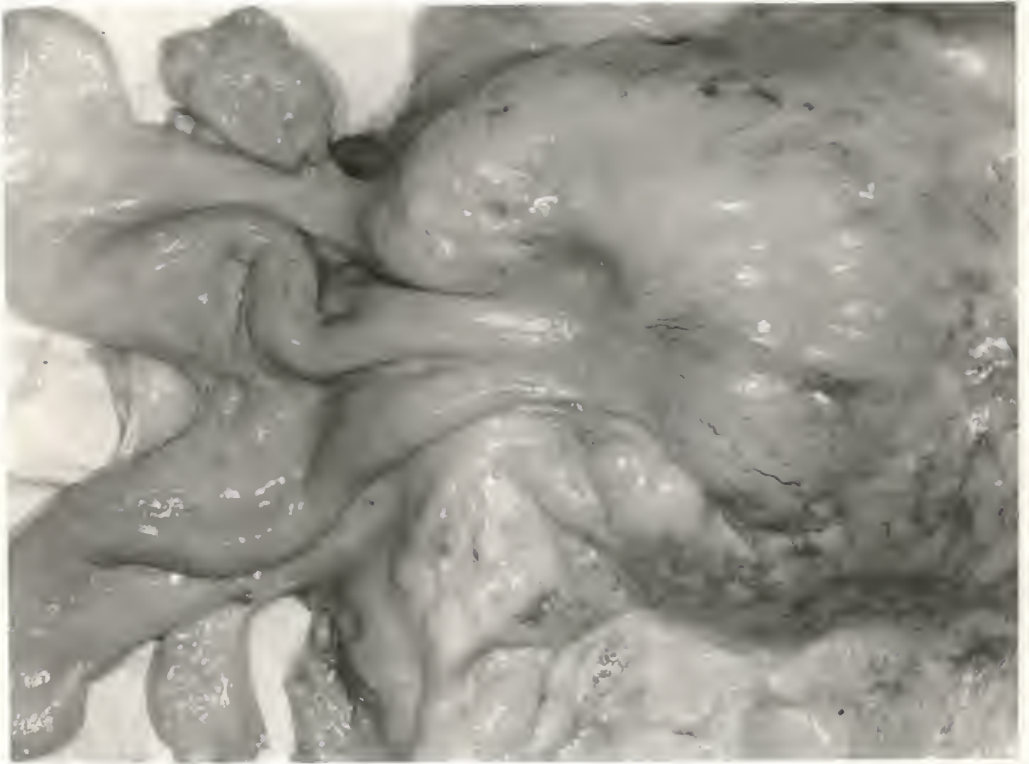Thompson and Roderick (1942) during a period of three years noticed that affected cattle showed increased lymphocyte numbers of the white blood cells. Many atypical lymphocyte cells were seen. These cells showed only slight difference between the nucleus and cytoplasm. Morphologically the cells changed to a large-type cell with a bizarre-shaped nucleus. Many large vacuoles appeared in the cytoplasm. Less common were lymphocytes containing 2 or more nuclei. Others showed several nucleoli. Of these 38 cases went to the necropsy room. Thirty six had gross lesions of lymphocytoma. Here it is assumed that generalized and visceral lymphosarcomas are an aspect of lymphoid leukosis.

Plummer (1948) observed lymphosarcomas amongst 24 tumors (21 cattle and three hogs). In one case Plummer found a lymphoid mass in the pelvic cavity of an aged cow. The tumor was attached to the rectum, vagina and the pelvic wall. The tumor weighed 10

EXPLANATION OF PLATE I

Lymphocytoma involving the cow's  
genital tract. (Unopened)

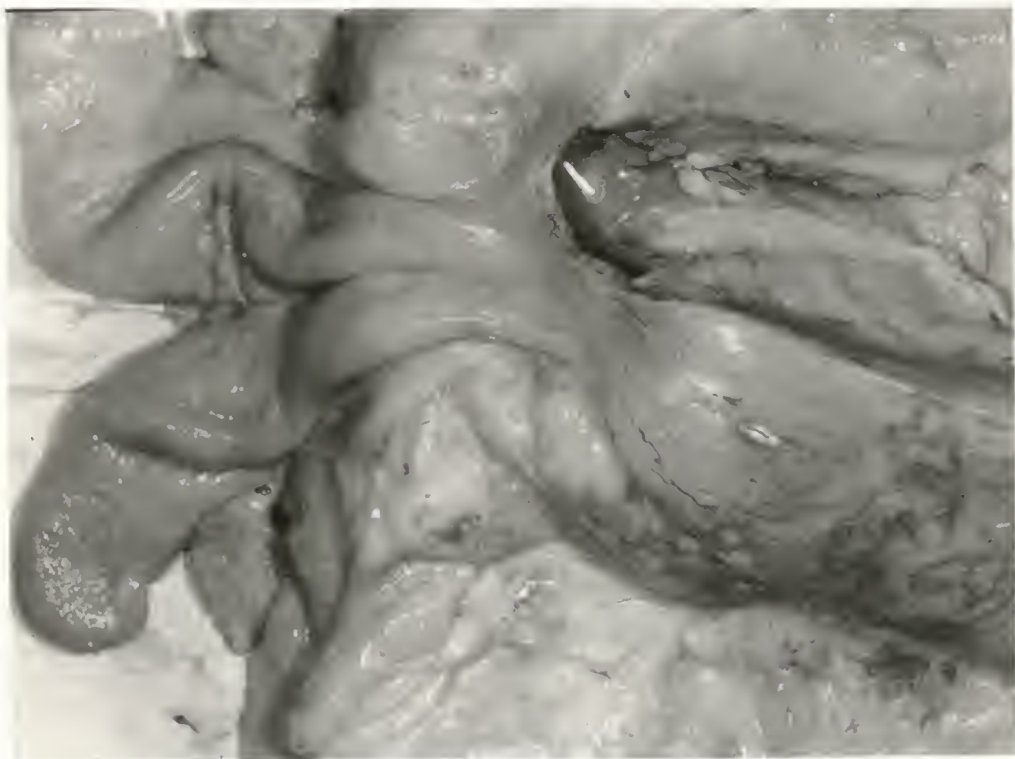
## PLATE I



EXPLANATION OF PLATE II

Lymphcytoma involving the cow's genital tract. (Opened)

## PLATE II



pounds.

The author noticed on necropsy examination of a cow an extensive lymphoid tumor involving the entire genital tract, the ovaries, oviducts, uterus, cervix and vagina. The tract is pictured in Figs. 1 and 2 .

Monlux et al. (1956) observed multiple uterine lesions in 6 animals with sublumbar lesions amongst 20 bovine cases. The uterine lymphosarcomas are easily confused with smooth muscle tumors, uterine carcinomas, and various granulomas.

#### MYELOBLASTOMA

According to Wadsworth (1952) myeloblastomas (Chlocomas) are rare neoplasms in the domesticated animals and have little significance if any to an average veterinary practitioner.

Feldman (1932) observed seven myeloblastomas amongst his collection of 535 tumors of animals. Amongst 230 tumors of cattle three were myeloblastomas. In one case the growths were present in the uterus, lung, spleen, kidneys, muscles and practically all of the lymph nodes.

Monlux et al. (1956b) observed two myeloblastomas (malignant) amongst 66 sheep tumors. Neither of the tumors exhibited greenish color noticed by Feldman. One of the two affected sheep had multiple lesions in the liver and in each cornua of the uterus. Growths also involved the broad ligament of the uterus as well as the peritoneum, posterior aorta, vena cava, and the sublumbar, internal iliac, renal and one external iliac lymph nodes.



## MELANOBLASTOMA

In horses, melanoblastomas may occur on external genitalia of either sex as well as on the ventral surface of the tail, the perineum and less frequently on other parts of the body.

McGowan (Feldman, 1932) recorded the occurrence of melanotic tumors in fowls. One was considered to be epithelial in nature and was arising from the membrana granulosa of the graffian follicle. The non cancerous type when irritated or incompletely excised may be transformed into the cancerous type melanoma.

## ENDOTHELIOMA

Davis et al. (1933) mentioned that they had observed one cavernous hemangioma (3.8%) involving the ovary amongst 26 tumors of swine and one hemangioma (2.9%) amongst 34 sheep tumors. Jackson (1936) reported a lymphangioma of the ovary of a mule. Bloom (1954) stated that angio-sarcomas were exceedingly rare in the uterus and the ovaries of dogs and cats.

## EPITHELIOMA

The majority of this group of tumors frequently affect domestic animals. These new growths arise from the epithelium of the skin, mucous membrane and glandular organs. Epitheliomas are sub-divided into three groups:

1. Papillomas---Non malignant but occasionally may have aggressive tendencies (papillary carcinoma).
2. Adenomas-----Adeno carcinoma.
3. Carcinomas---Malignant.

## Papilloma

Bloom (1954) stated that papillomas were the least common in the vestibule of the dog. Benign epithelial tumors were exceedingly rare in the vagina and included the epidermoid papillomas. In horses Papillomas can also occur on the external genitalia. Hobday (Feldman, 1932) described a case of toy Yorkshire bitch in which a papilloma was found in the vulva.

Jackson (1936) observed two epithelioma (accanthoma) involving the vulva amongst the 23 such tumors of cattle. Balog (Cotchin, 1956) wrote that papillomas of the vulvar region of young cows were not uncommon in Egypt. Pritchett (1941) described 2 vaginal papillomas in a calf. Williams (1939) referred a group of 26 unbred heifers, 15 of which developed epithelial tumors (Fibrosarcoma) of the vulva. Some disappeared when the heifers were turned on pasture. He stated that fibro-vulvo-vaginal tumors were not exceedingly rare in heifers. Kust (McEntee, 1952) reported that tumors in the vagina were not very common but they were mainly connective tissue tumors with well differentiated characteristics. Franklin (1946) observed a fibrosarcoma in the vagina of a shorthorn heifer, but the history of the development and regression suggested a benign growth.

Fibropapillomas of the external genitalia were described by Williams (1939) as papillary, fibrous tumors with variable amounts of epithelial covering. Fifty-five fibropapillomas of the external genitalia of cattle were studied in the Pathology Department of the New York State Veterinary College between Novem-

ber, 1929, and March, 1950. Among them 27 were from the vulva and vagina. The majority of them occurred in young animals, and it was suggested that they were due to a transmissible agent.

Mulligan (1949) observed 28 fibiopatillomas amongst 1000 tumors of dogs. He also noticed 31 infectious papillomas (*verruca vulgaris*) amongst the same 1000 dog tumors. These may regress spontaneously.

#### Adenoma-glandular Tumor

Adenomas are non-malignant squamous epithelial tumors. They consist of epithelial cells with a fibrous stroma. Epithelial cells are so arranged to simulate glandular structure. They are circumscribed, firm, nodular white or greyish white masses.

Simple adenomas do not invade or destroy tissue; however they can become malignant and assume the character of carcinomas (adeno-carcinoma). Sometime the secretion of an adenoma is retained in the acinii. It then becomes extremely distended with fluid and the epithelium undergo atrophy (cystadenoma). This form commonly occurs in the ovary of fowls. Occassionally, the proliferating epithelium may push into the lumen of the acini and take the form of branching papillae.

Koyama (Feldman, 1932) reported a case of multiple adenomas of the uterus of a rabbit. One tumor was in the right uterine horn and three were in the left. The mammary glands became large and milk was secreted. Polson (Feldman, 1932) found that the uterus was the most common site of tumors in rabbit. The

majority of these were either adenomas or adeno-carcinomas. He recorded eight adenoma and 21 adenocarcinoma tumors amongst the 52 cases recorded by him. Fox (Feldman, 1932) observed fibro-adenomas of the uterus and bile duct of a jaguar.

Cotchin (1954a) found two papillary cystadenomas in the ovaries of a bitch amongst the 14 ovarian tumors. Mols (Cotchin, 1956) described a papillary cystadenoma of the left ovary of a 9 year old bitch. Goldberg (1920) stated that cystadenomas of ovaries were common. Cotchin (1954a) mentioned one cystadenoma of the mesovarium. Mulligan (1949) found 121 adenomas amongst 1000 tumors of dogs. One cystadema was in the ovary.

#### Carcinoma

In carcinomas epithelial cells proliferate in an atypical and lawless manner. They exhibit a tendency to infiltrate and destroy the surrounding tissue and metastasize. The term, carcinoma, refers to malignant tumors in general unless otherwise indicated. Wadsworth (1952) stated they are frequently pink or greyish-white in color and those involving the ovaries may be colloid in nature.

Its degree of malignancy depends upon the tissue involved, the anatomical possibilities of early metastasis, the histologic character of the tumor, and its inherent capacity for growth. It causes the destruction of normal cells and may be the cause of death of the patient within a few months. Other cases progress slowly and the patient may live for years.

Involvement of the ovary or the oviduct usually induces cessation of ovulation and results in sterility. If the uterus

is affected, the usefulness of the animal as a breeder is definitely terminated.

The extreme cachexia, frequently a part of the picture in the human being suffering from carcinoma, is not so often observed in lower animals except in some cases of internal carcinomas. They usually show symptoms in the last stages of development. The great majority are discovered only on necropsy examination. External carcinoma become purulent after trauma.

An Adeno-carcinoma is also a true carcinoma which is characterised by an adenomatous, glandular, or duct like arrangement of the parenchymatous cells.

Squamous cell carcinomas originate from the cells of the epidermis and hence the majority of the carcinomas of the skin, penis, vulva, esophagus, mouth, pharynx and the nasal passages are of this type.

Basal cell carcinoma histogenesis is somewhat controversial. Mallory (1910) thinks that these arise from the undifferentiated epithelial cells of the matrix from which the hair normally develops. Krompecher (Feldman, 1932) observed that the cells were from the basal or deepest layer of stratum germinativum of the epidermis. Jackson (1936) stated that they are locally malignant but non-metastasizing tumors of the skin and are composed of basal cells of squamous epithelium or its derivative. The latter have the tendency to arrange themselves vertically to the septa of the stroma and especially in elongated or curved rows. These elements are arranged with their long axis verticle to the length of the strand of cells. He cited Haythorn and others

who considered that they are derived from the hair follicles and sebaceous gland epithelioma.

Liver cell carcinoma (malignant hepatoma). The specialized epithelial cells of the parenchyma of the liver often give rise to carcinomas. They are mostly seen in the dogs, cattle and sheep. In cattle and sheep hepatic carcinomas are comparatively common while cholangiocellular tumors are rare. The opposite is true in domestic carnivoras. They do not involve the reproductive tract. Other types of malignant epithelial neoplasms of the ovaries and the adrenal cortex are devoid of many of the qualifying characteristics possessed by the other carcinomas. They consist of very immature types of epithelial cells arranged in diffuse sheets or of closely packed masses of cells irregularly separated into indefinite units by variable amounts of fibrous connective tissue (see adrenal tumors).

Anaplasia are carcinomas originating at the same site and do not possess the identical cells and clinically do not have the same degree of malignancy. Feldman (1932) cited Broders who divided carcinomas into groups that are listed below.

Grade I includes carcinomas with  $\frac{1}{4}$  of the cells indiffer-entiated or immature in appearance and the remaining  $\frac{3}{4}$  of the cells with characteristics in common with the cells of normal tissue from which they arise. These are the least malignant.

In grade IV, none of the cells are differentiated or re-sembles the cells of the parent tissue. Many of the cells con-tain deeply stained nuclei, irregular mitotic figures and other

embryonic figures. These are most malignant.

Grades II and III have the intermediate positions.

Incidence in General. Hutchinson (Feldman, 1932) wrote---  
 "the most striking thing about cancer is its rarity in the lower animals, whether wild or domesticated." It is now however clearly indicated that it is rather common in lower animals.

Feldman (1932) evaluated various figures, and came to the conclusion that carcinomas probably occurred with greatest frequency in horses, dogs and cattle. Swine were occasionally affected. If the embryonal nephromas were excluded, swine would be more or less free from neoplastic diseases. This may be due to the fact that they are slaughtered at a comparatively early age in the United States. The same is true of sheep. Monpellier et al. (Cotchin, 1956) stated that cancer was seen particularly in ox, mare, bitch and rabbit, but it also occurs in other domestic species.

Sticker (Feldman, 1932) in his series found that the horses were most susceptible to cancer at or above seven to eight years while in dogs the age is from five to six years. In cattle the majority of carcinomas occurred after middle age. Feldman however observe malignancies as early as one year of age in cattle.

Monlux et al. (1956b) described 1002 tumors collected during the period 1953 and 1954 by the Animal Disease Research Laboratory at Denver from the food producing animals slaughtered. Amongst these 1002 tumors, 908, 66 and 28 tumors were amongst the 14,294,385 bovines (including 98,670 calves) 1,111,852 sheep and 982,700 hogs respectively.

Goldberg also reported another case in which a similar tumor was removed surgically before the metastasis had occurred. Fadyean's found one in the vulva and one involving the uterus amongst 5 cases of carcinoma. Udall et al. reported a case of carcinoma of the cervix of a 6 year old Holstein cow with metastasis to the lungs and mediastinal lymph nodes. Feldman found carcinomas involving the uterus, ovary, thyroid gland, gall bladder, vulva, kidney, thymus and skin in cattle. Feldman cited Schlegel who stated that carcinomas of the ovary of cows may be solid, cystic or papillary. Not infrequently these give rise to widespread metastasis throughout the abdominal cavity to the peritoneum, regional lymph nodes, liver, spleen and kidneys. Seldom is there more than superficial or subserous involvement of these structures. Guillebeau in 1899 (at Bone, Switzerland) observed 7 cases of which he believed five cases were carcinoma of the cervix.

Scholer (Feldman, 1932) examined 12,225 necropsy cases during a period of 2 years and found 2 tumors (columnar cell carcinomas) situated in the uterus. One had metastasized to both ovaries and the other had established secondary foci in one ovary, the kidney, and the liver. He also suggested that all of Guillebeau's cases were also adenocarcinomas of the uterus. Williams (1939) observed one cancer of the vagina in the cow. He also stated that carcinoma of the vulva should be differentiated from tuberculosis and actinomycosis.

Monius et al. (1956) cited that in 1951 a survey was conducted of all cases of neoplastic disease of food producing animals at the Animal Disease Research Laboratory at Denver Colorado. In dis-



tinctive tubular structures, such as neoplastic bile ducts and uriniferous tubules, suggested metastatic carcinoma. In this survey they had their primary site in uterus.

The occurrence of this type of tumor (adeno-carcinoma) in female animals only is essential supporting evidence for a diagnosis of probable uterine carcinoma.

Monlux et al. (1956) cited Sticker (Feldman, 1932) who in Berlin found in his series of 78 primary carcinomas in cattle, 46 (56%) were present in the urogenital tract. Of these 46, 10 were uterine carcinomas.

Monlux et al. (1956) cites the work of Carnat, who found carcinoma of uterus in the cow in 6 of 131 tumors at the Bern Veterinary Pathologic Institute from 1887 to 1918, and of Detroix, who found four epitheliomas of the uterus among 49 cattle tumors. He also mentioned Schutz and Johnes' observation on 78 bovine cases of carcinomas in which (56.4%) involved the urogenital tract. Monlux et al. (1956) suggested that adenocarcinomas of the uterus may rank only behind squamous cell carcinomas of the eye and its appendages and lymphoid tumors in causing economic loss to the cattle industry. Wyssmann (Cotchin, 1956), Sedlmeier, Karetta and Thieulin, as cited by Cotchin, 1956, described several cases of bovine uterine adenocarcinoma. Trotter, A.M. (1911) observed one case of adenocarcinoma of the uterus and four cases of carcinomas of the ovary amongst 300 cattle tumors.

Monlux et al. (1956) cited Ball and Boudet who reported an interesting case of uterine carcinoma in 1925. A six year old cow had been manually delivered of a normal calf. In three weeks the

cow was inappetant and constipated. Difficulty in urinating prompted an examination of the genital organs at the end of the fourth week. A large tumor was palpated in the uterus near the cervix as well as greatly enlarged pelvic and sublumbar lymph nodes. In a few more days the animal became dyspneic. Massive uterine hemorrhages into the peritoneal cavity were responsible for her death 40 days after the dystocia.

Ottosen (Monlux, et al. 1956) described one scirrhous adenocarcinoma of the uterus in 1941 and 14 cases in 1943. In eight of his cases metastases were found in the lungs. Lagerlof and Boyd (1953) found one scirrhous adenocarcinoma of uterus incidentally in the examination of 6,286 dairy cattle. Monlux et al. (1956) have classically described 26 adenocarcinomas of the uterus and five carcinomas involving other parts of the female tubular genital tract. These represented all examples of the primary adenocarcinoma of the tubular portion of the female genital tract diagnosed at the Denver Laboratory. In 5 of 26 adenocarcinomas of uterus the ovary was involved. Among the other five carcinomas four were squamous cell carcinomas. Two were involving the vulva, one was involving the vagina, and one was involving the cervix. The fifth had invaded the cervix. The ovary was not involved. Amongst the 26 adenocarcinomas of uterus 22 had metastasized to the lungs, 21 to lymph nodes and 14 to the peritoneum. The lesions tended to form a sclerotic annular constriction of the cervix with no perforation of the serosa and little or no extension onto the endometrium. The importance of the uterus as a site of primary origin for metastatic pulmonary and other cancerous

lesions was stressed. Williams (1939) reported that a 6-inch carcinoma of the ovary was removed by laparotomy from a Guernsey cow.

Lavis et al. (1933) observed six adeno-carcinomas amongst their total collection of 150 tumors. Amongst the 90 tumors of cattle, 5. (5.6%) were adenocarcinomas involving the ovary and 1 (2.9%) was found in the ovary of a ewe. None was noticed in swine. Plummer (1951) observed seven carcinomas amongst the 37 tumors of cattle. In one case there were two big tumor masses. The weight of each tumor was two lbs. There were a number of smaller ones about four cm. in diameter. One of these was attached to the uterus. In another case, one carcinoma was found practically buried in the musculature of the floor and walls of the pelvic cavity. Ball and Boudet (Cotchin, 1956) and Ball (Cotchin, 1956) reported that a tumor, which was examined 40 days after a normal calving, had metastasized to the pelvis and sub-lumbar lymph nodes and lungs. Karetta (Cotchin, 1956) found a scirrhous carcinoma of the uterus with secondaries in the local lymph nodes and in the lungs. Iyer (Cotchin, 1956) recorded two cases of uterine carcinoma in cows and Thieulin (Cotchin, 1956) one case. Paine (Cotchin, 1956) reported two cases of carcinoma of the vulva---both were typical squamous cell carcinomas. Both of these occurred at the same time on the same farm. Ingmire (Cotchin, 1956) found a squamous cell carcinoma of the left part of the vulva of a five year old cow. Dobberstein (Monlux, et al. 1956b) made a statistical evaluation of 1241 bovine tumors which had been reported by various investigators. He indicated that 37 of

these were involving the uterus. Nair and Sastry recorded 12 carcinomas involving the vulva and 3 the vagina. They stated that carcinomas of the uterus occur very rarely in India. Plummer (1948) reported one adenocarcinoma weighing 1½ lbs, of the ovary of an aged cow among 21 cattle tumors.

Feldman quoted Martel who mentioned that 38,000 horses were slaughtered in the abattoir of Paris. The majority of these were old, more than 15 years, and consisted of 2,000 mares, 16,200 gelding and 3,600 stallion. Animals (0.5%) affected with carcinomas were as follows: mare 80, gelding 43, and stallion 54. Metaplasia were not counted on account of the common occurrence. The ovary and uterus were affected in two and one cases respectively.

Kust (Feldman, 1932) studied tumors of the external genitalia of 195,239 mares examined at Berlin Polyclinic in a period of 22 years. Tumors of the vagina, clitoris and vulva were formed in 36 animals (0.019%). In the same period 4 among 20,220 animals (.018%) in Berlin surgical clinic had tumors of the external genitalia. Twenty one in this series of 36 were in the vagina and seven were carcinomas. Of 11 tumors of clitoris nine were carcinomas and two were sarcomas. Amongst the 4 vulva tumors, one was a carcinoma. Wintzer (Cotchin, 1956) reported that of 2,100 horses seen in the surgical clinic at Leipzig 44 had neoplasms. Amongst these 21 were carcinomas. Courteau (Cotchin, 1956) stated that material reviewed in Peyron's laboratory in Paris showed that neoplasms occur more frequently in horses than in cattle. This is contrary to Feldman's impression. The source

of origin of the specimens may have been responsible for this.

Sticker (Feldman, 1932) observed 11 carcinomas involving the vulva amongst 119 carcinomas of horses. In Sticker's series of 311 carcinomas of horses 18, 8, and 4 were cases of carcinomas involving the vagina, the uterus and the ovary respectively. Fadyean found one case of vulvar out of 26 tumors (cancers) of horses. Ball and Lombard (1926a) described a primary papilliferous carcinoma of the urinary bladder of a mare with secondary nodules in the uterus. A carcinoma of the uterus was reported by Eberlein (Feldman, 1932). Feldman mentioned that Kitt had reported primary carcinoma of the ovary with secondary foci on the serous surface of the liver and omentum. Runnels and Benbrook (1942) found one carcinoma of the clitoris and two in the vulva amongst the 54 squamous cell carcinomas of horses and mules. Cesari (Feldman, 1932) found 184 epithelial tumors amongst the 40,000 horses inspected at the abattoir at Decroix. He pointed out that the lesions were proportionally six times more frequent in stallions than in mares. Goffinet (Cotchin, 1956) commented that tumors of horses have less grave effects than do those in man. From Sticker's paper he said that in 10,000 horses of all ages 10 will have malignant tumors. Four or five of them will be carcinomas (epitheliomas) and five or six will be sarcomas. In one year in Brussels there were reported four cases of cancers of the head sinuses, three of the eye and one of the vulva. Also four foals were affected with osteo-sarcomas.

Dogs. It is stated that carcinomas occur more frequently in

dogs than in man. Sticker (Cotchin, 1956) compiled a series of 766 cases of carcinomas in 754 dogs.

The vagina, ovary, uterus and mammary gland were involved in 6, 3, 2 and 341 cases respectively. Schutz (Feldman, 1932) during a period of 14 years found carcinomas present in 69 (5.4%) of 1241 dogs examined on necropsy. Of these 26.6% were affecting the urogenital system. Feldman (1932) stated that primary carcinoma of the uterus and vagina is sometime seen, but it is extremely rare in the gastro intestinal tract. Williams (1939) observed one case of cancer of the uterus in an aged bitch. It carried a profuse fetid discharge. Stuzni (Cotchin, 1956) found 35 carcinomas on necropsy examination of 835 dogs. Collingnon (Cotchin, 1956) described an adenocarcinoma of uterine origin in a 12 year old bitch. Schlotthauer (1939) found a raised tumor approximately 3 cm. long involving the wall of the left uterine horn. The dog had a primary squamous cell carcinoma of the mammary gland. He found on necropsy examination a thread of cancer tissue 10-inches long from pylorus to the posterior portion of the rectum. All intestines were pushed together. The thread had cut through the wall of the intestine. The bitch had persistent vomiting and progressive emaciation during the last two weeks of life. Clinical examination and radiological studies failed to reveal the cause of illness and the patient died of generalized peritonitis. The left ovary had a small adenocarcinoma. In another case he encountered an adenocarcinoma of the right ovary. Cotchin (1954) found three carcinomas of the ovary amongst 14 ovarian tumors of the bitch. Mulligan (1949)

noticed 204 carcinomas amongst the 1000 tumors of dogs. Six of these were involving the uterus. One was in the vagina.

Cats. There are only a few reports pertaining to the occurrence of tumors in cats. None of these indicated involvement of the reproductive tract.

Sheep. Sheep appear to be relatively free of carcinogenic proliferations. Out of 500 tumors observed by Feldman in lower animals 41 were from sheep. Twenty five of these were carcinomas but none was affecting the genital tract. Davis et al. (1933) found 1 adeno-carcinoma of the ovary amongst a collection of 34 ovine tumors.

Hogs. Apparently carcinomas are rare in hogs. Williams (1939) observed 37 lb. cystadenoma in a 300 lb. sow. There was great distention of abdomen in this case.

#### SARCOMA

Collignon (Cotchin, 1956) saw a round cell sarcoma of the uterus in an 8 year old bitch. Lagneau (Cotchin, 1956) described a sarcoma in a seven year old bitch. It was a pedunculated oval tumor arising just in front of the cervix and appeared at the vulva. Kinsley observed 16 cases in three years in various tissues. He stated these are common and the most malignant of the entire group.

#### Alveolar Sarcoma

Kinsley reported that they occur occasionally in domestic animals especially in cattle and swine. The reproductive glands,

ovaries and testicles are the structures most frequently involved. He cited an alveolar sarcoma weighing about 15 kgms. and about 20 cm. in diameter in the ovary of a heifer. He stated that this variety may be differentiated from carcinoma. They grow slower, are usually encapsulated, have no tendency to metastasize and are mildly malignant.

Plummer (1951) noticed one spindle cell sarcoma amongst 37 bovine tumors. This tumor was involving practically the entire peritoneum and the dorsal serosa of the uterus.

Ball (Cotchin, 1956) reported a spindle cell carcinoma of the uterus of a mare. Henning (Cotchin, 1956) reported operative removal of the glans clitoridis and of the vulva respectively from two mares. Holterbach (Cotchin, 1956) saw a spindle cell sarcoma of the vulva of a cow.

Mast-cell Sarcoma. These occur chiefly in dogs and occasionally in cats. They are more common in females and occur most commonly on the thighs and external-genitalia.

Mulligan noticed 87 tumors in 78 dogs and 20% of these were on the vulva.

Mixed cell Sarcomas. Jackson (1936) reported 17 (2.9%) mixed cell sarcomas amongst 593 animal tumors. Amongst these 17 tumors he noticed that one was in the uterus of a cow while 4 or 5 were involving the ovaries of the birds.

Ovarioblastoma or Sarco-carcinoma. Goldberg (1920-21) reported this type tumor occurring in the ovary.



## Tumors of the Adrenal-gland

Karsner (Monlux, et al. 1956b) stated that adrenal gland tumors occur frequently in women. In the majority of cases hormonal phenomena were produced by adenomata which produce excessive secretion during childhood and adolescence. Monlux et al. (1956) did not notice any endocrine imbalance, but stated that if age corollary could be drawn to the tumors in man, one should be aware of possible excessive hormonal stimulation, if such a tumor is encountered in animals.

## TUMORS OF THE GENITAL TRACT

Involvement of the ovary or the oviduct with neoplasms usually stops ovulation with subsequent sterility. If the uterus is affected, the usefulness of the animal as a breeder is terminated. Monlux et al. (1956b) cited economic losses from bovine uterine carcinomas. They cause nonproductivity, debilitation, as well as death or condemnation in the abattoir. Simon and McNutt (1956) stated that tumors of the reproductive tract are rare and of little economic significance in the cattle industry. They observed that lymphoid tumors frequently affect the uterus.

According to the report of the U.S.F.A. (1954) epitheliomas and squamous cell carcinomas are the most common tumors of cattle; however in Wisconsin the tumor most commonly affecting general health seems to be lymphocytomas. Oberst (1957b) stated that this is also true in Kansas. According to the U.S.D.A. report a few bovine vaginal tumors examined appeared to be benign but

microscopically they were found to be malignant.

Some of the granulosa cell tumors of the ovary may produce oestrogen. The animal may show symptoms of nymphomania, relaxation of the pelvic ligaments and altered lactation. In a few cases pregnancy is erroneously diagnosed on rectal examination on account of an enlarged uterus and prominent middle uterine artery. Tumors ordinarily may be palpated; therefore they should be distinguished from infections, abscesses, tuberculosis and other diseases involving the reproductive organs. The majority of ovarian tumor cause no symptoms until they become greatly enlarged. Prominent clinical signs include a palpable mass, abdominal enlargement, ascities, gastrointestinal disturbance, pain and terminal cachexia. In malignant types symptoms are referable to the metastatic lesions.

#### Secondary Tumors.

Secondary tumors of the ovary are frequent in women but are rare in dogs and cats. In dogs they are usually metastatic from a mammary carcinoma and sarcoma. Often secondary deposits are confined to the corpus luteum. Malignant lymphocytomas, diffuse or nodular masses of lymphoid cells, are occasionally present in the medulla or hilus of the ovary and in the bursal fat.

Vaginal tumors, seldom cause infertility but may cause dystocia as do those of cervix if they are large enough. Most of the tumors are benign and pedunculated. Occasionally they may protrude through the vulva. Here surgical removal may be indicated.

Most of the pathological conditions of the reproductive tract are the result of trauma or infection or both. They occur most commonly at or after parturition and produce lesions that may interfere with fertility in cows. In spite of this we cannot forget the occasional presence of the tumors in that part of the body.

Sometime the tumors are in the bladder. Here a large sized polyp, steatomous growth or other mass may hinder parturition. Tumors can develop in connective tissue around the pelvic organs especially between vagina and rectum, however tumors closely associated with the anus are rarely a cause of difficult parturition.

It is not inappropriate to mention that at times early sexual maturity in immature or masculinization in the mature female are associated with tumors of the adrenal cortex.

Williams (1939) noted that malignant new growths of the genital organs were apparently less common than in man. It was his opinion that this might be erroneous since most of the animals are slaughtered before reaching an age conducive to the formation of cancer.

Cotchin (1956) mentioned that a variety of tumors have been recorded. The most common type was the granulosa cell tumor occurring particularly in horses, cattle and dogs. Epithelial tumors with the structure of an adenoma, (Grassnickel, 1940) or an adeno-carcinoma (Beumann, 1944, Stol, 1949, Monlux, 1956) or thecal cell tumors also occur. He further stated that the neoplasms of the female genitalia had been reviewed by Breuer and

Scholer, Ball and Lombard, Eyer, Ball, Collignon, Faure, Koning, Wilmes, Montpellier et al. and Wadsworth, all cited by Cotchin, 1956. The benign tumors are chiefly fibromas and leiomyomas. The malignant ones are carcinomas.

Mulligan (1949) reported that masculinizing tumors of the ovaries had so far not been reported.

Bloom (1954) stated that special tumors peculiar to the ovary have been noticed in animals. These include granulosa cell tumors, theca cell tumors, Brenner, and dysgerminomas. Other neoplasms are arrhenoblastomas, hypernephroid tumors, mesonephromas and those producing masculinizing effects. The latter are seen in human pathology, but have not been reported in the Veterinary medical literature. The term folliculoma is seldom applied to granulosa cell and theca cell tumors.

#### Granulosa Cell Tumors

It has been pointed out that granulosa cell tumors occur more commonly in women past the age of menopause. Occasionally they are seen in young children of four to seven years of age. In children they cause astonishing hyper-feminizing influence and produce precocious puberty. In elderly women the uterus increases in size and there is apparent establishment of menstrual function with endometrial hyperplasia. The production of estrogens by tumor cells thus disproves the older theory that neoplastic cells are purely paracitic and non-functional. The patient returns to normal eventually after removal of the primary tumor. Meyer, cited by Kingman and Davis (1940) stated that its origin is

apparently from normal ovaries and not from the granulosa of the adult follicle. In a serous cystoma the wall is thin, tough and fibrous and contains clear, colorless or brownish watery fluid. In granulosa cell tumors the cells are round or oval and resemble the granulosa cells of the ovary. In dogs the stroma is generally not conspicuous. When the stroma is luteinized, the term luteoma is sometime applied to the extensive transformation or leuteinization of granulosa cell and theca cell tumors. Leuteinization in a granulosa cell tumor occurs rarely in bitches.

The cells of these tumors usually produce estrogens and feminization. In dogs in about 75 percent of the cases there is abnormal uterine bleeding, disturbance of the estrous cycle, endometrial hyperplasia and sometimes metritis and pyometra.

#### Theca Cells Tumor (Thecoma)

These are rarely encountered, however they are comparatively more common in older dogs than in other species. These are firm, solid and pale yellow in color. Estrogen may be produced with feminizing effects but functional activity is generally lacking.

#### Cysts

Ovarian cysts are sometime described with the tumors. These are common and their frequency increases with age. Approximately 90% of all ovaries examined in older animals show cyst formation. Roberts (1956) stated that any cyst larger than a grapefruit (4") should be suspected as being a granulosa cell tumor. The weight and size of the large ovarian tumors tend to drag the ovary downward and forward into the abdominal cavity.

The ovarian artery to a large ovarian tumor is likely to be increased in diameter. Sometimes it is necessary to place forceps on the cervix and pull the uterus and ovary upward and backward in order to palpate the tumor. Roberts (1956) cited McEntee and Zepp who stated that in rare instances the tubules of reti ovarii may be confused with a neoplastic growth. The reti ovarii in a cow is a network arrangement of the tubules found near the mesovarium.

Follicular Cysts develop by cystic distention of mature follicles or atretic follicles. Clinical signs depend on whether or not they elaborate estrogenic substances. In cases where the granulosa cells are well preserved the fluid content is rich in estrogenic substance and the endometrium becomes hyperplastic. In some instances the animal exhibits nymphomania.

Cystadenomas, (Mulligan, 1949) are quite small. They are present in the same ovary with multiple follicular cysts.

Cystadenosarcomas may also occur in the ovary.

Germinal Inclusion cysts (Walthard cyst, Serosa cyst, Surface cyst.) are more common in bitches than in cats. They are most frequent in older animals. They originate from the germinal epithelium. In humans they are considered to have neoplastic potentialities and cystomas may develop from them clinically. They have no significance as there is no hormonal secretion.

According to Bloom (1954) carcus luteum cysts are rare. He noticed a peculiar solitary structure of small size surrounding a larger central cavity which contained eosinophilic albuminous fluid. Part of the cyst wall was lined with several layers of

intact granulosa cells. The remainder was lined by many layers of normal lutein cells. In most cases he found that the affected ovaries also contained normal mature corpora lutea in which there were central cavities.

Theca cell lutein cysts occur as multiple small cysts. In human pathology they are seen associated with hydatiform moles and chorioepitheliomas. Bloom (1954) stated that he had not observed them in dogs and cats and they are not mentioned by authors who describe hydatiform moles and chorioepitheliomas in animals.

Brenner tumors are benign and show no endocrine activity. They are white or yellowish in color. They are rare in dogs but may occur in old animals.

Dysgerminomas or seminomas are uncommon in animals. They may be unilateral or bilateral and they are potentially malignant. With them there is no endometrial function.

Teratomas. Teratomas are of two types. These are dermoid cysts, which are benign and solid teratomas, which are malignant. Williams (1939) stated that dermoid cysts of the ovaries or testicles are not rare in cattle but they are practically unknown in other species. It is stated that practically all teratomas described in dogs and cats are unilateral dermoid cysts. The cysts contain oily sebaceous material which becomes semisolid when cooled. Intermingled with this secretion are hairs. At other times there may be teeth, bone, cartilage and other substances.

Solid teratomas are usually very firm but they may contain small cystic spaces.

As a rule ovarian dermoid cysts are not clinically identified since no clinical signs are manifested. Generally the involvement of an ovary prevents function of that defective organ, but it is not known to interfere with the function of the opposite gland. It is possible that both gonads may be involved.

In human obstetrics Williams (1939) states that affected ovaries may become markedly pedunculated and may drop into the pelvic cavity during labor to cause dystocia. During the dystocia the dermoid cyst may be ruptured by the pressure of the fetal head. This causes the contents of hair and epitheloid debris to escape into the peritoneal cavity. This leads to fatal peritonitis. Such results are virtually impossible in domestic animals because of their quadrupedal position and the location of the ovaries. The enlarged ovary is more likely to lead to incarceration of the rectum. Such has been observed in pedunculated ovarian cysts.

Hydatid Cysts. Williams (1939) stated that sometimes the tubular remnants (Wolffian ducts) become distended with fluid to form which are known as hydatid cysts. After attaining a considerable size, they acquire a long pedicle. These hydatid cysts are quite common in women and rarely become so large that in upright position that they drop into the pelvis as in cases of dermoid cysts. They do not cause serious interference during labor. Such cysts are extremely rare in domestic animals.

#### Parovarian Tumors

Williams (1939) stated that parovarian tumors may cause severe obstruction and colic. In describing a case he reported



that he could pass his hand freely on rectal examination for about 18" to where the gut abruptly constricted to such an extent that only an index finger could pass through the lumen. Williams could not make a positive diagnosis at that time. The mare died a short time later. The necropsy examination revealed a large parovarian cyst with a long slender codiform pedicle. The cyst had fallen across the rectum from the right and had pushed the mesentry ahead of it. The long pedicle had then passed beneath the rectum and had dropped over the cyst which was covered by the mesentry. It was looped about in such a way as to form a half hitch. In a brief space of time this caused distention of the gut ahead of the constriction. This drew the loop tighter.

Richmond (1899) reported a pedunculated multi-lobular cyst in a mare. It was attached a few inches anterior to the ovary. The cyst weighed 150 lbs.

William (1939) stated that the most outstanding clinical expression of the presence of large ovarian or parovarian tumor is the sudden onset of violent pain like that of a strangulated hernia. Sometimes the patient recovers spontaneously from this with the probability of repetition. If incarceration is not overcome, early death may occur. Williams did not observe any case in cows but said that such was manifestly possible with a large ovarian cyst. He was of the opinion that rectal palpation should be performed in cases of severe abdominal pain. He further stressed that when there are recurrent colics in females, the possibility of ovarian or parovarian tumors should always be

considered. Radical surgical removal is a suggested treatment in such cases.

### Angiosarcoma

Williams (1939) cautioned against any attempt to rupture an angiosarcoma on account of two perils, hemorrhage from the large ovarian artery and emptying of malignant tissue in the peritoneal cavity. Liberal incision and proper ligation of all arteries are suggested precautions if removal is considered.

Chorioepitheliomas are rarely seen and are malignant.

Bloom (1954) reported 3 cases in dogs. Chorioepitheliomas have also been described by Riser (1942)

Cattle. Lagerlof and Boyd (1953) examined a total of 6,286 organs of cows of the Swedish Highlander breed from slaughter houses of four counties. All of the tumors observed were sent to the pathology department of Royal Veterinary College in Stockholm for histopathological examination. In some cases the material was not suitable for this examination because of post mortem decomposition. The tumors encountered are listed in Table 6.

Table 6. Tumors of the ovary and uterus

Uterine		Ovarian	
Leiomyoma	15	Carcinoma	3
Fibromyoma	12	Granulosa cell tumor	2
Fibrosarcoma	7	Small cystic granulosa cell tumor	1
Schirrous adeno-carcinoma	1	Sarcoma	1
Lymphosarcoma	1	Fibrosarcoma	1
Spindle cell sarcoma	1	Undiagnosed	5
Undiagnosed	7	Total	13
Total	44		

McEntee (1950) reported on 28 fibropapillomas from the vulva and vagina and 27 from the penis. He concluded that fibropapillomas are transmissible tumors of the external genital organs of cattle. They usually occur in young animals on the same premises and eventually undergo spontaneous regression. He suggested that these were similar to or the same as the common warts or papillomas on the body of young cattle, which are caused by a virus.

The occurrence of cystic ovarian degeneration including the affected ovary and the incidence in all the four counties reported by Lagerlof and Boyd (1953) is recorded below.

Table 7. Incidence of Cystic Ovarian Degeneration

Organs examined	Right		Left		Both		Total	
	No.	%	No.	%	No.	%	No.	%
Total	6,286							
	380	6.0	202	3.2	346	5.5	928	14.8

Perkins et al. (1954) studied 1000 bovine genitalia and their findings are given in Table 8 as follows.

Table 8. Tumors of the Genital Organs

Tumors	% in 1000	% of 554 cows	% in 444 heifers
cystic ovaries	2.2%	3.06%	1.125%
cystic vulva	3.1%	5.9%	0.225%
cervical cyst	0.2%	0.36%	0.000%
vaginal cyst	0.7%	1.08%	0.25%

Roberts (1952) reported on a granulosa cell tumor weighing 1080 grams and measuring 23 cm. by 14 cm. by 9 cm. from a 15 year old pure breed Guernsey heifer. Light amber colored fluid was found in cysts but it was not found to contain estrogen in repeated injections into spayed female rats. There was relaxation of the sacrosciatic ligament, elevation of the tail head and edema of the vulva. The heifer frequently showed signs of estrum for 4-5 days which indicated that some estrogenic substance was

being produced. The mammary gland was enlarged. He further stated that the records of the Pathology Department of the New York State Veterinary College showed that 17 cases of granulosa cell tumors of the ovary had been diagnosed during a 22 year period.

Roberts (1953) cited Fincher who found in one case the left ovary contained a single large cyst 14-inches in diameter. It was filled with bloody fluid and was diagnosed as a cystic granulosa cell tumor. The cow did not show the symptoms as already stated.

Harvey et al. (Cotchin, 1956) Dacorso (Roberts, 1953) Goldberg (1920-21) and Trotter, A.M. (1911) have described cases of granulosa cell tumors of ovaries of cows. Wilson (1945) described this tumor in a six month old Frierian heifer that showed marked mammary development with lactation. Kingman and Davis (1940) and Langhan and Clark (1945) have each described symptoms of nymphomania in cows. One was an eight year old Hereford cow and the other was a 2 year old Holstein heifer. Each had a granulosa cell tumor of one ovary.

Williams (1945) observed three ovarian tumors which had the general appearance of malignancy. He observed an angiosarcoma of the ovary in an infertile Holstein Friesian. One ovary was 4-inches in diameter. His colleague diagnosed it as an abscess, but Williams thought it was a cyst. Both were wrong. This is not surprising since the condition is extremely rare. William stated that if they had paid due heed to the greatly enlarged uterine artery the diagnosis would have been correct.

Cotchin (1956) cited Chabasse (1954) who reported a seminoma (dysgerminoma) of the left ovary of an eight year old cow.

Dacorso (Roberts, 1953) described one arrhenoblastoma of the ovary of a cow. McEntee and Zepp (1953) described 18 bovine ovarian neoplasms. Out of these 18 tumors 17 were of the granulosa cell type. They were able to study the histories of 10 cases. Three of these had symptoms of nymphomania while one had mucometra and cystic endometritis. The cow, a 2½ year old Guernsey, was bred once following expulsion of a mummified fetus but after that she did not show signs of estrum for 6 months. In describing three cases in Guernsey cows from one particular herd, they emphasized that the cow was one of a large family of cows which was known for its high degree of fertility and long life. Three of the 17 granulosa cell tumors were bilateral. One was malignant. The latter was in a two year old Holstein cow with the right ovary measuring 75 cm. in diameter while the left measured only 30 cm. It had metastasized to the regional lymph nodes, uterus, omentum and kidney. The cow was constipated for one week. This was followed by tympany and death. In another case, a 13 year old Guernsey cow, there were bilateral microscopic tumors. She was bred two times and was then destroyed as she had a perimetrial abscess. The 18th tumor (weighing 20 pounds) was from a two year old Holstein heifer. It was malignant and involved the left ovary. The heifer had three normal estrual cycles and was bred. She did not show the symptoms of estrum later.

Weyel (Cotchin, 1956) examined three cases of granulosa cell

tumors from abattoir cattle; the amount of follicular fluid was between 50-100 times the normal amount.

Harvey et al. (Cotchin, 1956) reported four granulosa cell tumors in calves. One was 15 by 10 cm. in size and was from the wall of a large ovarian cyst. In another case he found a bosselated unilateral ovarian tumor. It was 20 by 15 by 15 cm. in size and weighed about 15 pounds. It was strikingly yellow and solid with pin head sized cysts throughout. The uterus of this calf showed glandular and muscular hyperplasia. Another tumor weighed 10 pounds and was yellowish in color with hemorrhagic areas and a soft consistency. Large cysts contained a clear fluid. The uterine mucosa was hypertrophied.

Kingman and Davis (1940) reported a 10 year old cow with a granulosa cell tumor of the left ovary. There was endometrial hyperplasia. The cow had been constantly in estrum, would accept service at any time, and had a badly deformed croup. Langhan and Clark (1945) also described symptoms of nymphomania in a two year old Friesian heifer with a granulosa cell tumor of the right ovary. There was elevation of the tail head, constant bellowing, lowered tone of the voice, and mounting of other cows. Call-exner bodies were present in some follicle-like structures.

Langhan and Clark (1945) cited the following case report. A two year old Holstein heifer was diagnosed as being pregnant by a lay operator. She showed symptoms of nymphomania with elevation of the tail head, constant bellowing, lowered tone of the voice and mounting other cows. Slaughter and subsequent examination revealed a normal cervix, uterine horns and right oviduct. The

right ovary was 18 by 14 by 8 cm. in size, ovoid in shape and with increased blood supply. The cut surface was soft and lobulated.

Dacorso (Roberts, 1953) reported that in an eight year old cow, on routine post-mortem examination, there was a granulosa cell tumor measuring 17 by 13 by 10 cm. Boucher (1954) reported a case of a virgin 2 year old Ayrshire heifer. She had nymphomania and on rectal examination revealed a right ovary about 1½-inches in diameter. It was also firm in consistency. Six weeks later the ovary was 2½-inches in diameter. It was erroneously diagnosed as a cystic ovary. 10,000 units of choricnic gonadotrophin were given by intramuscular injection. The heifer again showed signs of estrum after 12 days. At this time the ovary was about 2-inches in diameter. Neoplasia was suspected and the right ovary was removed. Normal estrum occurred after a few false estrual periods.

Goldberg (1920-21) found two cases of granulosa cell carcinoma in cows amongst 13 tumors encountered by him in domestic animals. One was found in a two year old Holstein heifer. The right ovary was enlarged, 15 by 12 by 12 cm. in measurement. Its surface was smooth except at one point where it had ruptured. The left ovary was markedly hypoplastic. Metastasis had occurred to the peritoneum, mammary gland and the inguinal lymph glands. The other case was in a 10 year old cow. A diagnosis of abscessation of the broad ligament of about 6 months duration was made. On removal it was found that the right ovary was irregularly spherical and weighed 530 gms. It was a granulosa cell carcinoma.

Roberts (1953) mentioned an interesting case in a heifer. She showed signs of ovarian dysfunction with constant estrum and acceptance of the bull at any time. The croup and the tail head were badly deformed due to sunken sacrosciatic ligaments and high sacrum. There was no thickening of neck muscles or change of voice. The cow was examined for pregnancy later and a large hard object was palpated in the abdominal cavity. The uterine wall was thin and lacking in tone. The cervix was hard and open. The uterine arteries were enlarged. A diagnosis of pregnancy was made. The animal suddenly became lame and bony crepitus was easily discernible. On post-mortem examination a large ovoid, smooth, lobulated tumor (23½ pounds) was found involving the left ovary. The lobules were beneath the serous coat and measured between 1 and 2-inches in diameter. The cut surface was greyish, quite solid and granular with several rather large soft areas containing a thin light brown exudate. This was a benign growth, but more frequently they are malignant. Fracture of both ilia resulted eventually from the ovarian dysfunction.

Sheep and Goats. Feldman stated that tumors in goats were extremely rare. Roberts (1956) cited the 1954 report of Department of Agriculture of New Zealand where it was reported that a group of 25 ewes were mated a third season after 2 consecutive seasons of failure to conceive. Eleven lambed after only one service. Five apparently conceived but later post mortem examination showed that there was some interruption of pregnancy before term. Eight were bred several times but failed to conceive. On post mortem examination six of these sterile ewes had occluded



or cystic Fallopian tubes, and one ewe had a mummified fetus. Casarosa (Cotchin, 1956) described granulosa cell tumor in sheep.

Sow. Tumors of the genital tract are rare. Feldman reported leiomyomas and a fibroma of the uterus and one lymphoblastoma of one ovary.

Mare. Tumors of the genital tract in mares are rare and they may produce hormonal effects. Dimock and Edward (Roberts, 1956) reported six true tumors amongst 2000 mares. Of these, three were of the ovary, two were in the uterus. One benign fibrosarcoma was in the vagina. William (1939) described a dermoid cyst in the ovary and a fibroma of the uterus of a mare.

Benesch (Cotchin, 1956) described a granulosa cell tumor weighing 19.5 kg. of the left ovary of a 12 year old mare. Berthelon et al. (Cotchin, 1956) saw a granulosa cell tumor associated with chronic hyperplastic endometritis. The mare was showing persistent estrum. Williams (1939) observed a hydatid cyst (20 cm.) of an ovary of a mare on rectal examination. It was removed and recovery was uneventful.

Howard (1949) found an ovarian tumor measuring 14 by 15 by 18 cm.. Its external surface was smooth and covered with serous membrane. This was encountered in a 7 year old Thoroughbred mare which was bred in England and was later declared to be pregnant. On arrival in the United States the mare was found to be barren. Still later it was found that the left ovary had a growth on it. The animal died in an accident during the same year. The classification of the tumor mass in the ovary was not reported.

Dogs and Cats. Tumors are common in dogs but rare in cats. McEntee and Zepp (1953) described the ovarian tumors of dogs. They found 8 granulosa cell tumors amongst 19 ovarian tumors and stated that granulosa cell tumors were the most common neoplasms of dogs' ovaries. Most of the bitches thus affected had a cystic hyperplastic endometritis with varying amounts of uterine mucus, advanced metritis, and pyometra. The largest tumor measured 11 by 9 by 5 cm. and weighed 213 gms.

They further described six papillary cystadenocarcinomas and noticed pronounced ascities in two of these cases. Marked cystic endometrial hyperplasia with a bloody tinged vaginal discharge and irregular estrual cycles were also commonly observed. The largest ovary in that group measured seven by six by four cm. Peritoneal metastasis occurred in five cases and lung involvement was seen in two cases.

Other canine ovarian tumors described by them were luteomas, theca cell tumors, dysgerminomas and fibroadenomas. In one case dysgerminomas were involving both ovaries. They were associated with vaginal fibroids and a mammary gland adenoma. In another case a dysgerminoma was involving the right ovary. The bitch also had a leiomyoma of the uterus which caused a persistent bloody vaginal discharge.

Feldman (1932) and Bloom (1954) mentioned a carcinoma and a cystadenoma in cats.

Cotchin (1956) reported 266 tumors of female genital system amongst 1152 tumors of dogs. Two hundred twenty two of these

were in the mammary gland, 26 were in the vagina, 14 in the ovary and 1 was in the uterus and mesovarium. Mulligan (Cotchin 1956) noticed 1 adamantinoma, 1 ceruminous gland cyst and 4 epidermal inclusion cysts amongst 70 cat tumors. Drieux and Thiery (Cotchin, 1956) saw a hydatiform mole in a cat.

Cotchin (1954) found granulosa cell tumors amongst the 14 ovarian tumors of bitches. Roberts (1956) suggested that leiomyomas of the uterus in old dogs were quite common. Feldman (1932) and Bloom (1954) described fibromyomas, adenomyomas, carcinomas, lipomas, sarcomas and lipofibromyomas of the canine uterus.

Riser (1940) described a chorioepithelioma of the uterus. The bitch suffered from persistent bloody discharge for 30 days after whelping. Roberts stated that small benign tumors cause no trouble but large ones may cause hydrometra, pyometra, digestive or urinary disturbances, abdominal enlargement, uterine bleeding, dullness and emesis.

Cotchin (1956) cited Oakley who showed at a meeting reconstruction of slices of a teratoma of the ovary of a young bitch. Storm (1947) observed a teratoma in the ovary of an 8 year old Collie bitch through a period of three years. The bitch had shown progressive personality changes and timidity with occasional aggressiveness. The bitch suffered from periodic attacks of eczema around the eyes, mouth, anus and vulva. This was associated with estrum which was very irregular. The left ovary, 15 by 10 by 8 cm. in size, weighed 590 gm. and contained many cysts filled with sebaceous material. Hair was found growing

on the epithelial lining of the mammary gland. Most of the tumorous elements were ectodermal derivatives but mesodermal and endodermal tissue was also found. Benesch (Cotchin, 1956) reported a dermoid cyst with hair weighing  $2\frac{1}{2}$  kg. in the left ovary of an 18 months old Alsatian bitch. Cotchin (1956) also reported a teratoma in a collie bitch. Feldman (1932) describe a leiomyoma and a cystic fibromyoma of the uterus in bitches and metastatic lymphoblastomas of the uterus in cats.

Bloom (1954) mentioned that tumors of the cervix, vagina and vulva include leiomyomas, fibromas, neurofibromas and lipomas in order of decreasing frequency. Malignant tumors were rare. Carcinomas and sarcomas of the vagina were described by Feldman and Bloom.

Ovariohysterectomy is the treatment of choice in ovarian and uterine tumors. The prognosis is guarded when the tumors are associated with other diseases such as pyometra. Surgical removal is preferred when there is involvement of the vulva or vagina. Some have reported successful X-ray therapy, but its value is not yet definitely established since many tumors regress spontaneously.

#### Infectious or Transmissible Lymphosarcoma

(Histiosarcoma or Transmissible Venereal tumors). Venereal granulomas are composed of lymphoid cells with predilection for the genital organs of dogs. They are readily transmitted by coitus. They are slightly malignant and commonly affect the vagina of the female. Mulligan (1949) reported 10% of his cases involved the genital organs and 60% involved the head, ears, and fore limbs.

Bloom (1932) reported that the incidence of this kind has declined, and he did not agree with Mulligan and others who claimed that this tumor occurred on the skin of the fore-quarters and in the region of the base of heart. Beebe and Ewing (Feldman, 1932) stated that isolated tumors may occur anywhere in the body. When spreading to the surrounding tissues and lymph glands occurs, there is a bloody, purulent, fetid discharge usually from vagina. The tumors may protrude through the vulvar lips. There may be ulceration. Dysuria is seen when obstruction to the urinary meatus occurs. Feldman (1929) found seven (8.6%) amongst the 81 neoplasms examined by him. Beebe and Ewing (Feldman, 1932) secured numerous cases in kennels in New York for study.

Chorionepithelioma or Endometria. Riser (1940) stated that these are malignant tumors of the uterus.

Cotchin (1956) reported that hyperplasia of the endometrial glands may produce some strange things macroscopically and histologically. He indicated that a diagnosis of chorionepithelioma or endometria must be accepted with reserve.

Ball (Cotchin, 1956) stated that he had seen a chorionepithelioma in the uterus of a seven year old slaughter cow. She delivered about a year earlier and after that she had many infertile services. There had been a mucopurulent discharge for six months. A tumor weighing 8 kg. was found in uterine body and the cornua. The uterus was smooth, grey and firm. Histologically the tumor showed large clear cells (Laughan cells) and syncytia. It was suggested that it originated from placental debris.

Laszlo (Cotchin, 1956) describes endometrosis on the external

surface of the uterus and vagina of the cow.

Letulle and Petit (Cotchin, 1956) were said by Collignon to have seen two cases of uterine endometrioma. Schlotthaver (1939) on spaying a two year old cocker spanial bitch saw a chorion-epithelioma of the uterus. He stated that only one case had been reported in the American Veterinary Literature over a period of 25 years. Riser (1940) described a case in which three distinct tumor masses occurred in the uterus of a seven year old Boston terrier. The bitch had whelped three normal puppies 30 days previously, and since then had had a hemorrhagic vaginal discharge. There was no temperature but the mucous membranes were pale. Three growths, one in each cornua and one at the bifurcation, appeared as masses of firm dull-red tissue. Death occurred during surgery. Histologically the tumors showed disorderly arrangement of cells typical of chorionic tissue held together by areas of extensive hemorrhagic extravasations and areas of necrotic tissue.

Riser (1942) reported of a boston terrier bitch who gave birth to six normal puppies. After five days she had continuous vaginal bleeding, but her health and appetite were good and her temperature was normal. The vaginal flow was odorless. Through a laparotomy incision the uterus was found to be large, distended and firm with three enlargements, chorioepitheliomas of syncytial type. Mucoscoscopically, syncytical cells were invading the myometrium. There were very few pavement-like Laughan cells.

### Choriohemangioma

Karlson and Kelly (1941) found a lobulated mass measuring 6 by 3 by 3 cms. attached to the fetal surface of the allantois-chorion in a 2 year old Holstein Friesian heifer. It consisted of capillaries in a loose fibrillar stroma and was called a "choriohemangioma". It was found when the heifer gave birth to a healthy male calf. The parturition was normal and the fetal membranes were expelled normally soon after parturition.

### Embryonal Nephroma

It has not been recorded to affect the female genital tract.

## SUMMARY

No animal whether domestic or wild is immune to tumors.

Only a few cases are recorded as food producing animals. Cattle, sheep and swine, are usually slaughtered before the so-called "cancer age". A lack of interest amongst the Veterinarians and the public at large accounts for part of this. However, the presence of tumors especially in Dairy cattle, dogs and horses can not in any case be ignored.

Incidence of the various types of the neoplasms in the female genital tract has been discussed. A good many varieties of tumors occur in the ovary. The most common and important is the granular cell tumor seen particularly in the cow, mare and bitch. These may secrete estrogen and hence cause nymphomania in the cow or the mare and pseudopregnancy and abnormal cycles in the bitch. Usually the ovarian tumors are unilateral and have great practical significance.

Adenoma, adeno-carcinoma or thecal cell tumors also occur in the ovary. Sometimes cysts, follicular, lutein, germinal inclusion, as well as parovarian cysts are described with ovarian tumors.

As regards the uterus, vagina and vulva, it may be said that fibromas and leiomyomas (benign type) and carcinoma (adeno-carcinoma) and lymphocytoma (malignant type) are the usual ones. Tumors of this part of the tract whether benign or malignant depending upon the size and site, may prevent conception, cause abortion or predispose dystocia. They may also cause dysuria,



periodic constipation or posterior paraesis and paralysis. Sometimes, pregnancy is erroneously diagnosed because one fails to consider the possibility of the presence of neoplasms. The malignant forms, adeno-carcinoma or lympho-cytoma, may cause early death. It may however be stated that lymphocytoma occurs more commonly in the Midwest and in Wisconsin than in any other part of the United States.

Certain cancerous growths seem to be more important than others in a given section of the world. In another area others may assume greater importance. A good example of this is cancer of the horn. This is very common in India but is seldom seen in the United States.

## ACKNOWLEDGEMENTS

The author is deeply obliged to Dr. F.H. Oberst for his constant help, advice, guidance, encouragement and generousness. He is also thankful for the counsel and assistance of Drs. M.J. Twiehaus and L.M. Roderick. His thanks are also due to Dr. E.H. Coles who was kind enough to take the photographs included in this report.

## BIBLIOGRAPHY

- Age incidence in cancer.  
Vet. Rec., 18: 164-165. 1905-1906.
- Bloom, F.  
Pathology of the Dog and Cat. Amer. Vet. Publications,  
Inc. Evanston, Ill. 1954.
- Boucher, W. B.  
Granulosa-cell tumor in the ovary of a heifer. Vet. Ent.  
Quart. Univ. Pa. No. 133, PP. 73-76. 1954.
- Cotchin, E.  
Further observations on neoplasms in dogs, with particular  
reference to site of origin and malignancy. I. Cutaneous,  
female genital and alimentary systems. II. Male genital,  
skeletal, lymphatic and other systems. Brit. Vet. J. 110  
218-230 & 274-286. 1954.
- Cotchin, E.  
Neoplasms of the Domesticated Mammals (A review ) Review  
Series No. 4 of the Commonwealth Bureau of Animal Health,  
Commonwealth Agricultural Bureaus, Farnham Royal Bucks,  
England. 1956.
- Davis, C. L., R. B. Leeper and Shelton, J. E.  
Neoplasms encountered in Federally inspected establishments  
in Denver, Colorado. J. Amer. Vet. Med. Ass. 83: 229-237  
1933.
- Edgson, F. A.  
Bovine lipomatosis. Vet. Rec. 64: 449-454. 1952.
- Ewing, James.  
Neoplastic diseases Ed. 4. Philadelphia, W. B. Saunders  
Co., P 1-8. 1942.
- Feldman, W. H.  
A study of the tumor in the lower animals. Amer. J.  
Path. 2: 545-556. 1926.
- Feldman, W. H.  
So called infectious sarcoma of the dog in an unusual  
anatomic situation. Am. Jour. Path. 5: 183-194. (March),  
1929.
- Feldman, W. H.  
A report of forty tumors of sheep (*ovis ories*, Jordan)  
American J. Cancer. 15: 2044-2062. 1931. (original not  
seen).

- Feldman, W. H.  
Neoplasms of domesticated animals. Mayo Clin. Monogr.  
Philadelphia. W. B. Saunders Company. 1932.
- Franklin, R. D.  
A malignant Vaginal Neoplasm in a cow cured by Stilboestrol  
Implanation. Vet. Rec. 58: 171. 1946.
- Goldberg, S. A.  
The occurrence of epithelial tumors in the domesticated  
animals. J. Amer. Vet. Med. Ass. 58: 47-63. 1920-1921.
- Hewetson, R. W. and P. D. Carter.  
An unusual neoplasm in the uterus of a cow. Aust. Vet.  
J. 31: 80. 1955.
- Hopkirk, A. S. M.  
Tumor from uterus of cow. Aust. Vet. J. 2: 69. 1926.
- Howard, F. A.  
Granulosa cell tumor of the equine ovary--a case report. J.  
Amer. Vet. Med. Ass. 114: 134-135. 1949.
- Jackson, C.  
The incidence and pathology of tumors of domesticated animals  
in South Africa. A study of the Onderstepoort collection of  
neoplasms with special reference to their histopathology.  
Onderstepoort. J. Vet. Sci. 6: 3-460. 1936.
- Karlson, A. G. and M. D. Kelly.  
Choriohemangioma of the bovine allantoischorion. J. Amer.  
Vet. Med. Ass. 99: 133-134. 1941.
- Kenny, J. E.  
Some observations on bovine neoplasia. Vet. Rec. 56: 69-  
72. 1944.
- Kingman, H. E. and C. L. Davis.  
Granulosa-cell tumor of the ovary in a bovine associated  
with secondary sex changes. N. Amer. Vet. 21: 42-46. 1940.
- Kinsley, A. T.  
A text-book of Veterinary Pathology. Ed. 3. Chicago, A.  
Eger. 1917.
- Knight, G. E. and S. W. Douglas.  
The incidence of cancer in dogs. Vet. Rec. 55: 195-196.  
1943.

Lagerlof, N. and H. Boyd

Ovarian hypoplasia and other abnormal conditions in sexual organs of cattle in the Swedish Highland breed: Result of P.M. examination of over 6000 cows. Cor. Vet. 43: 1, 64. 1953.

Langham, R. F. and C. F. Clark.

Granulosa cell tumor of a bovine ovary. Amer. J. Vet. Res. 6: 81-83. 1945.

Lombard, C. M. and L. S. Lombard.

Urbain Leblanc, Early Veterinary Pioneer in Cancer Research. J.A.V.M.A. 126: 363-365. 1955.

Mallory, F. B.

The principles of pathologic histology, Philadelphia, W. B. Saunders Co., 1914. P. 371; Recent progress in the microscopic anatomy and differentiation of cancer. Jour. Am. Med. Ass'n. 55: 1513-1516. (Oct. 29), 1910.

McClelland, R. B.

Neoplasms in dogs. Cornell Vet. 30: 161-166. 1940.

McIntee, K.

Fibropapillomas of the ext. genitalia of cattle. Cor. Vet. 40. 3, 304. 1950.

McEntee, K. and C. P. Zepp, Jr.

Canine and Bovine ovarian tumors, Proc. First World Congress on Fert. and Steril. 4, 2, 128. 1953.

Monlux, A. W., W. A. Anderson, C. L. Davis and S. W. Monlux.

Adeno-carcinoma of the uterus of the cow-differentiation of its pulmonary metastases from primary lung tumors. Amer. J. Vet. Res. 17: 45-73. 1956. (a).

Monlux, A. W., W. A. Anderson and C. L. Davis.

A survey of tumors occurring in cattle, sheep and swine. Jour. of Veterinary Research, Vol. 17, No. 65, pp. 646-677. Oct, 1956. (b).

Morris, J. M.

Emergency slaughter and malignant neoplasia (bovine) Vet. Rec. 56: 119-121. 1944.

Mulligan.

Neoplasms of the dog. Baltimore: Williams and Wilkins Co. 1949.

- Nair Chandrasekharan, K. P. and A. Ganti Sastry.  
A survey of animal neoplasms in the madras state, I. Bovine.  
Indian Vet. J. 30: 321-333. 1954.
- Oberst, F. H.  
Commented while giving the 1st lecture on Veterinary  
obstetrics and genital diseases. 1957. (a).
- Oberst, F. H.  
Personal communication. 1957. (b).
- Ferkins, J. R., D. Old and Seath.  
A study of 1000 bovine genitalia. J. Dairy Sci. 37: 1158-  
1163. 1954.
- Flummer, P. J. G.  
A survey of twenty four tumors collected from animals  
slaughtered for food. Can. J. Comp. Med. 12: 7: 180. 1948.
- Flummer, P. J. G.  
A survey of sixty-four tumors from domesticated animals.  
Can. J. Comp. Med. 15: 10: Oct. p. 231-252. 1951.
- Pritchett, H. D.  
Multiple vaginal papilloma in a calf. Canad. J. Comp. Med.  
5: 89-90. 1941.
- Richmond, F. O.  
Large Abdominal cyst in a mare. Am. Vet. Rev. Vol. xxii, p.  
770. 1899.
- Riser, V. H.  
Chorioepithelioma of the uterus of a dog. J. Amer. Vet. Med.  
Ass. 96: 271-272. 1940.
- Riser, V. H.  
Chorioepithelioma of the bitch. J.A.V.M.A. 65: 1942.
- Roberts, S. J.  
An ovarian tumor in a heifer. Cornell Vet. 43: 531-536. 1953.
- Runnells, R. A. and E. A. Benbrook.  
Connective tissue tumors of horses and mules. Amer. J. Vet.  
Res. 2: 427-429. 1941.
- Runnells, R. A. and E. A. Benbrook.  
Epithelial tumors of horses. Amer. J. Vet. Res. 3: 176-179.  
1942.

- Schlotthauer, C. F.  
Primary neoplasms in the genito-urinary system of dogs: a report of ten cases. J. Amer. Vet. Med. Ass. 95: 181-186 1939.
- Simon, Joseph and S.H. McNutt.  
Three tumors of the bovine uterus. J.A.V.M.A. Nov 5: pp. 475-477. 1956.
- Steiner, P. E. and J. S. Bengston.  
Research and economic aspects of tumors in food producing animals. Cancer, N. Y. 4: 1113-1124. 1951.
- Steiner, E. Paul.  
An evaluation of the cancer problem. Cancer Res. Vol. 12. No. 7. pp. 445-464. 1952.
- Storm, R. E.  
Dermoid cyst of the ovary. N. Amer. Vet. 28: 30-31. 1947.
- Thompson, W. W. and L. M. Roderick.  
The relation of leucemia and bovine lymphocytoma. Amer. J. Vet. Res. 3: 159-165. 1942.
- Trotter, A. M.  
Malignant diseases in Bovines. Jour. Comp. Path. and Therap., 24: 1-20. 1911.
- Udall, D. H., J. G. Fincher and E. R. Cushing.  
Cancer of the cervix in a cow. Cornell Vet. 16: 230-231, July, 1926.
- U.S.F.A. Meat Inspection Branch.  
A.R.S. Summary of Activities for the fiscal year. 1954. (original not seen).
- Wadsworth, J. R.  
The distribution of genital tumors in the bovine. Vet. Ext. quart. Univ. Pa. No. 128, pp. 133-137. 1952.
- Willett, E. L.  
Developments in the physiology of reproduction of dairy cattle and artificial insemination. Journal of Dairy Science, Golden Jubilee issue 1906, June 1956.
- Williams, W. L.  
Diseases of the genital organs of Animals. 2nd Ed. 1939.

A STUDY OF INCIDENCE OF THE NEOPLASMS  
WITH PARTICULAR REFERENCE TO  
THE FEMALE GENITAL TRACT OF ANIMALS

by

OM PARKASH MALHOTRA

B.V.Sc. University of East Punjab, Solan, India, 1949

---

AN ABSTRACT OF A MASTER'S REPORT

submitted in partial fulfillment of the

requirements for the degree

MASTER OF SCIENCE

Department of Surgery and Medicine

KANSAS STATE COLLEGE  
OF AGRICULTURE AND APPLIED SCIENCE

1957



No animal whether domestic or wild is immune to tumors. Only a few cases are recorded as food producing animals. Cattle, sheep and swine, are usually slaughtered before the so-called "cancer age". A lack of interest amongst the Veterinarians and the public at large accounts for part of this. However, the presence of tumors especially in Dairy cattle, dogs and horses can not in any case be ignored.

Incidence of the various types of the neoplasms in the female genital tract has been discussed. A good many varieties of tumors occur in the ovary. The most common and important is the granular cell tumor seen particularly in the cow, mare and bitch. These may secrete estrogen and hence cause nymphomania in the cow or the mare and pseudopregnancy and abnormal cycles in the bitch. Usually the ovarian tumors are unilateral and have great practical significance.

Adenoma, adeno-carcinoma or thecal cell tumors also occur in the ovary. Sometimes cysts, follicular, lutein, germinal inclusion, as well as parovarian cysts are described with ovarian tumors.

As regards the uterus, vagina and vulva, it may be said that fibromas and leiomyomas (benign type) and carcinoma (adeno-carcinoma) and lymphocytoma (malignant type) are the usual ones. Tumors of this part of the tract whether benign or malignant depending upon the size and site, may prevent conception, cause abortion or predispose dystocia. They may also cause dysuria, periodic constipation or posterior paraesis and paralysis.

Sometimes, pregnancy is erroneously diagnosed because one fails to consider the possibility of the presence of neoplasms. The malignant forms, adeno-carcinoma or lympho-cytoma, may cause early death. It may however be stated that lymphocytoma occurs more commonly in the Midwest and in Wisconsin than in any other part of the United States.

Certain cancerous growths seem to be more important than others in a given section of the world. In another area others may assume greater importance. A good example of this is cancer of the horn. This is very common in India but is seldom seen in the United States.