

## **FUSOBACTERIUM NECROPHORUM IN RUMINAL CONTENTS AND ON THE RUMINAL WALL OF CATTLE**

*K. R. Bedwell, N. Wallace, and T. G. Nagaraja*

---

### **Summary**

*Fusobacterium necrophorum* was quantified from ruminal contents and ruminal wall tissue collected at slaughter. Livers were examined and scored for abscesses. The mean concentration of *F. necrophorum* on the ruminal wall ranged from  $2.9 \times 10^3$  to  $6.1 \times 10^5$  per  $\text{cm}^2$ . The dorsal sac had the lowest counts, and dorsal blind and ventral sacs had the highest counts of *F. necrophorum* adherent to the ruminal wall. The concentrations of *F. necrophorum* in ruminal contents and on the ruminal wall did not appear to be related to presence or absence of abscessed livers or to severity of abscesses.

(Key Words: *Fusobacterium necrophorum*, Ruminal Contents, Ruminal Wall.)

### **Introduction**

*Fusobacterium necrophorum* is the primary causative agent of liver abscesses in feedlot cattle and is a normal inhabitant of the rumens of cattle. The concentration in the rumen ranges from 100,000 to a million cells per gram of contents. Additionally, the ruminal ecosystem includes 'epimural bacteria', which are adherent to the ruminal wall. Reports on the isolation of *F. necrophorum* from the ruminal wall are limited and are almost always in relation to ruminal lesions. Whether *F. necrophorum* is part of the normal component of the ruminal wall population is not known.

Two studies were conducted. One was to quantify *F. necrophorum* attached to the ruminal wall. The second was to determine whether the concentration of *F. necrophorum* in ruminal contents and on the ruminal wall was related to the occurrence of liver abscesses in cattle.

### **Experimental Procedures**

In the first study, rumens were obtained immediately after slaughter from eight cattle fed a high-grain diet, and samples of ruminal contents and ruminal wall tissue were collected. Tissue sections were taken from the cranial sac, dorsal sac, dorsal blind sac, ventral sac, and ventral blind sac. The pH of ruminal contents was recorded.

In the second study, ruminal contents and ruminal wall sections (from the dorsal sac only) were collected from 76 grain-fed cattle at a slaughter house. Livers were examined for abscesses and scored on a scale of 0 to A+ with 0 being no abscess and A+ being one or two large or multiple small abscesses (Table 1). The pH of ruminal contents was measured immediately after collection. Samples were chilled and packed in ice and shipped by overnight delivery to the laboratory.

Ruminal contents were blended for 1 minute, strained through four layers of cheesecloth, and diluted anaerobically. Enumeration of *F. necrophorum* was by most-probable-number (MPN) technique using a selective culture medium dispensed in 96-well

microtiter plates and incubated in an anaerobic glove box. The plates were incubated for 48 hours and tested for indole production as evidence of *F. necrophorum* growth.

Ruminal wall tissues were cut into 8 mm circles with a biopsy punch, rinsed three times in anaerobic medium, and minced in a homogenizer. Serial dilutions of the suspension of homogenized ruminal wall tissue were made anaerobically, and *F. necrophorum* was enumerated as before.

### Results and Discussion

In the first study, the mean pH was 5.57, and *F. necrophorum* counts of ruminal contents averaged  $4.6 \times 10^5$ /gram of DM. The mean concentration of *F. necrophorum* on the ruminal wall ranged from  $2.9 \times 10^3$  to  $6.1 \times 10^5$  per  $\text{cm}^2$ . Some ruminal wall tissue samples showed no *F. necrophorum* growth. The dorsal sac had the lowest counts, and the dorsal blind and ventral sacs had the highest counts of adherent *F. necrophorum* (Figure 1).

In the second study, 39 samples were from cattle with normal livers (liver score 0)

and 37 samples were from cattle with liver abscesses (liver score A-, A, and A+). Mean pH of ruminal contents was similar between groups. Of the 39 ruminal wall samples from cattle with no liver abscesses, 14 samples yielded no *F. necrophorum* growth. Of the 37 rumen wall samples from cattle with liver abscesses, 17 exhibited no *F. necrophorum* growth. The mean *F. necrophorum* counts from ruminal contents were  $2.4 \times 10^6$  and  $.9 \times 10^6$  MPN/gram of DM from cattle with normal and abscessed livers, respectively (Table 1). Additionally, the mean *F. necrophorum* counts from ruminal wall were  $2.6 \times 10^3/\text{cm}^2$  for samples collected from cattle with normal levels and  $8.4 \times 10^3/\text{cm}^2$  for those with abscessed livers. None of the differences among groups for ruminal pH and *F. necrophorum* counts in ruminal contents and ruminal walls were statistically significant. However, it is interesting that counts of *F. necrophorum* adherent to the ruminal wall were numerically higher in cattle with abscessed livers than in cattle with normal livers. Further research is needed on *F. necrophorum* adherent to the ruminal wall in terms of factors affecting their presence or numbers and their role in causing liver abscesses.

**Table 1. *Fusobacterium necrophorum* in Ruminal Contents and on the Ruminal Wall from Cattle with or without Liver Abscesses**

Liver Abscess Score <sup>a</sup>	Number of Samples	Ruminal pH	<i>F. necrophorum</i>	
			Ruminal Contents, $\times 10^6$ MPN/g DM	Ruminal Wall, $\times 10^3$ MPN $\text{cm}^2$
0	39	6.15	2.4	2.6
A-	8	6.57	1.2	16.7
A	13	6.29	.4	2.3
A+	16	5.98	.2	6.3

<sup>a</sup>0 = normal liver; A- = Liver has one or two small abscesses or abscess scar; A = Liver has two to four well-organized abscesses under one inch in diameter; A+ = Liver has one or more large, or multiple small active abscesses with or without portions of the diaphragm adherent to the surface of the liver.

## Rumen wall location

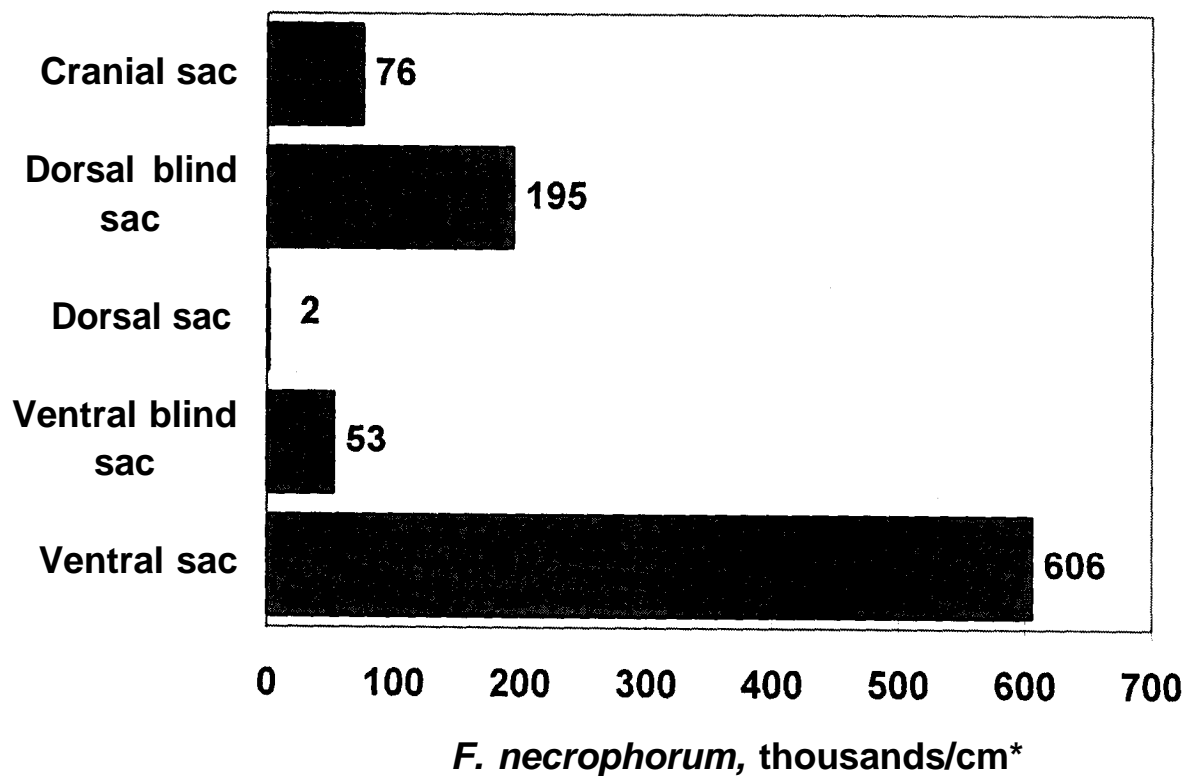


Figure 1. Counts of *Fusobacterium necrophorum* Adherent to the Ruminant Wall in Cattle Fed High Grain Diets.