

PATHOGENETIC STUDIES OF CANINE SEBORRHEIC SKIN
DISEASE IN THE WEST HIGHLAND WHITE TERRIER BREED

by

Janet Jimenez Raczkowski
B.S., Kansas State University, 1982
D.V.M., Kansas State University, 1984

A THESIS

submitted in partial fulfillment of
the requirements for the degree

MASTER OF SCIENCE

Department of Pathology
College of Veterinary Medicine
KANSAS STATE UNIVERSITY
Manhattan, Kansas

1984

Approved by:

Harold W. Geipold
Major professor

LD
2668
.T4
1984
.R328
C. 2

Al1202 956771

TABLE OF CONTENTS

	Page
ACKNOWLEDGEMENTS.....	iv
INTRODUCTION.....	1
I. LITERATURE REVIEW	
A. Introduction.....	3
B. Etiopathogenesis.....	4
C. Morphological Classification.....	11
D. Clinical Signs.....	14
E. Cutaneous Lipids.....	15
F. Cutaneous Bacteriology.....	16
G. Embryology, Normal Histology and Physiology of Canine Skin.....	17
H. Dermatohistopathology.....	22
I. References.....	25
II. MATERIALS AND METHODS	
A. Pedigree Analysis.....	28
B. Breeding Trials.....	28
C. Pathogenetic Studies.....	28
III. RESULTS	
A. Pedigree Analysis.....	32
B. Breeding Trials.....	34
C. Pathogenetic Studies	
1. Gross pathological findings.....	34
2. Histopathological findings.....	35
3. Special histopathological stains.....	38
4. Skin cultures.....	39
5. Electron microscopy.....	39

TABLE OF CONTENTS (CONTINUED)

	Page
IV. DISCUSSION.....	41
V. SUMMARY.....	46
VI. REFERENCES.....	49
VII. APPENDICES	
A. Literature Review - Tables.....	51
B. Literature Review - Clinical and Histopathological Features of Seborrhea.....	54
C. Materials and Methods - Table 4.....	56
D. Genealogy Chart and Pedigrees.....	57
E. Pathogenetic Studies - Photographs of Gross Pathological Findings.....	61
F. Pathogenetic Studies - Selected Photomicrographs of the Histopathological Lesions.....	63
G. Selected Transmission Electron Microscopic Features of Seborrheic Skin.....	68
H. Chi-Square Test - Table 5.....	70

ABSTRACT

ACKNOWLEDGEMENTS

I would like to express my most sincere gratitude to my major professor, Dr. Horst W. Leipold, and to the members of my supervisory committee, Dr. Marvin Samuelson, Dr. George Kennedy and Dr. Jacob Mosier, for their assistance and guidance throughout my graduate studies and work.

To Dr. H.W. Leipold I am deeply indebted for unselfishly sharing his knowledge and expertise and for his inspirational support in the completion of this degree.

Technical assistance by Dave Adams, Barbara Kelly, Shon Koenig, Duane Kerr, Frank Leatherman and Bob Mueller was greatly appreciated. Cooperation of Mrs. Alberta Parker and the owners of K-Hill kennels, Mr. and Mrs. Kelly, was invaluable.

Finally, I wish to thank my husband, Charlie, for all his patience and for always being there, giving me support and encouragement when I needed it.

INTRODUCTION

Seborrhea can be defined as a defect in the keratinization process associated with both qualitative and quantitative disturbances in the sebaceous secretions with or without apocrine gland involvement. The seborrheic complex is presented to the small animal clinician in a variety of clinical forms. The primary clinical signs are: generalized scaliness, crusting and alopecia with variable degrees of pyoderma, pruritus and self-trauma. A typical rancid fat odor and ceruminous otitis may or may not be present.

Based on the clinical appearance and distribution of the lesions the disease is classified morphologically into three categories; seborrhea sicca, seborrhea oleosa and seborrheic dermatitis. With respect to its etiology, metabolic disturbances and many other unrelated disease processes may cause seborrhea, but idiopathic seborrheic conditions are also well recognized.

Histopathological changes are not diagnostic and resemble those of a chronic dermatitis. Some researchers have demonstrated an aberrant lipid pattern as well as significant qualitative and quantitative changes in the cutaneous microflora of seborrheic skin.

The clinical and pathological aspects of canine seborrhea have been well described in the veterinary literature but more extensive research is definitely needed. Elucidation of the pathological changes leading to this condition as well as evaluation of other factors which might be involved in the

process will be of great benefit to our profession and to the animal population we serve. Early identification of individuals that may be born with the predisposition to develop this condition would be of great value in preventive medicine programs and selective breeding.

Hereditary predisposition to this disease complex in certain families of dogs has received little attention. Therefore, this study was designed for the purpose of:

1. Evaluating the significance of hereditary factors in the etiology of primary idiopathic seborrhea in the West Highland White Terrier breed. This was achieved by conducting:
 - a) genealogy studies of a particular family of dogs suffering from the disease.
 - b) breeding trials using members of this family of dogs.
2. Studying the pathogenetic characteristics of this disease complex by:
 - a) obtaining skin biopsies and examining these for histopathological changes.
 - b) performing skin cultures to evaluate qualitative changes in the cutaneous microflora.
 - c) visual examination assisted by photography to evaluate gross pathological lesions.
 - d) transmission electron microscopy studies of skin sections obtained from affected individuals.

II. THE SEBORRHEIC DISEASE COMPLEX : A REVIEW

A. Introduction

The term seborrhea is frequently used incorrectly to describe a host of scaly skin diseases. In the veterinary literature this complex has become a broad classification for a variety of clinical entities ranging from simple dandruff to severe erythematous, crusty, scaling lesions(16). Austin (1983) proposed the use of abnormal keratinization problems as a more accurate and descriptive term to designate this group of skin conditions that vary widely in form and intensity(3,6).

The word seborrhea literally combines the Latin sebum (referring to tallow or grease) and the Greek rhoia (meaning flow) thus implying an abnormal flow of sebum. Seborrhea, as it applies to the canine seborrheic skin disorder can be defined as a defect in the keratinization process accompanied by both quantitative and qualitative changes in the pilosebaceous apparatus with or without disturbances in the function of the apocrine sweat glands.

In the veterinary practice this syndrome is recognized as one of the most common chronic canine dermatoses encountered by the small animal clinician. Although the disease has been studied for over 75 years it still raises more questions than answers when it comes to etiology and therapy both in humans and in the canine species.

Seborrhea in man was first described in 1887 by Unna. His paper on Seborrheal Eczema consists of a detailed description of

this disease and is now a classic in dermatologic literature(42). In 1902, Schindelka described seborrhea in dogs and classified the disease into seborrhea sicca and seborrhea oleosa(38). In 1959, Kral described seborrheic dermatitis as a third form(21).

The following is a review of the clinical and pathological changes and the proposed etiopathogenetic mechanisms involved in the seborrheic syndrome.

B. Etiopathogenesis

True canine seborrhea is a specific entity for which the cause is not known. A few other diseases however, are consistently accompanied by seborrheic changes(29). It is essential to differentiate between primary (if a metabolic defect is found which causes the condition or if no secondary disease process can be determined) and secondary seborrhea (as a clinical sign in association with a number of unrelated processes).

Typical primary seborrhea is seen in some Cocker and Springer Spaniels in which there is oiliness, ceruminous otitis, mild or no pruritus, a lifelong course and poor response to therapy(31). Secondary seborrhea tends to be more scaly and less greasy, and accompanies many unrelated disease processes such as demodecosis, atopy, scabies, flea allergy dermatitis, contact dermatitis, male feminizing syndrome, some forms of hypothyroidism and some generalized dermatomycoses (1,2,11,15,16,31). Table 1 illustrates the etiological classification of seborrhea.

Primary Idiopathic Seborrhea

This is a discrete disease in which no contributing external or internal causation can be determined. Cure is most difficult in these cases and the condition shows a tendency to begin early in life. Familial factors are speculated to be involved. Many investigators (3,4,6,7,31) have reported an inherited tendency toward abnormal sebaceous gland function and keratinization in certain breeds of dogs but no research study had been conducted to provide scientific evidence for a genetic basis of this disease process.

Among the breeds that show a predisposition to this type of seborrhea we find the German Shepherd, Cocker and Springer Spaniel, Irish Setter, Dachshund, Poodle, Miniature Schnauzer and West Highland White Terrier (6,15,41).

Primary Metabolic Seborrhea

This term is used to describe cases in which a metabolic defect is implicated in the pathogenesis of seborrhea. Aberrations in lipid availability to the skin, hormonal changes or any other metabolic processes that lead to a deranged sebaceous flow or influence the keratinization process may contribute to this condition.

A. Endocrine-Related

Thyroidal and gonadal hormones both profoundly affect the physiological processes of the skin, particularly keratinization and sebum production. Thus, it is not surprising that variation in the production and/or utilization of these hormones may contribute to the development of the seborrheic lesions. Hypothyroidism is the most common endocrine disorder affecting

the skin of dogs(41). Clinically these patients show bilaterally symmetrical alopecia and pigmentary disturbances , and a coarse, dull, dry, brittle, easily epilated haircoat. Cutaneous changes may also include a normal to thick skin, comedone formation, poor wound healing and frequent pyoderma and/or seborrheic skin disease(41). Hyperkeratosis, epidermal atrophy, epidermal melanosis, follicular atrophy and keratosis, telogen hair follicles, sebaceous gland atrophy, dermal thickening and swollen, separated collagen bundles in the dermis are the major histopathological changes observed in this condition. History and clinical signs of hypothyroidism, if present, are subtle as these dogs generally do not fit the typical obese, lethargic, heat-seeker pattern. Clinicopathological evaluation is thus needed with T4 values of less than 1.4 $\mu\text{g}/100$ ml (Nuclear Medicine Test) being diagnostic if coupled with an abnormal TSH response test. Frequently, animals with a slightly depressed T4 level will respond dramatically to therapy. Irish Setters, German Shepherds, Doberman Pinschers and Afghan Hounds seem to be overrepresented in this category(15,16).

Hyperadrenocorticism is a well documented endocrine disorder of the dog. Cutaneous lesions and histopathological changes are similar to those observed in hypothyroid dogs except for the presence of a thin hypotonic skin and calcinosis cutis grossly, and dystrophic calcification histologically in the Cushinoid individual.

Gonadal disorders including testicular tumors, hypo and hyperestrogenism (associated with ovarian imbalances) and hypoandrogenism (male feminizing syndrome) may all be accompanied

by a secondary seborrhea. The gross and histological lesions observed in these cases follow the pattern exhibited by other endocrine related dermatosis previously described. In addition, hyposomatotropism has been reported to be involved in adult dogs showing a growth hormone responsive dermatosis(41).

Dogs with diabetes mellitus may develop a dry secondary seborrhea but the specific mechanism is unclear(31). Finally, because of the similarity of the dermatological lesions observed in acanthosis nigricans, this disease should be included in this group although the majority of the cases have no documented association with an endocrine disorder(41).

B. Aberrations in Lipid Availability

Nutritional deficiencies of the essential fatty acids lead to epidermal hyperplasia resulting in scaly skin problems. Vitamin A is necessary for normal skin maintenance but excessive amounts orally or topically will cause degeneration of the keratinocytes due to an increased release of acid proteases from lysosomes(3). On the other hand, vitamin A responsive dermatoses have been reported in dogs with normal levels of vitamin A in the serum(34). Recently, investigators at the University of California-Davis reported a scaly skin problem associated with the practice of feeding inexpensive generic dog foods. The problem was thought to be related to an underlying zinc deficiency in the diet. Because the keratinization process requires large amounts of available protein any disease that interferes with protein metabolism can cause changes that result in scaly skin.

Occasionally malabsorption and/or maldigestion due to chronic gastrointestinal problems can cause changes in the keratinization rate in dogs of any age. The possibility of an underlying pancreatic and/or intestinal problem should always be investigated. Since the liver is of utmost importance in the metabolism of lipids, an acute or chronic hepatic disease should also be considered in the diagnostic work-up of seborrheic cases.

Secondary Seborrhea

The mechanisms responsible for the development of seborrheic lesions secondary to a systemic disorder are unknown. The skin has a limited number of ways in which it can react to either external or internal insult; thus it is not surprising to find scaling, alopecia and crusting in association with a variety of disease processes(15,16). Virtually any skin disorder can be associated with acaling; however, these conditions are often presented with seborrhea as the major complaint with other, more classical, signs of the disease being absent.

Parasitic infestations, pyodermas, bacterial hypersensitivity reactions, allergies, immune-mediated diseases and neoplasia may all lead to secondary seborrhea. Each of these secondary seborrheic syndromes will usually exhibit a typical distribution pattern which coupled with the presenting clinical history aids in the differential diagnostic work-up.

A generalized mild seborrhea, perhaps associated with a continuous low grade self-trauma, is sometimes seen in animals with atopic skin disease. Pruritus, not seborrhea, is the primary complaint. The digital and facial involvement aids in the differential diagnosis which can then be substantiated with

intradermal skin testing. Food allergy is associated with a very generalized seborrhea and severe pruritus. Drug eruption resulting in erythema, rashes and dry scaly skin conditions, has also been implicated as a possible cause of seborrhea.

Occasionally generalized dermatophytosis may mimic seborrhea; however, ringworm lesions are more localized and usually discrete. With seborrhea the hairs epilate rather easily with nit-like crusts surrounding them. On the other hand, the hairs in dermatomycosis will be broken. Fluorescence of the hair itself, the location of the lesions and a history of contagion and owner involvement are all useful in the differentiation of this disease from primary seborrhea.

The most common of these secondary seborrheic conditions is that associated with a flea allergy dermatitis. Symmetrical scaling, especially in the dorsal lumbosacral area, is frequently misdiagnosed as primary seborrhea. Generalized demodecosis is characterized in it's early stages by a moderate inflammation and a severe seborrhea. As the disease progresses a secondary pyoderma develops; the seborrhea is then variable but it may be extreme. Seborrhea secondary to scabies is usually presented with generalized lesions. A primary maculopapular rash coupled with site predilections for the margin of the pinnae, lateral elbows and thoracic and ventral midline aids in the differentiation of sarcoptic mange. A history of rapid onset, multiple involvement and contagion is valuable for diagnosing Cheyletiella infestations. These result in a predominantly dorsal distribution of the seborrheic lesions.

An erythematous alopecic dermatitis of the chest and limbs along with seborrheic lesions are found among the cutaneous changes described in association with Dirofilaria immitis infection. In addition, a pruritic, ulcerative, sometimes nodular, dermatitis and a papulocrustous dermatitis resembling scabies may be observed(31). The history, clinical findings and skin biopsies should enable the clinician to make a diagnosis.

Symmetrical scaling of face and distal extremities is seen in cases of autoimmune diseases such as systemic lupus erythematosus (SLE). The scales are epidermal collarettes secondary to vesicles and pustules. Pemphigus foliaceus and other related immune mediated processes may be presented with thick keratotic plaque formations on any part of the body, particularly on the bridge of the nose and the mucocutaneous junctions. The unusual character and the severity of the cutaneous lesions observed in these cases usually rule out primary seborrhea as a diagnosis.

Neoplasms that produce a severe inflammation and alopecia may result in the formation of focal seborrheic plaques. Cutaneous lymphoreticular malignancies, including mycosis fungoides, are examples.

Certain short haired breeds such as the Boxer, Great Dane and Weimaraner, are predisposed to "short-haired dog" pyoderma. In this syndrome, patchy, focal areas of alopecia may be seen dorsally and the patients are presented with a moth-eaten appearance. Identifiable pustules are readily found in the groin and axillary areas.

Papules, focal erythematous areas, and scaling as well as

local trauma due to excoriations, are associated with delayed bacterial hypersensitivity reactions. The lesions begin as broken pustules and then spread peripherally to form scaly, intense inflammatory plaques. Coalescence of these plaques and hyperpigmentation follow in the chronic cases.

Finally, local irritation from a dry environment, too frequent wetting and shampooing, as well as contact with topical irritants such as soaps, organic solvents and propylene glycol, may produce extensive scaling.

C. Morphological Classification

The seborrhea syndrome has been classically subdivided into seborrhea sicca, seborrhea oleosa and seborrheic dermatitis, based on the subjective evaluation of the waxiness or oiliness of the haircoat and the presence or absence of focal, or multifocal, severely inflamed areas. Other keratinization disorders have been occasionally grouped in the seborrhea syndrome(5,7). These include: asteatosis, pityriasis, psoriasis, pyosebopsoriasis, and parapsoriasis.

Asteatosis involves a relative or absolute deficiency of sebum production with dryness, induration and discoloration of the hair being the primary clinical signs in addition to roughness of the skin. Pityriasis is characterized by dryness and large desquamates of skin flakes. It may be localized or generalized and etiological factors are many. That portion of the seborrheic syndrome characterized by hyperkeratotic plaques with erythemic borders and scaly crusts is referred to as psoriasis. Pruritus and alopecia are variable with hyperpigmentation and

lichenification often being observed in the chronic cases. Pyosebopsoriasis is a term used to denote bacterial invasion associated with seborrheic dermatitis or the psoriasis complex. Large breeds of dogs showing small alopecic patches with erythemic, non-elevated, macules and varying degrees of hyperkeratotic accumulations are often referred to as suffering from parapsoriasis. Moderate to severe pruritus may be involved. Histopathological changes observed are compatible with those seen in the epidermis and the papillary dermal layer of seborrheic skin.

Seborrhea sicca is the dry, scaling form of the disease which is characterized by a dry dull pelage in association with fine crusting and minimal oiliness(11,15,16,29,41). The scales vary from white and powdery to greyish large flakes and tend to be non-adherent. Irish Setters, German Shepherds, Doberman Pinachers, Dachshunds, Golden and Labrador Retrievers are typically affected(31).

Seborrhea oleosa is characterized by focal or diffuse scaling associated with excessive sebum production resulting in adherent, brownish yellow accumulations of keratinosebacopocrine debris(42). Nit-like flakes are present on the hairs and the coat is odoriferous and greasy to the touch. The pelage is matted and superficial peripheral lymphadenopathy is common. In addition, it is often accompanied by pruritus and erythema. Some degree of ceruminous otitis usually accompanies this form of the disease which frequently affects Springer Spaniels, Chinese Shar Peis, and dogs with a light colored pelage

such as the blonde Cocker Spaniel(16,31).

Seborrheic dermatitis is the most troublesome of the three conditions. It is described by Scott as a disease characterized by grossly evident, focal or diffuse inflammatory foci accompanied by scaliness and/or greasiness. It is frequently associated with folliculitis and pruritus is often noted. Classical localized seborrheic dermatitis lesions are well circumscribed circular areas of alopecia and erythema with central clearing and marginal epidermal scaling. Hyperpigmentation is often observed in those cases of long duration. This is the type most commonly observed in Poodles and in the West Highland White Terrier breed. Differential diagnoses include other disorders such as ringworm, demodecosis, bacterial hypersensitivity, subcorneal pustular dermatosis, and pustular folliculitis(42).

Patients can be found with a variety of lesions that meet the criteria for classification of both, seborrhea sicca and seborrhea oleosa, and simultaneously showing focal areas of seborrheic dermatitis. It should be noted that the previous morphological classification is mainly a descriptive tool and not three distinct diseases since characteristic lesions clearly overlap. Based on the fact that aberrant lipid patterns as seen in canine seborrheic skin is consistent in both, seborrhea oleosa and seborrhea sicca, it has been suggested that both types are actually the same disease exhibiting a range in clinical manifestation due to breed variations.

D. Clinical Signs

The primary clinical signs of seborrheic skin are generalized scaling, crusting and alopecia. In most cases of primary seborrhea the head and distal extremities seem to be spared. Seborrheic lesions can be found on any part of the body and consist of scaly crusted areas that are somewhat circular. The severity of the clinical signs varies with the individual but areas of exacerbation are often observed in those regions of the body with a higher concentration of glandular activity; namely, the preen area of the tail, periocular and perioral regions, pressure points such as the elbow, stifle and hock, anogenital and axillary regions as well as the dorsal lumbosacral area(15,16,42).

Greasy, scaly patches with clusters of fatty particles adhered to the haircoat and resembling louse nits are frequently described. In some areas the hair and skin are covered by extensive adherent yellowish brown greasy scales whereas in others intense scaliness is the major lesion. The degree of scaling and crusting is dictated by the variation in the lipid and keratinosebaceous production; a dry waxy debris will increase scaliness as particles are more readily shed from the skin and hair surfaces. A greasy debris will manifest as increased crusting and matting of the pelage.

A rancid odor is typical of some forms of seborrhea. Another characteristic seborrheic lesion is a scaly macule or patch of focal alopecia with a pigmented center surrounded by an erythematous halo(31). These lesions are very similar to

dermatomycotic lesions and are particularly typical on the chest area. The owners complain of increased hair shedding and a generalized thinning of the pelage.

Variable degrees of inflammation, self-trauma and pyoderma are involved in this disease complex. Keratinization defects as well as derangements of the surface lipids frequently accompany the inflammatory changes.

Dry scales and flakes can be found in localized areas or it can be generalized. The scales can be white, yellow, dry, greasy, branny, loose or adherent. Superficial pyodermas and pustular folliculitis are often seen secondary to seborrhea. A ceruminous otitis is frequently observed as evidenced by the increased production of an abnormally odorous cerumen and variable degrees of erythema, pruritus, hyperpigmentation and lichenification of the external ear canal.

Chronic cases typically develop a very thickened corrugated skin surface secondary to continuous low grade irritation caused by self-trauma and the presence of an abnormal cutaneous microflora. The lichenification is often accompanied by hypermelanosis which may also be localized or generalized. (Figure 1 illustrates the clinical signs characteristic of chronic seborrhea).

E. Cutaneous Lipids

There are differences in the skin lipid pattern between normal and seborrheic skin. Sebaceous gland secretions make up the skin lipid film which is a lipid-aqueous emulsion that covers and protects the skin and haircoat. In the normal canine

skin this lipid film is composed primarily of sterol and wax esters with small amounts of free cholesterol and triglycerides, but little or no free fatty acids are present. In seborrheic skin there is a significant decrease in the relative amounts of diester waxes and free fatty acids are consistently present(15,16).

Interestingly, the aberrant lipid pattern was consistently found in both seborrhea sicca and seborrhea oleosa as well as in all the breeds involved in the study(16). It is not known if this qualitative lipid shift is a key to the cause of seborrhea or if it simply reflects secondary biochemical changes. Table 2 illustrates the skin lipid components of normal and seborrheic skin in the canine species.

F. Cutaneous Bacteriology

Ihrke and his coworkers (1978) performed both quantitative and qualitative bacterial assays on the skin of fifteen normal and thirty two seborrheic dogs. The difference in the total aerobic counts between normal and seborrheic canine skin was highly significant. The geometric mean of the diseased skin ($16,150$ organisms/ cm^2) was about fifty times greater than that of the normal control group (329 organisms/ cm^2)(18).

The entire bacterial population of the control group comprised microorganisms which are normally considered to be comensal resident microflora; namely, coagulase negative cocci, diphtheroids, aerobic sporeformers, and Gram negative rods. Coagulase positive Staphylococcus aureus was consistently cultured (97% of the microflora) as the predominant microorganism

of the seborrheic skin in the absence of visible pyodermal lesions.

A marked qualitative and quantitative shift in the cutaneous ecosystem is associated with the seborrheic skin; therefore, affected dogs can be viewed as frequent carriers of pathogenic staphylococcal bacteria(18). Theoretically, the extended surface area observed in hyperkeratotic skin should support a greater bacterial population. In addition, bacterial proliferation may also be facilitated by the qualitative and quantitative changes in the sebaceousapocrine production characteristic of seborrheic skin.

Superficial pyodermas, such as impetigo and superficial folliculitis, are frequently observed in association with seborrhea. Lowered host resistance factors related to the inflammatory changes which are secondary to pruritus and self-trauma, as well as the continuous availability of potentially pathogenic bacteria would account for the increased incidence of secondary pyodermas in these individuals. Table 3 illustrates the microfloral changes observed in normal and seborrheic canine skin.

G. Embryology, Normal Histology and Physiology of Canine Skin

An appreciation of the pathogenetic changes involved in seborrheic skin depends on an understanding of the normal biology of the epidermis. Histological features of the skin components as well as embryological facts are also reviewed here(1,8,14,19, 22,24,25,28,31,33,35,44,45).

Histogenesis

A complete and accurate account of the embryologic development of the skin of the dog and its adnexa is not available. Basic facts pertaining to mammals would seem valid for the dog. Both ectoderm and mesoderm give rise to the integumentary system. The epithelial covering and its derivatives, the hair follicles, sweat and sebaceous glands, and the nervous tissue originate from ectoderm. The connective tissue and vascular elements are contributed by mesoderm.

At a very early stage a single layer of ectodermal cells develop into two layers, the basal layer or stratum germinativum and, above it, the periderm layer. This is followed by the development of the second, third and fourth epidermal layers which form in between these two layers through upward movement of cells from the basal layer. Prickle cells, cornification and, finally, true keratinization are evident before birth.

Melanocytes are derived from the neural crest and their appearance in the epidermis takes place in a craniocaudal direction. Melanocytes are functionally immature during their migration through the fetal dermis.

The embryonal stratum germinativum differentiates not only into basal cells, which give rise to the keratinizing epidermis, but also into hair germs (also called primary epithelial germs) which give rise to the hair, sebaceous glands, apocrine glands, and, into eccrine gland germs which will give rise to the eccrine glands.

The first hairs to appear on the fetus are vibrissae and tactile or sinus hairs that develop on the chin, eyebrows and

upper lip. Hair follicles develop as solid cords of epidermal cells growing obliquely downward into the dermis. As the epidermal peg advances it becomes bulbous and partially envelops mesenchymal tissue. Differentiation into the hair bulb (from epidermis) and dermal papilla (from mesenchyme) leads to the formation of the primary hair follicles which appear at regular intervals in the skin. As the fetus enlarges new follicles form among the older ones. At birth, hair follicles are simple (only one hair shaft per follicular orifice) and it takes up to six months for the typical canine compound hair follicle to develop.

Hair follicles grow at a slant and in the early bulbous stage develop two or three bulges on their undersurface. The lowest of the three bulges develops into the attachment of the arrector pili muscle whereas the middle bulge differentiates into the sebaceous gland. The central cells in each cord accumulate lipid and then disintegrate to form alveoli and ducts. These glands are probably functional before birth. The uppermost bulge develops into the apocrine sweat gland. It grows downward in a spiral manner and forms coils deep in the dermis or subcutis. Apocrine function in the dog is not fully developed until puberty.

Eccrine sweat glands are usually found only in the foot pads. They develop as solid cords of cells growing downward from the epidermis and progress deeply into the dermis and subcutis.

The dermis of the embryo consists of loosely arranged mesenchymal cells that are embedded in a ground substance. These cells soon develop into fibroblasts and argyrophilic reticulum fibers appear simultaneously. As these fibers increase in number

and in thickness, they arrange themselves in bundles that no longer can be impregnated with silver and, instead, stain with the methods for collagen. Elastic fibers appear in the dermis much later than collagen fibers.

Structure and Dynamics

No area of the body is subject to such varied disease influences and mechanical injuries as the integumentary system which is one of the largest organ systems of the body. Canine skin is composed of two layers which function as a unit: an outer layer, the epidermis and an inner layer, the dermis. At the dermoepidermal junction there is a basement membrane zone which acts as a chemical interface. In the dog this junction is smoothly undulating and is more or less parallel to the skin surface. The rete ridges found in human skin are only observed in the non haired (foot pads and planum nasale) and scrotal skin of small animals. If present in haired skin it indicates a pathologic process.

The epidermis is composed of multiple layers of columnar to flattened cells referred to as keratinocytes. In addition, we find three other types of cells, or epidermal "clear cells": melanocytes, Merkel cells and Langerhans' cells. As they differentiate into horny cells the keratinocytes are arranged into four layers; the basal layer, the prickle cell layer, the granular layer and the horny layer. An additional layer, the stratum lucidum, can be recognized in hairless areas such as the footpads and sometimes in the planum nasale. The term stratum germinativum is applied to the lower two layers where most of the

mitotic activity takes place. Baker(1973) has studied epidermal cell renewal time in the dog and determined it to be approximately 22 days. In pathologic processes such as seborrhea, an increased epidermopoietic rate results in replacement of the entire epidermal cell population in only three to four days.

The basal cells are columnar in shape and lie with their long axis parallel to the dermoepidermal junction. These cells have a deeply basophilic cytoplasm and a dark staining oval or elongated nucleus. They are connected with each other and with the prickle cells above by intercellular bridges or desmosomes which are less distinct than those of the stratum spinosum. The melanocyte is the second type of cell found in the stratum basale and appears as a clear cell in H & E sections. Normally the skin contains about one melanocyte per every ten keratinocytes. The melanin granules that they produce are transferred to the epidermal keratinocytes where they form cap-like aggregates just above their nuclei. Merkel cells are confined to the stratum basale of tylotrich pads (epidermal papilla), they possess desmosomes, and are thought to function as slow adapting mechanoreceptors.

The stratum spinosum is one to three layers thick and composed of lightly basophilic polyhedral to flattened cuboidal cells. The spinous keratinocytes are viable nucleated cells which are actively synthesizing keratin. Langerhans' cells are mononuclear dendritic cells located throughout the stratum germinativum with characteristic striations and intracytoplasmic granulations. They are thought to be involved in antigen

processing and allo-antigen stimulating functions.

The cells of the granular layer are diamond-shaped or flattened and their cytoplasm is filled with keratohyaline granules that stain deeply basophilic and are irregular in size and shape. This layer is usually one cell layer thick, its thickness being directly proportional to the thickness of the stratum corneum or horny layer. This is the keratogenous zone of the epidermis where a lot of autolytic changes are taking place.

The clear layer, or stratum lucidum, is a fully keratinized, compact, thin layer of non-nucleated cells. It is observed in non haired areas as a homogenous eosinophilic zone and contains refractile droplets (eleidin).

The outermost layer of the epidermis, the stratum corneum, is formed by flat, anucleated, eosinophilic staining cornified keratinocytes. The keratinization process is completed and the vertically oriented basal cells are transformed into horizontally aligned, thin, cornified cells. An orderly rate of desquamation is normally balanced by proliferation of the basal cells to maintain a constant epidermal thickness.

H. Dermatohistopathology

Histopathologic evaluation of a skin section may be suggestive of seborrhea but the pathologic lesions are not specifically diagnostic. The disease appears microscopically as a spongiotic and/or hyperplastic superficial perivascular dermatitis(31). There is usually a marked keratinization defect and considerable variation in thickness of the epidermis is observed depending on the degree of chronicity. Epidermal

hyperplasia is quite evident in seborrheic skin as shown by an increase in keratinocytes from the stratum granulosum to the epidermal basal layer. In the acanthotic skin the various stages of the maturing keratinocytes are more easily recognized. This pathologic alteration is accompanied by the formation of rete ridges at the dermoepidermal junction.

A diffuse orthokeratotic and multifocal parakeratotic hyperkeratosis is commonly observed. These pathological changes which indicate an excessive formation of keratin, are usually observed in association with changes in the thickness of the granular layer (hyper and/or hypogranulosis). The parakeratosis is characterized by retention of nuclei in the stratum corneum and/or within the hair canal and it reflects imperfect or abnormal keratinization of the epidermal and adnexal keratinocytes. Interestingly, hypogranulosis is seen in those areas showing a prominent parakeratotic hyperkeratosis whereas hypergranulosis is observed in sections exhibiting marked orthokeratotic hyperkeratosis.

An increased amount of keratin is found in the dilated pilosebaceous follicular ostia. The extensive follicular keratosis is accompanied by periadnexal fibrosis in the chronic cases. Acanthosis, hypergranulosis and hyperkeratosis of the external root sheath are also commonly observed(37). Abnormalities of the sebaceous glands are rarely seen except in cases of endocrinopathies where atrophy of these glands may be present(4,42). The apocrine sweat glands are sometimes secondarily involved showing cystic dilatation and a flattened epithelial lining.

The dermis shows a mild subacute or chronic inflammatory cell infiltration. The perivascular cellular infiltrate consists of variable numbers of lymphoplasmacytic cells, polymorphonuclear leukocytes, mast cells and histiocytes(15,16,31). Evidence of inflammation and secondary bacterial infection is commonly seen as superficial crusting, epidermal edema and perifolliculitis or folliculitis. Collections of inflammatory cells, red blood cells, fibrin and cellular debris in the horny layer are sometimes accompanied by microabscessation (intraepidermal pustular dermatitis) in the severe pyosebopsoriatic cases. The spongiosis is characterized by edema between the keratinocytes. The edema fluid separates the individual cells and the desmosomes are well defined and appear stretched. This change frequently occurs in inflammatory dermatoses(13).

Occasionally, epidermal and dermal hypemelanosis, as evidenced by an increase in the number of melanocytes, is observed in the chronic seborrheic cases. Papillary dermal fibrosis can be found in association with hyperpigmentation and is also suggestive of chronicity.

Figure 2 illustrates some of the major histopathological changes observed in seborrheic skin.

REFERENCES

1. Anderson, R.K.: Exfoliative Dermatitis in the Dog. *Comp Cont Ed* 3(10):885-890, 1981.
2. Anderson, W.N.: A Treatment Regimen for Seborrhea of Dogs. *J Am Vet Med Assoc* 164(11):1111-1113, 1974.
3. Austin, V.H.: A Clinical Approach to Abnormal Keratinization Diseases of the Dog. *Comp Cont Ed* 5(11):890-898, 1983.
4. Austin, V.H.: Congenital Seborrhea of Springer Spaniels. *Mod Vet Pract* 54(4):53-55, 1973.
5. Austin, V.H.: Scaly Diseases of the Canine Skin. *Proc Am An Hosp Assoc*, pp.106-111, 1974.
6. Austin, V.H.: Sebopsoriasis in the Dog. *Mod Vet Pract* 55(5):379, 1974.
7. Austin, V.H.: The Skin In: Canine Medicine, pp.1207-1209, 1222-1226. American Veterinary Publications, Santa Barbara, 1979.
8. Baker, B.B.: Epidermal Cell Renewal in the Dog. *Am J Vet Res* 34(1):93-94, 1973.
9. Bland-Van Den Berg, P.: Common Canine Dermatoses. *J So Afr Vet Assoc* 48(4):247-253, 1977.
10. Calhoun, M.L. and Stinson, A.W.: Integument In: Textbook of Veterinary Histology, ed. Dellman and Brown, pp.459-476. Lea & Febiger, Philadelphia, 1976.
11. Chester, D.K.: The Differential Diagnoses of Seborrheic Skin Disorders. *Proc Am An Hosp Assoc*, pp.141-144, 1976.
12. *Dorland's Illustrated Medical Dictionary*, 25th ed. W.B. Saunders, Philadelphia, 1974.
13. Graham, J.H., Johnson, W.C. and Helwig, E.B.: *Dermal Pathology*, pp.1-46, 119-135. Harper & Row, Hagerstown, 1972.
14. Halprin, K.M.: Cyclic Nucleotides and Epidermal Cell Proliferation. *J Inv Derm* 66(6):339-343, 1976.
15. Ihrke, P.J. and Horwitz, L.N.: Canine Seborrhea In: Current Veterinary Therapy VI-Small Animal Practice, ed. R.W. Kirk, pp.519-524. W.B. Saunders, Philadelphia, 1976.
16. Ihrke, P.J.: Canine Seborrheic Disease Complex. *Vet Clin North Am (Small Anim Pract)* 9(1):93-106, 1979.
17. Ihrke, P.J.: Effects of Hormonal Therapy on the Microbiology of Seborrheic Skin. *Am J Vet Res* 40(10):1495-1497, 1979.

18. Ihrke, P.J.: Microbiology of Normal and Seborrhic Canine Skin. *Am J Vet Res* 39(9);1487-1489, 1978.
19. Jarret, A.: The Physiology and Pathophysiology of Skin Vol I, pp.1-24, 235-236. Academic Press, New York, 1973.
20. Jones, T.C. and Hunt, R.D.: Veterinary Pathology 5th ed., pp.1078-1082, 1097. Lea & Febiger, Philadelphia, 1983.
21. Kral, F. cited by Muller, G.H.: Canine Seborrhia. *An Hosp* 2:228-235, 1966.
22. Kral, F. and Schwartzman, R.M.: Veterinary and Comparative Dermatology, pp.173-178. J.B. Lippincott, Philadelphia, 1964.
23. Langham, R.F. and Schirmer, R.G.: Value of Histopathologic Examination in Diagnosis of Dermatologic Disorders in Small Animals. *J Am Vet Med Assoc* 153(12):1754-1758, 1968.
24. Lever, W.F. and Schaumburg-Lever, G.: Histopathology of the Skin 6th ed., pp.3-14, 99, 476-481. J.B. Lippincott, Philadelphia, 1983.
25. Lovell, J.E. and Getty, R.: The Hair Follicle, Epidermis, Dermis and Skin Glands of the Dog. *Am J Vet Res* 18(10):873-885, 1957.
26. Luna, L.G. ed.: Manual Of Histological Staining Methods of the Armed Forces Institute of Pathology 3rd ed., McGraw-Hill, New York, 1968.
27. McManus, J.F.A. and Mowry, R.W. ed.: Staining Methods-Histologic and Histochemical. Harper & Brothers, New York, 1960.
28. Milne, J.A.: An Introduction to the Diagnostic Histopathology of the Skin, pp.86, 89-93. Williams & Wilkins Co., Baltimore, 1972.
29. Muller, G.H.: Canine Seborrhia. *An Hosp* 2:228-235, 1966.
30. Muller, G.H.: Seborrhia. *Proc Am An Hosp Assoc*, pp.117-122, 1966.
31. Muller, G.H., Kirk, R.W. and Scott, D.W.: Small Animal Dermatology 3rd ed., pp.1-88, 605-613. W.B. Saunders, Philadelphia, 1983.
32. Nesbitt, G.H.: Canine and Feline Dermatology: A Systematic Approach, pp.1-14, 111-116. Lea & Febiger, Philadelphia, 1983.
33. Nielsen, S.W.: Glands of the Canine Skin - Morphology and Distribution. *Am J Vet Res* 14(7):448-453, 1953.

34. Parker, W., Yager-Johnson, J.A. and Hardy, M.H.: Vitamin A Responsive Dermatitis in the Dog: A Case Report. *J Am An Hoasp Assoc* 19(4):548-554, 1983.
35. Pinkus, H. and Mehregan, A.H.: *A Guide to Dermatohistopathology* 3rd ed., pp.97-99. Appleton Century-Crofts, New York, 1981.
36. Prieur, D.J. and Hargis, A.M.: A Severe Form of Canine Juvenile Pyoderma with an Inherited Component [Abstract]. *Federation Proc* 41(1), pp.696, 1982.
37. Rojko, J.L., Hoover, E.A. and Martin, S.L.: Histologic Interpretations of Cutaneous Biopsies from Dogs with Dermatologic Disorders. *Vet Path* 15:579-589, 1979.
38. Schindelka cited by Muller, G.H.: Canine Seborrhea. *An Hoasp* 2:228-235, 1966.
39. Scott, D.W.: Clinical Assessment of Topical Benzoyl Peroxide in the Treatment of Canine Skin Disease. *Vet Med/Sm An Clin* 74(6):808, 810-811, 1979.
40. Scott, D.W.: *Feline Dermatology 1900-1978: A Monograph*. *J Am An Hosp Assoc* 16(3):412-414, 1980.
41. Scott, D.W.: Histopathologic Findings in Endocrine Skin Disorders of the Dog. *J Am An Hosp Assoc* 18(1):173-183, 1982.
42. Scott, D.W.: *Veterinary Dermatology Class Notes*, New York State College of Veterinary Medicine, Cornell University, Ithaca, New York, pp.95-100, 19__.
43. Unna cited by Muller, G.H.: Canine Seborrhea. *An Hosp* 2:228-235, 1966.
44. Webb, A.J. and Calhoun, M.L.: The Microscopic Anatomy of the Skin of Mongrel Dogs. *Am J Vet Res* 15(4):274-280, 1954.
45. Weinastein, G.D. and Frost, P.: Abnormal Cell Proliferation in Psoriasis. *J Inv Derm* 50:254-259, 1968.

PATHOGENETIC STUDIES OF CANINE SEBORRHEA
IN THE WEST HIGHLAND WHITE TERRIER BREED

II. MATERIALS AND METHODS

A. Pedigree Analysis

Four kennels with a history of having families of West Highland White Terriers with seborrhea were visited. The breeding records of one particular family of dogs from K-Hill kennels in Clifton, Kansas were reviewed to obtain accurate information regarding the familial relationships between affected individuals. Based on this information a complete genealogy chart was constructed on 100 dogs involving 12 generations.

B. Breeding Trials

Three members of the breed (one male and two females) showing clinical signs of the disease were donated to the project by Mr. and Mrs. Kelly, owners of K-Hill kennels. A third affected female dog was obtained from Mr. and Mrs. Cetingler, owners of Cetingler kennels in Green, Kansas. This particular kennel had also encountered dermatological problems in the WHW breed. Skin scrapings, skin biopsies, skin cultures, intradermal skin testing and clinicopathological tests such as CBC, SMA 12, fecal flotation, bile acids and T3T4 analyses were performed. The three females were bred to a stud dog from K-Hill kennels. This male had a history of producing affected litters and was included in the genealogy chart. Two litters of puppies were born in November of 1982. The nine pups were then utilized to perform the pathogenetic studies.

C. Pathogenetic Studies

The puppies were adopted by regular clients to simulate "normal" environmental conditions. From the time they were two

weeks old until they reached eight months of age skin biopsies and skin cultures were done at two week intervals. The axillary and inguinal areas were utilized for specimen collection in a rotational basis (every two weeks). Each particular site was cultured every two months and then biopsied in the following session. Photographs were taken on a monthly basis. The results from the above procedures were then recorded in a special form which has been included in the appendix (Table 4). In addition, the dogs were immunized at the recommended age utilizing DA2P-CPV^a and rabies^b vaccines.

1. Skin Cultures

The area to be cultured was carefully cleansed with cotton and sterile water. A dull Bard Parker #22 blade was used to gently but firmly scrape the skin surface until small petechiae developed. A sterile cotton swab was rolled over the surface of the scraped area. The swab was placed in a transport media^c and, following 24 hr. of incubation, streaked onto a blood agar culture plate. Bacterial growth at 37°C was recorded at 24 and 48 hrs. The slide coagulase test utilizing equine plasma was performed on isolated staphylococcal colonies.

2. Skin Biopsies - Collection Techniques and Histopathology

Xylazine^d at a dose of 0.5 mg/lb was given IM as a

^a DA2P-CPV, Norden Lab Inc., North Kansas City, Mo.

^b Rabguard TC, Norden Lab Inc., North Kansas City, Mo.

^c Stuart's transport media without charcoal.

^d Rompum, Haver Lockhart, Bayvet Division, Miles Lab, Shawnee, Ks.

tranquilizer. Mepivacaine HCl^e(2%) was injected subcutaneously as a local anesthetic into the area to be biopsied. A 6 mm biopsy punch^f was utilized in a rotary motion and the whole thickness of the skin was transected in a circular fashion. The skin specimens were then placed in 10% buffered neutral formalin for fixation.

The tissues were processed in an autotechnicon^g, embedded in paraffin, sectioned at 6 microns by a rotary microtome^h and stained with H & E by an automatic slide stainerⁱ. Selected skin sections were stained with differential stains by hand: Altmann, Periodic Acid Schiff (PAS), Fontana Mason (FM), Trichrome, and Ayoub-Shklar methods were used to differentiate melanin from keratohyaline products^j.

3. Electron Microscopy

Cubed (0.5 mm) sections of skin were placed in cold (4 °C) Karnovsky's^k fixative for four hours, washed in phosphate buffer

e Carbocaine-V HCl (2%), Winthrop Lab, Sterling Drug Co., New York, N.Y.

f Baker's Biopsy Punch, Baker Cummins, Key Pharmaceuticals Inc, Miami, Fla.

g Autotechnicon Ultra II, Technicon Instruments Co., Tarrytown, N.Y.

h Spencer Rotary Microtome, model 820, AO Co., Buffalo, N.Y.

i Miles Lab Tissue-Tek Slide Stainer, model 4446, Ames Co., Elkhart, IN.

j Manual of Histologic Staining Methods of the Armed Forces Institute of Pathology 3rd ed, L.G. Luna, McGraw-Hill, N.Y., 1968.

k Karnovsky, M.J.: A Formaldehyde-Glutaraldehyde Fixative of High Osmolality for Use in Electron Microscopy, J Cell Biol 27:137A, 1965.

and post-fixed in 1% osmium tetroxide for one hour. The small diced fragments of tissue were then washed in buffer, dehydrated in ascending alcohols and then embedded in LX-112 resin¹.

Thick sections (0.5 to 1 microns) were cut from each block^m, stained with toluidine blue and examined by light microscopy to confirm orientation. Ultrathin sections (80 to 100 nanometers thick) were placed on a copper grid, stained with uranyl acetate and lead citrate, and examined by TEMⁿ.

1

Ladd LX-112 Resin, Ladd Research Industries Inc., Burlington, VT.

^m

Sorvall Porter-Blum MT-2 Ultramicrotome, Ivan Sorvall Inc., Newton, CT.

ⁿ

Hitachi Electron Microscope, Model H-300, Nissel Sanyo America Ltd., Mountain View, CA.

III. RESULTS

A. Pedigree Analysis

A survey of the kennels with affected families of WHW revealed no potential environmental causes for the skin problems. These dogs were housed in the same facilities as other breeds and other families of dogs and fed the same diet. The use of drugs or other medication was not reported and the vaccination and worming procedures were routine.

A genealogy chart (Figure 3) involving 12 generations and 100 individuals was constructed. Close examination of this chart revealed 21 (13 males and 8 females) dogs affected, almost all of which were related to three common ancestors (stud dogs V-1, VIII-1 and XI-2). No familial relationships were found between these three individuals.

Ten (3 females and seven males) out of 21 affected dogs were related to stud dog V-1: the three females through their dams (VIII-2 and VIII-3) whom were daughters of his, and a male by his mating to an unrelated dam (II-2). Another male was produced from his mating to III-14 (six out of the ten were also related to this female). Five out of a litter of five were produced by breeding him to IX-10 who was a daughter of III-14 and one of the females in our study. Figure 4 illustrates the pedigree of this stud dog as it relates to the affected individuals.

Ten out of the affected members of this kennel were also traced back to another stud dog (VIII-1) whose pedigree is illustrated in figure 5. Three females out of two separate dams (VIII-2 and VIII-3) were recorded. One of these dams was also bred to stud dog XI-2 and likewise produced an affected pup. Five (4 females and one male) were traced back to three separate

matings between VIII-1 and III-14. Two out of those five (V-5 and IX-10) were full sisters out of the same litter and were part of our research studies. From his two matings with III-15 two affected pups resulted, one from each litter. This dam (III-15) also produced an affected male out of a litter of eight when bred to stud dog XI-2.

Stud dog XI-2 had a full sister who was affected with the disease but he showed no clinical signs of the condition. His pedigree is outlined in figure 6. He was bred to four separate dams, three of which were not affected but had a history of producing affected litters when bred to other stud dogs. One affected pup resulted from each one of these matings, the litter size varied from two (XI-4 was the dam of this litter) to eight (in this case III-15 was the dam).

In addition, it should be noted that two females (III-14 and III-15) whom were full sisters, were bred to these stud dogs in repeated occasions (III-14 to V-1 and VIII-1 and III-15 to VIII-1 and XI-2) and consistently produced affected puppies in every one of these matings. This suggested the possibility that the three stud dogs as well as these two females were carriers of the disease condition.

The information obtained regarding generation pedigrees of this family of West Highland White Terriers provides substantial evidence that seborrhea may be genetically controlled. A familial occurrence was demonstrated in this kennel with a recessive mode of inheritance or a polygenic transmission being likely.

B. Breeding Trial

Three dogs (two females :V-5 and IX-10, and one male VII-9) were originally donated to our project by K-Hill kennels. Skin biopsies revealed histopathological changes compatible with seborrhea and the skin scrapings and cultures were negative. Complete blood counts and serum chemical constituents as well as bile acids and T₃T₄ analyses were all within normal limits except in the male. He showed unusually high bile acid levels and a shift in the T₃T₄ ratio which suggested a potential "sick euthyroid" condition. Semen collection and evaluation revealed his semen to be aspermatic and eventually this male was euthanatized.

The three females (one from Oetinger kennels and two from K-Hill kennels) were then bred to stud dog V-1 and two litters of pups were born in November of 1982. A litter of six resulted from his mating to the Oetinger female and a litter of three was born to dam IX-10. The nine puppies (four females and five males) were randomly assigned numbers for identification purposes (215 through 223).

C. Pathogenetic Studies

Gross Pathological Findings

The puppies were essentially normal until they reached ten weeks of age. At this time they started showing a mild degree of multifocal to generalized hyperpigmentation on the ventral abdominal region (Figure 7). This change was accompanied by the presence of a very dry haircoat and diffuse scaliness. The hypermelanosis varied greatly in it's degree and distribution

between dogs with some showing a marked hyperpigmentation of the inner aural skin.

Two of the puppies (#215 and #220) exhibited more classical signs of seborrhea in separate occasions. Dog #215 was presented in May of 1983 with a severe generalized erythema on the inner thighs and the left axillary area (Figure 8A). The skin showed a thickened appearance and several papules and pustules (0.5-1.0 mm in diameter) were observed. In addition, some encrustations were found on the ventral abdominal area. She was about 27 weeks old when she first showed active lesions of seborrhea. For three consecutive sessions the clinical signs were present but following conservative therapy the condition improved noticeably and no recurrence of clinical signs has been recorded since.

Dog #220 was brought in at one year of age with clinical signs of the disease. Multifocal alopecia and severe erythema accompanied by evidence of pruritus and excoriation were observed at this time (Figures 8B & 8C). Papules and pustules were found on the ventral abdomen in association with a mild degree of pustular folliculitis. This dog recovered without therapy.

A complete necropsy examination was conducted on dog #216. All major organs were closely examined for both gross and microscopic lesions. No significant pathological findings were observed. The skin showed no major gross lesions except for a very dry haircoat and diffuse hyperpigmentation accompanied by moderate scaliness.

Histopathological Findings

Skin biopsies of all nine puppies were examined under light

microscopy and several histologic changes were observed even in the absence of major gross lesions. Dermatohistopathological findings ranged from variable degrees of orthokeratotic and parakeratotic hyperkeratosis to hypergranulosis, hypermelanosis, multifocal acanthosis, follicular keratosis and epidermal dysplasia.

A diffuse orthokeratotic hyperkeratosis was the first lesion observed in these puppies. This histological change was consistently present in almost all the skin tissue sections with a great variability in severity and form being observed. A basket weave pattern (Figure 9B) was more frequent than the lamellar or compact patterns and in some sections the stratum corneum was about ten layers thick. Retention of the nuclei in the superficial layers was the second major microscopic lesion observed. The parakeratotic hyperkeratosis accompanying the orthokeratotic type (these were first noticed simultaneously) started to develop when the puppies were about six weeks old. Figure 9C shows a section of skin with parakeratotic hyperkeratosis.

Patchy or multifocal acanthosis (Figure 9D) was found in association with mild spongiosis or intercellular edema. The desmosomes or intercellular bridges became prominent in those areas exhibiting epidermal edema. In addition, rete ridge formation was observed in several of the skin sections showing multifocal acanthosis.

Another histological lesion observed was hypergranulosis (Figure 9E) or an increase in the thickness of the stratum granulosum. The keratinocytes of the granular layer appeared to

be very active in keratin production as evidenced by an increased accumulation of keratohyaline granules in the superficial epidermal layers.

A greater number of melanocytes was present in most of the sections (Figure 9C). Increased numbers of these cells were found within the deeper layers of the epidermis as well as in the papillary dermal layer. The amount of melanin granules within the keratinocytes was also found to be greater than normal.

One of the major dermatohistopathological alterations was denoted as epidermal dysplasia (Figure 10). From the time they were several weeks old the skin of the puppies started to show the presence of abnormal keratinocytes in the superficial epidermal layers suggesting a developmental disorder of the epidermis. These cells were not maturing normally and retention of the nuclei along with accumulation of keratohyaline granules were noted. The abnormal keratinocytes exhibited a large round eosinophilic cytoplasmic body and tended to aggregate themselves in a disorderly fashion. Isolated "islands" of these abnormal cells were frequently observed surrounded by multiple layers of keratin on the surface of the epidermis. In addition to the presence of abnormal keratinocytes there was a considerable variability in the thickness of the epidermis. In some areas it was only 3 to 5 cell layers thick whereas in other sections of the same slide between 15 and 20 keratinocytes were noted in the epidermis (Figure 10A). The basal keratinocytes of the defective epidermis lacked the typical palisade arrangement. A noticeable increase in the number of basal cells was noticed in some of the

hyperplastic areas of the epidermis (Figure 10F).

Crust formation and microabscessation of the granular and horny layers were evident in a few sections. The crusts were mainly composed of keratinous debris with some cellular (RBC's and neutrophils) and exudative (serous) components accumulating on the surface of the skin. Munro microabscesses were observed in two sections (Figure 11C & 11D) and correlated with the clinical signs of pyoderma presented by dog #215 in one occasion. Both of these histopathological lesions were limited to the skin of the two affected puppies correlating with those sessions in which active clinical signs were recorded.

Poral or follicular keratosis was quite evident in most of the sections (Figures 11A & 11B). The lumen of the hair follicles showed an accumulation of keratinosebaceousapocrine debris which was associated with orthokeratotic and parakeratotic hyperkeratosis of the follicular epidermis. The adnexal epithelium also showed a moderate degree of acanthosis and hypergranulosis in some sections.

The sebaceous glands were found to be essentially normal in most cases. These adnexal structures exhibited a mild degree of vacuolar degeneration in very few sections. No histopathological changes were recorded of the apocrine sweat glands nor the dermis.

Special Histopathological Staining

Selected histopathological sections of skin biopsies taken from the pups and from affected adults were stained with special methods to aid in the differentiation between melanin and keratohyaline products. Increased numbers of both melanin and

keratohyaline granules were confirmed with these methods: Fontana Mason (Figures 12A & 12B) for melanin and Altmann (Figure 13B) and Ayoub-Shklar (Figure 13C) for keratin and pre-keratin products. Periodic Acid Schiff (PAS) and Trichrome stained slides (Figure 12D) revealed periadnexal fibrosis to be quite extensive in the chronic cases.

Skin Cultures

A significant correlation between the pathological findings and the cutaneous microflora could not be established. A variable number of bacterial colonies were inconsistently isolated and subsequently identified as:

1. non-hemolytic coagulase positive Staphylococcus aureus
2. Double zone hemolytic coagulase positive Staphylococcus aureus
3. Staphylococcus epidermidis
4. Bacillus sp.

Electron Microscopic Findings:

For adequate keratinization to occur the keratinocyte must contain, in adequate amounts, both tonofilaments and a cementing substance to bind the filaments. The tonofilaments of the spinous cells were densely aggregated and relatively abundant. Their plasma membrane was thrown into numerous folds and the intercellular desmosomes were quite evident. The filaments were arranged in bundles at their attachment to the cytoplasmic side of the desmosomes and were distributed in a random fashion within the rest of the cell. In addition, many cells exhibited double nucleoli (Fig. 15A & 15B) which may be suggestive of increased mitotic activity and/or protein synthesis within the keratinocyte

both of which were observed in light microscopy (as evidenced by acanthosis and hypergranulosis). Finally, numerous melanosomes were noticed in the paranuclear region of the keratinocytic cytoplasm (Fig 15B & 15C) as membrane bound granules.

In the stratum granulosum electron dense, irregularly shaped, keratohyaline material was present in significant amounts. The granules were located throughout the cytoplasm and were increased in size and number, being deposited around and in between the tonofilaments (Fig 16A & 16B). This second important component of epidermal cells (the first being the tonofilaments) is the matrix or cementing substance. Since it reacts strongly with osmium tetroxide this material is speculated to contain sulfur.

Several abnormal cells were observed in the stratum corneum. These cells retained many of the membrane bound granules and their nuclei was still present (Fig 16C & 16D). Finally, most of the horny keratinocytes showed a markedly striated cytoplasmic membrane probably due to the excess keratin production characteristic of this disease.

IV. DISCUSSION

The seborrheic disease is characterized by altered keratinization with variable degrees of sebaceous and/or apocrine gland involvement. Many skin conditions which vary widely in form and intensity, from simple dandruff to severe erythematous and crusty, scaly lesions, are clinically diagnosed as seborrhea(1,3,10). Generalized scaling, crusting and alopecia with variable degrees of pyoderma, pruritus and self-trauma are the primary clinical signs.

The etiology of primary seborrhea is disputed but familial factors are speculated to be involved. Many investigators (1,2,3,4,16) have reported an inherited tendency toward functional disorders of keratinization and sebaceous glands in certain breeds of dogs. However, the literature review revealed no research conducted on this subject to provide a scientific evidence for this statement.

In this project genealogy studies of a particular family of West Highland White Terriers affected with this condition was conducted. The information obtained regarding generation pedigrees of this family of dogs provided substantial evidence to support the fact that seborrhea may be genetically controlled. A familial occurrence was demonstrated in this kennel with a polygenic inheritance or a recessive mode of transmission being likely involved. In addition, the disease occurred independent of season or management methods in the kennels.

Developmental disorders might evolve from genetic or environmental disruptive influences or from a complex interaction between both group of factors. Genetic transmission results from single gene defects, multifactorial polygenic inheritance,

chromosomal abnormalities, teratogenic influences or from unidentified causes. Polygenic inheritance is due to small but additive effects of many genes whose phenotypic expression is greatly affected by small, usually undefined, changes in the environment(5). Practically all polygenic traits can be influenced in some degree by various factors in the environment(9) .

Recessive mutations in dogs are more common than dominant ones. This pattern of inheritance involves two phenotypes (normal and abnormal) and three genotypes (SS, Ss and ss). Expression of the defect as evidenced by development of clinical signs occurs in the homozygous dog receiving one mutant gene, each from sire and dam. In most cases we found parents to be phenotypically normal and heterozygous (Ss) or "carriers" of the defective gene. As these animals are phenotypically normal, it is not known whether an animal is heterozygous or not until puppies affected with seborrhea appear in some litter. In these cases (Ss X Ss), the proportion of seborrheic puppies in their progeny should be about 25% and the chance of any pup getting the defective gene s from his sire is 1 in 2; from his dam, 1 in 2; and from both, 1 in 4 (9).

In 13 such litters from both parents both carriers there were 61 pups altogether, so, if the defect were a simple recessive trait the ratio theoretically expected was 15.25 seborrheic: 45.75 normal. Actually the ratio observed was 18:43. The slight excess of affected puppies is not significant as such an excess is to be expected when ratios are counted for only the

litters (or families) in which at least one pup is affected.

Furthermore, there were two litters produced by the mating of an affected (V-5 and IX-10) dam with potential carriers (V-1 and XI-2 respectively). In these litters all the progeny should get *s* from their seborrhic dam but only about half the progeny will get *S* from the phenotypically normal sire. In theory, the ratio expected out of such matings is 1:1. From two such litters the actual ratio observed was 2 normal : 6 seborrhic instead of 4:4. Again, an increase in the number of affected dogs was recorded. The reason for this slight deviation from expected relies in the fact that random fertilization of gametes is assumed for calculating these expected ratios. This means that just as many gametes carrying *S* should fertilize eggs as do gametes carrying *s*. However, in nature those gametes are never counted out in equal numbers and, by chance alone, there are deviations from the 1:1 ratio expected(9).

In the breeding trials we mated one affected (*ss*) and one carrier (*Ss*) female to a heterozygous male (*Ss*). Out of *Ss* X *ss* mating (V-1 and Oetinger female) two out of a litter of six puppies (dogs #215 and #220) came out to be phenotypically affected. The expected ratio was 3:3. In the mating of carrier X carrier (V-1 X IX-10) about 25% of the progeny was expected to show clinical signs (or one out of a litter of four). In the study none out of a litter of three turned out to be phenotypically affected.

Multifactorial polygenic inheritance involves additive effects of many minor genes and subtle environmental influences. Simulation of autosomal recessive inheritance coupled with a

variable expressivity and incomplete penetrance of the defective gene(s) involved in this syndrome would be consistent with, but not proof of, polygenic inheritance of seborrhea in the WHW breed.

The question of how much deviation from our expectations we can accept as likely being due to chance leads us to consider the chi-square (χ^2) test (6). This is a mathematical tool to determine "goodness of fit" and will enable us to make a judgement in this question. Table 5 illustrates this principle and its application to the data obtained. Based on the P values obtained we can expect a deviation as large or larger than we experienced in 99% of the repeated trials for our Ss x ss mating. On the other hand, for the mating between two heterozygotes (Ss X Ss) we can expect between 50 and 70% of repeated trials to show such a deviation from what was expected. Such a deviation could, therefore, readily be due to chance and the data obtained is compatible with a simple autosomal recessive mode of transmission for the defective gene s.

Histopathological lesions of seborrhea are not diagnostic for the condition. The results recorded from the microscopic examination of skin biopsies closely correlates with those observed by other investigators. However, epidermal dysplastic changes suggestive of a keratinocytic developmental disorder were found to be quite prevalent in these tissue sections. Light microscopy studies revealed significant abnormalities of the seborrheic keratinocytes. The basal cells lacked their typical palisade arrangement and there was a great variation in the

thickness of the epidermis within the same section. These pathological alterations, particularly the presence of abnormal aggregates of defective keratinocytes on the surface of the epidermis, were not found to be recorded in previous studies.

In active lesions of seborrhea the epidermopoietic rate is markedly accelerated; however, it is not fully established by which this excessive replication rate comes about(12). This rapidly accelerated replication rate may hold the key to the etiopathogenetic mechanisms which might be involved in the development of abnormal keratinocytes in seborrheic skin.

It is concluded in this study that seborrhea is genetically controlled in the West Highland White Terrier breed. Characteristics of both simple autosomal recessive and polygenic inheritance were observed. However, the exact mode of transmission remains undefined. Extensive breeding trials and further field studies, complemented with genealogy analyses, in cooperation with the dog breeders are necessary to confirm the significance of heritability factors and their mode of expression in the etiology of primary idiopathic seborrhea in the West Highland White Terrier breed. Additional experimental studies are likewise essential to provide more light in the elucidation of aberrant developmental mechanisms involved in the pathogenesis of seborrheic lesions.

V. SUMMARY

Four kennels with a history of having families of West Highland White Terriers with seborrhea were visited. The breeding records of a particular family of dogs were carefully reviewed and a complete genealogy chart involving one hundred dogs and twelve generations was constructed. Breeding trials using members of this family of dogs were performed and the nine puppies (two litters) obtained were then utilized for the pathogenetic studies. Skin biopsies and skin cultures were done on the pups until they were nine months old. Photographs of the gross lesions were taken on a monthly basis.

The pedigree analysis revealed substantial evidence that this disease condition may be genetically controlled. In the particular kennel involved a familial occurrence of seborrhea was demonstrated with a polygenic transmission and/or an autosomal recessive mode of inheritance being likely. In the matings recorded between heterozygotes and homozygotes as well as in those where two heterozygotes were crossed the phenotypic and genotypic frequencies observed closely correlated with what was expected. The same close correlation was observed when the breeding trials were performed. In addition, when the chi-square test was applied to the data obtained it was demonstrated that the deviations from what was expected for our breeding trials could readily be due to chance. Therefore, the data obtained was highly compatible with a simple autosomal recessive mode of transmission for the defective gene s.

The gross pathological findings were limited to a mild to moderate multifocal to generalized hyperpigmentation on the ventral abdominal region accompanied by a very dry haircoat and

diffuse scaliness. Two dogs out of the litter of six showed clinical signs of the disease condition in several occasions. The pathological findings in these cases were a diffuse erythema, multifocal alopecia, excoriation, pruritus, crust formation and papules and pustules in some areas of their body.

Histopathological changes observed were characteristic of the condition, namely, orthokeratotic and parakeratotic hyperkeratosis as well as patchy acanthosis, hypermelanosis, hypergranulosis and follicular keratosis. Epidermal dysplastic changes characterized by a great variability in the thickness of the epidermis within the skin sections and the presence of abnormal keratinocytes at all levels of the epidermis were found to be quite prominent in the skin biopsies examined. These pathological alterations started to appear very early (when the pups were several weeks old) in the course of the pathogenetic studies sessions. In addition, the skin of the two phenotypically affected dogs showed crust formation accompanied by intraepidermal pustular dermatitic changes correlating with the clinical signs observed. The sebaceous glands exhibited mild degenerative changes as evidenced by some degree of vacuolation in very few sections. The apocrine sweat glands as well as the dermis were found to be essentially normal in the great majority of the sections. An increased amount of melanin and keratohyaline granules were demonstrated throughout the epidermal layers with the use of special staining methods, particularly Fontana Mason, Altmann and Ayoub-Shklar stains. PAS and Trichrome stains were conducted on selected histopathologic sections to demonstrate the severe degree of periadnexal fibrosis

observed in the skin of the chronically affected adults.

Finally, a significant correlation between the skin cultures results and the gross and histological findings could not be established. Therefore, the isolation of pathogenic staphylococcal bacteria was considered to be a secondary change in the pathogenesis of seborrhea and not a major mechanism in the development of the diseased skin to begin with.

It was concluded that seborrhea is genetically controlled in the West Highland White Terrier breed but the exact mode of transmission remains undefined. Extensive breeding trials and further field studies coupled with genealogy analyses should be conducted to confirm the significance of heritability factors and their mode of transmission in the etiopathogenesis of this disease complex in the WHW breed. Additional research studies are likewise essential to elucidate aberrant developmental mechanisms which could possibly be involved in this skin disorder.

VI. REFERENCES

1. Austin, V.H.: A Clinical Approach to Abnormal Keratinization Diseases of the Dog. Comp Cont Ed 5(11):890-898, 1983.
2. Austin, V.H.: Congenital Seborrhea of Springer Spaniels. Mod Vet Pract 54(4):53-55, 1973.
3. Austin, V.H.: Sebopsoriasis in the Dog. Mod Vet Pract 55(5):379, 1974.
4. Austin, V.H.: The Skin In: Canine Medicine, pp.1207-1209, 1222-1226. American Veterinary Publications, Santa Barbara, 1979.
5. Barkyoub, S.D.: Nature and Cause of Bilateral Ocular Dermoids in Hereford Cattle. Doctoral dissertation, Kansas State University, Manhattan, Kansas, 1983.
6. Burns, G.W.: Probability and Goodness of Fit In: The Science of Genetics 3rd ed, pp.110-114. Macmillan Publishing Co., New York, 1976.
7. Dorland's Illustrated Medical Dictionary 25th ed, W.B. Saunders, Philadelphia, 1974.
8. Graham, J.H., Johnson, W.C. and Helwig, E.B.: Dermal Pathology, pp. 1-46, 119-135. Harper & Row, Hagerstown, 1972.
9. Hutt, F.B.: Principles of Genetics In: Genetics for Dog Breeders, pp.7-19, 58-61. W.H. Freeman and Co., San Francisco, 1979.
10. Irhke, P.J.: Canine Seborrheic Disease Complex. Vet Clin North Am (Small Anim Pract) 9(1):93-106, 1979.
11. Karnovsky, M.J.: A Formaldehyde-Glutaraldehyde Fixative of High Osmolality for Use in Electron Microscopy. J Cell Biol 27:137A, 1965.
12. Lever, W.F. and Schaumburg-Lever, G.: Histopathology of the Skin 6th ed, pp.3-14, 99, 476-481. J.B. Lippincott, Philadelphia, 1983.
13. Luna, L.G. ed.: Manual of Histological Staining Methods of the Armed Forces Institute of Pathology 3rd ed. McGraw-Hill, New York, 1968.
14. McManus, J.F.A. and Mowry, R.W., ed.: Staining Methods - Histologic and Histochemical. Harper & Brothers, New York, 1960.
15. Milne, J.A.: An Introduction to the Diagnostic Histopathology of the Skin. pp.86, 89-93. Williams and Wilkins Co., Baltimore, 1972.

16. Muller, G.H., Kirk, R.W. and Scott, D.W.: Small Animal Dermatology 3rd ed. pp.1-88, 605-613. W.B. Saunders, Philadelphia, 1983.

VII. APPENDICES

A. LITERATURE REVIEW - TABLES

TABLE 1. ETIOLOGICAL CLASSIFICATION OF SEBORRHEA

- I. Primary Idiopathic Seborrhea
- II. Primary Metabolic Seborrhea
 - A. Endocrine-Related
 - 1. hypothyroidism
 - 2. gonadal aberrations
 - 3. Cushing's disease (hyperadrenocorticism)
 - 4. pituitary dwarfism (hyposomatotropism)
 - 5. diabetes mellitus
 - B. Aberrations in Lipid Availability
 - 1. dietary deficiencies (fat, protein, zinc, vitamin A)
 - 2. maldigestion/malabsorption (intestinal, pancreatic, hepatic)
 - 3. defects in fat metabolism ("fat responsive")
- III. Secondary Seborrhea
 - A. Allergy/Hypersensitivity and Drug-Eruption
 - B. Dermatophytosis
 - C. Ectoparasitism
 - 1. pediculosis
 - 2. demodecosis
 - 3. scabies
 - 4. cheyletiellosis
 - 5. flea infestation
 - D. Endoparasitism
 - 1. dirofilariasis
 - 2. intestinal parasitism
 - E. Immune-Mediated
 - F. Malignancies/Neoplasia
 - G. Pyoderma and Bacterial Hypersensitivity
 - H. Others
 - 1. any chronic catabolic state
 - 2. local trauma or irritants
 - 3. environment (dry heat)

*Modified from Muller, Kirk and Scott: Small Animal Dermatology
3rd ed. W.B. Saunders pp.606 Philadelphia, 1983.

TABLE 2. SKIN LIPID COMPONENTS (mean percentages) of Canine Skin

	Total labile fatty acids*	Diester waxes	Total chol- esterol**
Normal skin	3.45	48.19	48.45
Seborrhea sicca	12.20	32.20	54.82
Seborrhea oleosa	7.57	38.05	54.31

* fatty acids, mono, di and triglycerides.

**free cholesterol and cholesterol esters.

Obtained from Ihrke, P.J. and Horwitz, L.N.: Canine Seborrhea.
In: Current Veterinary Therapy VI - Small Anim Pract, ed. R.W.
 Kirk, pp.519-524. W.B. Saunders, Philadelphia, 1976.

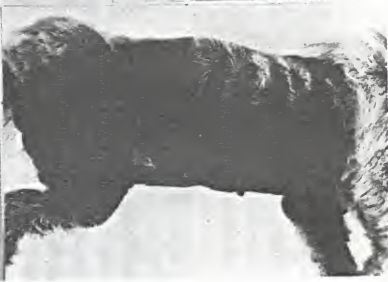TABLE 3. INCIDENCE AND COMPOSITION OF THE CUTANEOUS MICROFLORA
IN THE DOG

<u>Microbial Groups</u>	Group I Control		Group II Seborrheic dogs	
	I*	F**	I*	F**
Aerobes:				
<u>Staph aureus</u>	0	0	63	97
Coag neg cocci	100	89	38	86
Sporeformers	0	0	19	35
Diphtheroids	23	34	9	6
Gm neg rods	0	0	3	0.01
Anaerobes:				
<u>Clostridium sp.</u>	60		34	
* % incidence				
** % of the microflora when present				

From Irhke, P.J.: Microbiology of Normal and Seborrheic Canine Skin. Am J Vet Res 39(9):1487-1489, 1978.

B. LITERATURE REVIEW

CLINICAL AND HISTOPATHOLOGICAL FEATURES OF SEBORRHEA



A |
—| B
C |
—| D

Fig. 1: Gross cutaneous lesions observed in chronic primary idiopathic seborrhea in the dog.

- A. Generalized pyosebopsoriasis in a male Scottish Terrier showing severe alopecia, crust formation, lichenification and hyperpigmentation.
- B. A close-up view of the same patient. Notice the extremely thickened and corrugated skin.
- C. Chronic primary seborrheic dermatitis in a West Highland White Terrier. Note the alopecia, excoriation and focal erythematous plaques (arrows).
- D. Same dog exhibiting extreme hypermelanosis, lichenification and generalized alopecia.

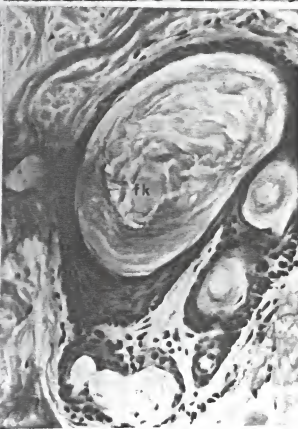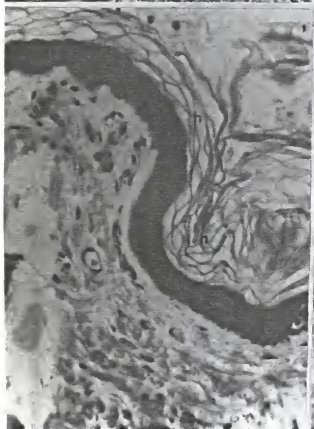
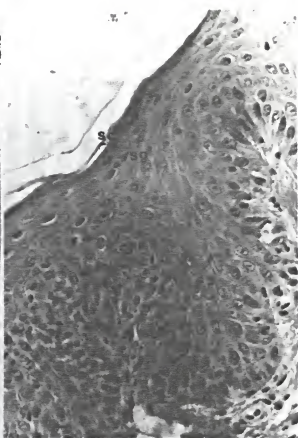
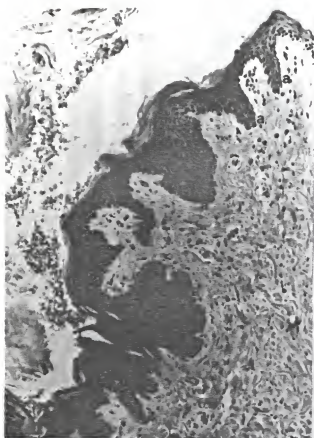




Fig. 2.: Dermathistopathological lesions of seborrhea in dogs.

- A. Photomicrograph of a skin biopsy showing extremely prominent rete ridge formation (a) and multifocal epidermal hyperplasia.
- B. A close-up view of the acanthotic skin where various maturing stages of the epidermal keratinocytes can be easily recognized. (sb: stratum basale, sa: stratum spinosum, ag: stratum granulosum, sc: stratum corneum).
- C. Orthokeratotic hyperkeratosis(h) in a basket weave pattern is one of the major histopathological changes observed in this abnormal keratinization disorder.
- D. Extensive follicular keratosis (fk) as shown in many seborrheic cases. Acanthosis and hypergranulosis of the adnexal epithelium is also evident.

C. MATERIALS AND METHODS - TABLE 4

DEPT. OF PATHOLOGY - COLLEGE OF VETERINARY MEDICINE - KSU
 PATHOGENETIC STUDIES OF CANINE SEBORRHEA IN THE WEST HIGHLAND WHITE BREED - BREEDING TRIAL

DOG ID NO. _____ AGE _____ SEX: M / F BODY WEIGHT _____ DATE _____ NO _____
 SLIDE NO _____

① GROSS LESIONS: present / not present

	GENERALIZED	LOCALIZED	MILD	MODERATE	SEVERE
scaliness					
dry haircoat					
hyperpigmentation					
alopecia					
crust formation					
ceruminous otitis					
pyoderma (papules, pustules)					

① HISTOPATHOLOGICAL CHANGES: present / not present

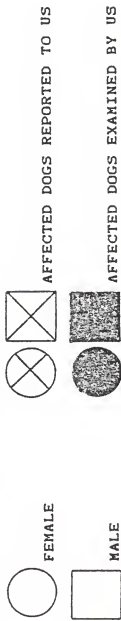	GENERALIZED	LOCALIZED	MILD	MODERATE	SEVERE
hyperkeratosis					
parakeratosis					
dyskeratosis					
hyperpigmentation					
accumulation of ke- ratohyaline granules					
follicular plugging					
epidermal atrophy					
epidermal inclusion cysts					
involvement of seba- ceous +/- apocrine sweat glands					
acanthosis					
intracellular edema					
spongiosis					
inflammatory cells pre- sent					
papillary dermal fibrosis					

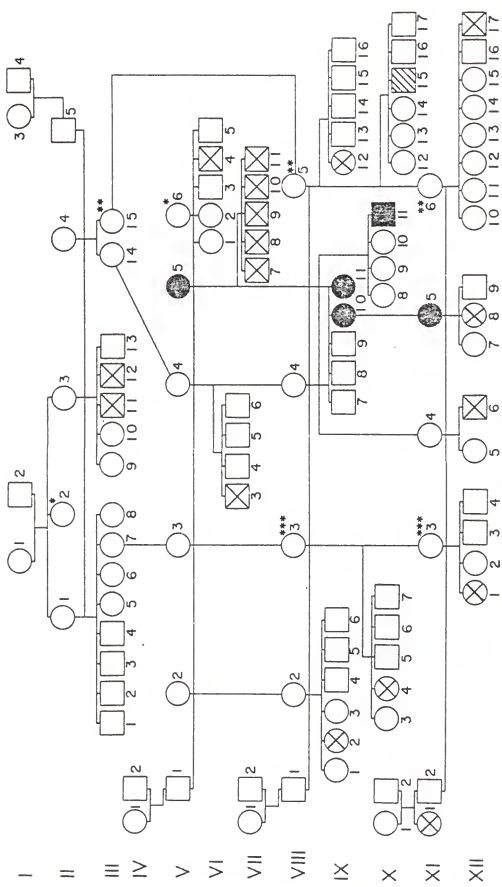
① CULTURE RESULTS:

* additional information to be recorded on the back of the form.

D. GENEALOGY CHART AND PEDIGREES

Figure 3: Genealogy chart of a family of West Highland White
 Terriers with seborrhoea. Twelve generations are involved with
 twenty one out of one hundred individuals affected. Circles
 denote the females and squares the males.





- I
- II
- III
- IV
- V
- VI
- VII
- VIII
- IX
- X
- XI
- XII

Figure 4: PEDIGREE 1

Ten (three females and seven males) out of twenty one affected dogs were related to stud dog V-1: the three females through their dams (VIII-2 and VIII-3) whom were daughters of his, and a male by his mating to an unrelated dam (II-2). Another male was produced from his mating to III-14. (Six out of the ten were also related to this female.) Five out of a litter of five males were produced by breeding him to IX-10 who was a daughter of III-14 and one of the females in our study.

Fig. 4 Pedigree 1: Stud dog V-1

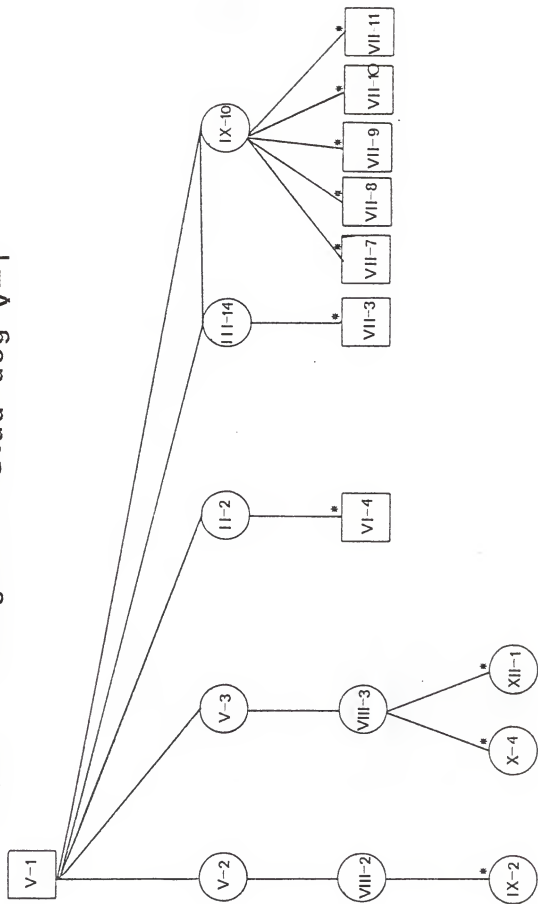


Figure 5: PEDIGREE 2

Ten of the affected dogs were traced back to stud dog VIII-1: three females out of two separate dams (VIII-2 and VIII-3). Five (four females and one male) were traced back to three separate matings with III-14. Two of those five (V-5 and IX-10) were full sisters out of the same litter and part of our breeding trials. From his two matings with III-15 two affected puppies resulted, one out of each litter.

Fig. 5 Pedigree 2: Stud dog VIII-1

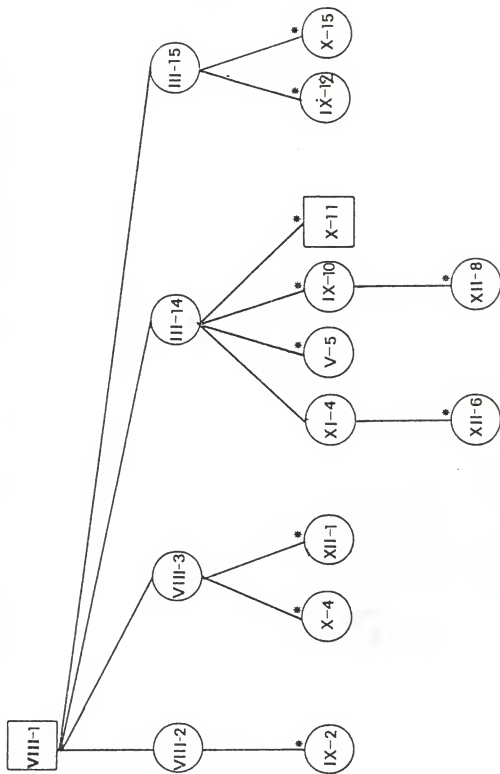
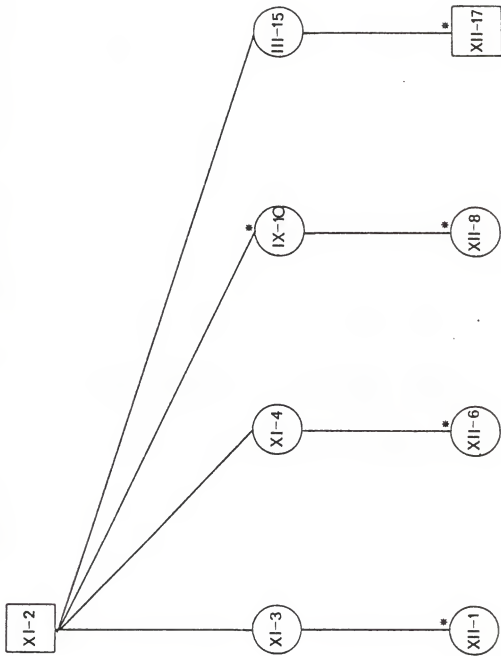


Figure 6: PEDIGREE 3




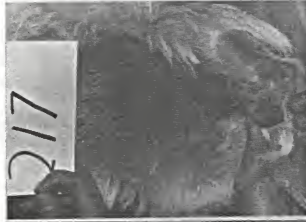

Stud dog XI-2 had a full sister who was affected but he showed no signs of the disease. He was bred to four separate dams, three of which were not affected but had a history of producing affected litters when bred to other stud dogs. One affected dog resulted from each mating, the litter size varying from two (XI-4 was the dam) to eight (in this case III-15 was the dam).

Fig. 6 Pedigree 3: Stud dog XI-2



E. PATHOGENETIC STUDIES

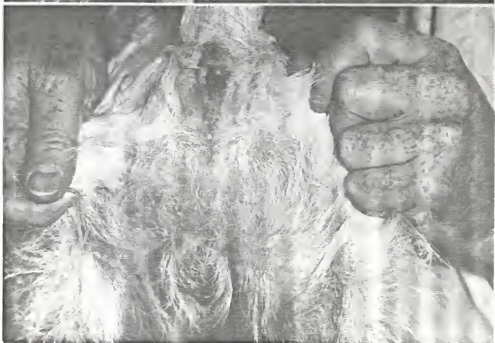
PHOTOGRAPHS OF GROSS PATHOLOGICAL FINDINGS



A	B	C	D
E	F	G	H

Figure 7:

THE VENTRAL ABDOMINAL AREAS OF THE PUPPIES SHOWED MODERATE TO SEVERE HYPERPIGMENTATION IN A DIFFUSE PATTERN. THIS GROSS PATHOLOGICAL LESION WAS ASSOCIATED WITH SOME SCALINESS AND A VERY DRY HAIRCOAT.



A

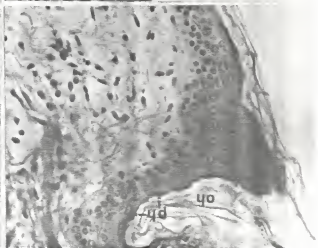
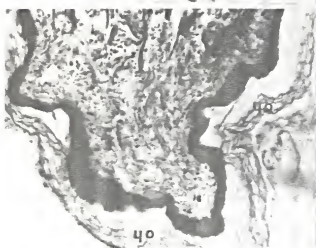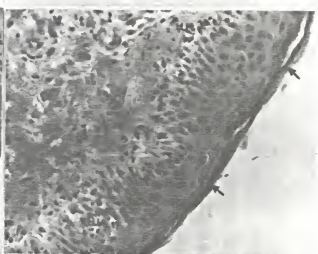
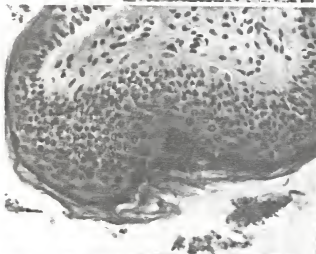

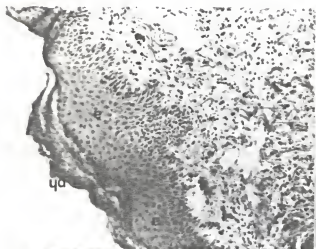B

C

Figure 8: Gross lesions of seborrhea as shown by two of the puppies during the pathogenetic studies sessions.

- A. Dog #215 showing severely erythematous patches on the inner thigh accompanied by maculopapular formations.
- B. Evidence of pruritus, excoriation and pyoderma were observed in the abdominal and inguinal regions of dog #220.
- C. A view of the perineal area of the same dog exhibiting multifocal alopecia and generalized erythema.


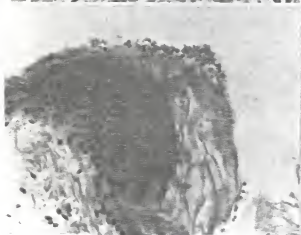
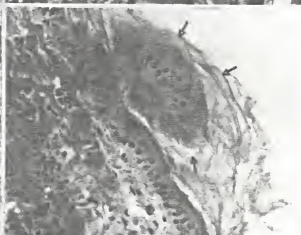
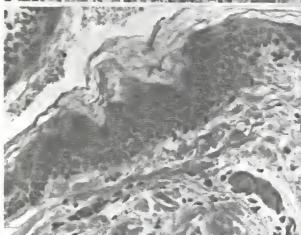
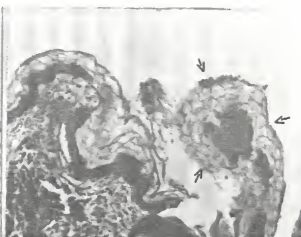
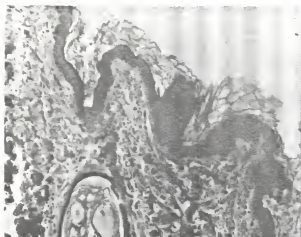
F. PATHOGENETIC STUDIES
SELECTED PHOTOMICROGRAPHS OF HISTOPATHOLOGICAL LESIONS
H & E AND SPECIAL STAINS



A	B
C	D
E	F

Figure 9: Selected photomicrographs showing the major microscopic changes observed upon the histopathological examination of the skin biopsies.

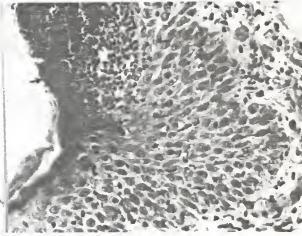
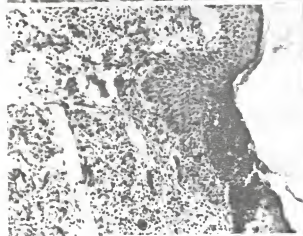
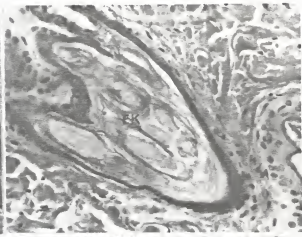
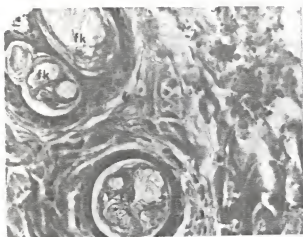
- A. Orthokeratotic (oh) and parakeratotic (ph) hyperkeratosis were consistently present in the skin sections. Note how the keratinocytes have lost their orderly arrangement.
- B. Orthokeratotic hyperkeratosis (oh) in a basket weave pattern was the most frequently observed histological lesion.
- C. Parakeratotic hyperkeratosis (arrows) as well as hypermelanosis (increased number of melanocytes - m) are evident in this section.
- D. This photomicrograph shows patchy acanthosis, hypergranulosis, and hypermelanosis as well as an accumulation of keratohyaline granules in the upper layers.
- E. Close-up view of hypergranulosis. The granular keratinocytes (gk) appear to be very active in keratin formation.
- F. Acanthosis (a) or epidermal hyperplasia and parakeratosis (ph) are present in this section.



A	B
C	D
E	F

Figure 10: Epidermal dysplastic changes suggesting a keratinocytic developmental disorder were frequently observed.

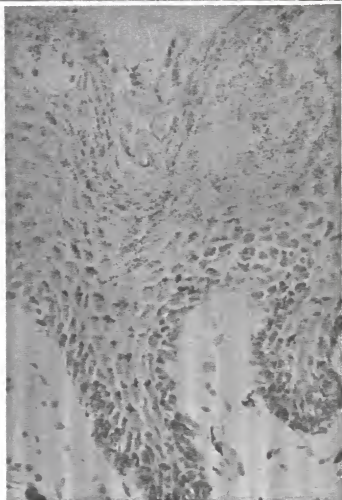
- A. This section shows the severe variability in epidermal thickness noted in these skin biopsies. In some areas it was 15 to 20 cell layers thick (1) whereas in others it was 3 to 5 cell layers thick (2).
- B. "Islands" of abnormal keratinocytes surrounded by keratin (arrows) were evident in many sections, again indicating an abnormal epidermal development.
- C. This photomicrograph shows the presence of the defective keratinocytes which were frequently observed. Notice the lack of parallel arrangement of the basal keratinocytes.
- D. A view of another group of these keratinocytes (arrows). These abnormal cells were large, rounded and tended to retain their nuclei and accumulate keratohyaline granules.
- E. Some sections of the epidermis were markedly hyperplastic with the keratohyaline granules being quite prominent (arrows) in the superficial layers.
- F. A noticeable increase in the number of basal cells (arrows) was evident in those areas of the epidermis which were becoming hyperplastic.



A	B
C	D

Figure 11: Selected photomicrographs of dermatohistopathological lesions.

- A. & B. Two views showing follicular keratosis (fk) as was observed in many sections. The accumulation of keratinous debris was attributed to an increased production by the follicular epithelial cells.
- C. Munro microabscesses were noticed in the superficial epidermal layers (arrows) in those sections of skin exhibiting pyodermal lesions grossly. This section was taken from dog #220 at the time she was presented with clinical signs of seborrhea.
- D. A close-up view of the previous photomicrograph showing the aggregation of degenerate neutrophils within the stratum corneum and stratum granulosum.

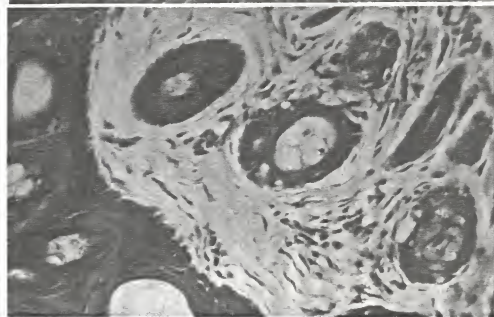



A

B

Figure 12: Selected histopathological sections stained with special methods.

A. & B. Fontana Mason stained sections demonstrated an increase in melanin granules (brownish black) contained in the keratinocytes within all epidermal layers. This is a silver method based on the argyrophilic characteristic exhibited by melanin granules.





A

B

C

Figure 13: Selected photomicrographs of special histopathological stains.

- A. & B. Periodic Acid Schiff (PAS) stain showing the extreme hypermelanosis (melanin granules appear brownish black and are more prominent in the deeper layers of the epidermis) as compared to the increased amount of keratohyaline granules which stain magenta to deeply basophilic in color (in the superficial epidermal layers).
- C. Trichrome's method was also used to accentuate the fibrous tissue deposition surrounding the sebaceous glands (periadnexal fibrosis).



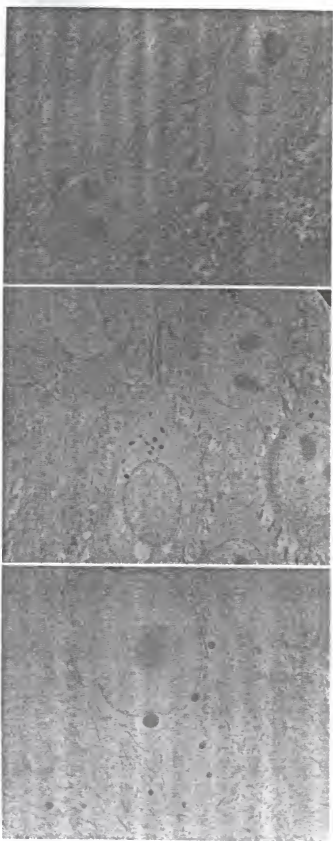
A

B

Figure 14: Special histopathological staining for keratin and pre-keratin products.

- A. Altmann stain - keratin appears orange to magenta in color. This section exhibits the extreme orthokeratotic hyperkeratosis as present in all the skin biopsies of chronically affected individuals.
- B. Ayoub-Shklar method for keratin (deep orange to red) and pre-keratin (paler orange) products. Stratified squamous epithelium stains bluish gray in color.

G. SELECTED TRANSMISSION ELECTRON MICROSCOPIC
FEATURES OF SEBORRHEIC SKIN



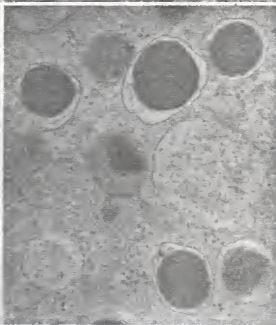
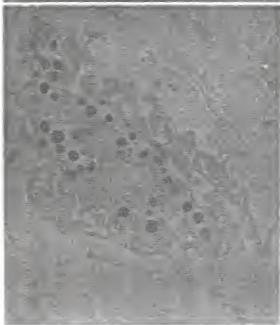
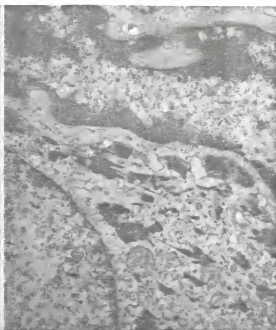A

B

C

Figure 15: Selected electron microscopy photographs of the keratinocytes in the stratum spinosum.

- A. This photograph illustrates the presence of double nucleoli in the nuclei as was observed in many keratinocytes. This suggested the possibility of increased mitotic activity and/or protein synthesis within these cells.
- B. Melanosomes were present in significant amounts within the epidermal cells. These membrane bound granules tended to aggregate in a paranuclear position.
- C. Another view of the same area in the epidermis showing the increased amount of tonofilaments and melanosomes observed in the electron microscopy studies.



A	B
C	D

Figure 16: Electron microscopy findings in the granular and horny layers of the seborrheic epidermis.

- A. The keratinocytes of the stratum granulosum exhibited increased amounts of the keratohyaline material within their cytoplasm as well as a marked degree of granularity.
- B. This photograph shows a closer view of the irregularly shaped and electron dense keratohyaline material. This is the matrix or cementing substance which binds the tonofilaments within the epidermal cells.
- C. Abnormal cell observed at the level of the stratum corneum. These cells tended to retain their membrane bound granules and their nuclei was still present.
- D. A higher magnification (30,000 X) of the membrane bound granules present in these cells. Both melanin and keratohyaline products appear to be contained in them.

H. CHI-SQUARE TEST - TABLE 5

TABLE 5. THE CHI-SQUARE TEST*

The formula is $\chi^2 = \sum \left[\frac{(o-c)^2}{c} \right]$

where,

o = observed frequencies

c = calculated or expected frequencies

Σ = indicates that the bracketed quantity is to be summed for all classes.

I. For Ss X as mating (Oetinger female X V-1):

o = 2 puppies were affected out of 6

c = 3 (we expected a ratio of 3:3)

$$\text{so, } \chi^2 = \left[\frac{(2-3)^2}{3} \right] = 0.33$$

For DF (degrees of freedom = n-1) = 5 we obtain P=0.99.

That is, we can expect a deviation from what was expected to be as large or larger than what we obtained in 99% of the repeated trials.

II. For Ss X Ss mating (IX-10 X V-1):

o = 0 (none out of three were affected)

c = 0.8 (we expected less than 1 pup to show signs of the disease)

$$\text{so, } \chi^2 = \left[\frac{(0-0.8)^2}{0.8} \right] = 0.8$$

For DF=2, we obtain a P value in between 0.50 and 0.70.

That is, we can expect between 50 and 70% of the repeated trials to show such a deviation from what was expected.

*Obtained from Burns, G.W.: Probability and Goodness of Fit In: The Science of Genetics 3rd ed., pp. 110-114. Macmillan Publishing Co., New York, 1976.

PATHOGENETIC STUDIES OF CANINE SEBORRHEIC SKIN
DISEASE IN THE WEST HIGHLAND WHITE TERRIER BREED

by

Janet Jimenez Raczkowski

B.S., Kansas State University, 1982

D.V.M., Kansas State University, 1984

AN ABSTRACT OF A THESIS

submitted in partial fulfillment of
the requirements for the degree

MASTER OF SCIENCE

Department of Pathology
College of Veterinary Medicine
KANSAS STATE UNIVERSITY
Manhattan, Kansas

1984

Seborrhea can be defined as a defect in the keratinization process associated with both qualitative and quantitative changes in the pilosebaceous apparatus with or without disturbances in the function of the apocrine sweat glands. A variety of clinical forms exist with generalized scaliness, alopecia and crust formation being the main clinical signs. Metabolic disturbances and many other unrelated disease processes may be causes of seborrhea, but idiopathic seborrheic conditions are also well recognized. Dermatohistopathology is not diagnostic and the microscopic changes observed resemble those of a chronic dermatitis.

Hereditary predisposition to this disease complex in certain families of dogs has received little attention. Therefore, this study was designed for the purpose of evaluating the significance of hereditary factors in the etiology of this condition as well as studying the pathogenetic characteristics of this disease complex.

Four kennels with a history of having families of West Highland White Terriers with seborrhea were visited. Breeding records of a family of dogs were reviewed and a complete genealogy chart was constructed on 100 dogs involving 12 generations. Breeding trials using members of this family of dogs were performed and the two litters (nine puppies) obtained were then utilized for the pathogenetic studies until they were nine months old. Skin biopsies and skin cultures were done at two week intervals and photographs of the gross lesions were taken on a monthly basis.

Analysis of the family of dogs involved revealed substantial

evidence that seborrhea may be genetically controlled. A familial occurrence was demonstrated in this particular kennel with a recessive mode of inheritance or a polygenic transmission being likely.

Gross pathological findings in seven out of the nine dogs were limited to a variable degree of multifocal to generalized hyperpigmentation accompanied by a dry haircoat and diffuse scaliness. Two dogs exhibited more classical signs of the disease (generalized erythema, excoriation, pruritus, patchy alopecia and papulopustular formations) in several occasions but these regressed following conservative therapy.

Histologically all nine dogs exhibited a moderate to marked orthokeratotic and parakeratotic hyperkeratosis accompanied by diffuse follicular keratosis. Epidermal dysplasia, acanthosis, hypergranulosis and hypermelanosis were also observed. Cellular and hemorrhagic crust formation associated with microabscessation in the superficial layers of the epidermis were present in some sections. The latter changes correlated with the clinical signs showed by the two mostly affected dogs mentioned previously. In some instances the sebaceous glands were involved showing some vacuolation and mild degenerative changes. Periadnexal fibrosis was evident in the more chronic cases. No primary histopathological changes were observed in the apocrine sweat glands.

A significant correlation between the cutaneous microflora and the skin lesions could not be established. A variable number of bacterial colonies were inconsistently isolated with the great majority being non-hemolytic and double zone hemolytic coagulase

positive Staphylococcus aureus. Staphylococcus epidermidis and some Bacillus sp. were also isolated.

The clinical and pathological aspects of canine seborrhea have been well described in the veterinary literature but more research is definitely needed. Elucidation of the pathological changes leading to this condition as well as evaluation of other factors which might be involved in the process will be of great benefit to our profession and the animal population we serve. Early identification of those individuals that may be born with the predisposition to develop this condition would be of great value in preventive medicine programs and selective breeding.

positive Staphylococcus aureus. Staphylococcus epidermidis and some Bacillus sp. were also isolated.

The clinical and pathological aspects of canine seborrhea have been well described in the veterinary literature but more research is definitely needed. Elucidation of the pathological changes leading to this condition as well as evaluation of other factors which might be involved in the process will be of great benefit to our profession and the animal population we serve. Early identification of those individuals that may be born with the predisposition to develop this condition would be of great value in preventive medicine programs and selective breeding.