

CHOLESTEROL PATHOLOGY IN THE RABBIT

by

MARIE MAGDALENE HILDEBRAND

B. A., Concordia College, 1964

---

A MASTER'S THESIS

submitted in partial fulfillment of the

requirements for the degree

MASTER OF SCIENCE

Department of Zoology

KANSAS STATE UNIVERSITY

Manhattan, Kansas

1967

Approved:

*H. T. Gier*

Major Professor

LD  
2602  
TH  
1967  
NS

## TABLE OF CONTENTS

INTRODUCTION.....	1
LITERATURE REVIEW.....	2
METHODS AND MATERIALS.....	13
RESULTS.....	16
DISCUSSION.....	29
CONCLUSIONS.....	35
ACKNOWLEDGEMENTS.....	37
LITERATURE CITED.....	38
APPENDIX.....	42

## INTRODUCTION

In this era of health conscious people, there is great concern about the large number of people each year which are affected by diseases of the cardiovascular system. A large portion of these are affected by atherosclerosis, the cause of which has been blamed on a derangement of the lipid metabolism in the body. At present, there is a world wide search going on in hospitals and research laboratories for a nutritional means of modifying or even preventing such disturbances in lipid metabolism and the resulting pathological conditions. The need is becoming even more urgent because, as the average American becomes able to spend a larger part of his income for food, 40% of the calories of his diet will be coming from animal fat (Wolf et al., 1962). Animal fats are high in components such as cholesterol, saturated fats and triglycerides which are implicated in causing atherosclerosis. Also, the average American tends to do less physical work and so does not work off those extra fat calories. As a result, we build up a potentially unhealthy situation which is causing concern in the medical field today. Add to this the stress and tension of "keeping up with the Joneses" and the danger becomes even greater as it has been shown that emotional stress will markedly raise the serum levels of cholesterol (Wolf et al., 1962).

Thus we see that building an understanding of lipid metabolism is an important area of research if we are to save many lives in future generations. In this experiment, we have attempted to show what effects, if any, would result from feeding rabbits a high fat-cholesterol diet supplemented with a high or a low level of wheat germ oil or octacosanol which is a fraction of wheat germ oil.

## LITERATURE REVIEW

The modern era of research in cholesterol metabolism was opened by Russian experiments with the rabbit as the experimental animal. Fatty arterial lesions were experimentally induced by Antischkow (1914) by using diets of meat, milk and eggs, with the atherogenic effect determined to be in the fat portion. Since that time, the rabbit and rat have been commonly used for cholesterol experiments.

The rabbit is easier to use in some respects as it is more susceptible to the effects of cholesterol feeding. When 0.4 mg C/gm body weight was fed to rabbits and rats in a single dose, the rat retained only 46% of the amount given, but the rabbit retained 77%. Plasma samples of the rats were clear of excess lipemia after 12 hours, but the rabbit plasma contained many chylomicrons after 72 hours. The faster clearance of the serum was postulated to be due to the greater number of reticuloendothelial cells in the liver of the rat, as interference with this system by the injection of India ink causes a response in rats similar to that found in rabbits (Friedman and Byers, 1954).

The usual diet for the induction of atherosclerosis contains one to three percent cholesterol and a high level of fat. Fats can not circulate in the blood in a free form. They must either be made soluble as a protein-lipid complex or with a vehicle which is protein, cholesterol, or phospholipid. The four major forms of circulating fats are chylomicrons, beta lipoproteins, alpha lipoproteins and a small portion of non-esterified fatty acids attached to albumen. Coronary artery disease is associated with an abnormally high concentration of very low-density lipoproteins in the serum. The various low-density lipoproteins are protein-cholesterol-phospholipid moieties which differ in triglyceride concentration. As the triglycerides of the complex

increase, the molecule loses its solubility as a protein and becomes more like the water-insoluble fat particle. As the low-density lipoproteins accumulate more triglycerides, they merge into the chylomicron class, which is made mostly of triglyceride particles in association with small amounts of protein, cholesterol and phospholipid. Since triglycerides make up an increasingly large part of lipoproteins as the density decreases, the total triglycerides of serum give a good measurement of the proportion of low density lipoproteins weighted on the side of those of the lowest density. The beta lipoproteins normally carry 75% of the circulating cholesterol, but with a massive increase in triglycerides, 80-90% of the low density cholesterol is present in the chylomicrons (Albrink, 1962).

Absorption of cholesterol from the intestine is dependent on the type of dietary fat which is present. More cholesterol is absorbed in rats when polyunsaturated fatty acids such as oleate and linoleate are present (Printer, Miller and Hamilton, 1964). The intestinal mucosa shows a marked preference for esterification of cholesterol with unsaturated fatty acids, especially oleic acid. Intestinal cholesterol esters released in the blood are rapidly removed by the liver and great amounts can accumulate in the liver in a short time, most when unsaturated fatty acids are fed. The cholesterol ester which accumulated most, irrespective of the fatty acid fed, was cholesterol oleate, indicating that some of the esters in the liver undergo hydrolysis and transferase activity to form other fatty acids, especially to arachidonate which is then released into the blood in association with the lipoproteins (Swell, Law and Treadwell, 1964).

In rats which were fed cholic acid and 3% cholesterol, a marked regression of previously accumulated hepatic sterol esters and triglycerides was obtained by feeding 5% or more linoleate, but no effect was observed on coronary lipid

deposits. Oleate had no effect and palmitate prevented the regression of the hepatic esters. This suggests that linoleate induces synthesis of arachidonate which is involved in phospholipids and is thus involved in transport of cholesterol and glycerides (Morin et al., 1963). Free fatty acids perfused in vitro into rat liver showed palmitate is incorporated into glycerides and linoleate into phospholipids (Nestel and Steinberg, 1963). Thus, when excess cholesterol is added to a diet over a prolonged period, it seems to limit the supply of arachidonate available for phospholipid formation. The level of liver phospholipid and phospholipid arachidonate in rats was decreased when cholesterol was added (Morin et al., 1962). Linoleic, linolenic and arachidonic are essential fatty acids which must be supplied in the diet. When a diet is low in essential fatty acids, liver cholesterol levels will increase. If extra cholesterol is added to these diets, essential fatty acid deficiency will develop more rapidly thus indicating that cholesterol places a stress upon the supply of essential fatty acids (Morin et al., 1962).

It has been demonstrated that diets containing large amounts of unsaturated fatty acids promote the reduction of serum cholesterol levels. Weanling rats fed either high or low fat diets containing cholesterol supplemented with ethyl linoleate have reduced carcass and plasma cholesterol levels. The livers of animals fed the high fat-cholesterol diets stored from 50-80% of the total cholesterol. Animals on a comparable diet with 2% linoleate had only 13-19% of the total body cholesterol present in the liver and had greatly reduced total carcass stores (Nath et al., 1958). This seems to be the result of linoleate facilitating the transport of cholesterol to the liver where it is metabolized into bile acids and excreted in the bile (Nath and Brahmankar, 1961-rats; McMillan, Weigensberg and Ritchie, 1960-rabbits).

Rabbits with atherosclerosis showed a high percent of oleic acid and a low percent of linoleic acid in their aortae, livers and serum. When there is a shift in the fatty acid pattern of the diet, there is an indiscriminate deposition of cholesterol esters into the aorta from the plasma and then the aorta determines the final composition of its esters by selective retention of saturated and mono-unsaturated esters (Swell, Law and Treadwell, 1963). Thus, the fatty acid composition of the aortae of rabbits with atherosclerosis depends on the type of fat in the diet. Rabbits fed a diet high in cholesterol supplemented with linoleic acids develop a lesser degree of atherosclerosis (Kritchevsky et al., 1956). The functional condition of the adrenal will affect the degree of plaquing as cortisone prevents atheromatosis in the rabbit when included in the diet (Albrecht et al., 1965).

The length of the fatty acid chain is also important. In dogs, saturated fatty acids fed as 40% of the calories increases the serum cholesterol most if the chain length is 12 to 14 carbon atoms, to a lesser extent if 16 to 18 carbon atoms and only slightly if 8 to 10 carbon atoms. Fatty acids with a chain length of less than 10 carbons are absorbed directly from the intestine into the portal blood. As chain length increases, a greater portion of fatty acids are absorbed via the lymphatic channels. The lower concentration of the 18 carbon mixture in the animals was explained by the fact that there was a poorer intestinal absorption of the longer chain corresponding with an increase of fat and sterol in the feces as the chain length increased (Grande, 1962). It has since been shown that no esterification of cholesterol occurs with fatty acids with fewer than 12 carbons (Murthy, Mahadevan and Ganguly, 1961). Ingestion of short chain fatty acids causes a high level of palmitic acid synthesis, but ingestion of long chain fatty acids inhibits all synthesis of fatty acids (Reiser et al., 1963).

Cholesterol fed with heated fats is more atherogenic for rabbits than the usual cholesterol-fat diet. Even short term heating of fat results in hydrolysis with the release of free fatty acids. It has been proposed that this excess of free fatty acids is responsible for the increased atherogenicity (Kritchevsky and Tepper, 1964).

The matter of saturation versus unsaturation of fats is not yet completely resolved. One dissenter who compared the effects of a saturated fat, coconut oil, and an unsaturated fat, linoleic acid, supplemental to a 2% cholesterol diet fed to rabbits found that linoleic acid increased the liver concentration by more than twice, did not reduce serum levels, and did not increase the excretion of cholesterol catabolic products (Merrill, 1960). Beiberdorf and Wilson (1965) proposed that the mechanism of action of unsaturated fats lies not in increased excretion, but in the shift of the cholesterol pool from the serum into the skeletal muscle of the body. Much work remains to be done in this area.

Other factors such as the accompanying carbohydrate and protein may also affect the expression of cholesterol. In an effort to eliminate as many unknown factors in the feed as possible, the use of purified feeds has been attempted. In comparing the effect of lactose versus sucrose in rabbits fed 0.35% cholesterol, Wells and Anderson, (1959) found that lactose increased the intestinal absorption of cholesterol, caused less weight gain, more severe atheroma, changes in the vessels five times more extensive and higher levels of cholesterol in both the liver and serum. Wilkens and Krut (1965) found that in rabbits and man cholesterol may crystalize from solution in a lipid carrier phase and thus become involved in atheroma formation. High levels of glucose were postulated to adversely affect the cholesterol complex stabilizing ability of the serum, thus causing the formation of crystalline



cholesterol in the arterial intima and initiating secondary tissue reactions characteristic of atherosclerosis. Other sugars have a comparable effect.

The type and amount of protein also has its effects. Rabbits fed a 38% casein diet without cholesterol for six months developed plaque formation and twice the normal amount of plasma cholesterol. When a low level of cholesterol was added to this diet, there was marked sclerosis but only a moderate level of blood cholesterol suggesting the existence in or production by the casein of a toxic factor favoring the deposition of cholesterol (Meeker and Kesten, 1941). Kritchevsky and Tepper (1965) have shown casein to be atherogenic with palm oil but not with corn oil which contains a high level of unsaturated fats. Casein does not seem to have these effects on the rat which is more resistant to atherosclerosis in general (Farnell and Burns, 1962). In man, low protein diets have been found to be hypercholesterolemic without added cholesterol (Beveridge, Cornell and Robinson, 1963).

The entire small intestine is capable of absorbing cholesterol, but the ileum is most active in this respect. The total amount absorbed will depend on four factors other than the type of fat present in the digestive tract: the transit time through the intestine (Buchwald and Gebhard, 1964); the presence of bile and pancreatic juice, as their absence will totally abolish absorption of cholesterol into the thoracic duct lymph, and intestinal cholesterol esterase activity will stop (Borja, Vahouny and Treadwell, 1964); and the total time that cholesterol has been fed. The presence of large quantities of cholesterol leads to an increase of the esterifying activity of the mucosa. Esterification has been postulated to be a rate-limiting step during absorption of cholesterol, so if the esterification rate is increased, more cholesterol can be absorbed per unit of diet as the animal adjusts to this type of feeding (Murphy et al., 1961).

Cholesterol is absorbed in an emulsion containing bile salts and ingested triglycerides which have been hydrolyzed to 2-monoglycerides and free fatty acids. This emulsion is in a micellar solution which then penetrates the mucosal cell (Hofmann and Borgström, 1962) in droplets of 65  $\mu$  which filter through the intermicrovillous spaces to the base of the microvilli where they pass through the cell membrane by the process of pinocytosis. The fat particles pass through the endoplasmic reticulum enclosed in membrane vesicles during which time they increase in size, and then they are discharged at the other surface of the mucosal cell (Palay and Karlin, 1959). During the trip through the mucosal cell, triglycerides are resynthesized and these, along with the cholesterol, are released as chylomicrons into the intestinal lymphatics (Ashworth and Johnston, 1963). They are carried via the thoracic duct and the blood stream to the liver where they are taken up by pinocytosis into the liver cells (Ashworth, Wrightsman & Buttram, 1961). Here there is intracellular hydrolysis, with resynthesis into low-density lipoproteins, and these are released into the serum. The total low-density lipoprotein composition of the blood at any one time is a combination of chylomicrons being carried to the liver and low-density lipoproteins being released from the liver (Albrink, 1962).

Under normal conditions, the utilization and catabolism of lipids by the liver occurs at a rate sufficient to prevent the accumulation of lipids. In the rabbit, excess cholesterol is conjugated with glycine and excreted via the bile acids into the intestine (Bremer, 1956). However, when excesses of cholesterol are fed over an extended period, it loads the liver and is deposited in other organs as well in an attempt to keep the serum reasonably clear. An article by Prior, Kurtz and Ziegler (1961) on the secondary effects of hypercholesteremia in rabbits described a progressive involvement

of the whole animal over a period of months. The first month there was a rise in blood cholesterol from a normal of 30 mg/100cc to 1,120 mg/100cc of blood. Foam cell collections were found resting on the internal elastic membrane of the aorta with an intact endothelial cell surface. Already, there was a severe involvement of the coronary arteries with a narrowing of the lumen due to a deposition of lipid in the subendothelial coat, but still with an overlying intact endothelial cell layer. The adrenal glands were enlarged because of lipid deposition within the zona fasciculata and reticularis. Isolated lipid-containing histiocytes were seen in the spleen, bone marrow and lymph nodes. After two months of cholesterol feeding, the blood cholesterol levels averaged 1,800 mg/100cc and there was increased lipid in the lymph nodes, bone marrow and spleen. The spleen showed heavy lipid particularly in the subcapsular sinusoids. The peribronchiolar lymphatic tissue showed heavy lipid infiltration and metaplasia of the mucosa. The pulmonary arteries and veins had severe luminal narrowing because of masses of lipid filled histiocytes which also appeared in the collecting tubules of the kidneys and stromal tissue of the ovary. The adrenal glands had heavy lipid deposited within all layers of the cortex and there was evidence of necrosis. Gross lesions of the aorta occurred with intimal thickening caused by intra- and extracellular lipid deposits. At the end of three months administration, the blood cholesterol averaged 3,000 mg/100cc. Most of the changes described before were exaggerated. The myocardial arteries were transformed into lipid masses with extreme luminal narrowing. The aorta showed surface fibrosis and the fatty process extended into the medial coat. Similar changes occurred in the pulmonary arteries. Lipid accumulation was prominent in the liver, hind paws, and stomach. The lipid in the liver was deposited in the central one-third of the lobule within the hepatic polygonal cells.

At the end of four months, Prior et al. (1961) found the blood cholesterol levels averaged 4,000 mg/100cc. The splenic parenchymatous tissue was almost replaced by lipid-containing histiocytes, and collections of these cells were found forming a "plaque" on the capsule of the spleen. The entire gastrointestinal tract showed lipid deposition in the mucosa and the kidneys also had lipid deposits, especially in the renal papilla. Striated muscle showed replacement by large collections of lipid histiocytes. The eyes had lipid in the iris, ciliary body, and choroid coat. Despite sustained hypercholesteremia, cholesterosis of the gall bladder was not produced in these animals.

These animals showed a consistent weight loss of 1,500 gm over the course of the five month experiment. The blood cholesterol had dropped during the last month, perhaps as a result of the reduced food intake. All of the pathological conditions found before had become more severe, and now the proximal convoluted tubules of the kidney became lipid filled. The damages at this time were so severe that the authors believed it highly probable that these animals were suffering from functional failure of the liver, adrenal cortex, reticuloendothelial system and genitourinary systems.

Albrecht and Schuler (1965) reported that, contrary to Prior et al. (1961), the blood cholesterol of their rabbits rose until 35 days and then reached a plateau. Lynn et al. (1958) found that cholesterol fed animals drank 500-1000 ml of water per day while the controls drank only 200 ml. The urine volumes were proportional to the intakes. Water was found to be important in facilitating the clearance of cholesterol from the blood. There was a marked increase in the excretion of calcium, potassium, phosphate and sulfate, but not of sodium. Severe osteoporosis was also found in animals in a similar experiment.

Another effect not mentioned by Prior et al. (1961) but which has been

reported in rabbits, rats and guinea pigs is anemia. In rabbits, two types have been reported, hemolytic (Pinter and Bailey, 1961) and macrocytic (Graham, Beare and Grice, 1959). The hemolytic anemia showed an increase in the reticulocyte count, the appearance of nucleated red blood cells of different maturity in the peripheral circulation, anisocytosis, anisochromia and a decrease in the number of red blood cells which is lowest at 8 to 12 weeks. Half life of the red blood cells is decreased from 12 to 3-7 days. It was found that the weakness is inherent in the mature erythrocyte, so the anemia is a consequence of the production of red blood cells with decreased resistance. Macrocytic anemia resulted in reduction both in the hemoglobin level and in the number of circulating red blood cells. The bone marrow exhibited very high activity but blood cells produced were fragile and had a reduced life span. This type of anemia was accompanied by fatty livers, enlarged spleens, jaundice and atrophic gastritis. Guinea pigs are very susceptible to macrocytic anemia when fed cholesterol, developing hypertrophic bone marrow and red blood cells with 2.5 times the normal amount of free cholesterol (Ostwald and Shannon, 1963).

Simon, Still and O'Neal (1961) found that lipid filled macrophages (lipophages) develop with high fat diets regardless of whether butter or corn oil is given, and that their numbers are related to the level of blood cholesterol. These cells can be found penetrating and clinging to and penetrating the aortic endothelium. Tompkins (1946) demonstrated that macrophages will collect in the area when a single injection of colloidal cholesterol is made into the abdomen of mice. There is an infiltration of monocytes which gradually turn into macrophages. These join the tissue macrophages already present in accumulating cholesterol crystals on the surface of the cells and then ingesting the cholesterol. Later, cholesterol

esters filled these cells indicating that cholesterol esterification had taken place, most likely at the surface of the macrophage. Since then, Day, Gould-Hurst and Wilkinson (1964) have proven that macrophages convert cholesterol into a lipoprotein complex and produce phospholipids to stabilize this complex and thus remove the cholesterol from the body fluids. Bernick and Patek (1961) have shown that this takes place not only in the liver and spleen, but also in the lungs. The pulmonary macrophages phagocytized lipid droplets and migrated into the alveoli and bronchioles, while others formed clumps throughout the lung often to the point of making nodules on the surface of the lungs. These nodules also contained connective tissue and lymphocytes. The presence of lipophages in the glomerular capillaries and their similiarity to lung macrophages suggested migration via the blood stream.

Several other miscellaneous factors can affect the course of experiments. Maintaining a rabbit colony on cholesterol feed at a temperature of 45 to 50 F will result in more plaque formation even though the serum cholesterol level will be lower than those of animals maintained at 80 to 85 F (Sodeman and Logue, 1960). If a stress is placed on the animal, such as placing them in a restraining cage, this will alter the metabolism of liver cholesterol esters in rats (Klein and Dahl, 1961). Kobernick, Niwayama and Zuchlewski (1957) found that atherogenesis in rabbits could be inhibited by exercise if the amounts of the atherogenic diet were limited, but the ingestion of ad lib quantities of the same diet overwhelms the beneficial effect of exercise (Brainard, 1959). The serum levels may also be affected by sex hormones in that the cholesterol concentration in female rats was the highest during the proestrus to estrus period and then fell until the diestrus period (Fillos et al., 1958).

Ever since the early Russian experiments which proved that the lipid portion of certain food is at least partly responsible for atherosclerosis, there has been a search for a means of reducing these pathological effects. This experiment was set up to determine the effects of wheat germ oil which contains 28% oleic acid, 52% linoleic acid, 3.5% linolenic acid, 12% palmitic acid and 3% steric acid as its fatty acid composition. In addition, it contains vitamin E, which has been postulated to be an important natural antioxidant in the body to prevent the oxidation of unsaturated fats (Alfin-Slater et al., 1954), and methionine which has been shown to lower serum cholesterol levels (Seidel and Harper, 1963). Van Handel and Zilversmit (1959) fed wheat germ, cottonseed oil and hydrogenated cottonseed oil to three groups of rabbits and compared the effects. They found that the liver cholesterol was much lower in the wheat germ group, but that the degree of atheroma was greater. By using only the wheat germ oil in this experiment, we hoped to reduce the degree of atheroma as well.

#### METHODS AND MATERIALS

Forty-five 2 year old rabbits were divided into five groups of equal weight and sex distribution. The animals were given numbers according to group, the highest numbers to the largest animals. All animals were individually caged in wire bottomed cages and given water and a purified pelleted ration ad libitum. The diet consisted of casein, dextrin, cellulose and fat with adequate salt mix and vitamins, with only cholesterol, octacosanol and the type of fat varied between the five groups (Table 1). To prepare the feed, the cholesterol and octacosanol were dissolved in the warmed oil, and then the other components were added and the mixture pelleted by the KSU milling department. It was stored in a cold room until used. The control

diet was fed to all groups for one week, then experimental feeding was begun. Weekly feed consumption and weights of the rabbits were recorded throughout the experiment.

Blood samples of 0.5 ml were taken via the marginal ear vein and placed in ether-alcohol as the animal was held in a restraining cage. Samples were taken from three animals of each group after one week on the base feed, and then at 1, 2, 3, 6, 11, 12 and 13 weeks on the experimental feeds. Samples were also taken from each animal at the time of sacrifice. Hematocrit readings were taken and blood smears were made from each animal during the last 4 weeks of the experiment.

Two animals from each group were sacrificed at 4, 7, 10 and 13 weeks. Photographs were made of the heart, aorta, liver, spleen and kidneys. Weights were recorded of the kidneys, adrenals, lungs, spleen, liver and heart (Table 2). Gross descriptions of these organs and the aorta as well as any other unusual conditions were recorded. To examine the interior of the heart, an incision was made beginning on the ventral side of the base of the aorta down beside the interventricular septum to the base of the ventricle. Then the scissors was inserted into the atrium through the bicuspid valve and an incision was made to expose the interior of the left atrium. The opened heart along with the spread aorta were pinned to a black wax bottomed pan for photography.

Samples of heart, aorta, liver, spleen, adrenal, kidney, lungs and ovary were fixed in Bouin's, infiltrated with paraffin, sectioned at 8 microns and stained with periodic acid Schiff, Mallory's triple, and hematoxylin orange G and examined for pathology. Samples of heart, aorta, liver, spleen and adrenal were fixed in 10% formalin, sectioned on the cryostat at 12 microns and stained with hematoxylin-Sudan IV and examined for fat deposits.



Samples of blood, liver, spleen and adrenal were taken for cholesterol determination by the Leiberman-Burkhart colorimetric method of Bloor (1916) (Table 3). A 0.5 ml sample of blood or a 0.5 gm sample of tissue which had been ground fine with a mortar and pestil was placed into a 150 ml beaker containing about 40 ml of an alcohol-ether mixture (3 parts isopropyl alcohol: 1 part ethyl ether). This was heated to boiling to aid in extraction and allowed to cool, and filtered through Watman No. 2 filter paper (12.5 cm). The volume was brought up to 50 ml for the blood samples and divided equally into two 30 ml beakers. For the tissue samples, the volume was brought up to 60 ml, half was used for total fat determination and the other 30 ml was divided into two beakers for cholesterol determination. The filtrate was evaporated to dryness in a vacuum oven under negative 25 cm Hg pressure taking care not to allow the temperature to rise above 65 C which would cause scorching and alter the results. The beakers for total fat determination were then weighed on a Mettler balance and total fat calculated by subtraction of the tare from the total weight.

The residue in the beakers for cholesterol determination was extracted with three 3 ml portions of dry chloroform which were heated and decanted into a test tube. The volume was brought up to 5 ml. At this time, a blank was prepared and placed in the Bausch and Lomb Spectronic 20 and, with the wave length set at 615 mmu, the upper limit of the transmission scale was set for 100% transmission. The appropriate wave length had been previously determined by calibration. A standard was prepared by using 0.5 ml of a 0.1% standard solution of cholesterol dissolved in chloroform. This was diluted to 5 ml, to which was added 2 ml acetic anhydride and 0.2 ml concentrated sulphuric acid, and the contents mixed thoroughly. As the color developed from blue to green, the tube was placed in the Spectronic 20 and

read when the peak of the green color developed which usually occurred within 3-5 minutes. The standard, so tested, consistently gave a reading of 34% transmittance. Appropriate dilutions were determined for the experimental samples by repeated testing until a reading between 10 and 80% transmission was obtained. The acetic anhydride and sulphuric acid were then added to appropriate dilutions of each of the samples in turn and read at the peak of the color development. The standard chart (Fig. 1) was then used to calculate the total cholesterol present.

#### RESULTS

When the purified feed was first introduced, the animals were somewhat reluctant to eat it, but reluctance was soon overcome by hunger. After this, the feed consumption was twice the requirement calculated on the basis of calories and past experience. This meant that the experimental groups would run out of feed before the end of the 13 weeks. There was not time to order materials for a new batch of feed, so it was necessary to take the feed set aside for the control group, add the proper components for the experimental groups, and divide it among them. This necessitated returning the control group to the regular rabbit lab chow supplemented with 10% fat after 7 weeks.

Feed consumption tended to be somewhat erratic (Fig. 2). One week a rabbit would eat very well and then would slack off in the next week. This was especially noticeable in the animals which were beginning to be seriously affected by the cholesterol. In these animals, feed consumption decreased over a period of several weeks to the point where they ate nothing. This decrease was accompanied by a severe weight loss, as much as 300 gm per week. When these symptoms became apparent, that animal was sacrificed at

the next scheduled period because it had entered the terminal phase of cholesterol damage. There was a great increase in feed consumption and weight in the control group at the eighth week on the experiment. This was caused by returning these animals to the regular rabbit chow supplemented with 10% fat. This diet was much more tasty and therefore the rabbits ate better and gained more weight.

The weekly weight record (Fig. 3) of each animal gave a good indication of the amount of damage occurring. At the beginning of the experiment, the average weight of the animals was between 3700-3900 gm. As the experiment progressed, the control group continued to gain weight, but the experimentals did not. Groups 2, 3 and 4 managed to maintain their weight or gain a little for the first four weeks. Group 5 lost weight from the beginning and continued to do so throughout the experiment. After the fourth week, most experimental groups lost weight continuously, although group 3 maintained a little longer and did not lose as rapidly. The average weight of the experimental groups at the end of the experiment was below 3000 gm.

The blood cholesterol rose rapidly during the first week of cholesterol feeding from an average of 150 mg/100 ml blood to 510 mg/100 ml blood (Fig. 4). It continued to rise for the next four weeks until it reached a plateau at about 1500 mg/100 ml, from which it continued to rise slightly until the last sacrifice. Some of the animals seemed to be able to build up a tolerance or compensate in some way for the high cholesterol-fat intake. In others, the blood cholesterol increased rapidly to the 3,000-4,000 mg level at which time they quit eating (Fig. 5). At this point, we usually sacrificed them or they died. Toward the end of the experiment, the blood looked abnormal and so hematocrit readings and blood smears were taken from the surviving animals during the last four weeks. The controls had

hematocrit values around 40 which is normal for a rabbit. The experimental values ranged mostly 20 to 28 with several readings as low as 16-19. The blood smears showed a high percentage of eosinophils in the blood, some of which were fragmenting. Also the red blood cells seemed to have an increased fragility (Fig. 21). By the 10th week, we experienced great difficulty in drawing blood from the ear veins of the rabbits. The veins collapsed readily when the negative pressure was put on them and they refilled very slowly.

The later stages of pregnancy seemed to lower serum cholesterol remarkably. The animals were caged separately, but we found later that, when the waste tray was removed from the cages for cleaning, the animals were able to get into the cage next to it. Therefore on the last sacrifice, No. 18 was in the process of parturating six young, and on the second sacrifice, No. 34 had eleven near term fetuses. These animals had low cholesterol levels of 73 mg and 560 mg respectively.

Liver Damage. Even at the first sacrifice, after 4 weeks on the experimental feed, organ damage was drastic. Grossly, liver damage consisted of a progressive blanching of the tissue from the dark-reddish brown of the normal liver to a light brown, to a yellow brown, to a beige and then on to an ash white (Fig. 6, 7, 8, 9, 10 & 11). Some of the livers turned from light brown to greenish brown usually accompanied by necrosis (Fig. 12). On the first sacrifice, livers of 21, 31, 47 and 52 were light brown; ash-white livers were found in 32, 41 and 59; and No. 26 had a severely jaundiced greenish-brown liver. On the second sacrifice, the beige livers were 34, 43, 44 and the ash white were 23, 28, 37, 51 and 56. At the third sacrifice, the livers were all beige or light brown. The damage here seemed to be less than on the first two sacrifices, possibly because we had selectively sacrificed those

animals which were least able to handle the high level of fat and cholesterol. Therefore those remaining, although not in good condition, were never-the-less better able to cope with the situation. By the last sacrifice, one of the control animals, 18, had developed a fatty slightly lightened liver, but not the severe lightening seen in the experimental animals. The liver of animal No. 27 was light brown, 22 and 42 were beige, and 36, 39, 48, and 54 had varying degrees of green intermingled with brown.

The gall bladders of several of the animals were greatly distended (37, 33, 39, 43, 45, 58), from undetermined cause (Fig. 11). Animal 25 was sacrificed at 9 weeks because it gave indications of severe damage; loss in weight of 1 kg in 3 weeks, blood level of 3000 mg, no food intake for 2 weeks. Upon sacrifice, our suspicions of imminent death were verified by this liver and spleen (Fig. 12) and an aorta and pulmonary trunk which were loaded with plaques.

Histologically, the liver is primarily composed of a cord arrangement of cuboidal cells that give a bright PAS+ reaction. There is a complex of an artery, hepatic portal vein and a bile duct entering the lobules, and a hepatic vein which drains the center of the lobules (Fig. 14). The liver showed marked effects from cholesterol even on the first sacrifice. The first indication of change occurred around the hepatic veins which drain blood from the center of the hepatic lobules. The veins enlarged and the cells surrounding the vein became swollen, lost their heavy PAS+ glycogen content, and vacuoles occurred causing the cells to appear "foamy" (Fig. 15). The nuclei at this time were normal. As more cholesterol was brought to the liver for conversion and storage, more cells were affected and these foam cells began to radiate out from the veins, giving the section a spotted appearance as these areas were more lightly staining with PAS. The glycogen in the cells around the arteries clumped and appeared granular and dense (Fig. 16).

Up to this time, the cord structure remained fairly intact, but now some of the cells around the veins began to enlarge and specialize as fat cells; others shrunk and had bright red pycnotic nuclei, and now the cord structure became disarranged (Fig. 17). The area became disorganized with necrotic patches and only a few of the cells had glycogen granules. Fibrocytes became more prominent in the area around the veins. At this stage, the cells around the arteries also began to lose their glycogen developing the appearance of a "new" cell (Fig. 18) of normal hepatic cell size with a plump nucleus, but devoid of glycogen and staining pale homogeneous blue with PAS-hematoxylin. These cells still had normal cord arrangement, but soon the degenerative process appeared in them and they became vacuolated and enlarged as foam cells (Fig. 19). These "new" cells around the arteries were the last to be affected, and functional failure of the liver occurred when they became numerous. This condition was characterized by a negative PAS stain and complete disruption of organized hepatic cord structure. Original hepatic cells were mostly modified to foam cells or large clear fat cells with pycnotic nuclei (Fig. 20). Fibrosis, as determined by Mallory's triple stain, was far progressed especially around veins. Early in this stage, the animal usually quit eating and then died as the damage progressed to involve the arteries.

Typical "signet ring" fat cells were encountered in four of the animals (18, 44, 52 and 58), including a control rabbit. These cells had the fat in a single large clear vacuole instead of in foam cells as was the case with high cholesterol and relatively low total fat. This condition correlated with the high fat determined for several of the animals. The fat deposition seemed to be independent of the cholesterol effects, as in animal 44 there was 26% fat but only 9% cholesterol (Table 3).

Spleen damage. Grossly, the spleens showed a condition similar to that of the livers. The color, which is normally dark reddish-brown, gradually lightened to muddy red, to bright red and finally to pinkish-gray in the final stages (Fig. 6, 7, 8, 9, 10, 11 & 12). This blanching was caused by a progressive deposition of fat under the capsule and in the tissues of the spleen which finally replaced the splenic tissue with fat cells. This damage was accompanied by a marked increase in size (Table 2). The amount of damage found in the spleen did not always correlate to the damage found in the liver. At times, a bad liver and a fairly good spleen were found together and the opposite could also be true (Fig. 11).

At the first sacrifice, spleens of animals 26, 47, 52, and 59 were normal in size and color, but animals 21, 31, 32 and 41 had enlarged spleens that, with the exception of No. 21, were severely grayed with only a few traces of red. At the second sacrifice only the spleen of No. 23 showed severe damage while 34, 37, 43, 44, 51 and 56 were enlarged but had a muddy red color with the exception of No. 43 which was bright red. By the third sacrifice, the spleens of experimental animals were enlarged and were light red except for No. 57 which was brown. These did not show the severe graying found earlier. Spleens of the last sacrifice also showed enlargement and light red color, but again the severe blanching was not found.

Normally the spleen is composed of two types of tissue: red pulp and white pulp. The white pulp comprises the splenic nodules, composed of a mass of lymphocytes surrounded by a fine connective tissue sheath, with a "halo" of more loosely packed lymphocytes. The red pulp consists of venous sinuses and splenic cords which are rows of lymphocytes and fixed macrophages separating the sinuses, making up a spongy network. There are also free macrophages in the sinuses which store hemosiderin freed by the breakdown of red blood cells (Fig. 22).

When lipid in the blood increases, the macrophages of the spleen have the ability to remove and store them, resulting in considerable damage to the spleen with continuous high lipid levels. The first changes were seen in a great increase in hemosiderin inside the macrophages and an increase in the number and size of macrophages found in the sinuses. The sinuses also seemed to increase in size (Fig. 23). Soon after this, free and fixed macrophages which had formerly contained a great amount of hemosiderin now contained a little hemosiderin and the beginning of vacuoles (Fig. 23, 24 & 27).

With cholesterol blood levels remaining high, the damage became more severe. The white pulp nodules were reduced in number and size down to and even inside the connective tissue sheath (Fig. 25). The lymphocytes disappeared from the cords and increased in the blood and then even became reduced in the blood (Fig. 24 & 25). Macrophages greatly increased in number and size in the cords and in the sinuses, where they appeared to be phagocytizing lymphocytes and other cells (Fig. 25, 26 & 27). In some swollen cells, PAS+ patches appeared, indicating degenerative processes (Fig. 27). Rows of fibrocytes became apparent and some connective tissue appeared. Disorganization of the capsule occurred as large fat cells became interspersed within the connective tissue and formed masses over the top of it (Fig. 28). These masses were visible grossly as white patches on the surface of the spleen.

Even before the last sacrifice, terminal conditions had been reached in some of the animals. These were typified by a great reduction in the splenic nodes, the absence of lymphocytes, fibrosis, and a great number of fat laden macrophages which replaced the splenic cords and clogged the sinusoids resulting in a reduction in the number and size of the sinuses (Fig. 29).



Adrenal damage. Grossly, the adrenals showed little change, but histologically there was considerable damage. Normally, the adrenal is composed of two types of tissue; a three layered outer cortex and a smaller central medulla. The thin outer layer of the cortex, the glomerulosa, contains rows of cuboidal cells with plump nuclei and darker staining cytoplasm. The middle thick layer, the fasciculata, has larger cells which are arranged in radial cords all leading toward the moderately thick reticularis which has anastomosing cords of smaller cells with close, compact nuclei. The medulla is composed of large columnar cells arranged in cords around blood capillaries with plump, ovoid nuclei and dark homogenous cytoplasm.

The first changes occurred in the heavily vascularized areas of the outer medulla and reticularis. Patches of cells appeared which were larger than the surrounding cells and whose cytoplasm was pale and homogenous. As more of these cells appeared, some of them became PAS+ and heavily vacuolated, giving the appearance of typical foam cells (Fig. 31). Such patches then appeared throughout the fasciculata (Fig. 32). As these swollen, vacuolated, PAS+ cells developed throughout the tissue, the cord structure was destroyed and the difference between the fasciculata and reticularis disappeared, giving the appearance of constant enlargement of the reticularis. The changes in the medulla followed the same pattern with the larger, clear cells appearing first, then vacuolated PAS+ foam cells appearing around the periphery, and then farther in until almost all the columnar cells became irregularly rounded and vacuolated (Fig. 31). Lymphocyte infiltration occurred as the damage progressed.

The zona glomerulosa resisted change and was the last area to be affected. It finally lost its stainability and then, when the rest of the adrenal had become severely damaged, also began to succumb to the same changes that were

destroying the rest of the tissue although cord disruption never seemed to be as severe (Fig. 33).

Renal damage. At the first sacrifice, no noticeable damage to the kidneys was found, but at the second sacrifice white spots or general graying on the surfaces of some of the kidneys began to show. Upon cutting them open, we found white streaks through the medulla, extreme in several of the animals (Fig. 13) extending up into the cortex and even out to the capsule. This type of damage was found in most of the experimental animals after the first sacrifice with no correlation of damage to the experimental group. The amount of damage seemed to be a matter of individual tolerance.

Histologically, damage to the kidneys was apparent even for the first sacrifice group. Since this damage occurred in the control group as well as the experimental, perhaps this was, in part at least, due to some component of the purified feed. The hemosiderin content of the blood vessels increased, especially in the collecting tubule area, and large macrophages began to appear in the blood vessels (Fig. 34). The cells of the collecting tubules developed a swollen, foamy appearance. The nuclei became pycnotic and eventually the cell membranes broke down and the tubule was replaced by connective tissue (Fig. 35 & 37). These changes were next seen in the proximal tubules and eventually necrotic patches extended out to the capsule (Fig. 36). Tubule destruction was accompanied by degeneration or reduction in size of some glomeruli; appearance of excessive lymphocytes in the blood and in the collecting tubules, macrophages and many leucocytes in the blood (Fig. 37); and a great increase in the size of the lymph channels which appeared to be blocked by a homogeneous substance. As the necrotic areas spread, the remaining kidney tubules and blood vessels enlarged, perhaps in compensation for reduced functional capacity. The most severe cases were characterized by

necrosis of tubules, fatty degeneration between tubules, fibrosis, many macrophages and lymphocytes in the blood vessels and collecting tubules, infiltration of lymphocytes, edema and degenerate glomeruli.

Lung involvement. The only gross evidence of damage to the lungs was the appearance of small, whitish nodules on the surface in two animals on the second sacrifice and on most animals of the third and fourth sacrifices. Pleural fluid, 60 ml, was found in animal 49. Histologically, the explanation for the nodules was seen in an abundance of foam cells and many macrophages, some of which contained hemosiderin. The macrophages were indiscriminate as to position and were found in the tissue, in arteries and veins, and in alveolar and bronchiolar spaces, often to the extent of blocking small lumens (Fig. 30 & 38). The arteries contained many plaques (Fig. 38 & 39), and collections of lymphocytes were seen around large arteries. The blood vessels also contained an excessive number of polycytes and other leucocytes in relation to the number of red blood cells (Fig. 39). In addition, we found unusual cells in the blood vessels, not of usual blood cell type, which resemble cell types characteristic of cancer cells.

Ovary. Pathology of the ovary was noted mainly in the appearance of small patches of PAS+ vacuolated cells scattered through the interstitial tissue in a few of the animals sacrificed at 10 and 13 weeks when all the other tissues studied seemed to be loading up with foam cells.

Heart and Aorta. Although the hearts and aortas on the first sacrifice were generally in fairly good condition, several distinct changes were observed. Of the ten animals sacrificed, six showed distinct whitish nodules along the base of the bicuspid valve (Fig. 41). Similar granulations were observed at the base of the tricuspid valve in No. 41. Excess pericardial fluid was found in animal 32. The beginning of plaque formation in the aorta was seen

in four animals (Fig. 41); small flecks in the aortic arch and around the segmental arteries in No. 21, at the opening of the subclavian A in No. 41, around the openings of the caortid arteries in No. 47, and in the arch and around segmental arteries of No. 52. These beginning areas of damage point up a principle which seems to be followed throughout; plaques will form in areas of rapid blood flow and turbulence such as at the openings of arteries leading off from the aorta and at valves (Constantinides, 1965).

By the second sacrifice, these conditions had been extended. The controls were still normal, but all the experimentals showed signs of plaquing to a varying degree. Granular plaques were found around the base of the bicuspid valve on all eight experimental animals. Granulations were found in the base of the tricuspid valve in three animals. Excess pericardial fluid was found in No. 34 and 51. Aortic plaquing was much less in groups four and five, these having only a few scattered plaques throughout the arch of the aorta. Plaquing was heavy in groups two and three, especially in 23, 34, and 37 in which the thoracic aorta was almost completely lined with plaques which had become confluent (Fig. 43). The plaques of No. 37 were crisp and grainey indicating arteriosclerosis instead of atherosclerosis, the grainyness being caused by calcification of the injured area. The surface of some hearts also showed mottling with light areas in 23, 28, 34 and 37.

At the third sacrifice, the controls were still normal (Fig. 41). Plaquing occurred around the bases of the bicuspid, tricuspid and semilunar valves in all experimental animals. In the worst cases of plaquing around the valves, the plaques extended onto the valve itself and back into the surrounding tissue. As a result, the opening of the coronary artery tended to be plaqued over and partially closed (Fig. 43). The musculature of the

artial wall became plaqued in 38, 45 and 57 (Fig. 41). The bases of the cordae tendinae were also lightened by beginning plaques (Fig. 42). The surface of the heart was mottled in animals 29, 38, 49, 55 and 59. Excess pericardial fluid was found in animals 45, 49, 55 and 57. Plaquing in the aorta showed considerable variation, being light in 25, 29, 35, 45, and 55, and heavy in 49 and 57 (Fig. 42, 43). By selectively sacrificing the animals which were unable to cope with the high cholesterol in the first two sacrifices, the damage in the aorta here was actually not as severe as that seen in the second sacrifice, even though the plaquing was heavy around the opening of vessels in the arch of the aorta. One new condition found here was the formation of plaques in the pulmonary artery in 45, 49 and 57 (Fig. 41).

By the fourth sacrifice, even the most resistant showed signs of severe damage. The controls remained almost normal, but all the experimentals showed heavy plaquing in the arch of the aorta and animals 22, 27 and 36 showed heavy plaquing throughout the aorta (Fig. 44). The others had fairly clear abdominal aortas except for small plaques at the orifices of branch arteries. The valves were all heavily plaqued except on 48 and 57 in which the plaquing was light. The large plaques formed nodules of up to 3 mm diameter and made the flaps of the valves stiff and hard. The surface of the heart of No. 58 was gray. Excess pericardial fluid was found in animals 18, 39, 42 and 54. Plaquing of the orifices was heavy especially in the carotid and pulmonary arteries. Even the venae cavae openings were heavily plaqued in animal 27 and the left atrium was plaqued in No. 36 (Fig. 43).

Histologically also, the controls remained normal throughout the course of the experiment. In the first sacrifice, all the hearts of the experimentals had a similar degree of damage consisting of slight fatty degeneration

of the tip of the papillary muscles and a few small areas of glycoprotein on the side of the papilla and in the adjoining walls of the ventricle. There were a few clear vacuoles on the under side of the bicuspid valve and traces of fatty degeneration of the atrial wall in some of the animals. By the second sacrifice, these changes were accentuated. Plaquing appeared heavier in the bicuspid valves of the left ventricle (Fig. 44), in the arterioles at the bases of the papilla, and patches of PAS+ cells appeared in the ventricle wall and sides of the papilla. These effects were more severe in groups two and three. By the third sacrifice, in group two, some arterioles in the base of the papilla were closed by swelling of the intima, and necrosis of the papilla had begun, sections showing degenerating cells with pycnotic nuclei. More plaquing had formed on the bicuspid valve (Fig. 45) involving both the upper and lower surfaces. PAS+ degeneration of the inner ventricular walls became apparent with plaquing appearing in the coronary arteries (Fig. 46). Fatty degeneration of the tip of the papilla became even more severe. Similar but more moderate effects were seen in groups 3, 4, and 5, with group 5 being least damaged. By the last sacrifice in group 2, fibrocyte invasion had occurred in the papilla and ventricular wall with fatty degeneration of the cells in the tip of the papilla. Similar damage was found in the other groups again being least severe in group 5. In general, the degree of histological damage corresponded to the degree of gross damage found.

As for the aorta, the controls remained normal except for two tiny plaques in one animal at 13 weeks. At the first sacrifice, group 2 showed finely vacuolated cells and swollen intima of the tiny arterioles of the aortic wall. The other groups also showed fine vacuolization. By the second sacrifice, these areas of swelling had developed into thin plaques in group 2 (Fig. 47). Groups 3, 4 and 5 showed the fine vacuolization in some cells but

still remained essentially normal. By the third sacrifice, group 2 had thick fibrous and fatty plaques and evidences were seen of fatty degeneration and fibrocytes which were PAS+ (Fig. 48). Some of these changes appeared in group 3, but to a lesser degree. Groups 4 and 5 now had developed thin plaques as seen previously in group 2. By the fourth sacrifice, group 2 had large aortic plaques, degenerating cells with pycnotic nuclei in areas of fatty degeneration, and the beginning of fibrous connective tissue. Similar changes were seen in the other groups, again becoming progressively less in groups 3, 4 and 5. The degree of histological damage corresponded to the degree of plaquing seen grossly in the aorta.

Many of the animals, especially those which survived longer, showed severe jaundice. Their skin became yellowed and the eyes lost their clear pink color and became orange. Another condition found was lesions in the stomachs of several of the animals.

#### DISCUSSION

Purified feed, as used by Ershoff (1961) and others, certainly has advantages for certain types of work, but in this case, disadvantages of the unknown limiting of essentials, unpalatability and atherogenic effects of casein (Meeker and Kesten, 1941) make their use questionable. Previous trials in this laboratory with high fat-cholesterol added to regular laboratory feeds produced much of the liver and heart damage observed in the present series, without the extreme toxicity. In that series, wheat germ oil had more definite ameliorating effects on cholesterol pathology. Unfortunately, the purified feed for this series did not pellet properly, and the repelleting process resulted in reheating, perhaps resulting in hydrolysis as another complication as Kritchevsky and Tepper (1964) have shown that heated fats

were more atherogenic in rabbits, because of an excess of free fatty acids. A feed analysis by VioBin Corporation has shown that the fat used in the feed contained 12.0% free fatty acids which is much higher than the amount used by Kritchevsky and Tepper (1964) to show the atherogenic potential of free fatty acids. Also, it is possible that reheating and storage, even at low temperatures, could have resulted in saturating double bonds and peroxidizing, or in denaturing some of the vitamins, thus nullifying beneficial effects of the unsaturated fats or actually creating a new toxic condition.

From the beginning, the food consumption in group 5 was less than in the other groups and it remained low throughout the experiment resulting in more rapid weight loss. Animals of this group also had less plaquing in the aorta. Lower intake of food could not be the full answer to these differences as the livers had severe damage. The high percent of linoleic acid in wheat germ oil probably exerted its beneficial effect here (Kritchevsky, 1956). We have no explanation as to why the octacosanol group ate more feed or was able to maintain its weight longer as the cholesterol levels and tissue damage were not different from those in the group without octacosanol.

The blood cholesterol levels rose rapidly for the first four weeks reaching a high of about 1,500 mg/100cc blood. Prior (1961) reported similar levels at one month, but reported increasing levels for the next four months to a high of 4000 mg. The highest maintenance level in this series was about 2,600 mg and all the animals that exceeded 3,000 mg progressed rapidly to terminal state. The difference between the two series must have been the added toxic factor in our feed which so greatly augmented the effects. Most of our animals were able to compensate for the excess cholesterol and maintained reasonably normal function for several weeks. At about the tenth week, we discovered that the animals were suffering from acute anemia. The



hematocrit readings dropped from a normal of 40 to as low as 16. The hematocrit reading did not necessarily correspond to the blood cholesterol levels because, as the terminal stages developed, the animal quit eating and the blood cholesterol would drop as the hematocrit dropped. Pinter and Bailey (1961) described a very active bone marrow in animals in a similar condition indicating rapid production of more fragile corpuscles, anemia probably resulting from rapid destruction rather than slower production of erythrocytes. Abnormality of the blood was also seen in unusually large numbers of eosinophils and fragile red blood cells. Ostwald and Shannon (1963) reported that in guinea pigs red blood cells were formed defectively and were quite fragile.

Liver damage included process of fat and cholesterol accumulation causing severe blanching from the normal reddish-brown color to ash-white as the normal cells of the liver were replaced with fat to the point of destroying the glycogen storing capacity of the liver. The first changes occurred around the central veins with the appearance of swollen cells with fine vacuolization caused by fat storage. As these cells became progressively filled, adjoining cells began to be affected and so the damage progressed from the central vein of the lobule to the arteries as affected cells became irregular, disrupting the cord structure of the liver and thus the sinusoids. Necrosis appeared in the worst areas. Degeneration progressed to functional failure of the liver (Prior, 1961). The fat content of the liver increased from a normal of 7% to an average of 20% with extreme cases running as high as 26%. The cholesterol levels increased from an average of 0.7% to 11%, with the highest levels reaching 18% which is higher than that reported by Graham, et al. (1959). There was no difference between the experimental groups in total fat, cholesterol content, or organ weights.

Spleen damage was also caused by a severe accumulation of lipid. Normally the macrophages of the spleen can phagocytize fat droplets and Tompkins (1942) proposed that macrophages can turn the cholesterol into a lipoprotein complex for transport. As the cholesterol levels remained high and the liver was unable to clear the serum effectively, the macrophages of the spleen increased greatly in number and size and considerable hemosiderin was found in them, indicating increased breakdown of blood cells. Macrophages were observed in the process of phagocytizing erythrocytes, leucocytes and other cellular debris. Some of the macrophages stained intensely PAS+ indicating degenerative processes. Lymphocytes disappeared from the cords perhaps by conversion into macrophages or by degeneration and phagocytosis by macrophages. Macrophages increased to the point of clogging the sinusoids and restricting the blood flow to a ring of open sinuses between the areas of worst damage. The lymphocytic nodules also became reduced in size. Fat infiltration was obvious grossly as the color turned from dark reddish-brown to pinkish-gray. Comparable splenic damage was described by Prior (1961), but his rabbits took much longer to develop the same pathological state. Total fat increased from a normal of 3.8% to 14% in groups 2, 3 and 4, but group 5 averaged only 8% fat. The cholesterol concentration increased from 0.4% to 8% in groups 2, 3 and 4, but group 5 had only 4% indicating less splenic damage. The weights of the spleens increased from 2.8 gm to 5 gm in groups 2 and 4, but only to 4 gm in groups 3 and 5.

Adrenal damage was not obvious grossly. The cholesterol content increased from 14.5% in the normal to 27% in the experimental with the most severe reaching 37%. The fat levels increased from 31 to 42% and reached as high as 54%, with group 5 showing a little less accumulation. The weight of the adrenals were significantly different with group 5 showing less increase than the other experimental groups (Table 2). Histologically, the cells of

the medulla and reticularis were affected first by progressive vacuolization spreading throughout the medulla, reticularis and fasciculata. The glomerulosa remained apparently normal until the last, showing only slight vacuolization.

All of the kidneys showed some damage, even in the control group possibly resulting from some component of the purified feed or as a result of using old rabbits for the experiment. Kidney weights were the same for all groups. Damage first appeared as vacuolization of the cells of the collecting tubule area followed by fatty degeneration of the tubules and then they were replaced with connective tissue. Hemosiderin in the blood vessels and macrophages in some animals indicated excessive erythrocyte destruction. Vacuolization and further necrosis eventually involved the entire convoluted tubule area and some glomeruli. Necrotic areas were visible on the surface of the kidney as gray or white patches. Somewhat comparable but less severe renal necrosis was reported by Prior (1961). No renal necrosis had been observed in the preliminary series.

The ovaries showed little evidence of pathology with only a few patches of PAS+ vacuolated cells found in the stromal tissue. No indication was found of infiltration into the stromal connective tissue transforming the ovary into an adrenal-like organ as reported by Prior (1961).

Evidence of nodules on the surfaces of the lungs were supported histologically by collections of vacuolated macrophages spread throughout the lung and on its surface. These macrophages contained hemosiderin as well as fat vacuoles. The arteries of the lung were filled with an excess of polycytes, leucocytes and enlarged macrophages, in many cases, blocking the small arterioles. The large arteries had plaques and often a collection of lymphocytes beside them. This damage appeared in all experimental groups.

The greatest general interest in cholesterol pathology has been centered

on the complications regularly encountered in the heart and major blood vessels. Plaque formation in the aorta seems to begin in the eddy immediately distal to the opening of a branch artery and expands from there, progressively lining the entire aorta, or setting up eddies that permit establishment of other plaques. Aortic plaques have been shown (Swell et al., 1963) to be high in cholesterol oleate, with deposition enhanced by saturated triglycerides. Such plaques were encountered to various degrees in all experimental groups at all sacrifices although less frequently and less intense in group 4 and much less in group 5, indicating that something in the wheat germ oil reduced the factors favorable for plaque formation. Early stages of plaque formation appeared to involve primarily fat cells, possibly macrophages, with later stages becoming distinctly fibrous. In the rabbit, plaque formation was found to begin at the orifices of the vertebral arteries, extending progressively proximally and distally. In all severe cases, plaques were present throughout the ascending, transverse and descending aorta, in some cases almost blocking the orifices of the branches. Only in a few cases were plaques found in the abdominal aorta.

The pulmonary artery became involved with plaque formation only in extreme cases (Fig. 42), and in no case were pulmonary artery plaques as extensive as aortic plaques in the same animal.

Heart damage showed first as accumulation of cholesterol-fat plaques on the bicuspid valves, first under the base of the valve next to the ventricle wall (Fig. 45) then progressively over the surfaces to the tips. In severe cases, fatty plaques covered both surfaces and the edge of the valves, part of the chordae tendinae and the papilla (Fig. 44, 46). As bicuspid valve plaques became severe, the aortic semilunar valves (Fig. 42), then the pulmonary semilunar valves developed plaques on the cusp side, and in a few

cases so severe that the plaques made the valves almost useless and all but blocked the coronary arteries.

Involvement of the heart wall was minimal with some indications of fatty degeneration in the papilla (by Sudan IV stain) and of the inner layer of the ventricular wall, as indicated by a high PAS+ reaction. Arterioles in the basal portion of the papillae began to swell about the time of first valvular plaquing progressively filling with fat cells, possibly macrophages, until the lumen was completely blocked. With the blocked arterioles, there occurred progressively; fat vacuolization, pycnotic nuclei, muscular necrosis and fibrosis. No case was found in which such conditions could be designated as the cause of death.

Accumulation of pericardial fluid has apparently received little attention during cholesterol studies, although it occurred in this series with considerable frequency. In several cases, severely involved with aortic and valvular plaques, pericardial fluid was present in such quantities as to suggest congestive heart failure. This condition occurred in all cholesterol groups in near terminal conditions.

#### CONCLUSIONS

Disturbances of metabolism and organ function by cholesterol and fat-rich food were extensive and resulted in death after only a few weeks. These effects were augmented by some factor in the purified feed, probably excessive free fatty acids resulting from heating during pelleting.

Liver function was progressively destroyed by accumulation of cholesterol and fat in the hepatic cells, disruption of the hepatic cords, and increased fibrosis. The spleen lost its blood storing function and became a mass of lipophages. The adrenal became loaded with cholesterol and fat and function

was probably diminished. Renal function was impaired by fatty degeneration and necrosis. Lung efficiency was reduced by blockage of arterioles and accumulation of fat-filled macrophages in the alveolae.

Cardiac damage included (1) development of fatty plaques on the valves, progressively involving the bicuspid, the semilunars, and the tricuspid; (2) blockage of arterioles by fatty accumulations, first in the bases of the papillae, then progressively into the ventricular wall and atrial wall, and (3) fatty degeneration and necrosis of myocardial cells resultant from decreased blood supply. The coronary arteries proper were not usually affected.

Fatty plaque development occurred in the aorta, beginning around the orifice of the carotid artery, and progressing throughout the thoracic aorta, then into the abdominal aorta. Plaques began distal to branch artery orifices and spread, becoming confluent in severe cases. Complete blockage of large arteries was not observed, but blood flow was severely restricted.

Anemia developed as part of the terminal syndrome, with fragile red blood cells, excessive eosinophils and packed blood cells reduced to less than 50% of normal.

Death resulted from a combination of (1) anemia, (2) functional failure of the liver, (3) kidney necrosis, and/or (4) heart disease, primarily blockage of arterioles and resultant necrosis.

Under the conditions of this experiment, wheat germ oil reduced the effects of the high cholesterol-fat diet only concerning plaque formation in the aorta and on the heart valves. Ameliorating effects on liver and spleen damage seen in previous experiments were masked by some factor in the purified feed, probably excessive free fatty acids.

## ACKNOWLEDGEMENTS

Acknowledgement is made to Dr. H. T. Gier for his understanding and patient guidance during the course of this experiment and in the preparation of this thesis. Acknowledgement is also made to my parents whose understanding and support in my school years have made this thesis possible.

Acknowledgement is also due the Department of Zoology for laboratory space and equipment. Financial support for the study was provided by Dr. E. Levin, VioBin Corporation, Monticello, Illinois.

The author would also like to express appreciation to fellow students for their suggestions and assistance in fulfilling the requirements for this degree.

## LITERATURE CITED

- Albrecht, W., F. W. Kahnt, R. Neher and W. Schuler. 1965. The effect of short-term cholesterol feeding on the development of aortic atheromatosis in the rabbit. 2. The influence of hypercholesterolemia on adrenal function. *J. Atheroscler. Res.* 5:369-378.
- Albrecht, W. and W. Schuler. 1965. The effect of short-term cholesterol feeding on the development of aortic atheromatosis in the rabbit. 1. The influence of hypercholesterolemia on lipid deposition in the aorta, liver and adrenals. *J. Atheroscler. Res.* 5:353-368.
- Albrink, M. J. 1962. Triglycerides, lipoproteins and coronary artery disease. *Arch. Int. Med.* 109:345-359.
- Alfin-Slater, R. B. and R. S. Morris. 1963. Vitamin E and lipid metabolism, p. 183-210. In R. Paoletti and D. Kritchevsky (ed.), *Advances in Lipid Research*, Vol. 1, Academic Press, New York.
- Anitschkow, N. Über experimentelle erzeugte Ablagerungen von Anisotropenlipoid-Substanzen in der Milz und in Knochenmark, *Beitr. Path. Anat.* 57:201-212, 1914. In D. Kritchevsky and R. Paoletti (ed.), *Advances in Lipid Research*. Academic Press, New York, 1963, p. 214.
- Ashworth, C. T. and J. M. Johnston. 1963. The intestinal absorption of fatty acid: a biochemical and electron microscopic study. *J. Lipid Res.* 4:454-460.
- Ashworth, C. T., R. Wrightsman and V. Buttram. 1961. Hepatic lipids. *Arch. Path.* 72:620-624.
- Bernick, S. and P. R. Patek. 1961. Effect of cholesterol feeding on rat reticuloendothelial system. *Arch. Path.* 72:310-320.
- Beveridge, J. M., W. F. Connell and C. Robinson. 1963. Effect of the level of dietary protein with and without added cholesterol on plasma cholesterol levels in man. *J. Nutr.* 79:289-295.
- Bieberdorf, F. A. and J. D. Wilson. 1965. Studies on the mechanism of action of unsaturated fats on cholesterol metabolism in the rabbit. *J. Clin. Invest.* 44:1834-1844.
- Bloor, W. R. 1916. The determination of cholesterol in the blood. *J. Biol. Chem.* 24:227-231.
- Borja, C. R., G. V. Vahouny and C. R. Treadwell. 1964. Role of bile and pancreatic juice in cholesterol absorption and esterification. *Amer. J. Physiol.* 206:223-228.
- Brainard, J. B. 1959. Effect of exercise on cholesterol metabolism and atherogenesis in rabbits on a high cholesterol diet. *Proc. Soc. Exp. Biol.* 100:244-246.



- Bremer, J. 1956. Species differences in the conjugation of free bile acids with taurine and glycine. *Biochem. J.* 63:507-513.
- Buchwald, H. and R. L. Gebhard. 1964. Effect of interstitial bypass on cholesterol absorption and blood levels in the rabbit. *Amer. J. Physiol.* 207:567-572.
- Constantinides, Paris. 1965. Experimental atherosclerosis in the rabbit, p. 276-290. In J. C. Roberts, Jr. and R. Straus, (ed.) *Comparative Atherosclerosis*. Hoeber Medical Division, Harper & Row, New York.
- Day, A. J., P. Gould-Hurst and G. K. Wilkinson. 1964. The incorporation of <sup>14</sup>C-labelled particulate cholesterol into lipoprotein by macrophages. *J. Atheroscler. Res.* 4:497-506.
- Ershoff, B. H. 1961. Report to VioBin Corporation, Monticello, Illinois, on effects of wheat germ oil on cholesterol-fed rabbits. Unpublished data.
- Farnell, D. R. and M. J. Burns. 1962. Dietary starch: effect on cholesterol levels. *Metabolism* 11:566-571.
- Fillos, L. C., R. Kaplan, R. S. Martin and F. J. Stare. 1958. Some aspects of the gonadal regulation of cholesterol metabolism. *Am. J. Physiol.* 193:47-51.
- Friedman, M. and S. Byers. 1954. Pathogenesis of dietary-induced hypercholesterolemia in the rabbit. *Amer. J. Physiol.* 179:201-215.
- Graham, W., J. Beare and H. Grice. 1959. Atheromatous changes in cholesterol-fed rabbits treated with eggplant extract. *Circ. Res.* 7:403-409.
- Grande, F. 1962. Dog serum lipid responses to dietary fats differing in the chain length of the saturated fatty acids. *J. Nutr.* 76:255-264.
- Hofmann, A. and B. Borgström. 1962. Physio-chemical state of lipids in intestinal content during their digestion and absorption. *Fed. Proc.* 21:43-50.
- Klein, P. and R. Dahl. 1961. The sensitivity of cholesterol esterification to environmental stress. *J. Biol. Chem.* 236:1658-1660.
- Kobernick, S., G. Niwayama and A. Zuchlewski. 1957. Effect of physical activity on cholesterol atherosclerosis in rabbits. *Proc. Soc. Exp. Biol. Med.* 96:623-628.
- Kritchevsky, D., A. Moyer., W. Tesar, R. McCandless, J. Logan, R. Brown and M. Englert. 1956. Cholesterol vehicle in experimental atherosclerosis. II. Influence of unsaturation. *Amer. J. Physiol.* 185:279-280.
- Kritchevsky, D. and S. Tepper. 1964. Influence of fatty acids on serum and liver cholesterol in rats. *Med. Exp.* 10:345-349.
- Kritchevsky, D. and S. Tepper. 1965. Factors affecting atherosclerosis in rabbits fed cholesterol-free diets. *Life. Sci.* 4:1467-1471.

- Lynn, W. S. Jr., R. H. Brown, N. C. Perryman and C. Weber. 1958. The effects of cholesterol-feeding in rabbits, p. 206-218. In G. Popjak, (ed.), *Biochemistry of Lipids*, Pergamon Press, New York, 1960.
- McMillan, G. C., B. Weigensberg and A. Ritchie. 1960. Effects of dietary fats in rabbits fed cholesterol. Severity of atherosclerosis in rabbits fed highly saturated and unsaturated fats. *Arch. Path.* 70:220-225.
- Meeker, D. R. and H. D. Kesten. 1941. Effect of high protein diets on experimental atherosclerosis of rabbits. *Arch. Path.* 31:147-162.
- Merrill, J. M. 1960. Effects of an unsaturated and saturated lipid on experimental cholesterol atherosclerosis in rabbits. *Proc. Soc. Exp. Biol. Med.* 105:268-270.
- Morin, R., S. Bernick, J. Mead and R. Alfin-Slater. 1962. The influence of exogenous cholesterol on hepatic lipid composition of the rat. *J. Lipid Res.* 3:432-438.
- Morin, R., Y. Shimma, S. Bernick and R. Alfin-Slater. 1963. Effect of palmitic, oleic and linoleic acids on hepatic and vascular lipid deposits. *J. Lipid Res.* 4:351-356.
- Murthy, S., S. Mahadevan and J. Ganguly. 1961. High cholesterol diet and esterification of cholesterol by the intestinal mucosa of rats. *Arch. Biochem. Biophys.* 95:176-180.
- Nath, M. C., and D. H. Brahmkar. 1961. Effect of Vit. B<sub>12</sub>, unsaturated fat and hydrolyzed Glucosecyclo-acetate on bile acid excretion in experimental hyperlipemia. *Proc. Soc. Exp. Biol. Med.* 108:337-341.
- Nath, N., R. Wiener, A. Harper, C. Elvehjem. 1958. Diet and cholesteremia. I. Development of a diet for the study of nutritional factors affecting cholesteremia in the rat. *J. Nutr.* 67:289-307.
- Nestel, P. J., and D. Steinberg. 1963. Fate of palmitate and of linoleate perfused through the isolated rat liver at high concentrations. *J. Lipid Res.* 4:461-469.
- Ostwald, R. and A. Shannon. 1964. Composition of tissue lipids and anaemia of guinea pigs in response to dietary cholesterol. *Biochem. J.* 91:146-154.
- Palay, S. and L. Karlin. 1959. An electron microscopic study of the intestinal villus II. The pathway of fat absorption. *J. Biophys. Biochem. Cytol.* 5:373-383.
- Pinter, G. and R. Bailey. 1961. Anemia of rabbits fed a cholesterol-containing diet. *Am. J. Physiol.* 200:292-296.
- Printer, K. G., O. N. Miller and J. C. Hamilton. 1964. Effect of monoglycerides on absorption of cholesterol from the intestine and turnover rate of cholesterol esters in plasma and liver of the rat. *Proc. Soc. Exp. Biol. Med.* 115:318-323.

- Prior, J. T., D. Kurtz and D. Ziegler. 1961. The hypercholesterolemic rabbit. An aid to understanding atherosclerosis in man. *Arch. Path.* 71:672-684.
- Reiser, R., M. C. Williams, M. F. Sorrels and N. L. Murtz. 1963. Biosynthesis of fatty acids and cholesterol as related to diet fat. *Arch. Biochem. Biophys.* 102:276-285.
- Seidel, J. C. and A. E. Harper. 1963. Diet and cholesterolemia: VII. Effects of methionine, ethionine and p-fluorophenylalanine. *J. Lipid Res.* 4:75-80.
- Simon, R. C., W. S. Still and R. M. O'Neal. 1961. The circulating lipophages and experimental atherosclerosis. *J. Atheroscler. Res.* 1:395-400.
- Sodeman, W. A. and J. T. Logue. 1960. Effect of environmental temperature on cholesterol induced aortic atherosclerosis in the rabbit. *Proc. Soc. Exp. Biol. Med.* 103:255-261.
- Swell, L., M. D. Law and C. R. Treadwell. 1963. Dynamic aspects of cholesterol ester metabolism in rabbits with atherosclerosis. *J. Nutr.* 81:263-270.
- Swell, L., M. D. Law and C. R. Treadwell. 1964. Role of the liver in the metabolism of exogenous cholesterol esters. *Arch. Biochem. Biophys.* 105:541-553.
- Tompkins, E. H. 1946. Reaction of the reticuloendothelial cells to subcutaneous injections of cholesterol. *Arch. Path.* 42:299-319.
- Van Handel, E. and D. B. Zilversmit. 1959. Comparison of atherogenesis in rabbits fed liquid oil, hydrogenated oil, wheat germ and sucrose. *J. Nutr.* 69:202-208.
- Wells, W. W. and S. C. Anderson. 1959. The increased severity of atherosclerosis in rabbits on cholesterol-lactose containing diet. *J. Nutr.* 68:541-549.
- Wilkins, J. A. and L. H. Krut. 1965. The effect of glucose on the crystallization of cholesterol. *J. Atheroscler. Res.* 5:516-523.
- Wolf, S., W. McCabe, J. Yamamoto, C. Adsett and W. Schottstoedt. 1962. Changes in serum lipids in relation to emotional stress during rigid control of diet and exercise. *Circulation* 26:379-387.

APPENDIX

Table 1. FEED COMPONENTS USED FOR THE TESTING OF CHOLESTEROL EFFECTS.

Components	Group Number				
	I	II	III	IV	V
Casein <sup>1</sup>	25	25	25	25	25
Dextrin <sup>2</sup>	40	40	40	40	40
Cellulose <sup>3</sup>	10	10	10	10	10
Salt Mix <sup>4</sup>	5	5	5	5	5
Vitamin <sup>5</sup>	1	1	1	1	1
Fat <sup>6</sup>	10	10	10	8	--
Cholesterol <sup>7</sup>	--	1.6	1.6	1.6	1.6
Octacosanol <sup>8</sup>	--	--	0.02	--	--
Wheat Germ Oil <sup>9</sup>	--	--	--	2.0	10.0
Corn Cob Meal <sup>10</sup>	20	20	20	20	20

1. Casein, purified and high protein-General Biochemicals Inc. (GBI).
2. Dextrin (white technical)-Nutritional Biochemicals Corp. (NBC).
3. Alphacel (non-nutritive cellulose)-NBC.
4. Wesson Salt mix from GBI (modified Osborne-Mendel). Given as %.
  - 21.000 calcium carbonate
  - 14.900 calcium phosphate tribasic
  - .039 copper sulfate
  - 1.470 ferric phosphate
  - 9.000 magnesium sulphate, anhydrous
  - .020 manganous sulfate, anhydrous
  - .009 potassium aluminum sulfate
  - 12.000 potassium chloride
  - .005 potassium iodide
  - 31.000 potassium phosphate, monobasic
  - 10.500 sodium chloride
  - .057 sodium flouride

Table 1. (Continued)

5. Vitamin fortification mixture-GBI. Supplies the following vitamin content when added at a 1% level:

gm/100 lbs.

4.50	vitamin A conc. (200,000 U.S.P. u/gm)
.25	vitamin D conc. (400,000 U.S.P. u/gm)
5.00	alpha tocopherol
45.00	ascorbic acid
5.00	i-inositol
75.00	choline chloride
2.25	menadione
5.00	p-aminobenzoic acid
4.50	niacin
1.00	riboflavin
1.00	pyridoxine HCL
1.00	thiamine HCL
3.00	calcium pantothenate

mgm/100 lb.

20.00	biotin
90.00	folic acid
1.35	vitamin B <sub>12</sub>
----	corn starch diluent

6. Fat supplied by the lard oil "Mellocrust" from Swift & Co. of Kansas City, Kansas.
7. Cholesterol U.S.P. from NBC.
8. Synthetic octacosanol from VioBin Corporation of Monticello, Illinois.
9. Wheat germ oil from VioBin Corporation, Monticello, Illinois.
10. Corn cob meal added by the K.S.U. Milling department to facilitate pelleting as the original purified feed would not mold into pellets.

Table 2. Organ weights at sacrifice

Animal number	Week Sacrificed	Liver, gm	Spleen, gm	Adrenal, gm	Heart, gm
11	4	160	6.1	0.9	12.5
12	7	120	2.1	1.2	8.1
13	10	119	3.3	0.8	10.9
14	7	107	1.5	0.6	8.1
15	13	111	3.0	0.8	7.9
16	10	111	2.9	0.6	10.4
18	13	102	2.0	0.5	9.9
19	4	98	1.8	0.7	7.2
Average		116	2.8	0.8	9.2
21	4	---	6.4	0.6	10.0
22	13	141	6.3	1.1	9.5
23	7	143	9.8	1.3	9.9
25	9	139	5.8	2.0	8.5
26	4	78	3.0	0.5	9.4
27	13	104	3.8	0.8	8.0
28	7	115	2.5	0.6	8.0
29	10	128	3.7	1.1	9.5
Average		121	5.2	1.0	9.1
31	4	113	4.1	1.0	10.0
32	4	140	5.2	---	10.0
33D*	11	199	6.5	1.1	9.5
34	7	138	4.8	1.0	8.0
35	10	168	5.1	0.7	6.3
36	13	127	2.9	0.9	7.8
37	7	144	3.4	1.1	11.0
38	10	105	4.6	0.8	6.9
39	13	134	1.8	1.9	7.0
Average		141	4.3	1.1	8.5
41	4	126	9.0	1.2	---
42	13	137	3.9	1.4	9.9
43	7	131	6.3	0.7	9.6
44	7	98	1.8	1.1	10.0
45	10	119	9.2	1.1	9.3
46D*	9	132	4.4	1.2	10.4
47	4	100	1.5	1.0	7.5
48D*	13	148	6.4	1.5	---
49	10	126	2.1	2.0	6.0
Average		124	5.0	1.2	9.0
51	7	145	3.2	0.6	---
52	4	79	3.5	0.9	9.0
53	9	134	7.5	1.0	9.5
54	13	139	4.3	1.3	9.2
55	10	124	6.4	0.8	7.5
56	7	92	3.2	1.6	8.9
57	10	122	2.7	0.6	11.5
58	11	138	4.0	0.7	9.8
59	4	---	1.1	1.1	8.0
Average		122	4.0	0.9	9.2

\*Animals autopsied soon after death

Table 3. Tissue fat and cholesterol levels at sacrifice

Animal number	Week sac.	Liver		Spleen		Adrenal	
		% C	% Fat	% C	% Fat	% C	% Fat
11	4	0.4	4.0	0.4	2.8	16.2	31.2
12	7	1.2	9.2	0.4	5.6	14.6	33.2
13	10	0.5	9.2	0.4	2.4	19.5	41.6
14	7	1.0	8.0	0.6	3.6	16.8	44.0
15	13	0.6	3.2	0.4	4.4	17.0	32.0
16	10	0.3	8.4	0.4	3.2	3.5	11.6
18	13	0.8	22.4	0.4	2.8	8.0	26.0
19	4	0.6	5.6	0.5	5.6	20.0	32.0
Average		0.7	6.8	0.4	3.8	14.5	31.5
21	4	7.4	14.8	4.3	8.0	27.6	40.0
22	13	11.2	18.0	8.2	14.0	29.2	44.0
23	7	13.1	20.4	8.4	14.0	28.0	50.4
25	9	5.6	12.8	8.2	14.0	24.0	33.6
26	4	---	---	---	---	14.6	28.0
27	13	12.7	14.8	13.4	18.4	34.7	41.2
28	7	15.6	24.0	4.9	8.4	28.4	48.0
29	10	13.8	25.2	12.3	20.0	33.0	49.2
Average		11.3	18.6	8.5	13.8	27.4	41.8
31	4	6.0	12.0	4.7	8.8	35.0	52.0
32	4	6.9	12.4	8.1	13.2	29.2	35.2
33D*	11	13.4	20.4	17.0	30.8	30.0	36.8
34	7	7.5	16.4	3.0	6.0	15.2	24.4
35	10	12.0	24.4	2.8	6.2	29.2	42.8
36	13	13.1	23.2	8.4	15.2	30.9	40.8
37	7	13.4	22.0	3.5	6.4	30.0	46.0
38	10	13.4	23.2	5.6	9.6	26.4	43.6
39	13	11.6	20.0	7.2	30.0	37.3	46.8
Average		11.2	19.3	7.2	15.0	30.9	43.0
41	4	9.6	17.2	7.3	12.0	31.0	45.2
42	13	18.3	20.8	10.1	16.0	37.2	48.4
43	7	12.3	20.4	14.2	20.4	36.0	52.8
44	7	9.0	26.4	3.9	8.8	30.0	49.6
45	10	14.6	26.8	13.4	19.2	28.0	43.6
46D*	9	---	---	4.3	8.2	24.5	45.6
47	4	3.6	9.6	---	---	32.0	43.2
48D*	13	10.1	18.8	4.3	14.8	22.0	34.0
49	10	10.5	21.2	7.4	12.0	26.5	38.8
Average		11.0	20.2	8.1	13.9	27.5	44.6
51	7	13.4	23.2	5.2	8.8	32.0	45.6
52	4	3.5	16.8	0.9	3.2	16.2	26.4
53	9	14.6	25.6	3.9	7.2	26.4	39.0
54	13	9.2	18.0	8.5	14.0	34.1	46.8
55	10	13.8	25.2	5.3	8.0	33.7	44.8
56	7	12.0	24.0	2.5	6.4	37.2	53.2
57	10	10.8	25.6	3.1	6.8	18.1	31.2
58	11	11.2	25.6	6.0	7.2	24.2	35.6
59	4	7.4	15.6	1.6	8.8	26.5	41.6
Average		10.7	22.2	4.1	7.9	27.6	40.5

\*Animals autopsied soon after death



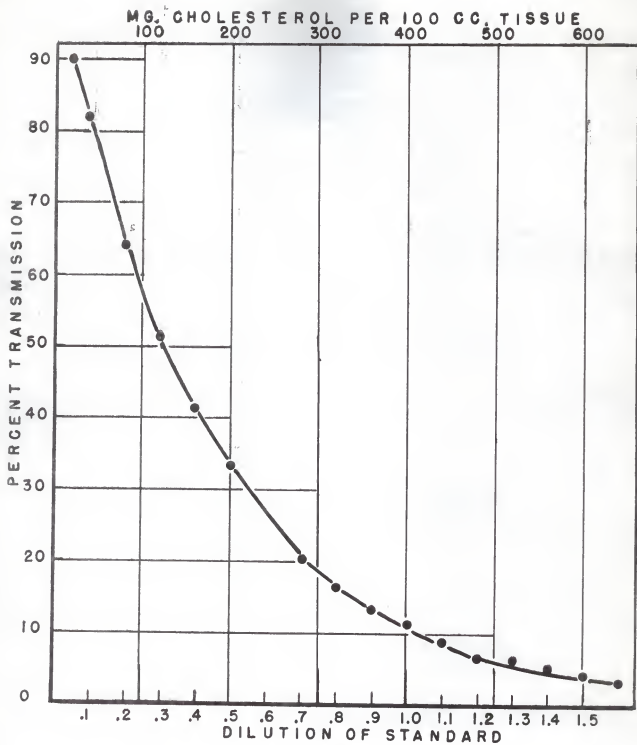


Fig. 1. The standard chart used to calculate total cholesterol by comparing % transmittance of the experimental sample to the curve obtained by diluting a known standard solution.

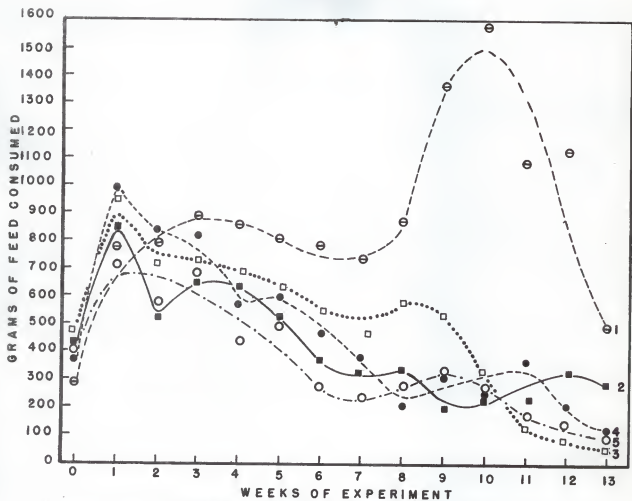


Fig. 2. Average feed consumption per week. The controls ate well, but feed consumption in the experimental groups tended to be erratic and they ate progressively less throughout the experiment.

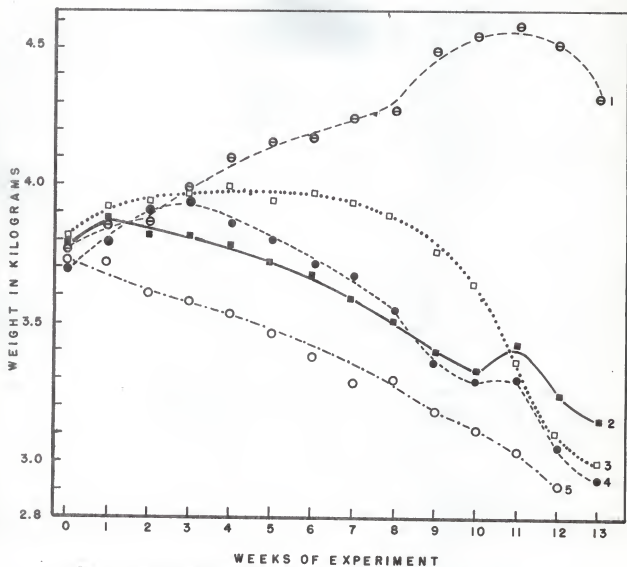


Fig. 3. Group average weights per week. The controls continued to gain throughout the experiment, but all the experimental groups lost weight progressively, with the most severe loss in group 5.

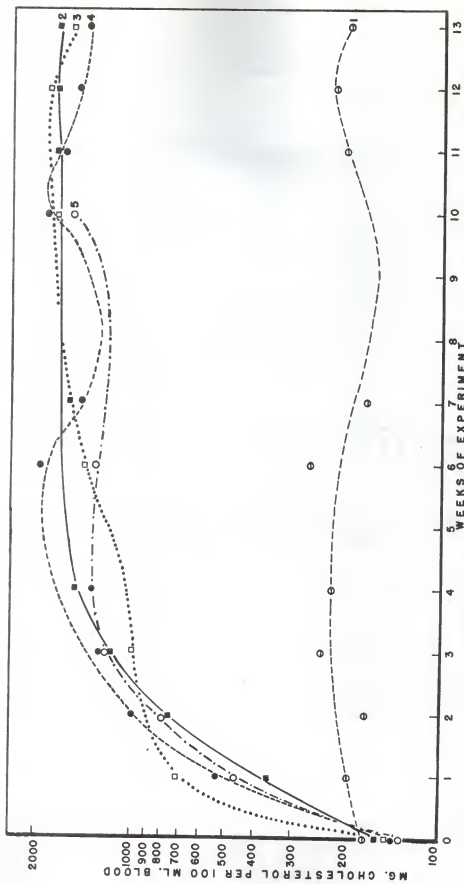


FIG. 4. Group average blood cholesterol levels. Blood cholesterol in all experimental groups rose rapidly until 4 weeks, then leveled out somewhat. There was no difference between the experimental groups.

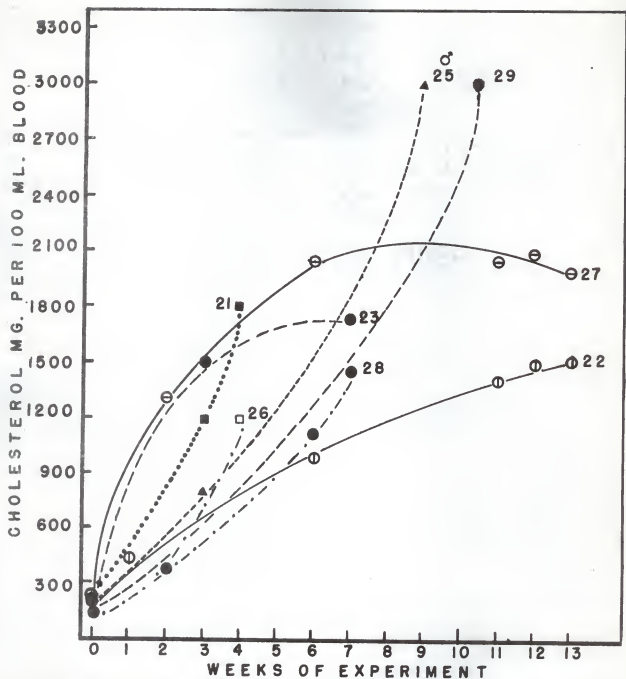


Fig. 5. Individual blood cholesterol levels for group 2. Some rabbits were unable to compensate for high fat-cholesterol intake and their blood levels rose continuously, while others were able to keep the blood level at a lower concentration.

#### EXPLANATION OF FIGURES

These figures were chosen to illustrate the types of damage found in the groups, and are not meant to describe the damage in any particular group.

6. Liver and spleen showing normal reddish-brown liver and brown spleen of normal size. Rabbit no. 13.

7. The beginning of progressive blanching of the liver and spleen caused by deposition of fat and cholesterol in the cells. The spleen was enlarged but still had a normal color. Animal no. 21.

8. A more severe blanching of the liver to a yellow-brown. The spleen had become light brown. Animal no. 57.

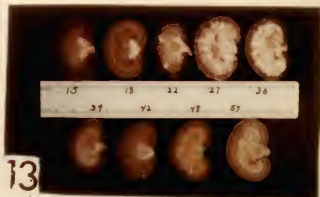
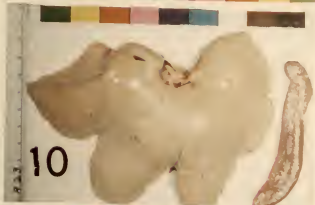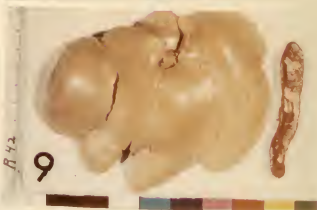9. More blanching of the liver beyond that in Fig. 8. The condition of the spleen was much worse here with the color lightened to a bright red and enlargement. Animal no. 42.

10. The most severe blanching of the liver to an ash-white. The spleen was greatly enlarged and a reddish-gray indicative of high cholesterol and fat content. Animal no. 23.

11. The liver and spleen damage were not necessarily related as here we had an extremely bad liver and a spleen which was still in fairly good condition. The opposite condition could also be true. This figure also demonstrates the gall bladder enlargement which was found in several animals. Animal no. 37.

12. Many of the livers were necrotic and green with jaundice. The spleen was enlarged and bright red. Animal no. 25.

13. Sagittal sections of the kidneys of the last sacrifice group with white streaks of fat damaged areas extended throughout the width of the organ, severely affecting several animals of each experimental group. Animal numbers accompany each section.



#### EXPLANATION OF FIGURES

14. Liver section showing the bright PAS+ reaction and the typical cord arrangement of the cuboidal cells with the venous sinuses between the cords. There was an artery in the upper right corner. Animal no. 11. (PAS- 220X)

15. The first stage of liver damage with the enlarged vein on the right side lined by swollen foam cells, shown grossly in Fig. 7. Animal no. 21. (PAS-220X)

16. Liver damage with destruction of the cords becoming evident, spread from the area of a vein in the upper left corner to an artery just off the field in the lower right corner of the figure. Animal no. 22. (PAS-170X)

17. Liver damage progressed toward an artery on the right side from the area of a vein on the left side. Fig. 16 and 17 show the clumping of the glycogen in the cells as they became finely vacuolated, shown grossly in Fig. 9. Animal no. 42. (PAS-220X)



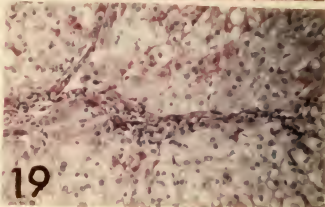
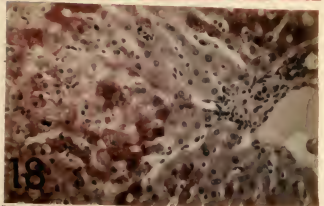
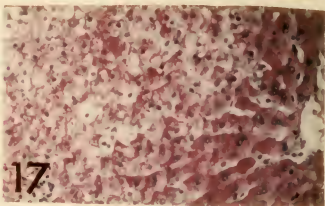
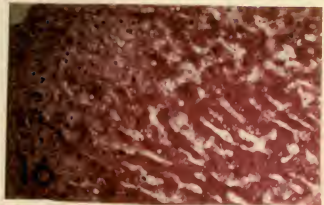
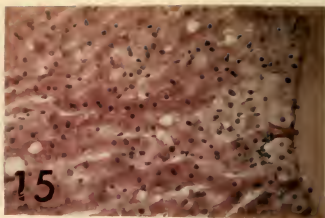
18. Progressive involvement of the arteries with the appearance of a "new" type cell. It was the size of the normal liver cell, but its cytoplasm was pale, homogeneous blue when treated with PAS stain indicating that the cell had lost its glycogen storing capacity. Animal no. 29. (PAS-220X)

19. More complete destruction of the cord structure around the arteries and beginning fibrosis especially around the veins. Animal no. 36. (PAS-220X)

20. Almost complete destruction of the cells of the liver and considerable fibrosis. This was the terminal condition of damage. Animal no. 35. (PAS-220X)

21. Blood smear illustrating the large number of eosinophils found in the blood of almost all animals in the last weeks of the experiment. These cells and also the red blood cells were fragile and fragmented easily. Animal no. 51. (Giemsa-1200X)





## EXPLANATION OF FIGURES

22. Normal histological picture of the spleen with the splenic nodules of lymphocytes comprising the white pulp, and venous sinuses separated by cords of lymphocytes and macrophages making up the red pulp. Animal no. 13. (PAS-200X)

23. Beginning damage as seen in a reduction in the size of the nodules, a reduction in the number of lymphocytes in the cords of the red pulp, and a great increase in the amount of hemosiderin in the macrophages in the sinuses. Animal no. 31. (PAS-200X)

24. Further reduction in the size of the nodules and expansion of the artery of the nodule with the presence of lipophages. There was an increase in the number of macrophages and some of these had PAS+ inclusions. Shown grossly in Fig. 9. Animal no. 42. (PAS-200X)

25. The red pulp cord structure has been replaced by lipophages which were beginning to clog the sinuses of the spleen. The lymphocytes had almost disappeared from the red pulp. Animal no. 29. (PAS-200X)

26. Higher magnification of one sinus and part of another sinus in the red pulp showing a macrophage loaded with brown hemosiderin, macrophages filling the sinuses, the absence of lymphocytes from the cords separating the sinuses and the large number of polycytes. Animal no. 36. (PAS-670X)

27. A greatly expanded sinus of the spleen containing many macrophages, some with hemosiderin and some with PAS+ inclusions. The cords have been taken over by macrophages which had PAS+ inclusions. Animal no. 42, shown grossly in Fig. 9. (PAS-200X)

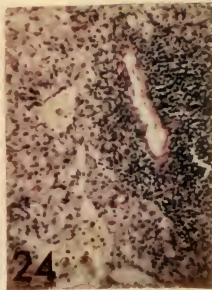
28. A "plaque" which had formed on the surface of the spleen consisting of a collection of foam cells and some connective tissue. These were found with either an intact or disrupted capsule. Animal no. 23. (Mallory's-200X)

29. A higher magnification of a splenic sinus in the terminal stage. The macrophages have taken over the red pulp almost entirely and crowded out the red blood cells, a few of which can be seen between the macrophages at the periphery of the sinus. Animal no. 45. (Mallory's-670X)

30. Lung involvement as shown by the presence of macrophages in the arteries of the lung, often to the point of blocking the small lumens of arterioles. Animal no. 39. (Giemsa-670X)



23



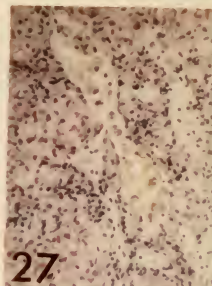
24



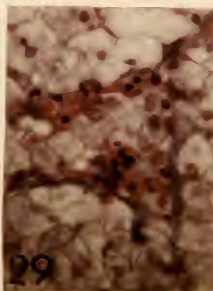
25



26



27



29



30

#### EXPLANATION OF FIGURES

31. The medulla and reticularis of an adrenal with moderate damage with the appearance of round foamy cells replacing the columnar dark cells of the normal medulla and the appearance of PAS+ cells throughout the reticularis. Animal no. 12. (PAS-200X)

32. The disruption of the cord arrangement of the adrenal fasciculata by the development of irregular foamy cells, some of which greatly enlarged and eventually became PAS+. Animal no. 22. (PAS-200X)

33. Adrenal glomerulosa with normal cord arrangement, but the beginning of vacuolization has occurred. The cord structure of this zone usually remained intact. Animal no. 45. (PAS-200X).

34. The collecting tubule region of a kidney with expanded blood vessels containing macrophages which seemed to be blocking the vessel. Animal no. 15. (Mallory's-200X)

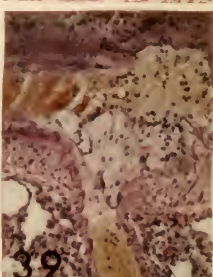
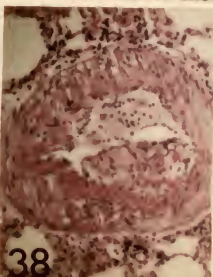
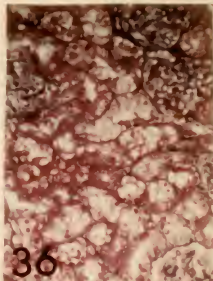
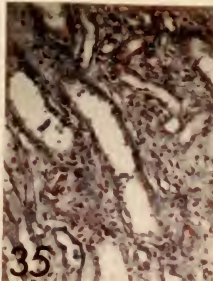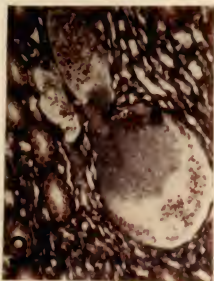

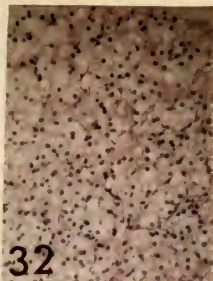35. The collecting tubule area of a kidney showing extreme damage. The cells of the tubules have undergone fatty degeneration and fibrosis has become prominent. The remaining tubules have greatly enlarged lumens. Animal no. 38. (Mallory's-200X)

36. The cortex of the kidney with the proximal collecting tubules which were becoming vacuolated and foamy. Animal no. 25. (Mallory's-200X)

37. The collecting tubule area with the blood vessels greatly enlarged and filled with macrophages. The collecting tubules were gone and had been replaced with connective tissue. Animal no. 38. (Mallory's-200X)

38. A large artery in the lung which has been almost obstructed with a large plaque. Animal no. 27. (PAS-200X)

39. A major artery in the lung which has been cut at an area where a branch was given off. This shows the blocking of the opening of the branch by macrophages and breakdown of the blood was indicated by the large amount of hemosiderin. Animal no. 25. (PAS-200X)



#### EXPLANATION OF FIGURES

40. Normal heart and aorta. The heart has been split to show the interior of the left ventricle and atrium. The aorta has been opened to show the segmental arteries given off from it. Animal no. 13.

41. Heart and aorta with plaquing on the semilunar bicuspid valves, in the aorta and in the pulmonary artery. The left atrial wall also had plaques. Animal no. 45.

42. Heart and aorta which were clear of plaques except around the valves. The ends of the papillary muscles had extensive areas of fatty degeneration. Animal no. 29.

43. One of the worst cases of plaquing with all of the previously mentioned areas being affected. Animal no. 36.

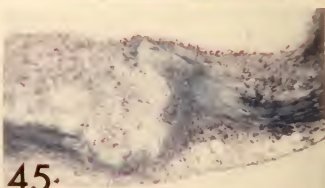
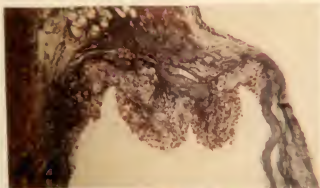
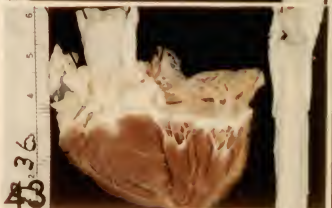
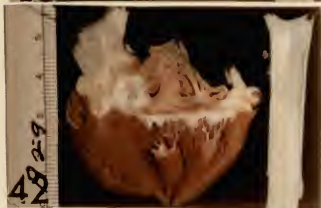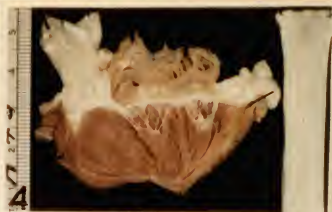
44. Section of the bicuspid valve with a small plaque forming under the base of the valve. The atrium was at the top and the ventricle below. Animal no. 36. (Mallory's-40X)

45. Section of the bicuspid valve proper with plaques covering the surfaces of the valve. Animal no. 54. (Mallory's-125X)

46. The musculature of the heart with a larger artery and an arteriole which were completely blocked by fatty plaques. Animal no. 54. (Mallory's-125X)

47. Section of the aortic wall through a beginning plaque with an aggregation of foam cells under the endothelium. Animal no. 56. (Mallory's-125X)

48. Section through a mature plaque in the aorta with foam cells and connective tissue, covered with an intact endothelium. Animal no. 48. (Mallory's-125X)



CHOLESTEROL PATHOLOGY IN THE RABBIT

by

MARIE MACDALENE HILDEBRAND

B. A., Concordia College, 1964

---

AN ABSTRACT OF A MASTER'S THESIS

submitted in partial fulfillment of the

requirements for the degree

MASTER OF SCIENCE

Department of Zoology

KANSAS STATE UNIVERSITY

Manhattan, Kansas

1967



## ABSTRACT

Effects of wheat germ oil and octacosanol on cholesterol metabolism were tested by the use of 45 mature rabbits divided into five groups. A base feed of casein (25), dextrin (40), cellulose (20), vitamin (1), Wesson salt mix (5), and corn cob meal (20) was pelleted with: Group 1, lard oil (10); Group 2, lard oil (10), cholesterol (1.5); Group 3, lard oil (10), cholesterol (1.5), octacosanol 0.02; Group 4, lard oil (8), wheat germ oil (2), cholesterol (1.5); and Group 5, wheat germ oil (10), cholesterol (1.5). Blood samples for cholesterol determination were taken weekly. Two animals from each group were sacrificed at 4, 7, 10 and 13 weeks. Portions of liver, spleen and adrenal were prepared for cholesterol determinations, and portions of these plus gonad, lung, kidney, aorta and heart were fixed in Bouin's fluid, sectioned and examined for pathology.

Blood cholesterol levels rose rapidly, then became somewhat stabilized at about 1500 mg/100 ml blood after five weeks. A few animals, regardless of group, were unable to compensate and the blood cholesterol in these animals rose to 3000-4000 mg/100 ml after which the animal soon died if it was not sacrificed.

Cholesterol effects were first observable in the liver, with pathology obvious at four weeks. Grossly, the liver became progressively grayed from the normal red-brown to ash-white, and in terminal stages, it was firm and greenish. Irregularly, the gall bladder was greatly enlarged. Early damage consisted of vacuolization of the liver cells around the central vein of the lobule, progressively expanding toward the artery, resulting in disruption of the liver cords and loss of glycogen storing capacity. No group differences were found. Cholesterol content of the livers increased proportionately with the histological damage from 0.7% in the controls to as much as 18% in

extreme cases. Total fat increased from 6.8% to 25%. Spleens became enlarged to almost double normal weight and changed in color to mottled pinkish-gray. Macrophages of the splenic cords greatly increased in number and size, became filled first with hemosiderin from disintegrating blood cells, then filled with debris from lymphocytes and finally with numerous fatty vacuoles. Splenic nodules were greatly reduced and lymphocytes all but disappeared except from the cores of the original nodules. The cholesterol content increased from 0.4% to 8% in groups 2, 3 and 4, but only to 4% in group 5.

Adrenal glands increased appreciably in size, cells of the fasciculata and reticularis became expanded with fat vacuoles, and the medullary structure was disrupted by progressive fatty degeneration. Cholesterol content increased from the normal 15% to as much as 35% in extreme cases. The 10% wheat germ oil group showed less enlargement and less fat accumulation.

Kidney damage appeared, unpredictably, at all sacrifice periods, with vacuolization of the convoluted tubules and necrosis of the collecting tubules. In severe cases, areas of fatty degeneration occurred in streaks from the papilla to the capsule, involving all kidney structures. There was no group difference.

Ovaries, generally, showed little effects from the high fat-cholesterol diet. In several animals, fat vacuoles were found in the stromal tissue. Pregnant females consistently showed less pathology and lower cholesterol levels.

Lungs became involved by 7 to 10 weeks, with accumulation of lipophages in the veins and in some alveoli. At 10 to 13 weeks, some blockage of arterioles with fatty plaques had occurred. There was no difference between groups.

The aorta developed fatty plaques immediately below each branch opening,

beginning with the brachiocephalic trunk and progressing toward the diaphragm. Progressively, the plaques increased in size and thickness until nearly all of the thoracic aorta was lined. Plaquing was worst in the fat-cholesterol group, and became progressively less in groups 3, 4 and 5. Heart damage appeared progressively as: granular plaques under the base of the mitral valve, plaques on the valve, fatty degeneration of the papilla muscularis, fatty blockage of arterioles in the base of the papilla and adjoining ventricular wall, plaques on the aortic semilunar valves, plaques in the pulmonary artery and pulmonary semilunar valves, and finally in the left atrium. Although organ damage was severe, death probably resulted from a combination of liver failure and severe anemia.