

SOME FACTORS AFFECTING GLYCOGEN CONTENT IN THE BOVINE ENDOMETRIUM

by

LARRY LEE LARSON

B. S., Kansas State University, 1962

---

A MASTER'S THESIS

submitted in partial fulfillment of the

requirements for the degree

MASTER OF SCIENCE

Department of Dairy and Poultry Science

KANSAS STATE UNIVERSITY  
Manhattan, Kansas

1965

Approved by:

  
Major Professor

LD  
2668  
T4  
1965  
L334  
C 2  
Document

TABLE OF CONTENTS

INTRODUCTION . . . . .	1
REVIEW OF LITERATURE . . . . .	2
MATERIALS AND METHODS . . . . .	19
OBSERVATIONS . . . . .	21
Bovine Endometrium During Estrus . . . . .	21
Bovine Endometrium from Two to Four Days Postestrus . . . . .	26
Bovine Endometrium from Five to Seven Days Postestrus . . . . .	27
Bovine Endometrium from 8 to 14 Days Postestrus . . . . .	30
Bovine Endometrium from 15 to 19 Days Postestrus . . . . .	32
Bovine Endometrium after Ovariectomy . . . . .	38
Endometrium in Ovariectomized Cows Following Estrogen Stimulation . . . . .	39
Endometrium in Ovariectomized Cows under Progesterone Stimulation . . . . .	40
Endometrium in Ovariectomized Cows under Combined Estrogen-Progesterone Treatment . . . . .	44
DISCUSSION . . . . .	48
SUMMARY . . . . .	57
ACKNOWLEDGMENTS . . . . .	60
REFERENCES . . . . .	61
APPENDIX . . . . .	65

## INTRODUCTION

Sterility, low conception rates, and reproductive abnormalities are problems of great concern to the livestock industry. Much time and effort have been directed toward solving these problems; however, many of the studies have been concerned with male fertility and processing and preserving sperm.

Histological and biochemical studies of the uterus have been conducted in a number of species in an effort to gain a broader understanding of the reproductive phenomena in the female. Endometrial studies have been conducted; but, considerable controversy and confusion among authors is evident from published reports. Cyclic changes in the endometrium, including glycogen content and alkaline phosphatase activity, have been observed. Investigators do not agree in all respects and have not been able to satisfactorily explain the hormonal stimuli responsible for the changes. It appears that the issues are confounded by species variations.

The bovine has been a relatively neglected species. Only a few histological studies of the bovine endometrium have been conducted with the tissue samples usually obtained at the time of slaughter.

The present study was conducted in an effort to identify cyclic changes in the bovine endometrium using tissue biopsies obtained from clinically normal cows. The histological and cytological changes were compared with results from a study of similar tissues obtained at slaughter. Ovariectomized cows were treated with physiological levels of steroids in an attempt to determine the role of these hormones in endometrial changes.

## REVIEW OF LITERATURE

According to Marion and Gier (33) the uterus of a sexually mature virgin dairy heifer weighs approximately 400 grams, is 150 mm from cervix to anterior tip and 120 mm from left to right across the widest curve of the horns. The cervix is 45 mm wide and 60 mm long with four partially spiralled rings internally closing the cavity. The body of the uterus is slightly narrower than the cervix (40 to 45 mm) and may be more than 20 mm long. The two horns are fused medially for nearly half their length. The anterior two-thirds of each horn curves laterally, and posteriorly in a 360 to 450° coil. Each horn is approximately 25 mm in diameter in the basal third, tapering around the curve to possibly 10 mm in diameter near the tip. The tip of each horn is directly continuous with the Fallopian tube.

The wall of the bovine uterus consists of three layers: (a) a thin outer covering, the perimetrium, (b) a thick muscular layer, the myometrium, and (c) an inner lining, the mucous membrane, the endometrium (Skjerven, 46). According to Marion and Gier (33) the bovine endometrium is comprised of several distinct layers. Next to the uterine lumen is a variable single-cell layer of pseudostratified columnar cells which are directly continuous with the lining of the uterine glands and which rest on a layer of flattened stratum compactum cells, the basement membrane. The stratum compactum is a layer of connective tissue oriented against the uterine epithelium, normally 12 to 16 cells thick (approximately .2 mm). They state that this layer is honeycombed with capillary net, but is distinct from the other layers because of the orientation and uniform, fibrous nature of the cells. Between the stratum compactum and the circular muscle layer is the stratum spongiosum which is comprised of (a) loose, connective tissue cells,

(b) uterine glands, and (c) a network of blood vessels (33).

The endometrium is also differentiated into two parts linearly: (a) the intercaruncular area and (b) the caruncles, which are the sites of attachment of the fetal membranes to the uterine mucosa (46). According to Marion and Gier (33) characteristic circular areas with slightly depressed centers appear at intervals over the surface of the uterine epithelium. These discs mark the caruncles. Each uterine horn typically has four rows of caruncles with 12 to 16 caruncles in each row. They further state that each caruncle is approximately 2 mm in diameter and is characterized by (a) having no uterine glands (b) a specialized tissue area (the discus), and (c) a highly developed vascular bed.

Based on tissues obtained at slaughter Marion and Gier (33) found that the intercaruncular epithelium varied with the estrous cycle. They reported that from one to three days postestrus it consisted of low columnar to cuboidal cells about 8 to 12 micra in height and there were approximately six cells per 40 micra of epithelium. Between 8 to 12 days postestrus the cells had increased in number to about 20 cells per 40 micra of epithelium and in height to approximately 30 micra. At 18 days postestrus about half of the nuclei appeared pycnotic and the intercaruncular epithelium consisted of a pseudostratified tall columnar layer approximately 30 to 40 micra in height. Weber et al. (52) stated that the uterine epithelium was highest during estrus while the glandular epithelium was lowest at this stage. According to Westh and Nerman (54) the uterine epithelium was highest at estrus and lowest about two to five days postestrus. Asdell (4) reported that the epithelial cells of the uterus are tall columnar prior to estrus and increase in height as estrus approaches. The nuclei during estrus are large, oval and clear except for strands of chromatin, and their position in

the cell is basal. Towards the end of heat these cells discharge their contents, so that by the second day the remaining cells are low and cuboidal. At this stage, the ratio of cell length to nucleus length is lowest. The effects of progesterone on the uterine epithelium is seen in the growth that begins to occur from the time of ovulation onward, so that by the twelfth day these cells have reached their greatest height.

The uterine glands originate embryonically as evaginations from the uterine epithelium and so are primarily made up of epithelial cells (33). Skjerven (46) stated that the uterine glands are branched, coiled, tubular glands which terminate near the myometrium. As the glands pass superficially they become straighter and their lumina become larger. The caruncles contain no uterine gland openings on to their surface and no glands in the stratum compactum. The edges of the stratum spongiosum beneath the caruncles may contain glands which extend from the surrounding spongiosum. Marion and Gier (33) reported that the uterine epithelium is continuous with the epithelium of the uterine glands and the necks of uterine glands occur at intervals of .5 to 1 mm over the entire surface of the intercaruncular epithelium with an average of 25 uterine glands per square centimeter of epithelium. According to Weber *et al.* (52) the neck is the straight portion of the gland and is lined with tall, pseudostratified columnar epithelium. The middle is that part of the gland which is extensively coiled and branched. It is lined by a low pseudostratified columnar to simple columnar epithelium. These authors also reported that many ciliated cells are present in the neck and upper middle portion of the uterine glands. The basal portion is the short terminal portion of gland beyond the terminal arborisations which contain simple columnar to cuboidal epithelium and extend to and occasionally into the myometrium.

Cole (10) stated that glandular hypertrophy was greatest from 8 to 11 days postestrus. Vollmerhaus (49) reported that the absolute length of the glandular tissue is the same in each phase of the cycle. The glands appear straight prior to and after estrus due to the edematous changes of the endometrium rather than changes in the glandular tissue. The apparent hypertrophy or actual coiling of the glands during the luteal phase is a result of the loss of edematous condition and reduction in thickness of the endometrium, which, on day 12 is only half as thick as it was one day postestrus (49). The secretion of these glands is probably not great until pregnancy ensues (53). In animals in which early and complete implantation occurs, uterine secretions would appear to be of importance only for a relatively short period. Weber et al. (52) described the four secretions of these glands as being: (a) a thin type of mucous secretion produced during all phases of the cycle; (b) fat droplet secretion stimulated by progesterone; (c) glycogen droplets secreted concurrently with fat; and (d) protein granules secreted during pregnancy.

The importance of these secretions cannot be underestimated. Hughes et al. (23) reported that histological and histochemical evaluations indicated that in humans the endometrium metabolized carbohydrates influenced the implantation of the fertilized ovum. Failure of these processes was a pertinent cause for sterility and repeated abortion.

Walaas (51) stated that the significance of glycogen breakdown in energy transformations during muscle contraction is well established. Its significance in uterine muscle contraction may be even greater than in skeletal muscle because of the low content of ATP and phosphocreatine. The author further stated that uterine contractility has been shown to be dependent upon the steroid hormones and therefore reasoned that the determination of



energy substances might also be influenced by these hormones.

Dukes (14) reported that whole excised sow organs were examined under warm oxygenated Locke's solution and that the musculature of the uterus and tubes showed spontaneous contraction waves, which varied with the stage of estrous cycle. The uterine musculature contractions were strong during estrus, becoming irregular following estrus, and gradually passing into a state of very slight but more rapid contractions eight to ten days after estrus.

Histological and biochemical determinations are the two major techniques used for determining glycogen content of tissues. Histological determinations have been used most frequently in the bovine (54; Moss *et al.*, 38; Sykes *et al.*, 48; 46), and in the human (23). The histological technique utilized by Moss *et al.* (38) included fixing material obtained at slaughter in cold acetone, absolute alcohol and Carnoy's fluid. These investigators dehydrated the tissue and infiltrated it *in vacuo* in a low melting point paraffin. The tissues were embedded in paraffin and sectioned. The above fixatives preserve tissue glycogen which could then be stained with vital stains. Glycogen and periodic-acid-Schiff (PAS) positive substances were determined on tissues fixed in Carnoy's fluid and some also fixed in absolute alcohol. Sections were cut at 5 micra and treated with the PAS technique of McManus (36) and Hotchkiss (22). Control sections were incubated in a dilute saliva solution prior to staining. Some sections were also treated with the Best's carmine or the Bauer-Schiff procedure for glycogen (Lillie, 29). Alkaline phosphatase was determined by the modified cobalt sulfide method of Gomori (20). Sections fixed in acetone and absolute alcohol were cut at 8 micra and incubated in a solution containing Na-glycerophosphate, buffered with veronal to pH 9.3 for 1, 2, 4, and 16 hours



at 37°C. Control sections were incubated in a solution from which either the substrate had been omitted or in the same solution after treatment with trichloroacetic acid.

Weeth and Herman (54) fixed tissue blocks in an alcoholic-picro-formalin fixative for glycogen and mucin staining. Paraffin sections of 8 micra thickness were prepared in the usual manner. The Bauer-Feulgen technique as presented by Lillie (29) was used to demonstrate glycogen and mucin. Schiff's reagent was freshly prepared before use, by the method of Lillie and Greco (31). Chromic acid was used to free the aldehyde groups of the polysaccharide to provide the chromophore for the leuco base of the fuchsin. The technique does not distinguish between glycogen and certain glycoproteins, such as mucin (Gomori, 19); however, the differentiation was made on selected sections by digestion in saliva for one hour at 37°C. If the tissue gave a delicate pink or red staining reaction following the salivary digestion, the reaction was assumed to be due to glycoprotein since the glycogen is readily hydrolyzed by salivary amylase (21). Weeth and Herman (54) identified alkaline phosphatase histochemically by the method of Gomori (18) as modified by Kabat and Furth (24) and by Wilmer (55). The pH of the sodium-beta-glycerophosphate substrate ranged from 9.0 to 9.3. Calcium nitrate (0.1 percent) was used as a source of calcium ions in the incubation medium of the control sections which were otherwise treated as the experimental sections. The extended incubation period, 8 to 14 hours, suggested by Wachstein (50) was used to develop maximal enzymatic reactivity.

Skjerven (46) took biopsies from the corpus uteri or from the basal parts of the uterine horns. These were fixed immediately after removal. At the beginning of the investigations the fixation fluids used were 96 percent alcohol, 10 percent formaldehyde solution and Kelly's fluid.

Later neutral 10 percent formalin (30) was used exclusively. For the demonstration of glycogen, paraffin sections were stained by the periodic-acid-Schiff (PAS) method (36, 22) as described by Lillie (30). The digestion test was performed with one percent malt diastase in distilled water or buffer solution, and to a smaller extent, with human saliva. The sections were incubated for one hour at 37°C. Controls were incubated in buffer solution without malt diastase before PAS treatment. A few sections were processed with water being substituted for periodic acid. The author demonstrated alkaline phosphatase by the coupling azo-dye method of Menten-Junge-Green carried out according to Grogg and Pearse (Pearse, 40). Frozen sections were incubated at room temperature in the sodium alpha-naphthylphosphate medium with the stable diazotate of 4-benzoylamino-2:5 dimethoxyaniline at pH 9.2 for 15 minutes. Controls were incubated after inactivation of the enzyme by heating to 90°C.

Sykes et al. (48) stated that the distribution of phosphatase and glycogen in the uterus of the cycling bovine differs in several respects from that which has been reported during the menstrual cycle in the uterus of the human subject and in the uterus of the cycling rat. Atkinson and Engle (6), Arzac and Blanchet (2), and Pritchard (41) stated that in both the human and the rat there is little or no activity in the fibrous endometrial connective tissue.

Sykes et al. (48) stated that it had been found that phosphatase was present in greatest quantity in the surface epithelium of the human uterus prior to ovulation, whereas they found that in the cow the greatest concentration occurs at midcycle. In the rat, phosphatase increases in the cytoplasm of the epithelium but not to the same extent as in the cow at midcycle. Glycogen is maximal during the progestational phase of the human menstrual

Table 1. Summary of studies concerning glycogen content and alkaline phosphatase activity in uterine tissues of different species during the normal estrous cycle.

Author	Species	Tissue	Follicular Phase			Luteal Phase		
			Glycogen	Alk. Phos.	Not cyclic	Glycogen	Alk. Phos.	Not cyclic
Weeth & Herman (54)	Cow	Uterine epithelium	High	Not cyclic	Absent	Low	Not cyclic	
Moss et al. (38)	"	"	"	"	"	High	"	
Sykes et al. (48)	"	"	"	"	"	"	"	
Skjerve (46)	"	"	"	"	"	"	"	
Atkinson & Bagle (6)	Human	"	"	High	"	Low	"	
Arzac & Blanchet (2)	"	"	Low	"	High	"	High	
Pritchard (41)	Rat	"	Low	Low	High	"	Low	
Hughes et al. (23)	Human	Endometrium	"	High	"	"	"	
Reynolds (42)	"	"	"	"	"	"	"	
Bo & Atkinson (7)	Rat	"	None	"	None	"	"	
Bo & Atkinson (7)	"	Uterus	High	"	Low	"	"	
Valaes (51)	"	"	"	"	"	"	"	
Moss et al. (38)	Cow	Endometrial stroma	None	"	None	"	High	
Atkinson & Bagle (6)	"	"	"	"	"	"	Low	
Arzac & Blanchet (2)	Human	"	"	"	"	"	"	
Pritchard (41)	Rat	"	Low	"	High	"	"	
Atkinson & Bagle (6)	Human	Myometrium	"	"	"	"	"	
Atkinson & Bagle (6)	"	"	"	"	"	"	"	
Pritchard (41)	Monkey	"	"	"	"	"	"	
Kestyo (25)	Rat	"	"	"	"	"	"	
Moss et al. (38)	Cow	Circular muscle	High	"	"	"	"	
Bo & Atkinson (7)	Rat	"	None	"	"	"	"	
Bo & Atkinson (7)	Cow	"	Low	"	"	"	"	
Bo & Atkinson (7)	Rat	Longitudinal muscle	High	"	"	"	"	
Weeth & Herman (54)	Cow	Gland necks	Moderate	"	"	"	"	
Moss et al. (38)	Cow	"	Moderate	"	"	"	"	
Skjerve (46)	"	Superficial Glands	Not cyclic	"	"	"	"	
Weeth & Herman (54)	"	"	Not cyclic	"	"	"	"	
Moss et al. (38)	"	Str. Compactus	Not cyclic	"	"	"	"	

Table 1 (cont.)

Author	Species	Tissue	Follicular Phase		Luteal Phase	
			Glycogen	Alk. Phos.	Glycogen	Alk. Phos.
Skjerven (46)	Cow	Str. Compactum	Low	Low	High	Moderate
Skjerven (46)	"	Vascular System	Not cyclic	Not cyclic	Not cyclic	Not cyclic
Zondek & Hestrin (57)	Human	Gland Cells			High	
Zondek & Stein (58)	"	Uterine Mucosa	Low		"	

Table 2. Glycogen content and alkaline phosphatase activity in uterine tissues of different species following ovariectomy.

Author	Species	Ovariectomized		Alk. Phos.
		Tissue	Glycogen	
Sykes et al. (48)	Cow	Endometrium	Unchanged or Increased	Decreased

Table 3. Glycogen and alkaline phosphatase activity in uterine tissues of different species following estrogen treatment.

Author	Species	Tissue	Glycogen	Alk. Phos.
Sykes <i>et al.</i> (48)	Cow	Endometrium	None	Increased
Sykes <i>et al.</i> (48)	"	Surface epithelium	High	High
Koutyo (25)	Rat	Uterus	"	"
Zo & Atkinson (7)	"	Myometrium	"	"
Koutyo (25)	"	"	"	"
Valaes (51)	"	"	"	"
Cecil <i>et al.</i> (9)	Rabbit	"	"	"
Valaes (51)	Rat	Uterus	"	"
Valaes (51)	"	Mucosa	"	"
Atkinson & Engle (6)	Monkey	Surface epithelium	None	High
Atkinson & Engle (6)	"	Glandular epithelium	"	"
Atkinson & Engle (6)	Human	"	"	"

Table 4. Glycogen and alkaline phosphatase activity in uterine tissues of different species following progesterone treatment.

Author	Species	Tissue	Glycogen	Alk. Phos.
Sykes <i>et al.</i> (48)	Cow	Surface epithelium	High	Low
Atkinson & Engle (6)	Monkey	"	"	"
Atkinson & Engle (6)	Human	Glandular epithelium	"	"
Atkinson & Engle (6)	Cow	"	"	"
Sykes <i>et al.</i> (48)	"	Endometrium	Increased	Increased

cycle, absent during menstruation, and minimal during the estrogenic phase (42). In the cow, glycogen is absent in midcycle and present prior to and after ovulation (54, 48, 46, 38).

Weeth and Harsen (54) reported that the surface epithelium was highly positive for glycogen at and around estrus with little or no glycogen staining from 8 to 14 days postestrus. The surface epithelium, however, produced a moderate to heavy alkaline phosphatase reaction at this stage with the enzymatic activity predominantly in a distal band of the columnar epithelium. Cyclic and gestational trends were not apparent. The authors further stated that glandular glycogen was largely limited to the uterine gland necks. Little or no glycogen was detected from 8 to 15 days postestrus. They observed alkaline phosphatase activity in the uterine gland epithelium. Nuclear activity was seen as coarse deposits of cobalt sulfide. The general cytoplasmic reaction was rather light or negative, and a distal band concentration was characteristic. The overall glandular activity was slightly increased at mid-diestrus and reduced at estrus. Activity appeared to be heavier in the superficial glands than in the terminal glands. The periglandular stroma produced a slight Schiff's reaction at all times. The general stroma was negative, except at one, four, and eight days postestrus scattered discrete deposits of about 12 micra in diameter were seen. Salivary digestion did not remove these deposits. The thickened connective tissue in the stratum basalis and in the periglandular and perivascular regions produced a moderate to heavy alkaline phosphatase reaction, but the general stroma appeared negative. Alkaline phosphatase activity in the stroma of the stratum compactum varied during the estrous cycle from very heavy at estrus to only a moderate activity during diestrus. No activity was detected in the lamina propria.



Moss et al. (38) reported that the greatest change in glycogen distribution during the estrous cycle was seen in the surface epithelium. Glycogen was present in the surface epithelium in large quantities for the last few days before and for at least the first five days after the beginning of estrus. From at least day 8 to day 13, at the time of high phosphatase activity, no glycogen was observed in the surface epithelium. Although some irregularity in the distribution of glycogen in some areas of the surface epithelium was noted there was no consistent difference in glycogen distribution between cotyledonary and intercotyledonary areas, nor in height of epithelium, degree of stratification or different locations in the same uterus. The distal border of the cells of the surface epithelium always contains phosphatase. There was, however, a marked variation in the phosphatase of the epithelial cells during the estrous cycle. The variation in phosphatase was more pronounced in this region than in any other area in the uterus. For a few days before and at least five days after the onset of estrus, phosphatase activity was low in the surface epithelium. From day 8 to day 17 there was a marked increase in phosphatase activity. The greatest concentration occurred about days 10 to 12.

The authors (38) further noted that some of the superficial glands always contained glycogen in the epithelial cells as well as in the gland lumina. Frequently large amounts of glycogen were seen in some of the superficial gland cells and lumina even when no glycogen was present in the surface epithelium. These authors could not establish any correlation between the amount of glycogen in the superficial glands and the stage of the estrous cycle. Glycogen granules were seldom present in intermediate and never in basal glands. The phosphatase activity of the glandular epithelium showed a gradation with depth, the activity was highest in the superficial glands



and diminished to low or no activity near the base of the endometrium. The cells of the superficial glands always contain high phosphatase activity along the distal border and phosphatase activity was also observed in the secretion, when present, in the wide portion of the lumen. The cytoplasm of the superficial glands always contained some phosphatase, but no consistent variation in cytoplasmic phosphatase similar to that seen in the cells of the surface epithelium was observed during the cycle.

Moss et al. (38) found that in the endometrial stroma glycogen granules were present in small round cells which were more concentrated in the upper endometrium beneath the surface epithelium and were observed more often in the corpus uteri than in the horn. The variation in the distribution of these cells could not be related to the cycle. Loose glycogen granules were often noted in abundance in the cotyledonous upper endometrial connective tissue stroma of the corpus uteri and were more concentrated during the midcycle. Alakline phosphatase was always present in large quantities in the fibrous sheaths of the gland tubules and blood vessels and in the areolar connective tissue. The amount of phosphatase activity found at these locations directly paralleled the degree of fibrous development. There was also an apparent increase of fibrous development and phosphatase activity throughout the uterine horn at the middle of the cycle.

Skjerven (46) stated that glycogen and alkaline phosphatase were distributed mainly in the surface epithelium, the glandular epithelium, the vascular system, and the stroma. The glycogen in the cells of the surface epithelium exhibited distinct cyclic variations. The cells during one stage of the cycle were completely filled with glycogen granules and at another stage glycogen granules were absent. The glycogen rich period covered the first six and last eight days of the cycle. The quantity, however, varied during this period.

Near estrus, during estrus and during the first few days after estrus the glycogen content was so great that low magnification revealed a reddish epithelium. At higher magnification it was apparent that the content varied from cell to cell, so that the appearance was one of alternating filled and emptied cells. Biopsies taken from 8 to 13 days postestrus contained only traces or were free of glycogen. The author stated that alkaline phosphatase activity was always limited to the supranuclear cytoplasm. Cells exhibiting minimal activity were characterized by a slight darkening limited to the distal border. A more intense reaction caused a darkening of the cytoplasm in the central portion of the cells. The basal cytoplasm and nuclei were inactive. During estrus and the next five days most of the cells were only weakly reactive. At this stage the surface epithelium contained a narrow, grayish-black zone immediately adjacent to the uterine lumen. The strongest activity was observed from 10 to 13 days postestrus. The supranuclear cytoplasm was then revealed as an intensely black zone including half or more of the height of the epithelial cells.

Skjerven (46) reported that glycogen containing cells varied from gland to gland in the same biopsy and from biopsy to biopsy. In general the superficial glands included more glycogen containing cells than the deeper situated glandular sections which were often free of glycogen. Distinct cyclic variations were not observed in the glandular epithelium. In a majority of glycogen containing glands, glycogen granules were visible in the lumen or entangled in the cilia. The distribution of alkaline phosphatase in the glandular epithelium was limited to the distal border of the cells. The superficial glands and especially the ducts contained the highest activity, whereas the deeper parts had weak or no activity. No distinct cyclic variation was observed.

Skjervén (46) found that the glycogen content was more constant and higher in those parts of the stroma where the tissue was relatively dense than where it was looser and less cellular. The quantity of glycogen in the stroma was never as great as that in the surface epithelium. The cyclic variations were greatest in the stratum compactum beneath the surface epithelium, and the variation was the opposite of that in the surface epithelium. During that part of the cycle when the surface epithelium was free of glycogen, from 8 to 13 days postestrus, glycogen granules were relatively common in the stratum compactum. Simultaneously with the reappearance of glycogen in the surface epithelium, glycogen disappeared almost completely from the upper parts of the stratum compactum. Alkaline phosphatase activity was higher in general where the connective tissue was denser and richer in fibres than where it was typical loose connective tissue. Therefore, the stratum compactum was considerably more reactive than the stratum spongiosum. Similarly the connective tissue sheaths around the glands were highly reactive. The activity was similar to the cyclic variation in the surface epithelium, however, it was not as obvious as the latter. The author also noted that independent of the stage of the cycle, small numbers of fine granules were generally visible in the capillary and pre-capillary endothelium and in the walls of large blood vessels. The vascular system contained alkaline phosphatase in the capillary and precapillary endothelium and in the adventitia of the blood vessels. The activity was unchanged during the cycle.

Sykes et al. (48) stated that the endometrial stroma of the cow contained much less glycogen than that which had been found in humans and did not exhibit a cyclic variation. So and Atkinson (7) observed that both the human and the bovine differed from the rat in that the endometrium of the rat did

not contain glycogen. Glycogen also appeared in the circular muscle of the uterus of the rat during proestrus and estrus, whereas it was not found in this tissue in the cow (48).

Sykes *et al.* (48) reported that following ovariectomy in the bovine, phosphatase decreased in all tissue elements of the endometrium. The surface epithelium and dense upper endometrium in particular showed marked decreases in phosphatase. The glycogen content of the surface epithelium remained high and may have actually increased.

When Sykes *et al.* (48) injected estradiol benzoate at the rate of 0.6 mg per day for three days, heat was induced on either the last day of injection or the day following. A marked increase in phosphatase occurred in the endometrium. The dense upper endometrial stroma remained low in phosphatase, but the surface epithelium contained phosphatase in a concentration similar to that seen at midcycle in cycling cows. Glycogen disappeared from the surface epithelium. Following the above period of injections, Sykes *et al.* (48) allowed the uterus to return to the characteristic pattern of the castrate and then injected 40 mg or more of progesterone daily for five days. They noted that the injections of progesterone, as with estrogen, increased the phosphatase content of the endometrial stroma and appeared to be somewhat more effective in restoring phosphatase to the dense upper endometrium than was estrogen. Phosphatase in the surface epithelium was largely restricted to the distal border. Marked deposition of glycogen was observed in the surface epithelium. The authors stated that the distribution of phosphatase and glycogen in the surface epithelium was thus similar to that seen in the uterus of normal cycling cows a few days before and after estrus.

Even though neither estrogen nor progesterone completely restored phosphatase and glycogen of the uterus of ovariectomized cows to the condition seen in the uterus of cycling cows, estrogen produced a pattern most typical of that seen at midcycle and progesterone produced a pattern most typical of that seen before and after estrus. Sykes et al. (48) stated that these observations suggest that progesterone is secreted both before and after estrus in cycling cows, and that secretion is minimal during midcycle when estrogenic effects appear to be predominant.

Biochemical determinations of glycogen have most frequently been used with rats (Armstrong, 1; Leonard, 26, 27, 28; Kostyo, 25; Schmidt and Leonard, 45; McKerns et al., 35; Walaas, 51), rabbits (Parsons, 39), and mice (Robson, 43).

Walaas (51) employing biochemical methods stated that results of glycogen determinations were contradictory and variable results after estrogen and progesterone treatment were obtained in different species.

Cecil et al. (9) reported that in rats, estrogens caused uterine glycogen deposition and this occurred only in the myometrium. They found that progesterone exhibited no effect. In humans the highest glycogen level in uterine mucosa was found to be during the pregestational phase (Zondek and Stein, 58). Hughes et al. (25) found that the deposition of glycogen was greatest between 18 and 24 days of the pregestational phase of the menstrual cycle in humans, while alkaline phosphatase was at a maximum between days 14 and 16 of the estrogenic phase. Moss et al. (38) reported that there was an inverse relationship between the amounts of alkaline phosphatase and glycogen in the bovine uterus. These workers indicated that alkaline phosphatase activity was necessary for glycogen utilization and that accumulation of glycogen occurred because phosphatase activity was low or absent. A

similar inverse relationship was observed in the human endometrium where phosphatase activity was high during the estrogenic phase of the cycle and low during the progestational phase at which time glycogen was increased.

#### MATERIALS AND METHODS

Uterine and vaginal tissues were obtained immediately after slaughter from 139 dairy cows with known reproductive histories. In order to compare tissues obtained at slaughter with those from an intact cow, daily uterine and vaginal biopsies were taken during two estrous cycles from clinically normal cows.

Two ovariectomized cows were given subcutaneous injections of .07 mg B-estradiol daily for three days. Estrus was induced on the second day after treatment and the cows were slaughtered during estrus. Two other ovariectomized cows were treated with progesterone for eight days, starting with 5 mg on the first day and increasing the level of treatment by 5 mg each day. These cows were slaughtered on the day after the last treatment. Uterine and vaginal biopsies were also taken from four ovariectomized cows prior to treatment, after which two were injected with steroid hormones to simulate an estrous cycle according to the schedule presented in Table 5. The others were similarly treated according to the schedule, except from day 6 to 16 they received .01 mg B-estradiol on alternate days. The treatment was repeated through a second simulated cycle and the cattle slaughtered during the third induced estrus. The cows were considered in estrus when mounting by other cows was allowed.

Tissues were immediately fixed, after they were obtained by biopsy or after slaughter, in cold 80 percent alcohol for glycogen and alkaline phosphatase determinations, in Carnoy for glycogen determination, and in



Table 5. Treatment schedule of ovariectomized cows.

Day of Treatment	Treatment	Biopsies Taken
1	1 mg Progesterone	Uterine
2	.07 mg beta-estradiol	
3	.07 mg beta-estradiol	
4	.07 mg beta-estradiol	Uterine
5	No Treatment	
6	5 mg Progesterone + .01 mg beta-estradiol*	Uterine & Vaginal
7	10 mg Progesterone + .01 mg beta-estradiol	
8	15 mg Progesterone + .01 mg beta-estradiol	
9	20 mg Progesterone + .01 mg beta-estradiol	
10	25 mg Progesterone + .01 mg beta-estradiol	
11	30 mg Progesterone + .01 mg beta-estradiol	Uterine
12	35 mg Progesterone + .01 mg beta-estradiol	
13	35 mg Progesterone + .01 mg beta-estradiol	
14	35 mg Progesterone + .01 mg beta-estradiol	
15	35 mg Progesterone + .01 mg beta-estradiol	Uterine & Vaginal
16	35 mg Progesterone + .01 mg beta-estradiol	
17	No Treatment	
18	.03 mg beta-estradiol	Uterine
19	.03 mg beta-estradiol	
20	.05 mg beta-estradiol	
21	.05 mg beta-estradiol	
22	.07 mg beta-estradiol	Uterine
23	.07 mg beta-estradiol	
24	.07 mg beta-estradiol*	
25	No Treatment	

\*Cows came into estrus.



Bouin for study of general structures. The tissues were dehydrated in a series of isopropyl alcohol and infiltrated with paraffin in vacuo. They were embedded in fresh paraffin and sectioned at 8 microns and mounted with Mayer's albumen on glass slides. Representative sections were stained by the Periodic Acid Leucofuchsin (PAS) method for glycogen and glycoprotein determination, adjacent sections digested by salt diastase in a 0.01 M acetate buffer solution for one hour at 37°C. served as controls. Other representative sections were stained for alkaline phosphatase by the method from Conn et al. (11) and control sections were prepared by destroying the enzyme activity by placing them in a 100°C. water bath for ten minutes. Some sections were stained by Mallory's triple for the study of general structures.

## OBSERVATIONS

### Bovine Endometrium During Estrus

The intercaruncular uterine epithelium during estrus consisted of a pseudostratified low columnar layer of cells approximately 20 micra in height. The ratio of cell height to nucleus length was 2.5:1. Nuclei were large, plump and vesicular in appearance. The caruncular epithelium was a simple cuboidal layer 15 micra in height with a 2:1 cell to nucleus ratio.

The intercaruncular and caruncular epithelium contained high levels of PAS positive material during estrus (Plate I, Figs. 1, 2, 3 and 4) which was located mainly in the distal cytoplasm, however, some PAS granules were distributed around the basally located nuclei. No PAS granules were noted within the nuclei.

EXPLANATION OF PLATE I

- Fig. 1. A photomicrograph of the intercaruncular luminal epithelium from a normal control cow during estrus showing a high concentration of PAS+ material in the pseudostratified low columnar cells (180x). Compare with Plate I, Fig. 2; Plate V, Fig. 3; and Plate VI, Fig. 1.
- Fig. 2. Control section of Plate I, Fig. 1 (180x).
- Fig. 3. Caruncular epithelium from a normal cow during estrus showing a high concentration of PAS+ material and low columnar cells (180x).
- Fig. 4. Control section of Plate I, Fig. 3 (180x).
- Fig. 5. Intercaruncular epithelium at estrus showing a low alkaline phosphatase activity (180x). Compare with Plate II, Fig. 4.
- Fig. 6. A photomicrograph of a caruncle from a normal control showing the alkaline phosphatase activity of caruncular epithelium, stratum compactum, stratum spongiosum, and capillary endothelium and its absence from the connective tissue cells of the discus (14x).

## PLATE I



Fig. 1

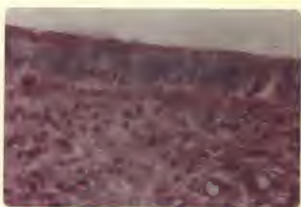


Fig. 2

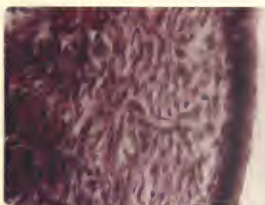

Fig. 3

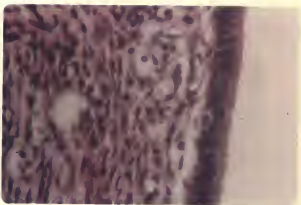


Fig. 4

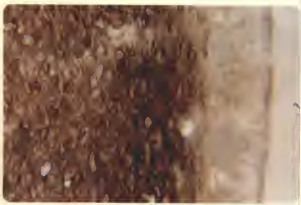

Fig. 5



Fig. 6

Table 6. PAS and alkaline phosphatase reaction of the endometrium during estrus.

	PAS	AP
Intercaruncular epithelium	+++	++
Stratum compactum	+++	+++
Stratum spongiosum	++	++
Superficial glands	+++	++
Basal glands	-	-
Large blood vessels	+++	-
Capillary endothelium	+++	++

PAS = PAS+ material. AP = Alkaline Phosphatase.

- absent.	- absent.
+ trace.	+ slight activity.
++ small amount.	++ low activity.
+++ moderate amount.	+++ moderate activity.
++++ large amount.	++++ high activity.

Alkaline phosphatase was always present in the distal border of the intercaruncular epithelium. Cytoplasmic activity, however, was low during estrus (Plate I, Fig. 5). Caruncular epithelium also was low in enzyme activity during this stage of the cycle (Plate I, Fig. 6).

The uterine glands during estrus were relatively straight glands with large lumens. Cilia were present in the more superficial parts of the glands and in the gland necks but were not observed in the deeper portions of the glands. Glandular epithelium was continuous with that of the uterine lumen therefore the epithelium of the gland necks and superficial glands resembled that of the uterine lumen. It consisted of low to tall ciliated columnar cells about 20 micra in height with large vesicular nuclei (Plate II, Fig. 1).

The epithelium in the gland necks and superficial glands contained relatively high levels of PAS positive material during estrus. The portion

of the glands located just below the stratum compactum were highly variable in PAS+ material and it was usually not observed in the deep portion of the glands. The cilia were positive to PAS staining and granules appeared to be closely associated with the cilia (Plate II, Figs. 1 and 2).

Alkaline phosphatase activity in the glandular epithelium also varied with the depth of the gland. Enzyme activity, even though relatively low during estrus, was highest in the superficial glands and diminished to low or no activity in the basal portion of the glands. Alkaline phosphatase activity was also found to be more variable than PAS+ material. Some areas of the glandular epithelium showed a positive phosphatase activity while other areas were negative. The cilia showed a highly positive reaction for alkaline phosphatase (Plate II, Fig. 3).

Edema of the upper endometrial stroma was observed during estrus. It appeared to be confined to the superficial layer of the stratum spongiosum. PAS+ material was generally more plentiful in the densely cellular areas of the stroma, so that the connective tissue sheaths around capillaries and the stratum compactum usually had a higher level than the stratum spongiosum. The stratum compactum was high in PAS+ material but the cells of the stratum spongiosum had somewhat lesser quantities.

Alkaline phosphatase activity was relatively high in the intercaruncular stratum compactum and in the stratum spongiosum of both caruncular and intercaruncular areas. The enzyme was very low in the stratum compactum of the caruncle and completely absent from the discus except for capillary endothelium (Plate I, Fig. 6). As with PAS+ material, the enzyme was found to be concentrated in the upper densely cellular zone of intercaruncular areas, and in the connective tissue sheaths around uterine glands.

The vascular system contained high levels of PAS+ material. The reaction was observed in the walls of all vessels, from the thin walls of small capillaries to the large muscular walls of the large vessels. No difference was observed between intercaruncular and caruncular vessels.

Alkaline phosphatase activity of the vascular system was similar in intercaruncular and caruncular areas. The enzyme was found in the capillary and precapillary endothelium, but the muscular walls of the large blood vessels were negative for the enzyme.

#### Bovine Endometrium from Two to Four Days Postestrus

The intercaruncular luminal epithelium from two to four days postestrus was reduced to a pseudostratified low columnar layer of cells ranging from 15 to 20 micra in height. Nuclei were large and vesicular and the cell height to nucleus ratio was approximately 2:1 (Plate II, Fig. 4). Caruncular epithelium was somewhat lower than the intercaruncular epithelium. It consisted of a simple cuboidal layer of cells approximately 15 micra in height with a 1½:1 cell to nucleus ratio.

Table 7. PAS and alkaline phosphatase reaction of the endometrium from two to four days postestrus.

	PAS	AP
Intercaruncular epithelium	+++	+
Stratum compactum	+++	++
Stratum spongiosum	++	+
Superficial glands	++	+
Basal glands	-	-
Large blood vessels	++++	-
Capillary endothelium	+++	++

The level of PAS+ material in both caruncular and intercaruncular epithelia was high during this period (Plate II, Fig. 4), however, alkaline phosphatase activity was low (Plate II, Fig. 5).

Uterine glands remained relatively straight with large lumena. Glandular epithelium varied from a low to tall columnar, ciliated layer in the superficial glands to a simple low to tall columnar layer in the basal portion of the glands. Glandular epithelium in the superficial area was only 15 to 20 micra in height and had a 2:1 cell height to nucleus length ratio.

Glandular PAS+ material and alkaline phosphatase activity varied greatly from gland to gland and also with gland depth. The level of PAS+ material in the gland necks and some of the superficial areas was quite high. Alkaline phosphatase activity was rather low. Neither substance could be demonstrated in the basal portion of the glands.

Edema in the stratum spongiosum proximal to the stratum compactum was observed during this stage. There was a high level of PAS+ material particularly concentrated in the denser areas so that the stratum compactum had a higher activity than the stratum spongiosum. The conditions in the caruncular regions and the blood vessels were unchanged from those reported during estrus.

#### Bovine Endometrium from Five to Seven Days Postestrus

The intercaruncular uterine epithelium during the period five to seven days postestrus had increased in height to a pseudostratified tall columnar layer approximately 20 to 25 micra in height. Nuclei were somewhat elongated and the cell to nucleus ratio was 2½:1. Caruncular epithelium consisted



EXPLANATION OF PLATE II

- Fig. 1. Superficial portion of a uterine gland at estrus showing glycogen granules and their association with the cilia (180x). Compare with Plate II, Fig. 2.
- Fig. 2. Control section of Plate II, Fig. 1 (180x).
- Fig. 3. A photomicrograph of the superficial portion of a uterine gland during estrus with highly alkaline phosphatase positive cilia (180x).
- Fig. 4. Intercaruncular luminal epithelium three days postestrus. Epithelial cells are low with large, plump nuclei and considerable PAS+ material (400x). Compare with Plate III, Fig. 1 and Plate IV, Figs. 1 and 2.
- Fig. 5. A photomicrograph of intercaruncular epithelium four days postestrus showing a slight cytoplasmic activity of alkaline phosphatase (400x). Compare with Plate III, Fig. 2.

## PLATE II

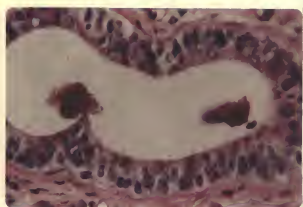

Fig. 1

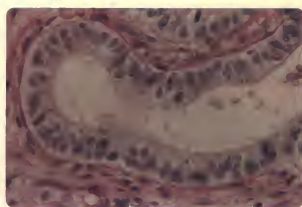


Fig. 2

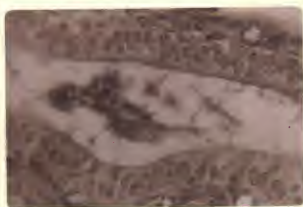

Fig. 3

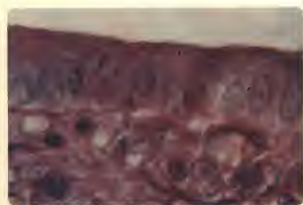

Fig. 4



Fig. 5

of pseudostratified tall columnar cells approximately 22 micra in height with a 2:1 cell to nucleus ratio.

Periodic-acid-Schiff positive material was less evident in both intercaruncular and caruncular epithelium than it had been during and after estrus, however, alkaline phosphatase activity was more intense.

Table 8. PAS and alkaline phosphatase reaction of the endometrium from five to seven days postestrus.

	PAS	AP
Intercaruncular epithelium	++	++
Stratum compactum	++	++
Stratum spongiosum	+	+
Superficial glands	+	+
Basal glands	-	-
Large blood vessels	+++	-
Capillary endothelium	++	++

Glandular epithelium had increased in height. This was most apparent in the more superficial glandular areas and gland necks. The uterine glands were highly variable in PAS+ material and alkaline phosphatase activity. Conditions found at this stage were not significantly altered from the conditions noted during the first three days after estrus, nor were there noticeable histochemical changes in either the stratum compactum or stratum spongiosum. There were no significant changes from the previous stage found in the vascular system.

#### Bovine Endometrium from 8 to 14 Days Postestrus

The intercaruncular epithelium was found to be quite high at this stage. It consisted of a pseudostratified tall columnar layer approximately

25 to 30 micra in height with a 3:1 cell to nucleus ratio. Definite nuclear elongation had taken place and the nuclei and cells appeared to be tightly compressed (Plate III, Fig. 1). Caruncular epithelium consisted of pseudostratified tall columnar cells about 25 micra in height.

Table 9. PAS and alkaline phosphatase reaction of the endometrium from 8 to 14 days postestrus.

	PAS	AP
Intercaruncular epithelium	+	+++
Stratum compactum	+	+++
Stratum spongiosum	+	+++
Superficial glands	-	+++
Basal glands	-	-
Large blood vessels	+++	-
Capillary endothelium	++	++

The PAS+ material in the intercaruncular epithelium was considerably reduced, appearing to be essentially absent in some tissue sections while only a trace along the distal border was observed in others (Plate III, Fig. 1).

Alkaline phosphatase activity in the intercaruncular epithelium appeared to be at its highest level from 8 to 14 days postestrus. The enzyme was concentrated along the distal border of the epithelium, although the entire surface epithelium was positive for alkaline phosphatase (Plate III, Fig. 2).

The uterine glands were hypertrophic and highly coiled. The height of the glandular epithelium had considerably increased by this period resulting in a decrease in size of glandular lumen. Epithelium in the superficial glandular areas consisted of a pseudostratified, tall columnar layer of ciliated cells, however, in the basal areas it remained a simple tall

### EXPLANATION OF PLATE III

- Fig. 1. A photomicrograph of intercaruncular luminal epithelium 11 days postestrum. The epithelium consists of a pseudostratified tall columnar layer of cells with elongated nuclei and contains only a slight amount of PAS+ material (180x).
- Fig. 2. Intercaruncular luminal epithelium 11 days postestrum showing a highly positive reaction for alkaline phosphatase (180x).
- Fig. 3. Superficial portion of a uterine gland 11 days postestrum. Cytoplasmic activity is only slight, whereas the cilia and distal border of the glandular epithelium show a high alkaline phosphatase activity (180x). Compare Plate III, Fig. 4 and Plate II, Fig. 3.
- Fig. 4. Control section of Plate III, Fig. 3 (180x).
- Fig. 5. Caruncular area eight days postestrum. The concentration of PAS+ material is low in the epithelial cells, however, the caruncular connective tissue contains considerable PAS+ material (14x).
- Fig. 6. The caruncular epithelium ten days postestrum shows a high alkaline phosphatase activity, whereas the activity in the caruncular connective tissue cells was slight (40x). Compare with Plate I, Fig. 6.

## PLATE III

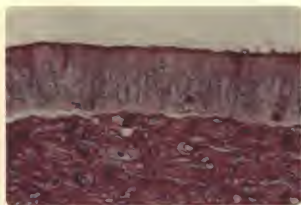


Fig. 1



Fig. 2



Fig. 3



Fig. 4

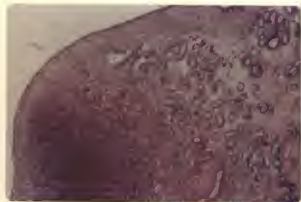

Fig. 5

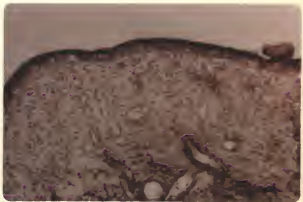


Fig. 6

columnar cell layer. Nuclei in the superficial portions of the glands were distinctly elongated and tightly packed together.

Concentrations of PAS+ material and alkaline phosphatase activity continued to be variable, however, PAS+ material was reduced in the gland necks and alkaline phosphatase was increased (Plate III, Figs. 3, 4 and 5).

Alkaline phosphatase and PAS+ material were always absent in the basal gland areas.

Edema as noted in the stratum spongiosum proximal to the stratum compactum during estrus was now absent. Changes in PAS+ material and alkaline phosphatase activity were not pronounced, although there appeared to be a slight decrease in PAS+ material and some increase in alkaline phosphatase. Both of the substances were found to be more concentrated in the stratum compactum than in the stratum spongiosum.

The dense caruncular discus was high in PAS+ material during this stage of the cycle (Plate III, Fig. 5). Alkaline phosphatase was not observed in caruncular stroma except in the endothelium of the capillaries (Plate III, Fig. 6). The enzyme activity was not changed in the walls of the vessels, however, PAS+ material was slightly reduced.

#### Bovine Endometrium from 15 to 19 Days Postestrus

Intercaruncular epithelial cells reached their greatest height during this period. They formed a pseudostratified tall columnar layer ranging from 28 to 35 micra in height with a cell to nucleus ratio varying from 2½:1. The nuclei were distinctly elongated and closely packed creating the impression that the elongation was due to the squeezing of cells. Some of the cells contained pyknotic nuclei and appeared to have lost most of their cytoplasm (Plate IV, Fig. 1 and 2).



Table 10. PAS and alkaline phosphatase reaction in the endometrium from 15 to 19 days postestrus.

	PAS	AP
Intercaruncular epithelium	+++	++
Stratum compactum	++	++
Stratum spongiosum	++	+
Superficial glands	++	++
Basal glands	-	-
Large blood vessels	+++	-
Capillary endothelium	++	++

Concentrations of PAS+ material in the intercaruncular epithelium had increased and was again present in relatively high amounts. The PAS+ granules were located mainly in the distal cytoplasm (Plate IV, Fig. 1).

Alkaline phosphatase had decreased in the intercaruncular epithelium although the activity remained relatively high in the distal border (Plate IV, Fig. 3).

The uterine glands from 15 to 19 days postestrus were highly coiled structures. The epithelium in the superficial portion of the glands consisted of pseudostratified tall columnar ciliated cells while in the basal areas it was a simple tall columnar epithelium. Gland lumens were small.

The PAS+ material in the gland necks had increased to a level similar to that noted in the intercaruncular uterine epithelium (Plate IV, Fig. 4). Alkaline phosphatase appeared to decrease in activity (Plate IV, Fig. 5). As previously observed, PAS+ material and alkaline phosphatase activity gradually decreased from a high level in the gland necks to complete absence in the basal portions of the glands.

Marked changes were not observed in the stratum compactum or stratum spongiosum during this stage, however, a slight increase in glycogen and

#### EXPLANATION OF PLATE IV

- Fig. 1. Intercaruncular luminal epithelium 18 days postestrum showing the tall epithelial cells with elongated nuclei and considerable PAS+ material (180x). Compare with Plate III, Fig. 2; Plate II, Fig. 4; and Plate V, Fig. 5.
- Fig. 2. Control section of Plate IV, Fig. 1 (180x).
- Fig. 3. A photomicrograph of the intercaruncular luminal epithelium 17 days postestrum showing some alkaline phosphatase activity (180x). Compare with Plate V, Fig. 6.
- Fig. 4. Glandular epithelium 18 days postestrum contains considerable PAS+ material (40x).
- Fig. 5. A photomicrograph showing the low cytoplasmic activity of the glandular epithelium and the high alkaline phosphatase activity of the distal border of the superficial portion of the glands 19 days postestrum. No activity is shown in the walls of the large blood vessels (40x).

## PLATE IV

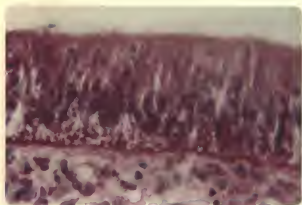


Fig. 1

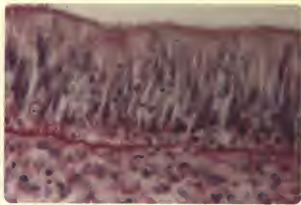


Fig. 2

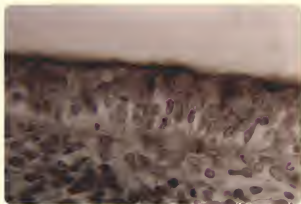


Fig. 3

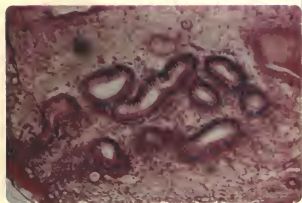


Fig. 4

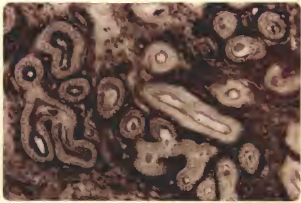


Fig. 5

decrease in alkaline phosphatase were indicated. Concentration of PAS+ material remained high in the walls of all vessels with alkaline phosphatase activity restricted to the endothelium of the small vessels and capillaries. This condition was evident in both caruncular and intercaruncular areas.

#### Bovine Endometrium after Ovariectomy

The intercaruncular uterine epithelium was reduced following ovariectomy. It consisted of a simple cuboidal to low columnar layer of cells ranging from 13 to 15 micra in height. Nuclei were smaller and there was a 2:1 cell height to nucleus length ratio (Plate V, Fig. 1).

Concentration of PAS+ material following ovariectomy was less than that observed during estrus (Plate V, Fig. 1). Alkaline phosphatase activity, however, decreased to a level similar to that found prior to and after estrus (Plate V, Fig. 2).

The uterine glands following ovariectomy were simple glands that appeared to have regressed in length. The glandular epithelium was reduced to a low columnar layer approximately 12.5 micra in height. Nuclear height and width were also slightly reduced following ovariectomy.

The PAS+ material and alkaline phosphatase activity appeared to vary from gland to gland as was noted in the intact animal, however, the level of PAS+ material did not appear to be significantly altered following ovariectomy but alkaline phosphatase appeared to be reduced.

No appreciable changes in the stratum compactum or stratum spongiosum were observed following ovariectomy, except for a slight reduction in the PAS+ material. Alkaline phosphatase activity was unchanged.

The concentration of PAS+ material remained relatively high in the walls

of blood vessels following ovariectomy and alkaline phosphatase was present in the capillary endothelium.

Table 11. PAS and alkaline phosphatase reaction in the endometrium after ovariectomy.

	PAS	AP
Intercaruncular epithelium	+	+
Stratum compactum	+	++
Stratum spongiosum	+	+
Superficial glands	+	-
Basal glands	-	-
Large blood vessels	+++	-
Capillary endothelium	++	++

#### Endometrium in Ovariectomized Cows Following Estrogen Stimulation

Two ovariectomized cows received intramuscular injections of .07 mg B-estradiol daily for three days. Estrus symptoms appeared on the second day after the last treatment and the cows were slaughtered during estrus. The intercaruncular epithelium in these cows was considerably higher than that in ovariectomized cows. The intercaruncular luminal epithelium was found to consist of tall columnar cells approximately 20 to 25 micra in height which were typical of the normal estrus condition (Plate V, Fig. 3). The caruncular epithelium consisted of a low columnar layer of cells about 15 micra in height.

The content of PAS+ material in the intercaruncular epithelium was increased following estrogen treatment to a level found prior to and after normal estrus (Plate V, Fig. 3). Estrogen stimulation also appeared to produce a slight increase in alkaline phosphatase activity (Plate V, Fig. 4).

Table 12. PAS and alkaline phosphatase in endometrium of ovariectomized cows following estrogen stimulation.

	PAS	AP
Intercaruncular epithelium	+++	++
Stratum compactum	++	++
Stratum spongiosum	++	+
Superficial glands	+++	+++
Basal glands	-	-
Large blood vessels	+++	-
Capillary endothelium	++	++

Estrogen stimulation of the epithelium in the superficial portion of the glands and gland necks resulted in conditions similar to those described for the intercaruncular epithelium as the cells increased in size and the quantity of PAS+ material increased. No change was noted in the basal portion of the uterine glands following ovariectomy or estrogen treatment.

Estrogen treatment resulted in an edematous condition in the superficial layer of the stratum spongiosum. Concentration of PAS+ material in the stratum compactum and stratum spongiosum was slightly increased while alkaline phosphatase appeared to be reduced. No histochemical changes were evident in the vascular system.

#### Endometrium in Ovariectomized Cows under Progesterone Stimulation

Two ovariectomized cows were given intramuscular injections of progesterone daily for eight days, starting with 5 mg and increasing the dose by 5 mg each day until a maximum of 35 mg was being administered. The cows were slaughtered on the day after the last treatment and tissue samples obtained.

Progesterone treatment resulted in an intercaruncular epithelial height greater than that produced by estrogen, consisting of pseudostratified tall



columnar cells ranging from 25 to 30 micra in height. The nuclei were characteristically elongated as was observed in the luteal phase of the normal cycle. The concentration of PAS+ material in the intercaruncular epithelium declined from that observed after ovariectomy (Plate V, Fig. 5). Alkaline phosphatase activity was intense along the distal border with the level of enzyme activity moderate in the cytoplasm (Plate V, Fig. 6).

Progesterone treatment resulted in a high degree of coiling in the uterine glands. Glandular epithelium in the superficial portion of the glands increased in height resulting in smaller lumena. The nuclei had enlarged and elongated as compared to that observed after ovariectomy. The PAS+ material and alkaline phosphatase activity were not noticeably affected except in the gland necks where the concentration of PAS+ material was decreased and the enzyme activity slightly increased.

Table 13. PAS and alkaline phosphatase reaction in endometrium of ovariectomized cows following progesterone stimulation.

	PAS	AP
Intercaruncular epithelium	+	+++
Stratum compactum	++	++
Stratum spongiosum	+	+
Superficial glands	+	++
Basal glands	-	-
Large blood vessels	+++	-
Capillary endothelium	++	++

There was some indication that both PAS+ material and alkaline phosphatase were reduced in the stratum compactum but no definite pattern could be established. No change was observed in the vascular system which could be attributed to progesterone treatment.

#### EXPLANATION OF PLATE V

- Fig. 1. Intercaruncular luminal epithelium following ovariectomy showing a relatively low PAS content in the nearly cuboidal cells (400x). Compare with Plate I, Fig. 1 and Plate IV, Fig. 1.
- Fig. 2. Intercaruncular epithelium following ovariectomy showing low alkaline phosphatase activity in the epithelial cytoplasm (400x). Compare with Plate II, Fig. 5 and Plate IV, Fig. 3.
- Fig. 3. The intercaruncular epithelium of an ovariectomized cow following estrogen stimulation showing a high glycogen content of the tall columnar cells. This condition is similar to that found prior to and after estrus (180x). Compare with Plate I, Fig. 1.
- Fig. 4. Intercaruncular epithelium following estrogen treatment of an ovariectomized cow showing alkaline phosphatase activity (180x).
- Fig. 5. Intercaruncular luminal epithelium of an ovariectomized cow when the hormonal balance was in favor of progesterone. This shows the pseudostratified columnar cells with elongated nuclei and a low content of PAS+ material (400x). Compare with Plate III, Fig. 1.
- Fig. 6. Intercaruncular luminal epithelium of an ovariectomized cow when the hormonal balance was in favor of progesterone showing a high alkaline phosphatase activity (180x). Compare with Plate IV, Fig. 3.

## PLATE V

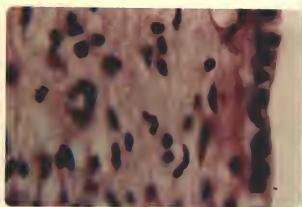


Fig. 1



Fig. 2

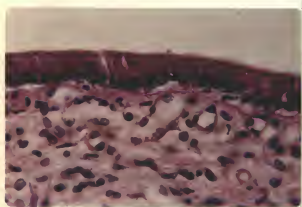


Fig. 3



Fig. 4

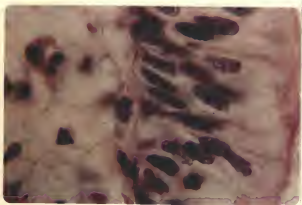


Fig. 5



Fig. 6

### Endometrium in Ovariectomized Cows under Combined Estrogen-Progesterone Treatment

In previous studies of ovariectomized cows, exogenous estrogen or progesterone were injected but no attempt was made to simulate the normal estrus cycle. By using a combination of these hormones at physiological levels such an attempt was made in this study.

The administration of 1 mg progesterone followed by three days of .07 mg  $\beta$ -estradiol, induced normal estrus symptoms in ovariectomized cows. The intercaruncular epithelium increased rapidly in height from a layer of cuboidal cells of about 13 to 15 micra in height in the untreated ovariectomized cows to a low columnar layer approximately 21 micra in height at the induced heat. The concentrations of both PAS+ material and alkaline phosphatase activity were found to increase at this time with slightly greater increase in PAS+ material (Plate VI, Fig. 1).

Following the induced estrus, progesterone was injected daily in increasing amounts from 5 mg up to 35 mg along with daily injections of .01 mg  $\beta$ -estradiol. Cellular height continued to increase during this period to a pseudostratified tall columnar layer about 30 micra in height. This condition was similar to that found from 8 to 14 days postestrus in the normal controls. With continued injections of 35 mg progesterone plus .01 mg beta-estradiol, the intercaruncular epithelium remained a variable layer of pseudostratified columnar cells approximately 23 micra in height. Content of PAS+ material was reduced and alkaline phosphatase activity increased during this period of high progesterone and low estrogen treatment.

Treatment with 1 mg progesterone and three days of .07 mg  $\beta$ -estradiol resulted in an increase in cellular height and cell to nucleus ratio of the glandular epithelium from that of the ovariectomized condition. As

progesterone treatment was increased from 5 to 35 mg along with injections of .01 mg B-estradiol, the ratio of cell height to nucleus length continued to increase until a condition similar to 14 days postestrus was reached. The nuclei were much elongated and the cells were tightly packed. Continued treatment with large quantities of progesterone and low levels of estrogen appeared to cause a slight reduction in glandular epithelial height. Glandular variations were not as pronounced under the stimulus of estrogen and progesterone as it had been in the ovariectomized condition.

No distinct pattern for the concentration of PAS+ material in glandular epithelium could be established with administration of exogenous hormones although there was some indication that the concentration reached its highest level at the time of the induced estrus or a few days thereafter (Plate VI, Fig. 2).

Alkaline phosphatase activity was partially restored to the glandular epithelium with exogenous estrogen and progesterone. The phosphatase was limited mainly to the distal border of the cells and no distinct pattern was established (Plate VI, Fig. 3).

The upper layer of stratum spongiosum was found to be edematous, while both the stratum compactum and stratum spongiosum were high in PAS+ material and low in alkaline phosphatase activity during the induced estrus. With daily injections of 35 mg progesterone and .01 mg B-estradiol the edema was reduced, glycogen content decreased, and alkaline phosphatase increased. The reactions were consistently more intense in the stratum compactum than in the stratum spongiosum.

Changes in the vascular system were minor. The concentration of PAS+ material was not changed by high levels of estrogen from that of the ovariectomized condition although it was slightly reduced by high progesterone

EXPLANATION OF PLATE VI

- Fig. 1. A photomicrograph showing a high content of PAS+ material in the intercaruncular luminal epithelium of an ovariectomized cow when the hormonal balance was in favor of estrogen, at the time of induced heat (400x). Compare with Plate I, Fig. 1.
- Fig. 2. A superficial uterine gland of an ovariectomized cow at the time of induced heat showing the accumulation of PAS+ material in the distal border of the cells of the glandular epithelium (400x). Compare with Plate II, Fig. 1.
- Fig. 3. A photomicrograph of uterine gland of an ovariectomized cow when the hormonal balance was in favor of estrogen showing the alkaline phosphatase activity limited mainly to the distal border of the cells (40x).



## PLATE VI

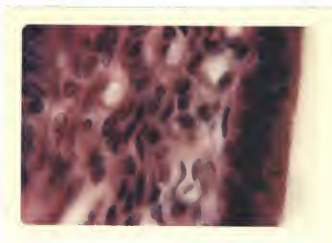

Fig. 1

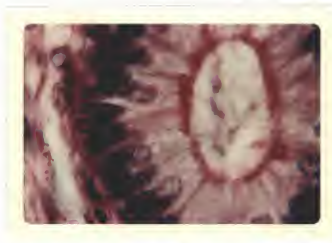

Fig. 2

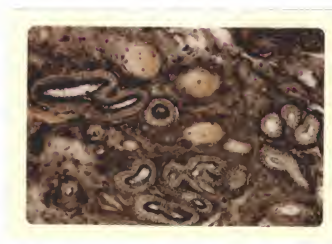


Fig. 3

and low estrogen treatment. The concentration of PAS+ material was greatest at the time of the induced estrus. Alkaline phosphatase activity in the vascular system did not appear stimulated by the administration of exogenous estrogen and/or progesterone.

#### DISCUSSION

A review of the literature concerned with cyclic changes in the bovine endometrium reveals a number of points of disagreement among the investigators in the interpretation of findings. A possible source of confusion is the failure by some to recognize the differences between caruncular and inter-caruncular areas and to clearly distinguish between these areas in reporting their observations. The variation of cells within a tissue sample must be determined and the complete sample should be evaluated. There may be time variation in the secretion cycle of cells which are under the influence of the same hormone. Some confusion might be eliminated by a uniform use of terms, methods and materials. Human error in collecting and processing tissues have contributed to further variations in interpretation.

Every known precaution was taken to prevent misinterpretation due to variation in obtaining and processing material during this study. Comparable histological and histochemical results were obtained from biopsy material and tissues obtained from a local abattoir. Biopsy material was fixed within two minutes after removal. Tissues obtained at the abattoir normally were fixed within 30 minutes after knockdown; however this varied considerably and may account for some of the variation observed in the histochemical studies. Some of the variations between biopsy material and tissues from the abattoir were undoubtedly due to the difference in time elapse before fixation. By digesting control sections in malt diastase before PAS staining, the quantity

of granules considered to be glycogen could be determined in the biopsy material. The same procedure with material from the abattoir, however, often failed to produce a positive test for glycogen even though it was high in PAS+ material. It may be that in order to determine histochemically glycogen levels in tissues, they must be fixed within a few minutes after removal from the animal. Glycogen apparently is broken down within a few minutes into components which will also produce a PAS+ reaction.

In this study Carnoy's fluid and cold 80 percent alcohol were the fixatives found to preserve most effectively tissue glycogen and PAS+ material. These fixatives were also used by Moss et al. (38) and Sykes et al. (48) except that these authors used absolute alcohol. Skjerven (46) determined glycogen content of tissues which had been fixed in 10 percent formalin. This is a questionable procedure since glycogen is dissolved by formalin; however, the results reported by the author are similar to our findings on the cyclic variation in glycogen content of the surface epithelium. Weeth and Herman (54) determined glycogen content in alcoholic-picro-formalin fixed tissues. Control sections for glycogen determination were digested by malt diastase in an 0.01 M acetate buffer solution for one hour at 37°C. Skjerven (46) also incubated control sections in malt diastase solution, but Weeth and Herman (54), Moss et al. (38), and Sykes et al. (48) incubated control sections in a dilute saliva solution. All of the above authors reported that glycogen was removed by the digesting procedures and that the delicate pink or red staining reaction found in the control sections following the digestion was due to glycoprotein. Our study indicated that malt diastase was more effective in digesting glycogen from the control sections and in obtaining repeatable results.

Alkaline phosphatase activity was determined in cold acetone fixed tissue by Weeth and Herman (54), in acetone and absolute alcohol fixed tissues by Moss et al. (38) and Sykes et al. (48), and in frozen tissues by Skjerven (46). In the present study cold 80 percent alcohol fixed material was used for alkaline phosphatase determination. The sections were incubated 1½ hours in the substrate solution at 37°C. The enzyme activity was destroyed on control sections by placing them in a 100°C. water bath for 10 minutes prior to the substrate incubation. Extended incubation times of 8 to 14 hours as followed by Weeth and Herman (54) may have been excessively long and caused a diffusion of the enzyme. This might account for the fact that Weeth and Herman (54) did not observe a cyclic change in alkaline phosphatase activity in the surface epithelium as found in this study. Moss et al. (38) and Sykes et al. (48) used incubation times of 1, 2, 4, and 16 hours. These authors stated that the 4 hour incubation period was most suitable generally for the demonstration of alkaline phosphatase in the structures of the bovine uterus and that most of their results were reported on this basis. It may be that the activity in the distal band of the surface epithelium regardless of the stage of the cycle reported by Moss et al. (38) was due to the incubation time used since 4 hours was found during this study to be too long to avoid diffusion of the enzyme. Skjerven (46) used frozen sections incubated for 15 minutes at room temperature.

It was attempted to administer estrogen and/or progesterone at physiological levels to simulate the normal cyclic condition in the ovariectomized cows. Daily injections of 0.07 mg B-estradiol for three days induced estrus on the day following treatment, whereas, Sykes et al. (48) injected 0.6 mg of estradiol benzoate for three days. The high level of estrogen administered by Sykes et al. (48) may account for the reported disappearance of glycogen

from surface epithelium.

Progesterone was given in varying dosages from 5 mg and increasing to 35 mg along with 0.01 mg E-estradiol, however, Sykes et al. (48) gave progesterone alone in dosages of 50 mg or more. Glycogen content was reduced when the hormonal balance was in favor of progesterone as would be expected from the observed normal controls, whereas, Sykes et al. (48) reported that glycogen content of the surface epithelium was increased.

Intercaruncular epithelium exhibited definite cyclic variations during the normal estrous cycle (Fig. 1). Minimum cell height similarly described by Asdell et al. (3), Weeth and Herman (54), and by Marion and Gier (32), was observed from two to four days postestrus. The low ratio of cell height to nucleus length was in agreement with Asdell et al. (3) and Marion and Gier (32). The high secretory activity of the epithelial cells when the ratio of cell height to nucleus length was low as reported by Weeth and Herman (54) was not found. Nor was the epithelial erosion as reported by Weber et al. (52) observed.

The increased epithelial height observed between 15 and 19 days post-estrus was similar to the report of Marion and Gier (32). The increased ratio of cell height to nucleus length was in agreement with Asdell (4) and appeared to be secretory as found by Marion and Gier (32) contrary to the quiescent appearance reported by Weeth and Herman (54). It would seem necessary for the epithelial cells to be secretory at this time in order to provide a favorable environment and proper nutrition of the zygote after entrance into the uterus. There was a distinct elongation and a corresponding decrease in nuclei diameter at this time as similarly reported by Asdell et al. (3) and Marion and Gier (32).

As reported by Marion and Gier (32) the intercaruncular epithelial height and cell numbers were decreased prior to and during estrus, whereas the nuclei were characteristically larger and more plump in appearance. Weeth and Herman (54) reported that the epithelial height was greatest at the time of estrus. This is contrary to the findings of the present study. The cell to nucleus ratio was also lower as described by Asdell et al. (3).

Caruncular epithelium was always found to be lower than the intercaruncular epithelium as reported by Marion and Gier (32) and contrary to the report of Moss et al. (38). Caruncular epithelium during the luteal phase of the cycle histologically resembled the intercaruncular epithelium during estrus.

Results of histochemical studies of the uterine epithelium as cited by Weeth and Herman (54), Moss et al. (38), Sykes et al. (48), and Skjerven (46) are in general agreement with the observations made in this study. Glycogen content of the intercaruncular epithelium (Fig. 2) was maximum prior to and immediately after estrus, or during the follicular phase, and was minimal from 8 to 14 days postestrus, or during the luteal phase of the cycle as similarly determined by Weeth and Herman (54), Moss et al. (38), Sykes et al. (48), and Skjerven (46). The reason for the reduction in glycogen and PAS+ material is not known. Possibly the material is mobilized and secreted as a readily available carbohydrate source for the zygote or it may be required in the process of cell proliferation which results in an increase in cell numbers and cell height, or both.

Alkaline phosphatase activity, as described by Sykes et al. (48), and Skjerven (46), was much more variable than glycogen but appeared to be inversely related to glycogen. Alkaline phosphatase activity (Fig. 2) in the cytoplasm of the epithelial cells was greatest from 8 to 14 days postestrus, and although present, it was at a lower level at other times of the cycle as



determined by Sykes et al. (48) and Skjerven (46). The significance of alkaline phosphatase or the relationship between glycogen content and alkaline phosphatase activity has not been explained. Moog (37) found that in the chick, most tissues during differentiation show waves of alkaline phosphatase activity. Possibly the presence of the enzyme in the actively dividing epithelial cells may be linked to this process of differentiation.

Intercaruncular epithelial cells of ovariectomized cows were collapsed (Fig. 6) so that they were small and nearly cuboidal as reported by Asdell (4). The concentration of PAS+ material following ovariectomy (Fig. 7) was less than that observed during estrus which is contrary to the increase in glycogen content following ovariectomy reported by Sykes et al. (48). Alkaline phosphatase activity decreased following ovariectomy (Fig. 7) to a level similar to that found prior to and after estrus, as similarly found by Sykes et al. (48).

A steroid hormone balance either in favor of estrogen or progesterone administered to ovariectomized cows (Fig. 6) resulted in an increased cellular height of the intercaruncular epithelium, however, a balance in favor of progesterone was found to be the most effective, in agreement with Asdell et al. (3). Observed changes in uterine epithelial cells in both normal controls and treated ovariectomized cows indicates that the epithelial height is influenced by the hormonal balance. Estrogen alone did not cause marked changes unless it was administered to previously non-treated ovariectomized cows but as the level of progesterone was increased the cellular height increased greatly. It appeared that once progesterone reached a certain level or balance with estrogen, active holocrine secretion was initiated and the cell numbers and height were consequently reduced.

The observed reduction in the concentration of PAS+ material in the epithelium following ovariectomy is in contrast to the high glycogen content following ovariectomy reported by Sykes et al. (48). A simulated follicular phase of the estrous cycle (Fig. 7) resulted in an increased concentration of PAS+ material, however, increased progesterone stimulation resulted in a decreased concentration of PAS+ material which does not agree with the report of Sykes et al. (48). Some of this difference in results may be attributed to the high levels of hormones that these workers administered. Results obtained from both the normal and treated groups tend to indicate that a hormonal balance in favor of estrogen increases the glycogen content which is in agreement with Skjerven (46), whereas a balance in favor of progesterone reduced the glycogen content which may reflect a mobilization of the glycogen.

The reduction in alkaline phosphatase activity following ovariectomy resulted in a condition similar to that seen prior to and after estrus as similarly reported by Sykes et al. (48). The increase in alkaline phosphatase due to estrogen treatment was similarly found by Sykes et al. (48). Contrary to the report by Sykes et al. (48), high levels of progesterone as in the luteal phase (Table 5), also increased the alkaline phosphatase activity from that observed in the ovariectomized state (Fig. 7). The less than expected increase in alkaline phosphatase activity when the hormonal balance is in favor of progesterone, as compared to normal luteal phase tissue, may be due in part to the level of estrogen being administered simultaneously (Table 5).

The lack of agreement among investigators concerning cyclic changes in uterine glands may be due to the failure of some workers to distinguish properly between the superficial and basal portions of the glands. The presence of ciliated cells in the neck and upper middle portion of the

uterine glands is in agreement with the observations of Weber *et al.* (52). However, the basal portions of the gland did not contain cilia nor were cyclic variations in cell characteristics noticeable. Glandular hypertrophy and coiling of the glands were found to be maximal between 8 to 14 days postestrus, as reported by Cole (10) and Vollmerhaus (49).

The glycogen content and alkaline phosphatase activity in the superficial portion of the uterine glands were found to follow a cyclic pattern (Fig. 5) contrary to reports by Moss *et al.* (38) and Skjerven (46). This pattern in glandular epithelium was not as well established as in the luminal epithelium. However, the concentration of PAS+ material appeared to be greatest at estrus, during the follicular phase, and least from 8 to 14 days postestrus, during the luteal phase, which agrees with that reported by Weeth and Herman (54).

Cyclic variations in the endometrial stroma were minimal (Figs. 3 and 4). As reported by Cole (10), edema was observed in the upper endometrial stroma during estrus. The concentration of PAS+ material and alkaline phosphatase activity appeared greater in the stratum compactum than in the stratum spongiosum; however, the cyclic pattern found in the stratum compactum and spongiosum was similar. The concentration of PAS+ material in the stratum compactum was greatest at estrus, whereas Skjerven (46) reported that the glycogen content was low at this stage. Moss *et al.* (38) reported that glycogen was not cyclic in the stratum compactum. Although alkaline phosphatase activity in the stratum compactum was quite variable it did exhibit a slight cyclic pattern contrary to that reported by Moss *et al.* (38). The observed decrease in alkaline phosphatase activity during the follicular phase and increase during the luteal phase is in agreement with Skjerven (46). No cyclic pattern in glycogen content and alkaline phosphatase

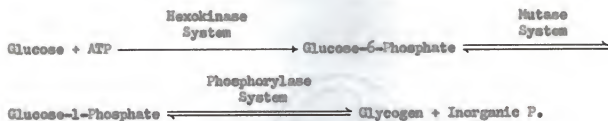
activity was observed in the vascular system as was similarly reported by Skjerven (46).

The mechanism of the increased glycogen formation in the uterus after estrogen treatment is unknown. Bullough (8) advanced the hypothesis that the increased glycogen deposition in the skin after estrogen injection is partly due to hyperglycemia. However, in the study conducted by Walaas (51), an increased glycogen formation in the uterus after estrogen treatment was also noted in fasting animals, indicating that the blood sugar level may not be of importance.

Spaziani and Szego (47) stated that numerous studies have demonstrated that estrogen administration to the immature or castrated adult rat rapidly induced uterine hyperemia which was accompanied by uptake of water, electrolytes, and labeled plasma proteins in this organ. The probable reason for estrogen induced uterine hyperemia is increased capillary permeability. The manner in which estrogens elicit the vascular response is not known. Factors such as increased rate of vascular penetration and increased metabolic activity in the uterus after estrogenic influence may be involved in the mechanism of increased glycogen formation (Walaas, 51).

Hughes et al. (25) stated that the steroids are the specific catalysts which primarily stimulate blood flow, cause cellular changes, and stimulate the enzyme and coenzyme systems which are directly responsible for the metabolic reactions and production of energy.

Walaas (51) believed that three enzyme systems participated in the conversion of glucose to glycogen. The first system involved phosphorylation of glucose with ATP as the energy donor (priming reaction).



Walans (51) found a significant increase of glucose uptake of the isolated rat uterus when estradiolbenzoate was injected 48 hours prior to the investigation. Thus, one principal effect of estrogens on carbohydrate metabolism of the rat uterus is an increased activity of the hexokinase reaction. Whether an increased amount of hexokinase is present or the physical structure of the cell surface is changed by estrogens, permitting an increased rate of glucose transport into the cell, has not been decided. However, it seems highly probable that the increased rate of the hexokinase reaction is the determining factor for the increased glycogen formation in the rat uterine muscles after estrogen administration.

#### SUMMARY

Uterine and vaginal tissues were obtained immediately after slaughter from 139 dairy cows with known reproductive histories. Daily uterine and vaginal biopsies were taken during two estrous cycles from clinically normal cows for comparison. Eight ovariectomized cows were treated with steroid hormones and tissue samples obtained.

Tissues were immediately fixed in cold 80 percent alcohol for glycogen and alkaline phosphatase determinations, in Carnoy for glycogen determination, and in Bouin for study of general structures. Representative sections were stained by the Periodic Acid Leucofuchsin (PAS) method for glycogen and glycoprotein determination, control sections were digested by malt diastase

in a 0.01 M acetate buffer solution for one hour at 37°C. Adjacent sections were stained for alkaline phosphatase by the method of Conn et al. (11) and the enzyme activity was destroyed in control sections by placing them in a 100°C. water bath for 10 minutes.

The most distinct cyclic pattern in the bovine endometrium occurred in the intercaruncular epithelium. The epithelium was lowest two to four days postestrus and highest 15 to 19 days postestrus. The concentration of PAS+ material was greatest during estrus and nearly absent from 8 to 14 days postestrus, whereas alkaline phosphatase activity was lowest at estrus and highest from 8 to 14 days postestrus. Therefore, the concentration of PAS+ material and alkaline phosphatase activity were inversely related.

The glandular epithelium was continuous with the uterine luminal epithelium and in the superficial portion of the glands it followed a cyclic pattern similar to, although more variable than that in the intercaruncular epithelium. The basal portion of the uterine glands did not exhibit a cyclic histochemical pattern.

The concentration of PAS+ material and alkaline phosphatase activity was quite variable and did not follow a distinct cyclic pattern in the endometrial stroma and vascular system.

Ovariectomy resulted in a reduction in the height of the uterine epithelium to a layer of low cuboidal cells. The concentration of PAS+ material and alkaline phosphatase activity was also reduced by ovariectomy as compared to high levels during the estrous cycle. A hormonal balance in favor of estrogen increased the height of the uterine epithelial cells, the concentration of PAS+ material and also the alkaline phosphatase activity. A hormonal balance in favor of progesterone further increased the cell height of the uterine epithelium. The concentration of PAS+ material was not



significantly changed from that of the ovariectomized condition, whereas, alkaline phosphatase activity was increased from that of the ovariectomized state.

Further studies including biochemical techniques are required to determine more accurately the glycogen content of the bovine endometrium.

## ACKNOWLEDGMENTS

The author wishes to extend his most sincere thanks to Dr. G. B. Marion and Dr. H. T. Gier for the constant assistance and advice given throughout the course of this study and to Dr. C. L. Norton, Head, Department of Dairy and Poultry Science, for his criticism of the manuscript.

Acknowledgment is made to Dr. K. A. Huston, Dr. A. O. Darwash and Dr. J. B. R. Choudary for their many helpful suggestions.

Appreciation is also extended to the Department of Dairy and Poultry Science for the laboratory space, equipment, and animals used in this study.

Recognition is due the author's wife, Gloria, for her courage, devotion and contributions toward the preparation of the thesis.

## REFERENCES

- (1) Armstrong, D. T. 1963. Stimulation of Glycolytic Activity of Rat Corpus Luteum Tissue by Luteinizing Hormone. *Endo.* 72:908-913.
- (2) Arzac, J. P., and E. Blanchet. 1948. Alkaline Phosphatase and Glycogen in Human Endometrium. *J. Clin. Endocrin.* 8:315-324.
- (3) Asdell, S. A., J. DeAlba, and S. J. Roberts. 1949. Studies on the Estrous Cycle of Dairy Cattle: Cycle Length, Size of Corpus Luteum, and Endometrial Changes. *Cornell Vet.* 39:389-402.
- (4) Asdell, S. A. 1955. *Cattle Fertility and Sterility.* Little, Brown and Company. Boston.
- (5) \_\_\_\_\_. 1960. Growth in the Bovine Graafian Follicle. *Cornell Vet.* 50:3-9.
- (6) Atkinson, W. B., and E. T. Engle. 1947. Studies on Endometrial Alkaline Phosphatase During the Human Menstrual Cycle and in Hormone-treated Monkey. *Endo.* 40:327-333.
- (7) Bo, W. J., and W. B. Atkinson. 1952. Studies on Glycogen Deposition in the Uterus of the Rat. I. In Intact Cyclic Animals and in Castrates Treated with Ovarian Hormones. *Anat. Rec.* 113:91-100.
- (8) Bullough, W. S. 1950. Epidermal Mitotic Activity in the Adult Female Mouse. *J. Endo.* 6:340-349.
- (9) Cecil, H. C., J. Bitman, and J. F. Sykes. 1962. Glycogen in the Decidual Tissue of the Rat Uterus. *Fed. Proc.* 21:208.
- (10) Cole, H. H. 1930. A Study of the Mucosa of the Genital Tract of the Cow with Special Reference to the Cyclic Changes. *Amer. J. Anat.* 46:261-301.
- (11) Conn, H. J., M. A. Darrow, and V. M. Emsel. 1960. *Staining Procedures.* The Williams and Wilkins Co., Baltimore. 289 pp.
- (12) Darwash, A. O. 1965. Effects of Melengestrol Acetate on Postpartum Reproductive Activity of the Dairy Cow. Ph.D. Thesis, Kansas State University.
- (13) Dawson, F. L. M. 1950. The Microbial Content and the Morphological Character of the Normal Bovine Uterus and Oviducts. *J. Agri. Sci.* 40:150-156.
- (14) Dukes, H. H. 1955. *The Physiology of Domestic Animals.* Seventh Edition. Comstock Publishing Associates.
- (15) Finn, C. A., and J. R. Hinchliffe. 1964. Reaction of the Mouse Uterus During Implantation and Decidua Formation as Demonstrated by Changes in the Distribution of Alkaline Phosphatase. *J. Reprod. Fertil.* 8:331-338.

- (16) Foley, R. C., and R. P. Reece. 1953. *Histological Studies of the Bovine Uterus, Placenta and Corpus Luteum*. Mass. Agr. Expt. Sta. Bul. 468.
- (17) Giering, J. E., and M. X. Zarrow. 1958. Changes in Uterine Morphology and Phosphatase Levels Induced by Chronic Stimulations with the Ovarian Hormones. *Acta. Endocrinol.* 29:499-507.
- (18) Gomori, G. 1941. The Distribution of Phosphatase in Normal Organs and Tissues. *J. Cellular Comp. Physiol.* 17:71-83.
- (19) \_\_\_\_\_. 1950. Microchemical Tests for Certain Substances other than Fats and Chromatins. In the *Microtomist's Vade-Mecum*. 11<sup>th</sup> ed. Edited by Gatenby, J. B. and Beams, H. W. The Blakiston Co., Philadelphia, Pa.
- (20) \_\_\_\_\_. 1952. *Microscopic Histochemistry*. Univ. of Chicago Press.
- (21) Hawk, P. B., E. L. Osier, and W. H. Summerson. 1949. *Practical Physiological Chemistry*. 12<sup>th</sup> ed. The Blakiston Co. Philadelphia, Pa.
- (22) Hotchkiss, R. D. 1948. A Microchemical Reaction Resulting in the Staining of Polysaccharide Structures in Fixed Tissue Preparations. *Arch. Biochem.* 16:131-141.
- (23) Hughes, E. C., R. D. Jacobs, A. Rubulis, and R. M. Hugney. 1963. Carbohydrate Pathways of the Endometrium. *Amer. J. Obstet. Gynec.* 85:594-608.
- (24) Kabat, E. A. and J. Furth. 1941. A Histochemical Study of the Distribution of Alkaline Phosphatase in Various Normal and Neoplastic Tissues. *Am. J. Path.* 17:303-318.
- (25) Kostyo, J. L. 1958. Effects of Some Steroids on Glycogen Metabolism in Uterus and Skeletal Muscle. *Proc. Soc. Biol. and Med.* 97:405-407.
- (26) Leonard, S. L. 1957. Comparison of Atrophy and Glycogen Storage in Some Muscles after Castration and Denervation. *Proc. Soc. Biol. and Med.* 94:458-460.
- (27) \_\_\_\_\_. 1953. Glycogen Deposition in Different Skeletal Muscles Induced by Cortisone and Estradiol. *Endo.* 53:226-232.
- (28) \_\_\_\_\_. 1962. Effect of Epinephrine on Phosphorylase and Glycogen Levels in the Rat Uterus. *Endo.* 71:803-809.
- (29) Lillie, R. D. 1948. *Histopathologic Technic*. The Blakiston Co., Philadelphia, Pa.
- (30) \_\_\_\_\_. 1952. *Histopathologic Technic*. The Blakiston Co., Philadelphia, Pa.

- (31) Lillie, R. D. and J. Greco. 1947. Malt Diastase and Ptyalin in Place of Saliva in the Identification of Glycogen. *Stain Technol.* 22:67-70.
- (32) Marion, G. B., and H. T. Gier. 1959. Histochemical and Cytological Changes in the Bovine Uterine Epithelium. *J. Animal Sci.* 18:1552 (Abstract).
- (33) \_\_\_\_\_. 1962. Unpublished Data. Kansas State University.
- (34) Marion, G. B., J. S. Norwood, A. O. Darwash, and H. T. Gier. 1962. Effects of Steroid Hormones on the Bovine Uterine Epithelium. *J. Animal Sci.* 21:1026 (Abstract).
- (35) McKerns, K. W., B. Coulomb, E. Daleita, and DeRenzo. 1958. Some Effects of In Vivo Administered Estrogens of Glucose Metabolism and Adrenal Cortical Secretion In Vitro. *Endo.* 63:709-722.
- (36) McManus, J. F. A. 1946. Histologic Demonstration of Mucin after Periodic Acid. *Nature.* 158:202.
- (37) Hoog, F. 1944. Localization of Alkaline and Acid Phosphatases in the Early Embryogenesis of the Chick. *Biol. Bull., Wood Hole.* 86:51-80.
- (38) Moss, S., T. R. Wrenn, and J. F. Sykes. 1954. Alkaline Phosphatase, Glycogen and Periodic Acid-Schiff Positive Substance in the Bovine Uterus During the Estrous Cycle. *Endo.* 55:261-273.
- (39) Parsons, U. 1950. Fructose in Rabbit Semen: A Study of Normal Fluctuations, and Changes Evoked by Testosterone and Stilbestrol. *J. Endo.* 6:412-422.
- (40) Pearse, A. E. G. 1953. *Histochemistry.* Churchill Ltd. London.
- (41) Pritchard, J. J. 1949. Alkaline Phosphatase in the Uterine Epithelium of the Rat. *J. Anat.* 83:10-24.
- (42) Reynolds, S. R. M. 1949. *Physiology of the Uterus.* Paul B. Hoeber Inc., New York.
- (43) Robson, J. M. 1949-50. Mechanism by which Progesterone and Other Steroids Inhibit the Vaginal Action of Oestradiol. *J. Endo.* 6:449-455.
- (44) Salisbury, G. W., and W. L. VanDenark. 1961. *Physiology of Reproduction and Artificial Insemination of Cattle.* W. H. Freeman and Company.
- (45) Schmidt, J. E., and S. L. Leonard. 1960. The Effect of Relaxin on Uterine Phosphorylase in the Rat. *Endo.* 67:663-667.
- (46) Skjerven, O. 1956. Endometrial Biopsy Studies in Reproductively Normal Cattle. *Acta. Endo. Supp.* 26:1-101.

- (47) Spanziani, E., and C. M. Szego. 1958. The Influence of Estradiol and Cortisol on Uterine Histamine of the Ovariectomized Rat. *Endo.* 63:669-678.
- (48) Sykes, J. F., S. Moss, and T. R. Wrenn. 1955. The Distribution of Alkaline Phosphatase and Glycogen in the Ovaries and Uterus of the Bovine. Michigan State University Centennial Symposium Report; Reproduction and Fertility. pp. 63-70.
- (49) Vollmerhaus, B. 1957. Untersuchungen über die normalen zyklischen Veränderungen der Uterusschleimhaut des Rindes. *Zentralblatt für Veterinärmedizin.* 4:18-50.
- (50) Wachstein, M. 1944. Renal Phosphatase in Choline Deficiency. *Arch. Path.* 38:297-304.
- (51) Walas, O. 1952. Effect of Oestrogens on the Glycogen Content of the Rat Uterus. *Acta. Endo.* 10:175-192.
- (52) Weber, A. F., B. B. Morgan, and S. H. McNutt. 1948. A Histological Study of the Metorrhagia in the Virgin Heifer. *Amer. J. Anat.* 83:309-327.
- (53) Weber, A. F., and A. W. Stinson. 1958. Unpublished Data. University of Minnesota.
- (54) Weeth, H. J., and H. A. Herman. 1952. A Histological and Histochemical Study of the Bovine Oviducts, Uterus and Placenta. University of Missouri, Agric. Expt. Sta. Bull. 501.
- (55) Wilmer, H. A. 1944. Renal Phosphatase. The Correlation Between the Functional Activity of the Renal Tubule and its Phosphatase Content. *Arch. Path.* 37:227-237.
- (56) Wislocki, G. B., and E. W. Dempsey. 1945. Histochemical Reactions of the Endometrium in Pregnancy. *Amer. J. Anat.* 77:365-403.
- (57) Zondek, B., and S. Nastrin. 1947. Phosphorylase Activity in Human Endometrium. *Amer. J. Obstet. Gynec.* 54:173-175.
- (58) Zondek, B., and L. Stein. 1940. Glycogen Content of the Human Uterine Mucosa Glycopenia Uteri. *Endo.* 27:395-399.



## APPENDIX

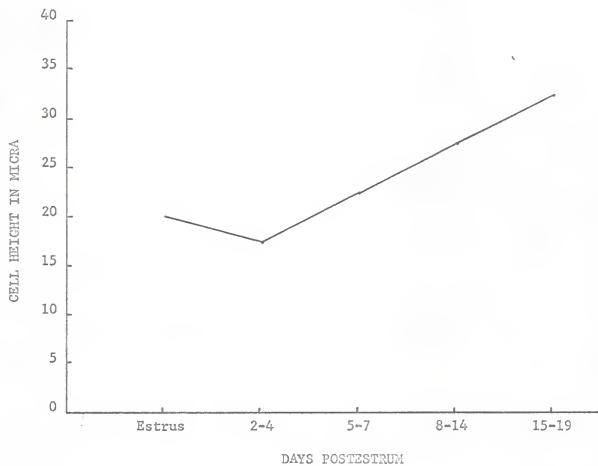


Fig. 1. Cyclic pattern of intercaruncular epithelial height.

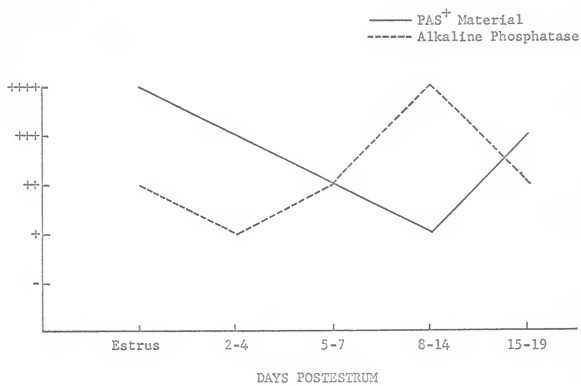


Fig. 2. Histochemical changes in the intercaruncular epithelium.

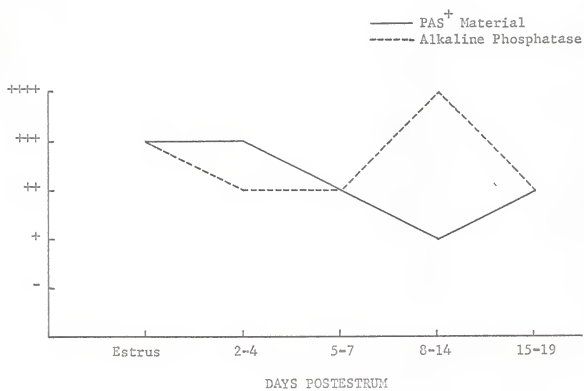


Fig. 3. Histochemical changes in the stratum compactum.

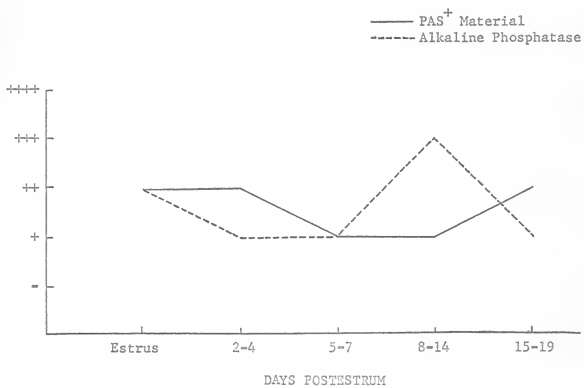


Fig. 4. Histochemical changes in the stratum spongiosum.

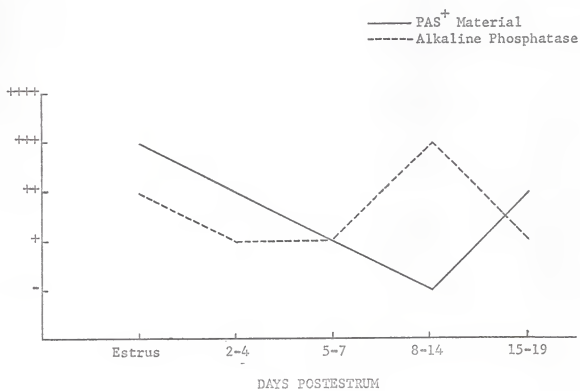


Fig. 5. Histochemical changes in the superficial portion of the uterine glands.



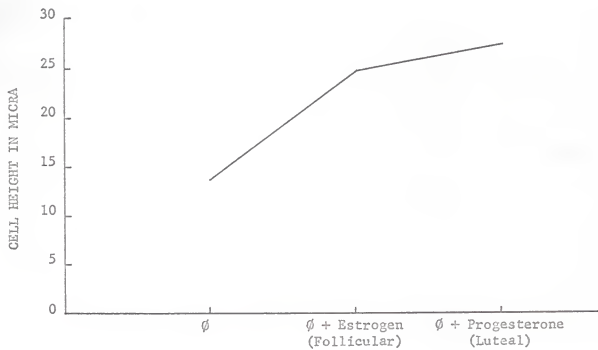


Fig. 6. Height of intercaruncular uterine epithelium following ovariectomy and treatment.

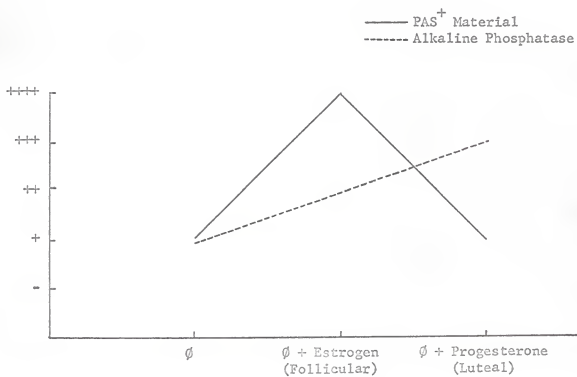


Fig. 7. Histochemical changes in the intercaruncular epithelium following ovariectomy and treatment.

SOME FACTORS AFFECTING GLYCOGEN  
CONTENT IN THE BOVINE ENDOMETRIUM

by

LARRY LEE LARSON

B. S., Kansas State University, 1962

---

AN ABSTRACT OF A MASTER'S THESIS

submitted in partial fulfillment of the

requirements for the degree

MASTER OF SCIENCE

Department of Dairy and Poultry Science

KANSAS STATE UNIVERSITY  
Manhattan, Kansas

1965

The histological and histochemical changes that occur in the bovine uterus, and the probable endocrine causes for their variations, have not been well established. The present study was undertaken to determine the changes which occur in the bovine uterus during the normal estrous cycle, after ovariectomy, and as a result of administering physiological levels of estrogen and/or progesterone to ovariectomized cows.

Uterine tissues from 139 dairy cows with known reproductive histories were obtained either at slaughter or by biopsy for histological study. Eight ovariectomized cows were treated with physiological levels of steroid hormones and tissue biopsies obtained.

The epithelium reached a low level of 15 micra 2 to 4 days postestrus and its highest level of 35 micra by 15 to 19 days postestrus. The concentration of Periodic Acid Schiff material was greatest during estrus and lowest from 8 to 14 days postestrus, alkaline phosphatase activity was inversely related. The glandular epithelium was continuous with the uterine luminal epithelium and in the superficial portion of the glands it followed a cyclic pattern similar to, although more variable than, that in the intercaruncular epithelium. The basal portion of the uterine glands, the endometrial stroma and vascular system did not exhibit a cyclic histochemical pattern.

Ovariectomy resulted in a reduction in height of the uterine epithelium, concentration of PAS+ material and alkaline phosphatase activity. In simulated estrous cycles, a hormonal balance in favor of estrogen resulted in a slight increase in the size of the uterine epithelial cells and in the alkaline phosphatase activity and a marked increase in the concentration of PAS+ material. A hormonal balance in favor of progesterone increased the number and height of the cells in the uterine epithelium. The concentration

of PAS+ material was not significantly changed from that of the ovariectomized condition; however, alkaline phosphatase activity increased from that of the ovariectomized state.