

THE INFLUENCE OF PREDINISOLONE UPON THE PATHOLOGIC  
RESPONSE OF ADULT MICE TO NEWCASTLE DISEASE VIRUS

by

CHIN SOO KIM

D.V.M., Seoul National University, 1960

M.P.H., Seoul National University, 1962

---

A MASTER'S THESIS

submitted in partial fulfillment of the

requirements for the degree

MASTER OF SCIENCE

Department of Pathology, Parasitology,  
and Public Health

KANSAS STATE UNIVERSITY  
Manhattan, Kansas

1965

Approved by:

  
Major Professor

LD  
2665  
TY  
1965  
K48  
c.2  
Document

TABLE OF CONTENTS

INTRODUCTION . . . . .	1
REVIEW OF LITERATURE . . . . .	2
Pathogenicity of NDV in Mammals . . . . .	2
Relationship of Corticosteroids to Infection and Resistance . . . . .	22
MATERIALS AND METHODS . . . . .	35
Strain of Virus . . . . .	35
Experimental Animals . . . . .	36
Histologic Studies . . . . .	37
Serologic Studies . . . . .	38
RESULTS . . . . .	39
Intranasal Route of Inoculation . . . . .	43
Intravenous Route of Inoculation . . . . .	51
Intracranial Route of Inoculation . . . . .	56
Histologic Findings in Control Groups . . . . .	61
DISCUSSION . . . . .	64
CONCLUSIONS . . . . .	67
ACKNOWLEDGMENTS . . . . .	68
REFERENCES . . . . .	69
APPENDIX . . . . .	75

## INTRODUCTION

The ability of Newcastle Disease Virus (NDV) to multiply in mammalian hosts appears to be quite limited; however, the virus has been isolated from various species of domestic animals and human beings (23, 29, 47, 59).

The increase in poultry population throughout the world in recent years focused attention on fowl as a reservoir of infections for man and animals. The milder the strain of NDV, the broader the host spectrum. This fact adds impetus to the importance of this virus from a public health point of view (67).

The injurious effects of NDV in abnormal hosts are quite widespread. Experimental studies, however, with different strains of the virus have resulted in considerable variation from strain to strain of the viruses employed and from species to species treated (22, 23, 25, 30, 31, 39, 43, 47, 51, 60, 61, 73, 77).

Corticosteroids are known to be effective agents for reducing resistance and producing increasing widespread infection (21, 33, 35, 36, 38, 46, 68). A considerable amount of work has been done with myxovirus groups employing corticosteroids for this purpose. Since experimental studies have not been done with NDV and corticosteroid in spite of the similarity of these viruses, experiments were designed in an attempt to elucidate the histopathologic response of adult mice treated with prednisolone and NDV and NDV alone.

## REVIEW OF LITERATURE

## Pathogenicity of NDV in Mammals

Man. Bawell, Legrier, Murrey, Schofield, and Brown (13) studied the occurrence of antihemagglutinins against NDV in serums from man with respiratory infection. Serums of 36 such human patients collected in the autumn and winter of 1946-1947 showed antihemagglutinin activity against NDV in two instances (5.5 per cent). Examination of serum from 31 cases of respiratory infection occurring in the winter and autumn of 1947-1948 revealed antihemagglutinins in 10 (32.2 per cent). Many serums from patients with influenza infections showed no antihemagglutinins against NDV. The titer of NDV antihemagglutinin was less than 1:100 in all but two instances. All but two of the same serums showed a higher titer of antihemagglutinins against some strains of influenza virus. The finding of antibodies against NDV may mean an exposure to the virus or a non-specific production of antibodies as a result of reaction to influenza and perhaps other viruses. Their findings did not exclude either possibility.

Hewitt, Bishop, and Kinsling (23) reported that NDV was responsible for many atypical central nervous system (CNS) infections reported in man during the past few years. This infection, as in fowl, was neurological in young individuals and influenza-like in adults. It was suggested that NDV originating in fowl had probably spread by man to man transmission rather than fowl to man dissemination. After they confirmed the

presence of neutralizing antibodies of avian pneumoencephalitis in the serums of groups of children and in some adults suffering from mild CNS illness of short, nonfatal courses, they emphasized the importance of NDV in public health.

From the further studies on the neutralization test against NDV in human serum, it has been found that the positive results previously published by Howitt et al. (23) were due to non-specific heat labile factors present in serum in varying amounts according to conditions of serum preservation. This factor for NDV was found in large amounts in normal serums of man, monkey, rabbit, and guinea pigs, and was in correlation with the hemolytic activity of the complement. This factor was not demonstrated in the serums of ferret, hamster, and chicken, although complement was detectable.

Quinn, Hanson, Brown, and Brandly (50) studied the history and clinical course of illness of five persons who were exposed accidentally to NDV. The principal clinical manifestations were malaise, conjunctivitis, ulcerations of the buccal mucosa, and periauricular lymphadenopathy. The onset followed exposure within 18 to 24 hours to NDV. The virus was isolated from conjunctival sac washings, urine, nasal discharges, saliva, and blood cells. As far as it was known, NDV was isolated for the first time from urine of human patients. It was suggested that NDV may have greater significance for man than is generally recognized.

Mitchell (42) mentioned two types of NDV infection in relation to public health. One, the most frequent or conjunctival

form, which appears to be far more important at the present time, and the other which affects the respiratory system and may result from aerosols. There was a third type of infection, which was a combination of the conjunctival and respiratory forms. The virus found its way through respiratory aveoli and from there invaded the mammary glands of the cow without difficulty.

Evans (15) studied NDV neutralizing antibody in human serum and its relationship to mumps virus. In a preliminary investigation of neutralization tests with the Roakin strain of NDV and human immune serum, it was found that the amount of virus neutralized fell off rapidly as the serum was progressively diluted, and titration of a standard virus preparation against undiluted serum was therefore adopted as a standard procedure. Significant amounts of antibody were found in the serum of 21 of 26 persons exposed to laboratory infection with the virus, and in 11 instances a neutralization index of log unit 4 was observed. The highest antibody titers occurred in persons exposed to infective aerosol. A human mumps immune serum neutralized the Roakin's strain of NDV, but was not effective against the Australian strain. Convalescent serum from two of six patients with mumps contained neutralizing and inhibiting antibodies to NDV. Neutralization of the latter virus was not generally due to the presence of mumps antibody. Neutralization of NDV occurred in only three of twenty-two serums tested. One serum gave a neutralization index of 1.5 log units with NDV and neutralized mump virus to a titer of 128. In this instance, the neutralization of NDV was evidently due to mump antibody. Attempts to study the

immunologic relationships of the two viruses by cross absorption tests did not give conclusive results, but suggested that some strains of NDV virus may possess an antigen in common with mump virus.

Evans (16) continued his studies on pathogenicity and immunogenicity of NDV in man. Serums from 21 of 26 persons exposed to laboratory infection with NDV neutralized more than 10 infective doses ( $ID_{50}$ ) in neutralization tests carried out by the intra-allantoic inoculation of mixtures of undiluted inactivated serum with serial dilution of virus, and in 11 instances, neutralization of more than 10,000  $ID_{50}$  was observed. Eleven persons had suffered from conjunctivitis, but antibody was also present in significant amount in nine who did not develop conjunctivitis. Exposure to infectious aerosol or the handling of foreign dried material apparently carried a high risk of infection. Serum of 26 control subjects neutralized 10  $ID_{50}$  of NDV, but this result was due to a cross reaction with mump antibody. Two of six mumps convalescent phase serum neutralized NDV; only two of twenty-two serums containing NDV antibody also contained mumps neutralizing antibody, and the independence of two antibodies was confirmed in absorption experiments in which absorption with a concentrated preparation of mumps virus failed to remove antibody.

Bang and Foard (4) studied the serology of NDV. The amount of NDV (B-1 strain) neutralized by different dilutions of anti-serum of chicken, rabbit, and human was determined by egg inoculation of serum-virus mixtures incubated for various periods. When

neutralization was measured in titers of reduction in specific death of embryo after direct inoculation of mixtures (incubated for one hour at 35°C) on the allantoic membrane, there was a 1:1 relationship between lethal dose (LD)<sub>50</sub> of virus neutralized and serum dilution. In contrast, when neutralization was measured as ID<sub>50</sub> reduction in mixtures inoculated into the allantoic sac, the relationship was about 2:1. The route of inoculation did not affect the amount of virus neutralized when serum was diluted 1:1000, suggesting that stronger concentration of serum neutralized more effectively when mixtures were inoculated intra-allantoically. The amount of virus neutralized by convalescent chicken serum was not sufficiently increased by prolonged incubation of serum virus mixtures up to two hours. With human serum, increasing neutralization took place up to at least an hour. Chicken immune serums may have antibody characteristics differing from those of human serum. This possibility is supported by the observation that chicken serums delayed the time of embryo death beyond the usual period when minimal amounts of virus were lethal, an effect which did not occur with human or rabbit serums. Chicken and rabbit serums against NDV did not neutralize mump virus. Neutralization antibodies against NDV were detected in the serums of a person injected with the virus, laboratory workers, and poultry workers, but not in the patients with infective monosclerosis. Neutralizing antibody against NDV was not found in the serums of persons vaccinated with mumps virus. Although seven individuals with clinical mumps failed to show a rise in antibodies for NDV during their illness, three



had NDV antibodies when admitted to the hospital. This was taken to support the possibility that there may be two types of mumps viruses, one of which gives rise to antibodies for NDV.

Hanson and Brandly (26) discussed NDV in man and compiled an up-to-date bibliography on the incidence reported since 1942. Markedly emphasizing the great variability in pathogenicity and other properties of NDV, they stated that differences or changes in tissue tropism among strains of NDV can account for variation in such properties as invasiveness of the virus and in the signs, course, and pathologic changes resulting from NDV. Furthermore, evidence was advanced to indicate that aside from individual and host factors, differences in pathogenicity and infective dosage, and route of infection act as principal modifiers of pathologic expression of the disease. The established tenacity of NDV obviously contributes significantly to its perpetuation and spread. In addition, its pneumotropic affinities favor air-borne infection, especially by infective droplets and particles from the respiratory system. Infection by way of the alimentary tract with eggs and through coitus, together with elimination by way of all body orifices and from the integument during life of fowl afflicted with NDV, further assured extensive dissemination of the virus. With ready spread of often concentrated infection, there was provided opportunity, which history indicates NDV has utilized efficiently for variation and mutation. The latter characteristic, reinforced by the multiple tissue tropism of NDV, accounts in part at least for its recognized adaptability to host species other than fowl. Continued frequent contact by

way of the respiratory, conjunctival, and other routes may facilitate development of NDV to person to person contagion and among other individuals of mammalian species. They pointed out that emergence of variants of NDV was responsible for the respiratory form of the disease in man and may result in man to man transmission of the infection in the future. A primary source of infection for chicken and one source of infection for man is the chicken in the initial stage of the disease. Beginning as early as 24 hours before the development of respiratory signs and continuing for several days thereafter, diseased birds discharge virus into air they exhale. The virus has been recovered from small samples of air taken within a few inches of the heads of such birds, and it also has been obtained from the air in a poultry house in which a number of diseased birds were present. The respiratory discharge contributes almost all of the virus that exists in the form of the natural aerosol to which poultry and man are exposed. Fecal discharge, except in the instances of infection with one of a few exotic strains, is relatively free of virus. Artificial aerosols are also a considerable hazard to man. Fluid virus is sprayed and nebulized as a method of vaccinating chickens. Virus dust preparations are used for the same purpose. Those who provide vaccinating are subject to exposure to these aerosols for periods varying from a few minutes to several hours, and at intervals as frequent as five times weekly or as infrequent as once or twice a year. The laboratories in which vaccines are produced and in which virus is studied provide another and important opportunity for exposure of man to

viral aerosols. The virus is isolated in embryonating chicken eggs for diagnosis and is propagated in them for the production of vaccine. The shell is broken in harvesting the infected fluids and tissues, and desired materials are removed with a suction device and transferred to mixing containers. The virus materials are ground, centrifuged, and lyophilized before packing. Aerosols may be created in transferring, grinding, or centrifuging operations. When lyophilization is done in a bulk drum, the dried virus is ground in a fine powder and distributed in measured quantities to the final vials. This process exposes the operator to a high concentration and to continuous virus aerosols. Such individuals usually have high serologic titers. Even in the incubative stage of the disease, the carcass of the chicken contains some virus. The concentration is highest in the viscera, particularly in the lung and spleen, although detectable quantities may be found in the blood and even in the muscle. Individuals working in eviscerating plants and in diagnostic laboratories are exposed when handling such infected tissues. Virus may be carried to the eyes by contaminated hands. The edible carcass should, under usual conditions of marketing, be quite free of virus. Human infection by the ingestion of diseased poultry with NDV has not been reported.

Since viremia occurs in NDV infection in the chicken, research workers have suggested that biting arthropods may play some role in the epizology of the disease. Little support has been found for this theory. Lice and mites do become engorged with the virus, and virus has been detected in these insects by

grinding and injecting material into eggs, but virus has not been transferred by bites of arthropods. Furthermore, instances in which Diptera were reported to transport or transmit the disease have not been confirmed. It is doubtful that man is exposed to virus by the agency of arthropods.

NDV has been reported in many species of wild and domestic birds. The virus may become better adapted to sparrows or pigeons, and these birds could then serve as a source of infection to man. Whether such a virus would be more or less pathogenic for man is pure speculation. Burnet (2) suggested in 1942 that NDV might be a potential human pathogen in its avian form since eventually it might, through selection afforded by frequent exposure, develop a mammalian form capable of perpetuation in man. Burnet has postulated that such a development from an avian form to mammalian form was the origin of influenza.

Karzon (32) studied properties of the substance present in normal human serum which produce non-specific inactivation of NDV. The amount of substance present was titrated by determining the reduction in infectivity produced by incubating standard quantities with serial dilutions of virus for one hour at 37°C; the mean titer in 12 samples of human serum was 39 log units.

Dardine, Yates, and Flanagan (14) suggested that dust type NDV (B-1 strain) caused bilateral conjunctivitis and malaise in man. Generalized infection was proved by isolating the virus from urine and by the immune response. The isolated virus, identified as NDV, proved to be of the lentogenic type. The report provided evidence that air-borne administration of NDV to chicken

may cause infection in man even though the virus in the vaccine may be of the milder strain.

Reagan, Chang, and Bruckner (59) described a case of conjunctivitis due to NDV which occurred in a laboratory worker who had handled the virus for some time. Virus was isolated by the intracerebral inoculation of 16 to 18-day-old hamsters with blood and also with conjunctival washing collected on the first day of illness. Both strains of viruses were identified as NDV by neutralization tests. No virus could be detected in blood collected on the second day of illness. Objects resembling virus particles were seen in electron micrographs of red blood cells collected on the first day of illness.

Laboratory Animals. Following the report of Hewitt, Bishop, and Kingsling (23), Wenner, Monley, and Todd (74) studied NDV in monkeys. Five monkeys inoculated with infected allantoic fluid intracerebrally developed encephalitis, focal meningitis, and inconstant but intense inflammation of the choroid plexus. Perivascular cuffing, neuronal necrosis, and neuronophagia were best seen in the rhinencephalon, particularly in juxtaposition to the fourth ventricle. No changes were seen in the spinal cord of monkeys inoculated with NDV infected allantoic fluid. In monkeys inoculated with NDV infected allantoic fluid which have passed several times, additional pathologic changes were found. These changes consisted of extensive inflammatory and degenerative changes in the gray matter, particularly in the anterior horn of the spinal cord. The Manhattan strain of NDV produced a choriomeningo-encephalitis.

Wenner, Monley, and Todd (75) further studied NDV encephalitis in Rhesus monkeys. The Manhattan strain of virus on intracerebral inoculation of Rhesus monkeys provoked a clinical illness characterized by fever and symptoms indicative of CNS disturbances, namely, gross tremors, awkward locomotion, ataxia, and occasionally, weakness of the extremities. In the acute stage of illness, the cerebrospinal fluid was cloudy and often had a yellowish tint. The white cell count was increased; the majority of cells were mononuclear in type. Specific humoral antibodies which inhibited agglutination of chicken red blood cells and which fixed complement appeared in serums of monkeys during convalescence. The histologic changes observed in the CNS were those of choriomeningitis. The California strain of NDV on intracerebral inoculation of Rhesus monkeys evoked a clinical illness characterized by fever, tremor, and muscular weakness of a progressive type leading to prostration. The illness was severe. Death occurred in two animals within 72 hours following inoculation. The two remaining animals were sacrificed when moribund. The cerebrospinal fluid showed abnormal changes similar to those observed in monkeys inoculated with Manhattan strain of NDV. The histologic changes observed in the CNS were those of choriomeningoencephalitis. The California strain of NDV provoked a more severe type of illness than did the Manhattan strain of virus. The Manhattan strain of NDV was inoculated intradermally in six monkeys. In six additional monkeys, NDV was delivered into the nasopharynx; three of six monkeys were exposed to the California strain of NDV and three

received Manhattan strain of NDV. The severed perineal nerve of three monkeys was exposed to the California strain of NDV. The California strain was used because it evoked a more severe encephalitis than the Manhattan strain of NDV. None of the monkeys, regardless of the peripheral portal used, developed clinical or serological evidence of illness. The intracerebral inoculation of NDV in Rhesus monkeys produced encephalitis limited largely to the brain stem.

Burnet (3) demonstrated influenza-like pulmonary consolidation in weanling mice following successive NDV inoculation by the intranasal route. Nimi and Immuta (45) studied an Asiatic strain of NDV in mice but reported no significant lesions. Brandly, Upton, and Hanson (6) inoculated the California strain of virus into weanling mice by the intracerebral route causing paralysis and death.

Kilham (30) reported that suckling Swiss albino mice were susceptible to NDV by intracerebral inoculation.

Reagan, Bruckner, and Brandly (54) studied the pneumopathogenicity of NDV for adult mice and demonstrated the virus in a pneumonic lung by chicken embryo inoculation. Serial to serial mouse transmission of pneumonia by intranasal inoculation of lung suspension was not demonstrated. The pneumopathic effect for the mice was less stable than the infectivity of the virus for the embryonating eggs, but the diversity of these characteristics has not been ascertained.

Ginsberg (18) studied the mechanism of production of pulmonary lesions in mice. Pulmonary lesions produced by NDV

appeared to be indistinguishable from those produced by influenza virus and murine pneumonia virus. Epithelial degeneration and eventual sloughing, and interstitial infiltration of mononuclear cells and red blood cells were observed. He demonstrated that the gross lesions appear quite late after extensive virus multiplication had occurred, and that the rate of pulmonary lesion development was slower than the rate of formation of new virus particles. Infectious NDV particles produced extensive pulmonary consolidation in mice.

Davenport (13) studied the pulmonary toxicity of NDV in mice. He suggested that the lesion produced by intranasal inoculation was from direct toxic action of the virus rather than from virus multiplication. Homologous immune serum prevented formation of lesions. No toxic effect was manifested following intracerebral inoculation of concentrated NDV. Mice developed hemagglutination inhibition (HAI) antibodies and antitoxic antibodies but were not protected when challenged with NDV intranasally. These unexpected results appear to be related to the intravascular location of the antibody and the rapid rate of adsorption of virus by cells.

Production of pneumonia by intranasal inoculation of undiluted NDV and development of encephalitis by intracerebral inoculation of the same virus in mice have been reported by several workers (13, 18), but Lius and Bang (39) first reported the development of encephalitis following intranasal inoculation of NDV.

Reagan, Day, and Hammon (56) studied the pathogenicity of



mouse adapted NDV for the chicken, hamster, and mouse. The virus proved to be pathogenic for hamsters by all routes of inoculation attempted except by intraperitoneal and oral routes. Only the intracerebral route of inoculation was pathogenic for mice.

Upton, Hanson, Dow, and Brandly (72) studied intracerebral inoculation of 25 strains of NDV in mice. Two variant strains, identified by their ability to cause CNS disturbances in weanling mice, were included. Eight strains produced high fatalities while five strains induced severe nervous signs in a small proportion of mice but no mortality. Eleven strains caused no apparent signs.

Okasawara and Nakayama (48) studied the mechanism of production of pulmonary consolidation in mice with NDV as influenced by chemicals. Non-infectious NDV particles inactivated by sodium ethyl mercuriothiosalicylate were capable of causing pulmonary consolidation in mice following intranasal inoculation. Appropriate administration of tetraethyl-ammonia, hydromide, or chlorpromazine prevented the pulmonary consolidation in mice. This indicates that participation of excitation through the autonomic nervous system in the production of pneumonia was possible.

Upton, Hanson, Dow, and Brandly (71) studied NDV in mice by inoculating the virus intracerebrally. Of four strains of NDV employed, three were lethal for weanling mice prior to passage in suckling mice but were apparently unable to multiply in the brain of older mice. Two of these three lethal strains were

adapted readily to suckling mice. One strain was unable to produce any untoward effects in weanling mice prior to passage in suckling mice. However, it was easily adaptable to suckling mice. The three easily adaptable strains attained titers in mice brains of  $10^1$  to  $10^4$  LD<sub>50</sub> per 0.1 gram brain tissue between the third and ninth passage, as determined by chicken embryo inoculation. The less easily adaptable strain seldom attained titers greater than  $10^2$ . As passages in mice were continued, the titers for chicken embryo underwent a gradual decrease. The strain did not attain titers for suckling mice greater than  $10^3$  LD<sub>50</sub> per 0.1 ml. of inoculum. They discussed further the possibility of the distinct identities of the infective and neurotoxic properties of NDV as demonstrated by the type of response to the two properties of the virus in mice of different strains.

Spier and Southam (62) studied NDV as a reference to oncolytic virus activity in mice on the basis of its ability to cause characteristic disease. They suggested that one method of suppressing this type of biological activity is to expose the normally susceptible cells, tissues, or organs to another virus often dissimilar in biological nature. Although such interference between the viruses has been known for many years, it remains poorly understood.

Reagan, Lillie, and Bruckner (52) adapted and passed the California strain of NDV in hamsters through more than 50 serial transfers by the intracerebral route. Viral assay in embryonated chicken eggs revealed that virus was concentrated in the brain and not in other vital organs or blood of moribund hamsters.

Reagan, Lillie, Smith, and Bruckner (53) compared the effect on hamsters by intracerebral and intranasal route of inoculation. Hamsters developed irritability followed by involuntary motor reaction and paralysis. Hamsters inoculated by the intracerebral, intranasal, intradermal, intratesticular, and oral routes developed similar signs including involuntary motor reaction; excessive salivary secretion resulting from pharyngeal paralysis; prostration and death. The hamster adapted California strain of NDV was serially passed in albino mice more than 20 transfers by the intracerebral route. Immune chicken serum neutralized the fifteenth mouse passaged virus while serum from normal chicken did not. The mouse adapted virus was pathogenic for Syrian hamster by intracerebral inoculation.

The hamster adapted NDV (California strain number 11914) of the second and third passage was successfully transmitted to Swiss albino mice and carried through 20 serial passages in this species by intracerebral inoculation by Reagan, Little, and Bruckner (55). The virus produced symptoms of irritability and malaise usually followed by paralysis, and often accompanied by a characteristic nervous jerking and labored breathing. Mice showing typical symptoms of CNS involvement did not recover. Positive NDV serum neutralized the virus from the fifteenth mouse passage while normal chicken serum was ineffective. The virus of the fifteenth mouse passage titered  $10^{-3}$  in mice by intracerebral inoculation. The mouse adapted virus proved pathogenic for Syrian hamster on intracerebral injection.

Mitroia and Vior (43) studied the pathogenicity and immunizing capacity of fowl plague and NDV for hamsters. They reported that intracerebral injection of as little as  $10^{-10}$  virulent NDV killed hamsters within four to sixteen days. Smaller doses were non-fatal. Intracerebral injection of attenuated virus in doses of  $10^{-1}$  to  $10^{-4}$  ml. dilution produced clinical symptom but was not fatal.

Prudovsky and Roizman (49) produced encephalomyelitis and pneumonitis in hamsters by inoculating NDV intracerebrally or by peripheral route. The amount of virus required to produce infection varied for each route, the least quantity by the intracerebral route and greater by the subcutaneous route. Virus was recovered from the brain but not from the lung or blood in the prodromal stage.

Reagan and Bruckner (57) studied NDV in cotton rats and found them to be susceptible by the intracerebral route of inoculation. Six different strains of NDV were tested. The cotton rats developed CNS symptoms.

Domestic Animals. Yates, Dorothy, and Henderson (77) isolated NDV from the lung of a six-month-old calf that died with respiratory symptoms. At necropsy, a subdural hematoma extending over the entire right cerebellum was observed. Histologic examination of the CNS of the calf showed slight to moderate encephalitis accompanied by a slight leptomeningitis. Small glial foci often accompanied the hemorrhagic lesions. They also examined the spinal cord as far back as the mid-thoracic region and noted slight gliosis and perivascular cuffings.

Hofstad (22) inoculated the virus into swine and sheep. Adult swine resisted repeated intravenous inoculation of a rather large amount of virus. Antibody response against NDV was slow and weak in swine following intracerebral inoculation. Young pigs weighing 30 to 75 pounds died in three to eleven days following the same route of inoculation. Two attempts at pig to pig passage employing the same route of inoculation failed. Sheep likewise resisted repeated intravenous inoculation of large amounts of NDV. Antibody response against NDV was more rapid in sheep than in swine. A histopathologic study of the brains of all animals failed to reveal lesions similar to those seen in chicken infected with NDV.

Quesnell and Ramanibajafg (51) studied the behavior of NDV in piglets. Seven piglets inoculated intracerebrally with NDV became completely paralyzed after an illness closely resembling Teschen disease. Nine piglets inoculated with NDV intranasally remained normal. After one passage in pig brain, NDV was pathogenic for one of two chickens. They inoculated a virulent strain of NDV intratracheally into two piglets. Both died after nine and eleven days, respectively. Virus was recovered from them before and after death.

Baldelli (5) studied NDV infection in puppies. Puppies two to five days of age were susceptible to intracerebral inoculation. Nervous symptoms developed and the virus was isolated from the brains of affected animals up to 10 days after infection.

Hamboldt, Lugenbuhl, and Hamner (25) studied NDV infection in farm animals. It is a common practice to allow the association

of dairy animals with poultry and pheasants. They suggested the possibility that a disease of one species may become established in another species. Twenty calves were inoculated with NDV. On the first post inoculation day, all animals manifested fever, anorxia, lethargy, and were reluctant to move. By the third day, most of them were killed for histologic examination. Marked purulent meningitis confined to the mid-cerebral portion of the spinal cord at the inoculation site was noted. Since bacteriologic and virologic studies of the brain, spinal cord, and spinal fluids from this calf failed to indicate infection, they presumed that meningeal reaction was in the nature of an allergic phenomenon.

Reagan, Dilaha, Cook, and Bruckner (60) studied the response of kittens to the California strain of NDV after oral and nasal route of exposure. Five kittens, two weeks of age, were exposed to 1 ml. of California strain of NDV intracerebrally. Another five kittens were nasally instilled with suspended NDV. Both groups of cats were held for observation for 14 days. None of them developed signs of infection. Fourteen days post inoculation, the cats in both groups were sacrificed. Brains were aseptically removed, ground, and made into a two per cent suspension in buffered saline solution. Ten-day-old embryonated chicken eggs were inoculated with 0.2 ml. of suspension. The embryos remained healthy and viable after injection. They concluded that kittens are not susceptible to the California strain of NDV by oral or nasal routes of inoculation, and that the virus was not in the nervous tissue.

Luttrell and Bang (40) produced encephalitis by intranasal, intracerebral, intraocular, and intraspinal injection in cats. The incubation period varied with the route of injection from 3 to 17 days with death in 12 to 48 hours after the onset of clinical neurologic signs. The principal signs were paralytic and convulsive. Lesions of encephalomyelitis with perivascular cuffing, neuronal degeneration, glial nodules, and local inflammatory changes were generally bilateral. The distribution of lesions involved the following parts: olfactory bulb and tract; the piriform and preoptic areas; the fornix; amygdoid nucleus; paraolfactory and septal areas; Ammon's horn; midline thalamus; and hypothalamus. There was bilateral symmetrical involvement of the red nucleus, substantia nigra, vestibular nuclei, reticular formation, cranial nerve nuclei, and gray matter of the cord.

Ozawa, Yoshiko, and Chow (47) isolated the B-1 strain of NDV from a cow affected with shipping fever.

Wilcox, Wood, and Jang (75) studied the morphologic and functional changes in corneal endothelium caused by the toxic effect of influenza virus and NDV. Progressive destruction of corneal endothelium of the rabbit was produced by influenza and NDV virus. No evidence of virus multiplication was shown, but an altered exchange relationship between the corneal area was demonstrated by utilizing  $I^{131}$  labelled human albumin. Regeneration of the endothelium subsequent to the viral toxic reaction was followed by refractoriness to challenge with homologous virus. Humoral antibody did not play a significant role in

this corneal resistance to the homologous challenges.

Wild Animals. Reagan, Schweak, Weaver, and Bruckner (52) studied the distribution of NDV in the tissue of the large brown bat. Seven groups of bats (Eptesices fuscus) were inoculated with NDV by intravenous, intracerebral, intradermal, intraperitoneal, intranasal, rectal, and oral routes. Examination of various tissues was made by neutralization tests to determine distribution of the virus in tissue. Virus was present in the lung and trachea, liver, spleen, heart, and kidney in the intracerebral group; in the lung and trachea, liver, and kidney in the intradermal group; in the liver in the intraperitoneal group; in the lung and trachea in the intranasal group; in the lung and trachea and heart of the rectal group; and in the lung and trachea of the oral group.

Karstad, Splatn, and Hanson (31) studied experimental infection in wild birds with Eastern equine encephalitis, NDV, and vesicular stomatitis viruses. NDV produced a lethal infection in crows when inoculated by the subcutaneous and intracerebral routes. The period from exposure to death varied from three to eleven days, and viremia was demonstrated at 48 to 72 hours post inoculation. It is theoretically possible for these birds to transfer infection from farm to farm.

#### Relationship of Corticosteroids to Infection and Resistance

Corticosteroids interfere with connective tissue reaction, reduce phagocytosis, result in lowered antibody formation and



other poorly understood reactions which facilitate dissemination of infectious agents and a greater incidence and severity of the infectious process (7).

Molnut, Spain, and Harber (44) reported that cortisone caused a significant reduction in the spleen size of mice. The spleen of a cortisone treated mouse was 21 per cent smaller than that of the untreated control in overall size. As little as 4 mg. of cortisone during a two-day period produced this effect. Continued cortisone treatment did not increase the original depletion, indicating that the effect was rapid and maximal. Histologically, there was a reduction in size of the Malphigian bodies and in the number of cellular elements in the pulp in the cortisone treated group.

Histologic changes following continued daily injection of rats with adrenocorticotrophic hormone (ACTH) have been described. Lymphocytolysis processed throughout the twenty-first experimental period. The formation of new lymphocytes was sharply curtailed, mitotic figures were generally absent, and large and medium sized lymphocytes were greatly reduced in number. Plasma cells were depleted from the lymph node if sufficient hormone was given (63).

Schwartzman (63) reported that corticosteroids had a depressing effect upon lymphoid tissue only in larger doses. The augmentation of this effect by stress and the effectiveness of the steroid upon a washed cell suspension suggested that they require a co-factor for their action. Lymphocytolysis in the lymph node is a normal function of germinal center. Pathologic lympho-

cytolysis is best seen in the cortex of the thymus and plas-  
malysis in the medullary cord of the lymph node.

Lurie (63) studied the various aspect of the effect of  
ACTH and cortisone on the development of immune response. Anti-  
body production was inhibited by these hormones during active  
immunization, after immunity is well established, and during  
development of secondary response. The failure of cortisone to  
effect the rate of disappearance of passively administered anti-  
body and the timing of the effect of cortisone on the secondary  
response suggest that the synthesis of antibody was inhibited as  
well as assimilation of antigen.

Kass and Finland (33) investigated the action of cortisone  
in pneumococcal and influenza infections and summarized the  
mechanism by which ACTH and cortisone may increase susceptibility  
to infection. These were by: inhibition of inflammation and  
phagocytosis; decrease of capillary permeability, and by in-  
creased fibrogenesis; inhibition of reticuloendothelial activity  
and inhibition of antibody formation.

Schwartzman (Arson) (63) studied the alteration of experi-  
mental poliomyelitis by means of cortisone with reference to  
other viruses. By administering large doses of cortisone and  
virus, a prompt and violent infection was induced. When the  
virulence of the virus is sufficiently high or when a sufficient  
concentration of a virus invades a highly susceptible host, a  
fulminating infection may occur under normal physiologic con-  
ditions. However, if the host is partially refractory or if the  
virus is of low virulence for the host, the hormone may enhance

the disease by allowing greater multiplication of the virus by decreasing severity of neurological signs, and by allowing the entry of virus through parenteral refractory routes.

Schwartzman (63) also undertook histologic studies on hamsters and monkeys to determine if any polio-enhancement occurred by administration of cortisone following intracerebral and intraperitoneal inoculation of strain MEF. The number of neurons destroyed was greater in affected hamsters receiving adjuvant cortisone than in non-adjuvant treated hamsters.

Kilbourne (36) by the use of cortisone, induced Coxsackie infection in adult mice. Adult mice which are ordinarily non-susceptible to Coxsackie virus may be lethally infected if treated by cortisone prior to inoculation. Multiplication, serial passage, and specific neutralization of the virus in adult mice have been demonstrated.

Solov (64) studied the bactericidal activity of the serum of infected animals and reported on the action of cortisone. Cortisone depressed the defense reaction and lowered the resistance to the majority of infections studied. By the combined use of ACTH and Butadonic with tetracycline in mice infected with pneumococcus, increased therapeutic activity of tetracycline was reported.

The adrenal cortical hormones are steroids, as are the hormones of the testes and ovaries. All steroid hormones resemble cholesterol and bile acids in their organic structure. Injection of C-11 (Cyclopenternoper-Hydroplunanthrem-Nucleus) oxygenated cortical steroids of excessive secretion of these compounds

resulting from stimulation of the adrenal by ACTH is followed by a decrease in lymphatic tissue and a rapid drop in the number of circulating lymphocytes. This results from disintegration of lymphocytes. Following injection of 11, 17 oxygenated cortical compounds, circulating eosinophils are destroyed rapidly. How and where the eosinophil is destroyed is not known. Concomitantly with lymphopenia, there is a rise in neutrophilic leukocytes, probably due to increased myelopoiesis in the bone marrow. Following stimulation of adrenals with ACTH, an increase in circulating reticulocytes has been observed suggesting stimulation of erythropoiesis (27).

On the basis of animal experimentation, it was originally stated that an excess of endogenous or exogenous C-11 oxygenated steroid induces a rise in antibody titer, caused by the liberation of gamma globulins from destroyed lymphocytes. There is some evidence that under certain experimental conditions, antibodies may be destroyed by cortical hormones, perhaps by a specific reflection of general protein catabolic action of these compounds. Desaturation of C-2 has yielded synthetic derivatives of cortisone and hydrocortisone in which the ratio of glucocorticoid to mineral corticoid activity has been enhanced. These steroids are called prednisolone and prednisone, respectively. These products permit delivery of a greater antiphlogistic dose without increase of the unwanted mineralcorticoid effects which tend to cause sodium retention, edema, and hypocalcemia (27).

The deleterious effect of prolonged medication with cortisone or its close relative have included all the phenomenon

seen in Cushing's syndrome in human, including hypertension, osteoporosis, diabetes, impaired carbohydrate tolerance, susceptibility to spreading infection, poor tissue healing, edema, hypocalcemia, alkalosis, acne, hirsutism, and psychosis (1).

The corticosteroids appear to be of value in established encephalitis. Administration of ACTH prior to virus inoculation has resulted in increased severity of infection in animal experiments; however, favorable results have been observed in clinically established infection in man (41).

Rovenski (61) studied the change in subcutaneous connective tissue of rats induced by cortisone. Cortisone stimulated fibroblast differentiation causing a striking increase in the mean percentage of the most differentiated fibroblast. Cortisone provoked no degeneration of fibroblasts nor any change of histochemical peculiarities in the ground substance or in connective tissue cells. No increase in the amount of ground substance was noted during the differentiation of fibroblasts into fibrocytes.

Kilbourne (35) studied the influence of cortisone on experimental viral infection and its effect on antibody formation and acquired immunity. The formation of neutralizing, hemagglutinating and inhibiting antibodies was suppressed by cortisone administered during infection of mice with influenza A virus. Suppression of antibody was dependent on prolonged administration of cortisone and was not affected by large doses given at the onset of infection. Acquired active immunity induced by infection of mice with a virulent virus was partially surmounted by administration of cortisone with a challenge inoculum of virulent

virus. Cortisone in doses sufficient to suppress antibody formation induced lesions characteristic of those produced by a pulmonary virus following challenge of mice with previously acquired immunity.

Kilbourne (36) studied the reactivation of non-infective virus on a cortisone treated host. The administration of cortisone to chicken embryos inoculated with large quantities of inactive influenza B virus resulted in a rate of viral increase greater than that which developed following inoculation of the inactive virus particles alone. Thus, more than a mere negative or autointerference was effected. He concluded that in the presence of cortisone, reactivation of non-infective virus participated in viral synthesis. Cortisone induced viral reactivation was dependent upon a high particle cell ratio and is thus analogous to the previously described phenomenon of multiplication reactivation. Cortisone does not interfere with either homologous or heterologous viral interference unless reactivation of the inactive interfering virus occurs. Virus reactivation with cortisone possesses both interfering and enzymatic properties. Reactivation of virus with cortisone cannot be effected in vitro but is mediated by the host cell.

Newsorns and Danach (46) demonstrated that cortisone acetate inhibits formation of circulating hemolytic antibodies in the mouse and the extent of inhibition depends on the dose of both antigen and hormones. A single intraperitoneal injection of 0.1 ml. of a one per cent suspension of washed red cells was given to female Swiss albino mice which were bled six days later.

The serums were pooled from groups of 10 to 20 mice for the estimation of hemolytic antibodies. Corticotropin was administered subcutaneously each day starting on the day before the injection of sheep cell antigen. The level of hemolytic antibody found was less with larger doses of corticotropin. This high dosage of corticotropin induced marked atrophy of the spleen and thymus; but in mice treated with this dose of hormone and given 100 times the usual dose of antigen, a substantial amount of antibody was found. In similar experiments with a suspension of corticosterone in saline and Tween 80 given as one subcutaneous injection on the day before the immunizing dose of sheep cell antigen, it was found that 1 mgm. of corticosterone caused partial inhibition of antibody formation, and that 5 mgm. caused complete suppression of it.

Cortisone administration combined with administration of antigen in small doses intravenously causes a significant and substantial decrease in circulating complement. Cortisone alone produces a hardly discernible effect. ACTH with or without simultaneous antigen administration has an apparent depressing action on complement (19).

Schriekner and Hanson (65) reported that 10 and 20 mg. of cortisone doses given for 18, 21, or 24 consecutive days lowered the resistance of young Guinea pigs to Leptospira pamona infection. The morbidity was greater in cortisone treated Guinea pigs as reflected by lower weight gains, but death accompanied by icterus and fever and by renal, hepatic, and vascular failure was not produced consistently. However, the resistance was

lowered sufficiently by cortisone to permit the Leptospira to remain in the circulating blood two weeks longer than in untreated Guinea pigs. The prolonged use of cortisone apparently enabled the Leptospiras to reenter the circulating blood one to two weeks after Leptospira negative blood samples had been obtained. The recurrent leptospiremia took place in spite of agglutination lysis serum titers. In a second experiment, cortisone and Leptospira pomona activated a latent Salmonella enteritidis infection, resulting in a bacterimia and high mortality rate. Neither cortisone or leptospiral infection alone activated the Salmonella infection.

Suppression of antibody formation may be a key mechanism by which cortisone reduces resistance to infection in animals, especially if there is a low or absent initial antibody titers. In animals with significant antibody titers, the corticosteroids do not appear to alter resistance to subsequent infection (17).

Thomas (68) reported the hosts in which the cortisone effects have been observed. The list includes: mice, rats, guinea pigs, hamsters, rabbits, dogs, monkeys, man, and chick embryos. The micro-organism concerned included the following: streptococci, pneumococci, staphylococci, brucella, typhoid bacilli, spirochetes, corynebacterium, malarial parasites, trypanosomiasis, several varieties of fungi, and viruses of poliomyelitis, influenza, coxsakie viruses, and rabbit fibromatosis. This appears to be a universal biological phenomenon which should lend itself to investigation, and one might expect much to have



been learned about the mechanism concerned. Several hypothetical possibilities have been offered, all of them equally plausible, but all of them still unproved.

Groupe, Dougherty, and Mauaker (20) studied the comparative effects of hydrocortisone, a derived pyridophrimidine (DPP), and xerosine on pneumonia produced by a virus and a bacterial endotoxin. Daily parenteral injection of hydrocortisone or the bacterial product, xerosine, suppressed pneumonia induced by Escherichia coli endotoxin. However, only DPP and xerosine suppress pneumonia induced by NDV and delayed the onset of convulsions induced by influenza virus neurotoxin. It is not clear whether the failure of cortisone to affect NDV induced pneumonia was associated with basic differences between such virus induced lesions and other inflammatory response or with the untoward affects of large amounts of hydrocortisone on the host.

Khobyanan and Welhr (37), in the course of their studies on the tissue damaging effects of influenza virus and factors which alter these effects, found that appropriate treatment with cortisone in mice increased their susceptibility to acute lethal effects of large quantities of intravenously injected virus. In view of the paucity of information on the effect of cortisone on reactions to viral reaction, they studied the effect of cortisone on mouse resistance to intravenous toxicity of influenza virus. Treatment of mice with cortisone significantly reduced the resistance to intravenous toxicity of influenza A, Lee influenza B, and Victorian strain of NDV. Death of cortisone treated mice was prevented by mixing specific immune serum with

the viral inoculum or by passage immunization of mice prior to challenge. For full effect, a dose of 2.5 mg. of cortisone was necessary when treatment was begun 24 hours before challenge. Smaller doses were effective if began earlier.

Baron and Bruckler (9) studied circulating interferon in mice after intravenous injection of NDV. After mice have been infected by large doses ( $10^7$  plaque forming units) of NDV intravenously, interferon was found in their sera. It was detected one hour after inoculation and reached a peak of up to 2,000 units at four hours. It was found to be true interferon, in that it acted on both vesicular stomatitis and encephalomyocarditis viruses in mouse embryo tissue cultures, but not in chick tissue cultures. It did not act in the absence of host cells. It still acted after ultracentrifugation to remove virus particles. It was destroyed by temperatures over  $56^{\circ}\text{C}$  and by trypsin, but it resisted a pH of 2.0 for seven days and a temperature of  $44^{\circ}\text{C}$ .

In a study of the effects of cortisone on chemically produced bronchiolitis obliterans in rabbit lungs, a striking proliferation of cells lining the bronchioles and alveoli was noted. This lesion, while present in animals not receiving cortisone, was more florid in the animals which received the drug. Either because of a direct cortisone effect or some indirect effect such as delayed fibroblastic activity, the cellular proliferation was so atypical that the possibility of neoplasia was considered. Therefore, Totten and Moran (69) designed experiments to test the effects of pretreatment with cortisone at

different time intervals on the repair process in a chemically damaged lung. Pretreatment with cortisone, penicillin, and streptomycin for periods of 7, 14, and 30 days resulted in marked proliferation of cells lining bronchioles and alveoli in rabbit lung following the intratracheal injection of one per cent nitric acid. The alveolar cells, thought to be either alveolar lining cells or derived from bronchiolar epithelium were evident within two days after acid injection. The most striking changes were seen seven to fourteen days after intratracheal injection. At this time, the large anaplastic cells forming glandular spaces and solid nests appeared histologically to be neoplastic. However, the degree of proliferation apparently subsided by 35 days, and no evidence of progressive growth was seen in animals observed up to 149 days after injection. It is not clear whether these changes are produced by direct action of cortisone on proliferating cells or whether proliferation occurs in a favorable environment in which cortisone reduced fibroblastic activity and antibiotic agents reduce inflammatory reaction.

Recent studies have shown atypical pulmonary epithelial hyperplasia in the lung of a rabbit following daily administration of cortisone. In view of the extensive utilization of steroid in treatment of chronic lung disorders, Berkheiser (10) investigated both the pathologic changes and the experimentally induced epithelial hyperplasia associated with cortisone administration. Lung tissues obtained and autopsies performed from the period of 1955 to 1962 in which there was history of cortisone administration were studied. Findings from this study were

compared to changes observed in the lungs of 70 female rabbits weighing from 2500 to 3500 grams which were subjected to cortisone. The incidence and pulmonary epithelial hyperplasia in human receiving cortisone therapy and that observed in cortisone injected rabbits was found to be basically similar. Alveolar epithelialization and epithelial metaplasia were the characteristic reactions noted most frequently. The incidence of abnormal nuclear forms and atypies was found to correlate roughly with the duration of cortisone administration, particularly in experimental animals. It is suggested that cortisone is an additional agent capable of inducing certain types of bronchiolar proliferation in experimental animals and probably also in man.

## MATERIALS AND METHODS

## Strain of Virus

The California R. O. strain of virus originally isolated by Brandly et al. (8) was used for this study. The virus was isolated from chicken lung tissue obtained from Beach. Lyophilized vials of NDV which initially had an embryo lethal dose (ELD)<sub>50</sub> titer of approximately  $10^8$  was obtained from the University of Wisconsin.<sup>1</sup> The lyophilized virus was suspended in 1 ml. of nutrient broth resulting 1:10 dilution. An antibiotic mixture consisting of 10,000 units of Neomycin and 10 mg. of penicillin per ml. solution was added. Ten-day-old chicken embryos were inoculated by way of the allantoic cavity with 0.2 ml. of the virus. The eggs were incubated at 37.5°C for 72 hours. The allantoic-amnionic fluids of embryo succumbing after 48 hours of incubation were harvested. Surviving embryos after 72 hours incubation were refrigerated for at least four hours, and the extra embryo fluids were harvested. The allantoic-amnionic fluids were pooled and centrifuged at 1,000 r.p.m. for 30 minutes using a horizontal clinical centrifuge. The hemagglutination (HA) titer of the pooled allantoic-amnionic fluids was 1:820 employing the fractional dilution method of titration (28).

---

<sup>1</sup>NDV Repository, University of Wisconsin, Madison, Wis.

## Experimental Animals

One hundred ninety-eight week-old CD albino strain mice were used.<sup>2</sup> The mice were randomly divided into 12 groups as indicated in Table 1. Mice were housed in standard steel wire cages with feed and water available. The number of animals in each group, treatment, and manner of treatment is given in Table 1.

Table 1. The grouping and treatment of experimental animals.

Group:	No. of animals :	Inoculum :	Route:	Prednisolone <sup>3</sup>
1	10	None	None	None
2	10	0.5 ml. Tet.	IM	None
3	10	None	IM	0.25 mg.
4	20	0.05 ml. NDV	IN	0.25 mg.
5	20	0.05 ml. Saline	IN	0.25 mg.
6	20	0.05 ml. NDV	IN	None
7	20	0.05 ml. NDV	IC	0.25 mg.
8	20	0.05 ml. Saline	IC	0.25 mg.
9	20	0.05 ml. NDV	IC	None
10	20	0.05 ml. NDV	IV	0.25 mg.
11	20	0.05 ml. Saline	IV	0.25 mg.
12	10	0.05 ml. NDV	IV	None

IN-intranasal route  
 IC-intracranial route  
 IV-intravenous  
 Tet-tetracycline

For the experimental as well as control groups prednisolone was given intramuscularly at least 18 hours before the virus inoculation.

<sup>2</sup>Charles River Farm, St. Brooklin, Mass.

<sup>3</sup>Pfizer Laboratories, Div. Chas. Pfizer and Co., Inc., New York, N. Y.

For the intranasal inoculation, mice were lightly anesthetized with ether, and 0.05 ml. of undiluted viral fluid was deposited in the external nasal opening employing a 0.5 ml. tuberculin syringe fitted with a 26 gauge needle. For intracranial inoculation, 0.05 ml. of undiluted viral fluid was deposited in the mid-cerebral region using a 29 gauge needle and 0.5 ml. tuberculin syringe. For the intravenous inoculation, 0.05 ml. of the virus was injected into the tail vein. Experimental as well as control mice were randomly selected for necropsy from each cage as indicated in Table 2.

Table 2. Necropsy schedule for experimental animals.

Routes	Hours				
	48	72	96	120	160
Intranasal	5-C 5-T 3-NDV	5-C 5-T 2-NDV	5-C 5-T 2-NDV	5-C 5-T 3-NDV	None
Intracranial	5-C 5-T 3-NDV	5-C 5-T 2-NDV	5-C 5-T 2-NDV	1-C 1-T	4-C 4-T 3-NDV
Intravenous	5-C 5-T 3-NDV	5-C 5-T 2-NDV	5-C 5-T 3-NDV	5-C 5-T 3-NDV	None
Antibiotic	2-C	2-C	2-C	2-C	2-C
Prednisolone	2-C	2-C	2-C	2-C	2-C
Non-treated	2-C	2-C	2-C	2-C	2-C
C-control	T-treated with Prednisolone			NDV-virus alone	

#### Histologic Studies

After gross examination, portions of the lung, brain, liver, spleen, and kidney were removed and placed in 10 per cent buffered formalin solution. The remainder was saved for the hemagglutin-

ation test. The tissue blocks were dehydrated and embedded in paraplast,<sup>4</sup> sectioned at a thickness of seven to eight microns, and stained routinely with hematoxylin and eosin and periodic acid schiff methods. All brain sections were cut across diencephalic junction unless otherwise indicated. All sections were examined by light microscopy.

#### Serologic Studies

Lung, brain, kidney, liver, and spleen were suspended in phosphate buffered saline solution (PBS) for the hemagglutination test.

---

<sup>4</sup>A. S. Aloe, St. Louis, Missouri.



## RESULTS

Four hundred and thirty-two histologic sections were prepared from the 190 adult mice for comparative purposes. Constant gross lesions were not observed in any group; however, in groups receiving prednisolone, the lymphoid organs, especially the spleen, were diminished in size. Splenic atrophy was observed only after 48 hours with no progressive decrease in size with further treatment (See Appendix, Fig. 1). The livers and kidney of a few mice were decreased in size as compared to the control group (Fig. 2). After 72 hours, subcutaneous ecchymotic hemorrhage on the inner aspect of the thigh muscle was observed in the group which received virus intranasally and prednisolone intramuscularly. Similar changes were found in group 10 at 92 hours. In group 7 paralysis of the hind legs and severe mental seizures were observed at 98 hours post inoculation. These persisted until necropsy (Fig. 3).

Information regarding the group of mice, the tissue used, and the results of the HA test is presented in Table 3.

Table 3. The results of HA test.

Organs used	Group	Lung	Spleen	Brain	Liver	Kidney
Prednisolone plus NDV treated	IN	20	20	-	-	-
	IV	-	-	-	-	-
	IC	-	-	-	-	-
NDV alone	IN	-	-	-	-	-
	IV	-	-	20	-	-
	IC	-	-	20	-	-

Note: HA titer below 1:20 counted as negative.

IN-intranasal route  
IC-intracranial  
IV-intravenous

The tissues selected for this  
test were from groups in 96 hours.

HA titers of lung tissue were negligible, regardless of route of inoculation, even though microscopic lesions in lung were observed. These results agree with the findings of Brandly (8) and Ginsberg (18). The slight increase of HA titers of the prednisolone and NDV treated group tissues as compared to NDV alone possibly reflects a higher virus multiplication.

Tables 4 and 5 were prepared using the total number of histologic sections examined from which affected sections from any source were compared with non-affected sections.

PERCENTAGE OF AFFECTED NUMBER OF  
LUNG SECTIONS

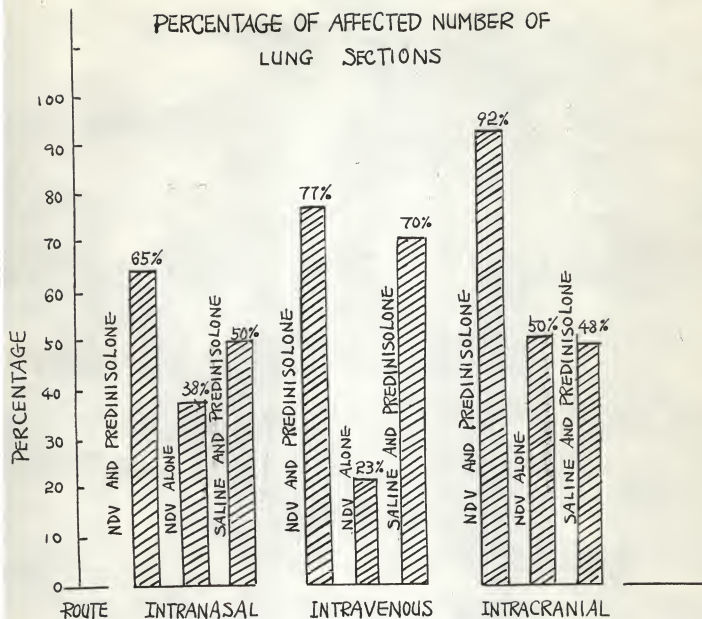
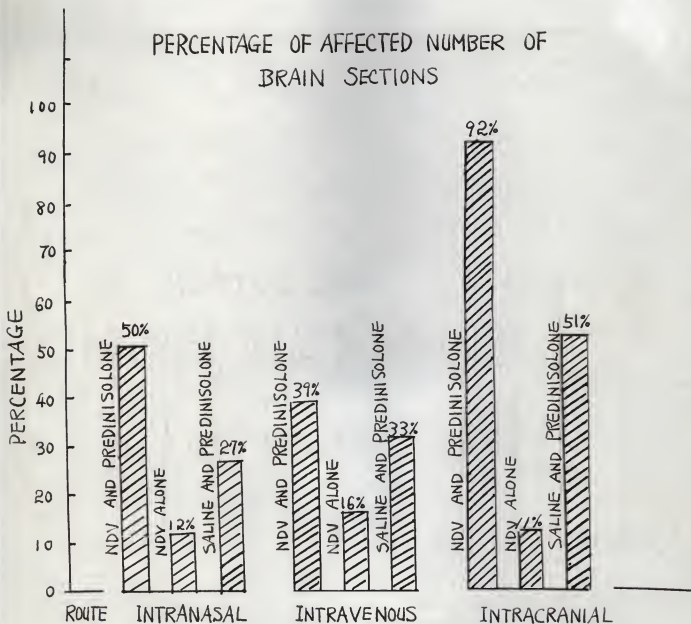


TABLE 4. PERCENTAGE OF HISTOLOGIC ALTERATIONS  
SEEN IN LUNG SECTIONS FOLLOWING NDV  
INOCULATION WITH PREDNISOLONE AND  
SALINE BY WAY OF INTRANASAL,  
INTRAVENOUS, AND INTRACRANIAL ROUTES.

PERCENTAGE OF AFFECTED NUMBER OF  
BRAIN SECTIONSTABLE 5. PERCENTAGE OF HISTOPATHOLOGIC ALTERATION  
SEEN IN BRAIN FOLLOWING NDV INOCULATION  
WITH PREDNISOLONE AND SALINE BY WAY OF  
INTRANASAL, INTRAVENOUS, AND INTRACRANIAL  
ROUTES.

## Intranasal Route of Inoculation

### Histologic Findings in Adult Mice Inoculated with NDV and Prednisolone.

#### Lung.

48 hours post inoculation (PI)--Moderate degree of alveolar atelectasis with diffuse congestion was found in all lung sections in this group. Two of five lung sections had thickened alveolar walls, mononuclear cell infiltration, and congestion. Numerous mononuclear cells were observed in the tissue around the pulmonary arteries. In one section, a focal area of mononuclear cell proliferation associated with macrophage and alveolar epithelial cell proliferation was observed (Fig. 4). Whether this was a discrete area of consolidation of the lung often associated with fibrosis as described in fowl with NDV has not been elucidated (11).

72 hours (PI)--Changes in two of five lung sections consisted of more diffuse congestion, atelectasis, mononuclear cell infiltration, and edema than observed 48 hours PI.

98 hours (PI)--Acute suppurative broncho-pneumonia with marked alveolar emphysema was observed in one section. Reticuloendothelial cells (RE) and mononuclear cells were diffusely infiltrated around the bronchial walls and pulmonary arteries. The alveolar walls were invariably thickened. Congestion and mononuclear cell infiltration were present in these areas. This involvement was more extensive in the periphery of pleural areas.

122 hours (PI)--There was more diffuse and extensive alveolar consolidation than in sections described above, and there was more extensive alveolar consolidation with some peribronchial lymphocytic infiltration. The bronchiolar epithelium was hyperplastic with some epithelial desquamation. Thrombotic tissue debris was observed in pulmonary arteries and veins in one of three sections with marked interstitial edema.

#### Brain.

48 hours (PI)--One of five histologic sections had mild cerebral hemorrhage and lymphocytic cell infiltration in the ventricular area. Focal areas of lymphocytic cell infiltration were also observed in the parenchyma of the cerebellum. Encephalitis due to NDV was reported by Liu and Bang (39) after intranasal inoculation of virus. This lesion observed may be due to the virus following the olfactory nerve or the virus may have entered the brain from the blood and multiplied as a result of lowered resistance due to administration of prednisolone.

72 hours (PI)--Focal lymphocytic foci were observed in the gray matter of the cerebellum of one brain section.

98 hours (PI)--In two sections, lymphocytic infiltration in the choriomeningeal area, a focal area of hemorrhage and possibly demyelination were observed.

122 hours (PI)--Demyelination of brain parenchyma and marked lymphocytic infiltration in the cerebellum were observed in two of five sections.

#### Liver.

48 hours (PI)--The cytoplasm of the hepatic cells was

extremely variable in appearance, and the intercellular outlines were indistinct. In one of three sections, cloudy swelling and hydropic degeneration (vacuolization) were extensive and conspicuous with a focal area of eosinophilic necrobiosis. Hepatic sinusoids were compressed. The centrolobular area was less severely affected than other portions of the lobule. The nuclear chromatin of the hepatic cells was aggregated, and many cells were degenerated.

Cortisone is known to effect the metabolism of carbohydrate, fat, protein, enzyme, water, and electrolytes. The effect on carbohydrate, fat, protein metabolism is not completely understood. Cortisone apparently increases the formation of glycogen from all sources, reduces the metabolic use of carbohydrate, and increases the urinary excretion of nitrogen (27). On the basis of this consideration, PAS stains were made, and increased amounts of PAS-positive material were seen in the cytoplasm of hepatic cord cells, specifically around the nuclei and in the lumen of convoluted tubules in the kidney sections (Fig. 5).

72 hours (PI)--The hepatic cytoplasm was aggregated into clumps, the nuclei were eccentric in location and some were pyknotic. There were focal areas of neutrophil infiltration in the hepatic triad.

98 hours (PI)--Hydropic degeneration, nuclear pyknosis associated with eosinophilic stained cytoplasm constituted the liver changes.

122 hours (PI)--Similar histologic changes described above were observed in the sections from this group.

### Spleen.

48 hours (PI)--There was a great variation in the size of the spleen. The distal end of the organ occasionally showed bifurcation. The red pulp filled the space between the terminal venous sinus forming the splenic cords. The framework was formed by the reticular fibers, primitive reticular cells, degenerated lymphocytes, and fixed macrophages. Megakaryocytes were constant constituents although their numbers varied considerably. The red pulp contained many degenerated small lymphocytes and numerous red blood cells, and were indistinctly delimited from the white pulp. The reticular cells of the red pulp contained varying amounts of yellowish pigment.

72 hours (PI)--The spleen was markedly congested. Band neutrophils were observed in the periphery of lymphoid follicles with red blood cells. Some of the lymphoid follicles were greatly enlarged with poor delimitation of white and red pulp.

98 hours (PI)--No changes other than those described above were observed.

122 hours (PI)--There were focal areas of congestion possibly due to blood sedimentation in the arteries. The red and white pulp were not discernible because of infiltrating degenerative lymphocytes.

### Kidney.

48 hours (PI)--Focal area of hemorrhage and a mild degree of tubular degeneration were observed in three of five sections.

72, 98 hours (PI)--No changes were observed.



122 hours (PI)--There was fatty infiltration in the tubular cytoplasm and mucoid cast formation in the convoluted tubules. Toxic tubular nephrosis had developed in one of three sections.

Histologic Findings in Adult Mice Inoculated with NDV Alone.

Lung.

48 hours (PI)--The lung sections revealed moderate atelectasis and congestion. The alveolar walls were thickened by mononuclear cell infiltration and congestion in some areas.

72 hours (PI)--Two of three lung sections were markedly infiltrated with mononuclear cells. The bronchial walls of two of three sections were similarly but less severely affected. There were areas of alveolar emphysema and atelectasis. The vessels were congested and there were focal areas of hemorrhage.

98 hours (PI)--Thickening of the alveolar walls, marked mononuclear cell infiltration, edema and congestion were observed in five lung sections. The markedly compressed alveolar walls appeared to be due in part to mechanical force; however, there was evidence of some inflammatory reaction.

122 hours (PI)--Focal areas of hemorrhage were observed in four of five sections. Mononuclear cells were observed in the walls of pulmonary veins and bronchial walls. The alveolar walls were thickened by infiltrating red blood cells. Areas of alveolar emphysema were seen in all sections.

Brain.

48, 72, 98 hours (PI)--No pathologic changes were seen.

122 hours (PI)--Two sections of the brain had a focal area of hemorrhage with slight mononuclear cell infiltration in the cerebellar parenchyma.

#### Kidney.

48 hours (PI)--The medullary vessels were congested. The glomeruli were swollen, filling the capsular space. There were focal areas of interstitial RE cell hyperplasia in the cortex between the convoluted tubules.

72, 92 hours (PI)--Slight congestion and mucoid cast formation in the convoluted tubules was observed in one of five sections.

122 hours (PI)--No lesions were found.

#### Liver.

48, 72 hours (PI)--No significant pathologic changes were observed.

98 hours (PI)--Focal areas of neutrophilic and lymphocytic infiltration around the bile duct had developed in one liver section.

122 hours (PI)--Mild fatty changes associated with marked neutrophil infiltration and RE cell hyperplasia around the bile duct were present in one of three sections.

#### Spleen.

48, 72, 98 hours (PI)--No lesions were found.

122 hours (PI)--No change except slight to diffuse congestion was observed.

Histologic Findings in Adult Mice with Saline and Prednisolone.

### Lung.

48 hours (PI)--Three of six lung sections were atelectatic. Congestion was present in the terminal part of alveolar walls. Mononuclear cells had infiltrated the bronchial and pulmonary artery walls.

72 hours (PI)--Marked congestion, emphysema, and atelectasis were observed in one of five sections.

98 hours (PI)--Suppurative bronchopneumonia was observed in three of six lung sections. Neutrophils were the predominant cell type in the bronchial lumina and blood vessels wall. Mononuclear cells were also present. Marked congestion and mononuclear cell infiltration around the bronchial walls and pulmonary arteries was observed in all sections examined in this group of animals. Excessive mucus was present in the bronchi and luminal epithelium with moderate degree of hyperplastic changes.

122 hours (PI)--Similar changes were seen. The hyperplastic changes were more pronounced. Some epithelial desquamation had occurred. Interstitial edema was present.

### Brain.

48 hours (PI)--There were numerous vacuoles in the gray matter of the brain parenchyma. In view of their irregular distribution and outline, these were inferred to be artifacts.

72, 98 hours (PI)--No lesions were found.

122 hours (PI)--In one of two sections intermeningeal hemorrhage had developed.

### Kidney.

48 hours (PI)--Vessels in the medullary region were markedly congested with mononuclear cell infiltration in one of five sections.

78, 98 hours (PI)--Similar changes were observed in the convoluted tubules associated with focal RE cell hyperplasia in the intertubular area. Whitish granular material was observed in the lumina of the convoluted tubules in H and E stains. PAS stain was positive.

122 hours (PI)--No lesions were observed.

### Liver.

48 hours (PI)--No lesions were observed.

72, 98 hours (PI)--The hepatic cytoplasm was aggregated into clumps, nuclei were eccentric in location, and some were pyknotic. This type of finding might be a normal histologic characteristic in female mice; however, a more systemic study would be required to substantiate this statement. The cytoplasm of liver cells of two sections was vacuolated. The nuclei were eccentrically located. Some were greatly enlarged while others were decreased in size.

122 hours (PI)--No lesions other than described above were found.

### Spleen.

48, 72, 98 hours (PI)--Some neutrophils and mononuclear cells were present in splenic venules in one section. Numerous megakaryocytes and band neutrophils were present in the red pulp. Some degenerated lymphocytes were found in white pulp. Whether

this is the type of lymphocytes found in lymphocytolysis described by Monlux and Spain is not clear (44).

122 hours (PI)--Similar lesions with marked severity were observed.

#### Intravenous Route of Inoculation

#### Histologic Findings in Adult Mice with NDV and Prednisolone.

##### Lung.

48 hours (PI)--Focal area of thickening of the alveolar walls was associated with focal area of hemorrhage and mononuclear cell infiltration in one of three sections. This lesion was observed in the alveolar walls adjacent to the pleura.

72 hours (PI)--There was a moderate to marked degree of mononuclear cell infiltration in the alveolar walls with a moderate degree of hemorrhage and congestion in three sections. In one of three sections, the alveolar walls were atelectatic associated with hemorrhage and mononuclear cell infiltration.

96 hours (PI)--The alveoli walls were moderately thickened by congestion and mononuclear cell infiltration. The bronchial epithelium was hyperplastic in one of five sections.

122 hours (PI)--Thickened alveolar walls in the peribronchial area were observed in three sections. These areas were infiltrated with red blood cells and a few mononuclear cells.

##### Brain.

48 hours (PI)--No changes were observed in the brain.

72 hours (PI)--A focal area of hemorrhage was observed in the stroma of the choroid plexus and in the meninges. A few lymphocytes were scattered in the parenchyma of the cerebellum.

96 hours (PI)--A focal area of mononuclear cell infiltration in the cerebellar parenchyma was observed in two sections.

122 hours (PI)--A focal area of hemorrhage in the meninges was present in one section. Round cells had infiltrated in the cortical area in other sections.

#### Spleen.

48 hours (PI)--Lymphoid follicle structures were greatly expanded into and replacing or displacing the red pulp and other inter-tissue spaces; in other areas the lymphoid follicles were atrophied. Megakaryocytes were numerous. There were focal areas of lymphocytolysis in one of two sections. These areas contained some tissue debris, which appeared to be primarily degenerated lymphocytes. Dark stained lymphocytes were focally infiltrated at the periphery of the white pulp.

72, 96, 122 hours (PI)--The white pulp in the section was enlarged to the extent that no red pulp was visible. Some lymphoid cells were hyperplastic, others were primitive.

#### Kidney.

48 hours (PI)--In one section a focal area of RE cell hyperplasia was observed in the intertubular area at the corticomedullary junction. Whitish granular material was present in the lumina of collecting tubules and some parts of the convoluted tubules. PAS stain revealed marked accumulation of PAS

positive material in the lumen of the convoluted tubules.

72, 96, 122 hours (PI)--Marked cloudy swelling was observed in the epithelium of the convoluted tubules. A whitish granular material filled the lumen.

#### Liver.

48 hours (PI)--PAS positive material was demonstrated in hepatic cells, especially at the periphery of the hepatic cells.

72, 96, 122 hours (PI)--No PAS positive material was demonstrated in these sections.

#### Histologic Findings in Adult Mice Inoculated with NDV Alone.

##### Lung.

48 hours (PI)--Two sections were normal except for a few focal areas of hemorrhage.

72 hours (PI)--A focal area of thickened alveolar walls with congestion was observed in one section.

96 hours (PI)--Acute suppurative bronchopneumonia was observed in one of three sections. Areas of cellular infiltration were present in the bronchial walls.

122 hours (PI)--A focal area of alveolar emphysema and atelectasis with diffuse congestion was observed in one of six sections. Areas of congestion and atelectasis of the alveoli, presumably due to mechanical force by hand manipulation on tissue were present.

##### Brain.

48, 72, 96, 122 hours (PI)--No significant pathology was found.

### Liver.

48 hours (PI)--Hepatic nuclei were hyperchromatic and the cytoplasm of hepatic cells in some areas was basophilic.

72, 98, 122 hours (PI)--Areas of cellular infiltration were present at the corticomedullary junction. There were focal areas of RE cell hyperplasia in two sections.

### Spleen.

48, 72 hours (PI)--The lymphoid follicles were hyperplastic in one section of five.

96, 122 hours (PI)--No particular changes other than described above were observed.

### Histologic Findings in Adult Mice Inoculated with NDV and Saline.

#### Lung.

48 hours (PI)--Focal areas of hemorrhage with thickened alveoli walls, marked congestion, and mononuclear cell infiltration were observed in one of three sections. The bronchial epithelium was hyperplastic in two sections. Arterial walls were thickened in one of two sections. This might be due to the different angle of sectioning.

72 hours (PI)--The alveoli walls were thickened due to atelectasis and congestion in three sections. The bronchial epithelium was desquamated resulting in ragged appearance.

96 hours (PI)--Changes of acute suppurative bronchopneumonia were observed in one section of five. In other areas, focal hemorrhage and diffuse congestion were observed. These changes were probably due to bacterial multiplication.



122 hours (PI)--Congestion and mononuclear cell infiltration around the pulmonary arteries were observed.

#### Brain.

48 hours (PI)--No lesions were observed.

72 hours (PI)--Congestion was observed in two sections. A focal area of hemorrhage was present in the parenchyma of the cerebellum. This was accompanied by demyelination in the white matter of the cerebellum.

96 hours (PI)--A focal area of parenchymal hemorrhage was observed in the cerebellum. Mononuclear cells had infiltrated in the tissue surrounding the ventricular area.

122 hours (PI)--A focal area of hemorrhage had developed in the choriomeningeal area in one section.

#### Kidney.

48 hours (PI)--No lesions were observed.

72 hours (PI)--A focal area of RE cell hyperplasia was observed. A whitish granular material was deposited in the convoluted and collecting tubules and was PAS positive.

96, 122 hours (PI)--No microscopic lesions were found.

#### Liver.

48 hours (PI)--No lesions were found.

72 hours (PI)--The cytoplasm was vacuolated and the nuclei were hyperchromatic. These changes were extensive.

96, 122 hours (PI)--In one section, the cytoplasm was deeply basophilic and the nuclei were hyperchromatic.

#### Spleen.

48 hours (PI)--The spleen was markedly congested.

72, 96 hours (PI)--No lesions were observed.

96, 122 hours (PI)--The spleens were moderately congested. There was marked band cell infiltration at the periphery of the lymphoid follicles.

#### Intracranial Route of Inoculation

##### Histologic Findings in Adult Mice Inoculated with NDV and Prednisolone.

###### Brain.

48 hours (PI)--Four of five sections had focal areas of hemorrhage in the cerebellar space, intermeningeal area, and in the brain parenchyma. The resultant hemorrhage appeared to be associated with mechanical trauma of injection rather than to viral infection or multiplication. Some neurons and oligodendria were degenerated as evidenced by variable shape and lack of specific staining reactions.

72 hours (PI)--Similar lesions were found in this group of sections.

98 hours (PI)--Moderate degree of perivascular cuffing, focal areas of hemorrhage, and marked infiltration of lymphocytes accompanied by demyelination in the white matter and neuronal degeneration in the gray matter of the cerebellum were observed in three of five sections. Central nervous alteration associated with NDV in fowl is characterized by thickening and proliferation of endothelium accompanied by early neuronal degeneration, glial clumps, and perivascular cuffings (Fig. 6). Since the virus control group of mice did not develop similar

lesions at this hour, the changes appear to be facilitated by the administration of prednisolone and NDV.

120, 160 hours (PI)--Varying degree of perivascular cuffing, lymphocytic infiltration in the gray matter and degenerative changes such as demyelination, chromatolysis, and neuronal degeneration were observed in four of six sections. In sections, the brain parenchyma stained irregularly basophilic, possibly indicating extreme degeneration immediately before necrosis.

#### Lung.

48 hours (PI)--Marked atelectasis and congestion were observed in lung sections. The bronchial epithelium was hyperplastic.

72 hours (PI)--Alveolar atelectasis with marked congestion was observed in lung sections. The bronchial epithelium was hyperplastic. Mononuclear cells had diffusely infiltrated the walls of the bronchiole in the area of marked alveoli emphysema in three of five sections.

98, 124 hours (PI)--Alveolar atelectasis with marked congestion was observed in seven sections. In some instances, mild fibrotic changes accompanied the atelectasis which appeared to have been present prior to the experiment.

#### Spleen.

42, 72 hours (PI)--Marked congestion of the red pulp with marked infiltration of band neutrophils surrounding the lymphoid follicles and primitive cells was observed in three sections. Some of the megakaryocytes were anuclear and

degenerated. The lymphoid follicles appeared to be enlarged with most lymphocytes undergoing hyperplastic changes.

98 hours (PI)--Degenerative changes as previously described with marked congestion of the perifollicular area was observed in one section.

124 hours (PI)--Marked congestion in the perifollicular area with focal area of hemorrhages was observed in two of five sections. Macrophages loaded with hemosiderin were numerous at the periphery of the congested red pulp.

#### Liver.

48 hours (PI)--Hydropic degeneration had developed in two of five sections. The hepatic sinusoids were compressed to the extent that no distinct hepatic lobules were seen. Markedly PAS-positive material was observed within the hepatic cytoplasm. Megakaryocytes were seen in one degenerated area of one liver section (Fig. 8).

72, 98 hours (PI)--Mononuclear cell infiltration in the wall of the bile ducts was observed in two of three sections. Hydropic degeneration was observed in all sections with small area of necrobiosis in some sections.

124 hours (PI)--No lesions were observed other than described above.

#### Kidney.

48, 72, 98, 124 hours (PI)--Mucoid cast formation and fatty droplet infiltration in the proximal convoluted tubules were observed in one section.

Histologic Findings in Adult Mice Inoculated with NDV Alone.

Brain.

48 hours (PI)--A small focal area of cerebral hemorrhage was observed in one of five sections.

72, 98 hours (PI)--There were intermeningeal hemorrhages which were considered to be due to trauma.

124 hours (PI)--There were mild focal areas of cerebral hemorrhage apparently due to mechanical trauma in three sections. An acidophilic stained mass was observed in the midcerebellar region which correlated with the point of injection.

Lung.

48 hours (PI)--The alveoli walls were thickened by congestion, edema, and mild mononuclear cell infiltration. The bronchial epithelium was also hyperplastic. There was excessive mucus formation in that region.

72, 98 hours (PI)--Alveolar emphysema and atelectasis with congestion was observed in two of seven sections. A moderate degree of septal cell proliferation had occurred along with diffuse congestion and a few areas of focal hemorrhage.

124 hours (PI)--Similar lesions were found in this group.

Liver.

48, 72 hours (PI)--A focal area of band neutrophil infiltration and an area of hemorrhage were observed in and surrounding bile duct area.

98 hours (PI)--The only change consisted of a few neutrophils which had infiltrated the bile duct area.

124 hours (PI)--No lesions were found.

Histologic Findings in Adult Mice Inoculated with Saline and Prednisolone.

Brain.

48 hours (PI)--Focal areas of hemorrhage and mild demyelination were observed in two of three sections.

72 hours (PI)--Sections from the brain had focal areas of hemorrhage in the meninges and chromatolysis was present in the brain parenchyma.

98, 124 hours (PI)--A focal area of hemorrhage was observed in the cerebellum of one of five sections.

Lung.

48, 72, 98, 124 hours (PI)--Acute suppurative bronchopneumonia was observed in three of five sections. This was accompanied by alveolar emphysema and atelectasis. The latter changes appear to be due to mechanical pressure by tissue manipulation rather than to antemortem changes.

Spleen.

48, 72, 122 hours (PI)--Some degree of lymphoid degeneration was observed in three of five sections. The regenerative architecture of two sections was replaced by scar tissue in the perifollicular area. This was probably a pre-existing lesion. There was no doubt that the prednisolone dosage used for daily treatment in this experiment exerted a marked degenerative effect upon the functional tissue of the spleen in adult mice.

### Liver.

48 hours (PI)--The cytoplasm of the livers was whitish granular within the cytoplasm in H and E stained sections; PAS stain revealed marked accumulation of PAS positive material.

72 hours (PI)--Hydropic degeneration with marked compression of the sinusoids and hepatic lobules was observed in three sections. The centrolobular areas were less severely affected. Compression of the hepatic lobe was marked making the limits of the hepatic lobules indistinct.

98, 124 hours (PI)--Marked hydropic degeneration had developed. A section stained with PAS method failed to reveal any glycogen-like material which has been described previously.

### Kidney.

48, 72 hours (PI)--Kidney sections revealed glycogen-like material deposited in the convoluted tubules and lesser amounts in the glomeruli.

98, 124 hours (PI)--Tubular degeneration with diffuse congestion of the medullary vessels was observed in one kidney section.

### Histologic Findings in Control Groups

Non-Treated Control Group. Ten mice which had received no treatment were randomly selected for the purpose of obtaining normal histologic sections for comparative purposes.

Lung. Three of five sections were congested with some degree of alveolar atelectasis.

Liver. Cloudy swelling with a focal area of fibrosis in a

bile duct area was observed in one of five sections.

**Spleen.** The red pulp filled the space between the terminal venous sinuses forming the splenic cords. The framework was formed by reticular fibers, primitive reticular cells and fixed macrophages. In addition to the lymphatic elements and the elements of circulating blood, free macrophage, small groups of myelocytes, erythroblasts, and plasma cells were present. Megakaryocytes were constant constituents although their number was variable. There was a great variation in the size of the spleen. The distal end of the organ occasionally was bifurcated.

Antibiotic Control. Ten mice were injected intramuscularly for five consecutive days with 2.5 mg. of Liquamycin as a check on the possible tissue damage due to agent.

**Lung.** Subacute broncho-pneumonia which is similar to that associated with the viral infection was found. This was typified by mononuclear cell infiltration in bronchial walls in three of six sections. No lesions were present in other organs.

Prednisolone Treated Group. Prednisolone diluted 1:5 with sterile saline solution resulting in a 2.5 mg. dose was injected intramuscularly in 10 adult mice as a check on the tissue effect of the steroid. A total of five injections were given at 24-hour intervals.

**Lung.** Atelectasis with congestion and some septal cell infiltration in alveolar walls was observed in one of five sections.

**Livers.** Sections from livers after 48 hours following initial treatment revealed marked degenerative changes with



severe vacuolization. PAS-positive materials were observed in the 48 to 72 hour sections. No lesions were observed in other tissue sections.

## DISCUSSION

Prednisolone profoundly altered the course of experimental NDV infection in adult mice. The administration of virus and steroid produced pulmonary and central nervous changes of greater severity as compared to lesions in groups of mice given virus alone or prednisolone alone. The histologic changes in the group treated with virus and prednisolone suggest that the hormone alters the animal's ability to localize the infectious process, not only in the lung but also elsewhere in the body.

The normal adult mice developed subacute pneumonitis when NDV was given by the intranasal route. Under the influence of prednisolone, encephalitis developed within 98 to 122 hours. Lesions were of greater severity in 122 hours. Liu and Bang (39) previously reported that encephalitis developed following intranasal administration of the virus in weanling mice although histologic examination was not made.

A moderate to marked degree of hemorrhage was observed in lung sections within 48 to 72 hours after the virus was given by the intravenous route. Marked hemorrhage was observed within 48 hours in the brain of mice of this group; however, signs of encephalitis developed several hours later. This may indicate that NDV virus given intravenously caused a toxic effect to the susceptible tissue.

Focal areas of hemorrhage encountered in the brain sections following intracranial inoculation are probably due to mechanical injury; however, a cellular response occurred after 98 hours.

The typical pneumonitis lesions developed after virus was given by the intracranial route. The mechanism of this development is not clear; however, the virus may have passed the blood-brain barrier in the reverse manner of encephalitis following intranasal inoculation, or the virus may be deposited in the vascular systems during inoculation.

The virus employed in this experimental study had a rather low HA titer. This may be due to the use of a non-refrigerated type of centrifuge or the use of eggs which had a titer of antibodies against the virus.

The important change in the cellular response induced by the prednisolone may not only alter the overall capacity of the host response, but also exert a more specific influence on individual cells such as lymphocytes, neutrophils, or fibroblasts which could disturb the orderly response to NDV infection and result in the establishment of a more favorable environment for microbial growth. The resultant suppurative bronchopneumonia which developed in numerous steroid treated mice during this experiment seems to substantiate this finding.

Marked deposition of PAS positive material in the liver and kidney sections in groups of mice within 48 to 72 hours followed steroid administration. No PAS positive material was detected after 72 hours in the same groups of animals.

Time apparently did not influence the sequence of lesion development. The duration of the histologic observation of this experiment was from 40 to 160 hours. This was based on the presumption that prednisolone must have markedly facilitated the

infection; however, prolongation of the experiment might have resulted in more definite lesions in sequence.

Tables 4 and 5 indicate that prednisolone considerably influenced tissue damage although they lack specific pathologic response. There appears to be marked degenerative effects to the parenchymal organs in prednisolone treated mice. The effect on lung following NDV inoculation intravenously resulted in considerable effects as shown in Table 4. Response to intracranial inoculation with the virus was markedly different. The mechanism of this variation may be due to or the result of the increased permeability of the brain barrier.

The administration of prednisolone to adult mice appeared to produce marked pulmonary congestion and, in some cases, alveolar atelectasis with emphysema accompanied by hyperplasia of the bronchial wall. These changes may be due to overmedication with the steroid.

This experiment has demonstrated that prednisolone induced suppression of the inflammatory response and other protective mechanism of the mouse to NDV, such as has been reported in other viral infections, thus rendering the animal susceptible to this infection.

## CONCLUSIONS

This experimental investigation indicates that R. O. strain of NDV has limited pathogenicity in adult mice for organs other than the lung and brain when the body resistance is reduced by the administration of prednisolone.

The "pneumoencephalitic nature" of NDV was greatly enhanced by the administration of prednisolone. The development of encephalitis and sub-acute pneumonitis within 48 hours after virus inoculation intranasally, intracranially, and intravenously confirmed this assertion. The control groups without prednisolone administration failed to reveal encephalitis by intravenous or intranasal route of inoculation.

## ACKNOWLEDGMENTS

The author would like to express his sincere and deep appreciation to Dr. J. L. West, Professor of Pathology, for his valuable suggestions and help that made this thesis possible. Many enlightening suggestions were available constantly from Dr. E. H. Coles, Head, Department of Pathology, Parasitology, and Public Health, and I would like to thank him for his help.

Dr. S. L. Issar, Instructor in the Department of Pathology, Parasitology, and Public Health, has given me much help during these experimental studies.

Part of this reference work was completed at Tulane University School of Medicine Library, New Orleans, Louisiana, where the author was privileged to work as a preceptee in laboratory animal medicine.

## REFERENCES

- (1) Anderson, W. A. H. Pathology. 16th ed., C. W. Mosby Co., St. Louis, Mo., 1957.
- (2) Burnet, F. M. The Affinity of Newcastle Disease Virus to Influenza Groups. Austral. J. Exptl. Biol. & Med., 20(1942):81-85.
- (3) Burnet, F. M. Human Infection with the Virus of Newcastle Disease Virus. Med. J. Austral., 2(1943):313-314.
- (4) Bang, F. B., and M. Foard. The Serology of Newcastle Disease Virus. I. The Reaction between Various Sera and the Virus. J. Immunol., 76(1956):342-347.
- (5) Baldelli, B. Sella Sensibilita dei Curiola al Virus die Newcastle. Vet. Ital., 6(1945):419-427.
- (6) Brandly, C. A., E. Upton, and R. E. Hanson. Intracerebral Inoculation of Mice with Newcastle Disease Virus. J. Infec. Dis., 96(1955):24-25.
- (7) Beckman, H. Pharmacology. 2nd ed., W. H. Saunder's Co., Philadelphia, Pa., 1961.
- (8) Brandly, C. A., H. E. Moses, E. L. Jungherr, and E. E. Jones. The Isolation and Identification of NDV. Am. J. Vet. Res., 78(1946):289-306.
- (9) Baron, S., C. E. Bruckler. Circulating Interferon in Mice after Intravenous Injection of Virus. Science, 141(1963):1061-1063.
- (10) Berkheiser, S. W. Epithelial Proliferation of the Lung Associated with Cortisone Administration. Cancer, 16(1963):1354-1364.
- (11) Biester, H. E., and L. H. Schwarte. Disease of Poultry. Iowa State Press, Ames, Iowa, 1959.
- (12) Bawell, M. B., M. Legrier, F. Murrey, W. Schofield, and G. O. Brown. Occurrence of Antihemagglutinins against NDV in Human Respiratory Infection with a Possible Instance of Virus Isolation. J. Lab. & Clin. and Med., 34(1949):1581-1582.
- (13) Davenport, R. P. Pulmonary Toxicity in Mice. Fed. Proc., 10(1951):405-406.
- (14) Dardine, A. H., V. J. Yates, and D. T. Flanagan. The Reaction to Infection with the B-1 Strain of Newcastle Disease Virus. Am. J. Vet. Res., 23(1962):918-920.

- (15) Evans, A. S. Newcastle Disease Neutralizing Antibody in Human Sera and its Relationship to Mump Virus. *Am. J. Hyg.*, 60(1954):204-213.
- (16) Evans, A. S. Pathogenicity and Immunology of Newcastle Disease Virus in Man. *Am. J. Pub. Health*, 45(1955):742-745.
- (17) Foley, E. J. Therapeutic Effect of Chlorotetracycline and Oxytetracycline in Immunized Mice Treated with Cortisone. *Antibiotic and Chemotherapy*, 5(1955):1.
- (18) Ginsberg, H. S. Mechanism of Pulmonary Lesions in Mice with Newcastle Disease Virus. *J. Exptl. Med.*, 94(1951):190-211.
- (19) Gordon, P., and E. P. Beneditt. Influence of Hormone (Growth, ACTH, Thyrotropin, and Cortisone) Upon Complement Level in Rabbit. *Proc. Soc. Exptl. Biol. and Med.*, 89(1955):286-288.
- (20) Groupe, V., R. M. Dougherty, and R. A. Mauaker. Comparative Effects of Hydrocortisone, a Derived Pyridopyrimidine and Xerosine on Pneumonia Produced in Mice by Viral and Bacterial Toxin. *J. Bac.*, 72(1956):604-609.
- (21) Germuth, F. G., Jr. The Role of Adrenocortical Steroid in Infection, Immunity, and Hypersensitivity. *Pharmacol. Rev.*, 8(1956):1-24.
- (22) Hofstad, M. S. Experimental Inoculation of Newcastle Disease Virus Into Swine and Sheep. *Cornell Vet.*, 40(1950):190-197.
- (23) Hewitt, B. F., Bishop, L. K., and R. E. Kingsling. The Presence of Neutralizing Antibodies of Newcastle Disease Virus in Human Sera. *Am. J. Pub. Health*, 38(1948):1263-1274.
- (24) Hewitt, B. F. A Non-Specific Heat Labile Factor in the Serum Neutralization Test for Newcastle Disease Virus. *J. Immunol.*, 64(1950):73-84.
- (25) Hamboldt, C. F., A. M. Lugenbuhl, and S. R. Hamner. The Effect of Some Avian Neurotropic Virus on Young Dairy Calves. *Am. J. Vet. Res.*, 16(1955):57.
- (26) Hanson, R. P., and C. A. Brandly. Newcastle Disease. Symposium on Animal Disease and Human Health. *Ann. N.Y. Acad. Sci.*, 70(1958):585-597.
- (27) Hoffman, W. S. Biochemistry of Clinical Medicine. The Yearbook Publisher, N.Y., New York, 1960.



- (28) Horsfall, F. L., and I. Tauner. Fractional Dilution Procedure for Precise Titration of Hemagglutination Virus and Hemagglutination-Inhibition Antibody. *J. Immunol.*, 70(1953):253-259.
- (29) Hull, H. Transmissible Disease from Man to Animals. 1st ed., Charles C. Thomas, Springfield, Illinois, 1955.
- (30) Kilham, L. M. Variation in Behavior of Newcastle Disease Virus on Passage Through Brain of Adult Mice. *Am. J. Vet. Res.*, 13(1950):305-307.
- (31) Karstad, L., J. Splatn, and R. P. Hanson. Experimental Infection of Wild Birds with the Virus of Eastern Equine Encephalitis, Newcastle Disease Virus and Vascular Stomatitis. *J. Infec. Dis.*, 105(1959):95-188.
- (32) Karzon, D. T. Non-Specific Viral Inactivity Substance in Human and Mammalian Sera. Natural Antagonist to the Inactivator of Newcastle Disease Virus and Observation on the Nature of the Serum between the Inactivator and Virus. *J. Immunol.*, 76(1956):454-463.
- (33) Kass, E. H., and M. Finland. Adrenocortical Hormones in Infection and Immunity. *Am. Rev. Microbiol.*, 7(1953):361-388.
- (34) Kall, E. Clinical Endocrinology. Harper's and Brother's, 1st., New York, N.Y., 1958.
- (35) Kilbourne, E. D. Influence of Cortisone on Experimental Viral Infection. II. Effects on Antibody Formation and Acquired Immunity. *Proc. Soc. Exptl. Biol. and Med.*, 90(1955):685-687.
- (36) Kilbourne, E. D. Reactivation of Non-infective Virus in a Cortisone Injected Host. *J. Exptl. Med.*, 101(1955):437-450.
- (37) Khobyanan and D. L. Welhr. The Effect of Cortisone on Mouse Resistance to Intravenous Toxicity of Influenza Virus. *Proc. Soc. Exptl. Biol. and Med.*, 94(1954):295-298.
- (38) Kass, E. H., and M. Finland. Adrenocortical Hormones and the Management of Infection. *Ann. Rev. Med.*, 8(1957):1-18.
- (39) Liu, V., and F. B. Bang. Development of Encephalitis of Intranasal Inoculation with Newcastle Disease Virus. *Am. J. Hyg.*, 55(1952):182.

- (40) Luttrell, C. N., and F. B. Bang. Newcastle Disease Encephalitis in Cats. 2. Clinical and Pathological Feature. Arch. Neurol. and Psychiat., 79(1958):642-657.
- (41) Le Masistre, C. A., and R. Tonsett. Emergence of Pseudo-tuberculosis in Rats Given Cortisone. J. Exptl. Med., 95(1952):393-408.
- (42) Mitchell, C. A. Newcastle Disease Virus in Relation to Public Health. Proc. Book. A.V.M.A., (1953):432-434.
- (43) Mitroia, P., and C. Vior. Pathogenicity and Immunity Capacity of Fowl Plague and Newcastle Disease for Hamster. Publ. Epis. Bucarest, 10(1960):47-56.
- (44) Molnut, N., A. M. Spain, and A. Harber. The Effect of Cortisone on the Spleen in Mice. Proc. Soc. Exptl. Biol. and Med., 73(1959):416.
- (45) Nimi, and G. A. Immuta. Pathological Studies on Experimental Fowl Pest with Mice. J. Jap. Vet. Sci., 5(1943):550-551.
- (46) Newsorns, S. E., and M. Danach. The Effect of Cortitropin and Corticosterone on the Production of Hemolytic Antibodies in the Mouse. Canad. J. Biochem. & Physiol., 33(1958):374-379.
- (47) Ozawa, Y., and P. C. Chow. A Study and Identification of Newcastle Disease from Ranch Cattle Infected with Shipping Fever. Poult. Sci., 37(1955):802-809.
- (48) Okasewara, K., and M. Nakayama. Mechanism of Production of Pulmonary Consolidation. Virology, 6(1955):288-290.
- (49) Prudovsky, S., C. N. Luttrell, and N. Roizman. Encephalomyelitis and Pneumonitis in Hamster Infected with Newcastle Disease Virus. Proc. Exptl. and Biol. and Med., 107(1961):656-659.
- (50) Quinn, R. W., R. P. Hanson, J. W. Brown, and C. W. Brandly. NDV in Man-Results of Studies in Five Cases. J. Lab. Clin. and Med., 40(1952):736-743.
- (51) Quesnell, B., and G. Ramanibajafg. Behavior of the Newcastle Disease Virus in the Pigs. Bull. Acad. Vet., 27(1945):367-370.
- (52) Reagan, R. L., M. G. Lillie, and A. L. Bruckner. Transmission of NDV to Syrian Hamster. Am. J. Vet. Res., 8(1947):136-138.

- (53) Reagan, R. L., M. Lillie, D. E. Smith, and A. C. Bruckner. Comparison of Newcastle Disease Virus in Hamsters Exposed by Intracerebral Injection and Intranasal Instillation. Proc. Soc. Exptl. Biol. and Med., 71(1949):293-295.
- (54) Reagan, R. L., A. L. Bruckner, and C. A. Brandly. Response of Swiss Albino Mouse to the Virus of Newcastle Disease. J. Bac., 61(1951):453-454.
- (55) Reagan, R. L., M. G. Lillie, and A. L. Bruckner. Transmission of the Hamster Adapted Newcastle Disease Virus to Swiss Albino Mice. Proc. Soc. Exptl. Biol. and Med., 70(1949):5-6.
- (56) Reagan, R. L., W. C. Day, and M. P. Hammon. Pathogenicity of Mouse Adapted Newcastle Disease Virus to Chicken, Hamster, and Mouse. J. Exptl. and Med., 42(1952):334-337.
- (57) Reagan, R. L., and A. L. Bruckner. Studies of Newcastle Disease Virus in Cotton Rat. Cornell Vet., 42(1952):331-333.
- (58) Reagan, R. L., D. M. Schweak, H. O. Line Weaver, and A. L. Bruckner. The Distribution of Newcastle Disease in the Tissue of the Large Brown Bat. Cornell Vet., 42(1952):80-84.
- (59) Reagan, R. L., S. C. Chang, F. S. Yancey, and A. C. Bruckner. Isolation of Newcastle Disease Virus from Man with Confirmation by Electron Microscopy. J. Am. Vet. Med., 129(1956):79-80.
- (60) Reagan, R. L., E. C. Dilaha, S. K. Cook, and A. C. Bruckner. Response of Kittens to the California Strain of Newcastle Disease Virus after Oral and Nasal Route of Exposure. Poul. Sci., 33(1954):1272-1276.
- (61) Rovenski, Y. U. Changes in subcutaneous Connective Tissue of Rats after Injection of Cortisone. Bull. Exptl. Biol. and Med., 50(1960):735.
- (62) Speir, R. W., and C. M. Southham. Interference of Newcastle Disease Virus With Neuropathogenicity of Oncolytic Virus in Man. Ann. N. Y. Acad. Sci., 83(1960):551-563.
- (63) Schwarzman, G. The Effects of ACTH and Cortisone upon Infection and Resistance. Columbia Univ. Press, New York, N.Y., 1953.
- (64) Solovov, U. N. The Effect of Bacterial Effect Activity of Serums of Infected Animals. Bull. Exptl. Biol. and Med., 47(1950):580-585.

- (65) Schriekner, R. C., and L. E. Hanson. Effect of Cortisone on Lentospira pomona Infection in the Guinea Pigs. Am. Vet. Res., 22(1961):580-585.
- (66) Stenbeck, W. A., and D. F. Durand. Host Influence on the Density of Newcastle Disease Virus. Virology, 20(1963):545-551.
- (67) Steale, J. H. Forwarding Remarks, Poultry Disease in Public Health: Review for Epidemiologist. U.S.P.H., Pub. No. 767 (1960):1.
- (68) Thomas, L. Cortisone and ACTH with Infection. Bull. N.Y. Acad. Med., 31(1955):383-499.
- (69) Thomas, L. Infectious Disease. Effect of Cortisone and Adrenocorticotrophic Hormone in Infection. Ann. Rev. Med., 31(1952):1-24.
- (70) Totten, R. S., and T. J. Moran. Cortisone and Atypical Pulmonary Epithelial Hyperplasia--Effect of Pretreatment with Cortisone on Repair of Chemically Damaged Rabbit Lung. Am. J. Path., 38(1961):575-586.
- (71) Upton, E., R. P. Hanson, D. Dow, and C. A. Brandly. Studies on Intracerebral Inoculation of Newcastle Disease Virus into Mice. I. Response of Weanling Mice to 25 Strains of NDV. J. Infec. Dis., 92(1953):175-182.
- (72) Upton, E., R. P. Hanson, D. Dow, and C. A. Brandly. Intracerebral Inoculation of Mice with Newcastle Disease Virus. J. Infec. Dis., 96(1955):24-33.
- (73) Wenner, H. A., and B. Lash. Choriomeningo-encephalitis Following Inoculation of Newcastle Disease Virus in Rhesus Monkeys. Proc. Soc. Exptl. Med., 70(1949):263-265.
- (74) Wenner, H. A., A. Monley, and P. Todd. Studies on Newcastle Disease Virus Encephalitis in Rhesus Monkeys. J. Immunol., 64(1950):305-321.
- (75) Wilcox, W. C., E. M. Wood, O. H. Jang, and C. H. Evans. Morphological and Functional Changes in Corneal Endothelium caused by the Toxic Effects of Influenza and Newcastle Disease Virus. Brit. J. Exptl. Biol. and Med., 107(1951):601-609.
- (76) Yates, V. S., F. Dorothy, and F. I. Henderson. Isolation of Newcastle Disease Virus from Calf. J.A.V.M.A., 120(1952):331-333.

REPORT OF  
THE LIGHT BOARD  
ON  
THE RIVER

APPENDIX

Fig. 1. Differences of spleen size are shown.

Fig. 2. Marked dissimilarity was noted in one group of animals. Notice the small liver and spleen in the cortisone treated animal on the left.

Fig. 3. Typical symptoms of mental seizure and hindleg paralysis were seen after the virus inoculation intracranially with prednisolone.

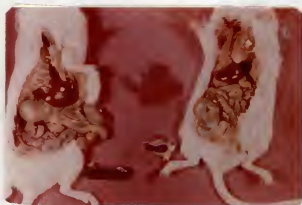



Fig. 4. Photomicrograph of lung showing a discrete focal area of consolidation which was possibly induced by NDV and Prednisolone. H & E stain: X 400.

Fig. 5. Photomicrograph of kidney showing marked accumulation of PAS-positive material in the convoluted tubules. PAS stain: X 400.



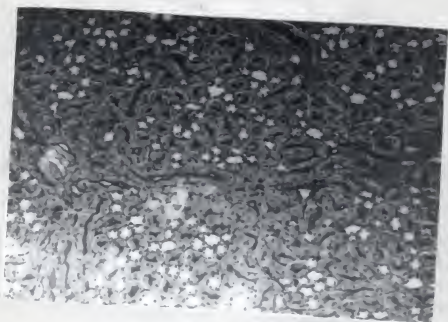
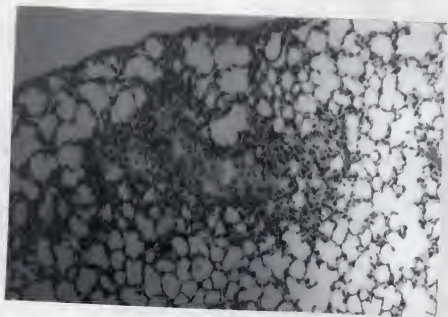


Fig. 6. Photomicrograph of medullary part of the brain showing marked perivascular cuffing in the cerebellum in prednisolone treated mice following NDV inoculation intracranially. H & E stain: X 600.

Fig. 7. Photomicrograph of lung section showing a marked alveolar atelectasis with mononuclear cell infiltration. Notice the hyperplastic bronchial walls or mucosa. H & E stain: X 400.

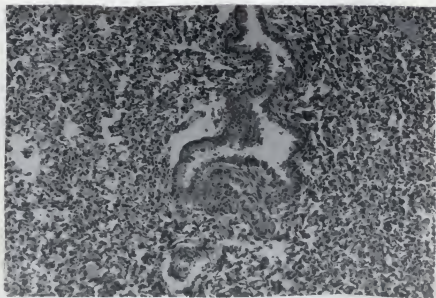
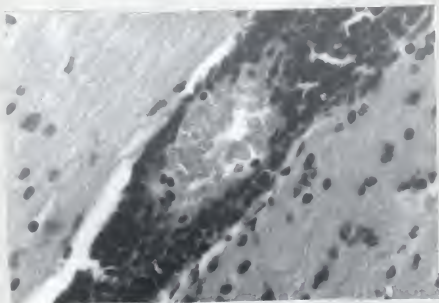
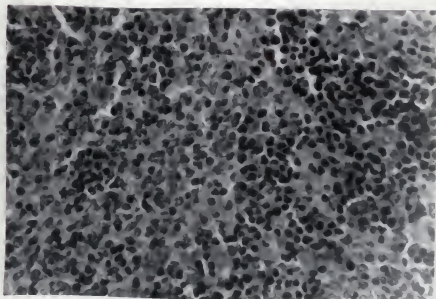
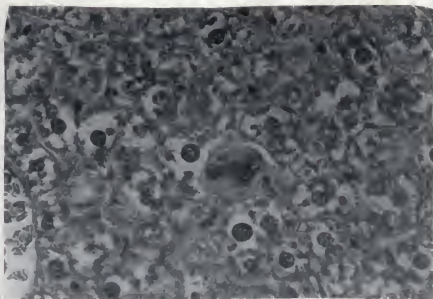


Fig. 8. Photomicrograph of liver section showing degenerated hepatic cytoplasm with presence of megakaryocytes. H & E stain: X 600.

Fig. 9. Photomicrograph of spleen showing the infiltrating small lymphocytes at the periphery of white pulp. H & E stain: X 600.



THE INFLUENCE OF PREDINISOLONE UPON THE PATHOLOGIC  
RESPONSE OF ADULT MICE TO NEWCASTLE DISEASE VIRUS

by

CHIN SOO KIM

D.V.M., Seoul National University, 1960  
M.P.H., Seoul National University, 1962

---

AN ABSTRACT OF A MASTER'S THESIS

submitted in partial fulfillment of the

requirements for the degree

MASTER OF SCIENCE

Department of Pathology, Parasitology,  
and Public Health

KANSAS STATE UNIVERSITY  
Manhattan, Kansas

1965

The ability of Newcastle disease virus (NDV) to multiply in mammalian hosts appears to be limited; however, the virus has been isolated from various species of domestic animals and human beings. The amazing increase in poultry population throughout the world in recent years has focused attention on fowl as a reservoir of infections for man and animals. The milder the strain of NDV, the broader the host spectrum. This fact adds impetus to the importance of this virus from a public health point of view.

The injurious effects of NDV in abnormal hosts are widespread. Experimental studies, however, with different strains of NDV have resulted in considerable variation in pathogenicity and virulence from strain to strain of the virus and from species to species employed.

Corticosteroids are known to be effective agents for reducing resistance and promoting widespread infection. A considerable amount of work has been done with myxoviruses employing corticosteroids for that purpose. Since no experimental studies have been reported concerning the combined effect of NDV and corticosteroids, experiments were conducted in an attempt to elucidate the histopathologic responses in adult mice treated with prednisolone and NDV and NDV alone. One hundred ninety-eight week-old Charles River albino mice were randomly divided into 12 groups according to the route of virus inoculation. For intranasal inoculation 20 mice were lightly anesthetized with ether, and 0.05 ml. of undiluted allantoic-  
amnionic infected viral fluid was deposited in the external

nasal opening employing a 0.5 ml. tuberculin syringe and 26 gauge needle. For intracranial inoculation, 0.05 ml. of undiluted viral fluid was deposited in the mid-cerebral region of 20 mice using a 29 gauge needle and 0.5 ml. tuberculin syringe. For the intravenous inoculation, 0.05 ml. of the virus was injected into the tail vein of 20 mice. For the experimental as well as control groups of animals without virus inoculation, 2.5 ml. (0.25 mg.) of prednisolone were given intramuscularly 18 hours prior to virus inoculation. Five mice from the experimental as well as control group were randomly selected for necropsy at the following time intervals: 48, 72, 96, 120, and 160 hours. Portions of lung, liver, kidney, spleen, and brain were carefully examined grossly before placing in 10 per cent buffered formalin fixative. Tissues were embedded in paraplast, sectioned at a thickness of seven to eight microns, and stained routinely with hematoxylin and eosin and periodic acid schiff methods. Portions of the indicated tissues were used for hemagglutination test.

Four hundred and thirty-two histologic sections were examined in detail. The results of this experimental investigation indicated that R.O. strain of NDV had limited pathogenicity in adult mice for organs other than lung and brain. The lesions were more severe when body resistance was reduced by administration of prednisolone. The pneumoencephalitic nature of NDV was greatly enhanced by administration of prednisolone. Development of encephalitis and sub-acute viral pneumonitis within 48 hours following intranasal, intracranial, and intravenous inoculation



confirmed this assertion. Control groups failed to develop these changes.