

AN EVALUATION OF A CHEMICAL DEPILATORY FOR PREPARATION
OF VETERINARY SURGICAL PATIENTS

by

GLENN THEODORE HARTKE

B.S., Kansas State University, 1958
D.V.M., Kansas State University, 1960

A MASTER'S THESIS

submitted in partial fulfillment of the

requirements for the degree

MASTER OF SCIENCE

Department of Anatomy

KANSAS STATE UNIVERSITY
OF AGRICULTURE AND APPLIED SCIENCE

1965

Approved by:


Major Professor

LD
2668
T4
1965
H36
c.2
Document

TABLE OF CONTENTS

INTRODUCTION	1
MATERIALS AND METHODS	3
REVIEW OF LITERATURE	15
RESULTS	20
DISCUSSION	28
SUMMARY	35
ACKNOWLEDGEMENTS	38
LITERATURE CITED	39
APPENDIX	42

INTRODUCTION

The removal of hair from the body surface is an important step in the aseptic preparation of a patient for surgery. Due to the very nature of veterinary surgical patients, with their heavy hair cover, hair removal is not only important but a vital step prior to surgery. Clipping alone or clipping together with shaving are two traditional methods currently used in veterinary medicine to remove hair prior to surgery. Although generally satisfactory, these methods are attended by several disadvantages. Both are time-consuming, and adequate removal of hair may be difficult due to the topography of certain areas of the body. Shaving or clipping over a sensitive area may be extremely painful to the patient and because of patient resistance difficult to perform. In the case of an open wound, it is almost impossible to clip or shave the area around the immediate edge of the wound. There is also the possibility of a foreign body reaction occurring from hair entering the wound and delaying healing. If the above techniques are not skillfully performed, the skin may be excoriated, offering an ideal portal of entry for infection, and resulting skin blemishes may occur after healing. If the equipment is not sterile, there is the possibility of transferring pathogenic organisms from one patient to another or, if the equipment becomes contaminated, the transference of an infection from one area to another area of the same patient may occur.

Chemical methods of hair removal offered an intriguing possibility in the preoperative preparation of the surgical patient. This method avoids some of the aforementioned shortcomings and difficulties of the shaving and/or clipping techniques. Chemical depilation has been known since antiquity but has only recently been investigated as an agent or tool to aid in surgery.

Some of the earlier chemicals tried by Prigot *et al.* (21) were malodorous, unpredictable in their action, and had a high incidence of local irritation and systemic toxicity. Some of the early investigators as Irwin (13) specifically warned against their use on cats.

Today's fashions in women's apparel necessitates the removal of superfluous hair, and for this cosmetic purpose many different chemical depilatories have been developed. It was not until the introduction of depilatories with thioglycollates as their active ingredient that reliable and relatively safe, nontoxic chemical depilatories became available. Investigation of these preparations indicated their possible use for preoperative hair removal.

An ideal chemical agent for the preoperative removal of hair should effectively remove the hair; be nontoxic locally and systemically; be easy to apply and remove; should not interfere with wound-healing; should not be detrimental to the skin; should not inhibit regrowth of hair; should be effective in less time; and should cause the patient less discomfort than shaving and/or clipping techniques.

For this investigation the chemical depilatory Neet,¹ a proprietary compound containing calcium thioglycollate used extensively in the cosmetic field, was selected and evaluated for its efficacy as a hair-removing agent in veterinary surgery. Cats were chosen for the experimental animal because earlier investigators indicated that they were extremely sensitive to other chemical depilatories containing thioglycollates; also, cats were easier to obtain and maintain as experimental animals; and because of the difficulties encountered when attempting to clear an area of hair using the clipper and/or razor.

¹"Neet"; Whitehall Laboratories, New York, N. Y.

MATERIALS AND METHODS

This study was divided into two parts. Part I was a study of the use on cats of a chemical depilatory to prepare sites for surgery. This was further divided into eight experimental trials designed to study the phases necessary for a complete evaluation. Part II was set up to clinically evaluate the knowledge gained from Part I on other domestic animals.

Part I

In Part I a total of 41 cats, 11 males and 30 females, were used. Because stray or abandoned animals were used, the ages of the cats were not determined accurately and were classified as either adults or kittens when used in the experimental trials (Table 1).*

As the cats were received, they were examined for status of health and kept in an isolation ward under close observation for a period of at least 2 weeks. Those cats exhibiting indications or possibilities of any active disease process, which was considered infectious in nature, were euthanatized. This was done to reduce the possible spread of an infectious disease among the experimental trial groups and to build up a reserve of healthy cats for succeeding experimental trials. Some cats were received with open wounds and abscesses. These cats were kept in the isolation ward and used immediately for Experimental Trial Number 7. Any cat with endoparasites or ectoparasites was treated and kept to be used when healthy following treatment. Pregnant females were used in all trials except when the clinical procedure called for the use of a general anesthetic. If young were born while the female was

*All tables are in Appendix.

involved in an experimental trial or waiting in isolation, they were kept together as a family and used as such.

The cats were handled with a minimum of restraint and without the use of tranquilizers or sedatives. This procedure was instituted to guard against the possibility of masking or exaggerating any responses which might occur during any phase of this investigation.

As each cat was selected, it was moved from isolation to the experimental ward where it was allowed to stay for 2 days before any experimentation was initiated. While the cats were in an experimental trial, they were housed in stainless steel cages which were cleaned daily with a Chlorox and detergent mixture, rinsed thoroughly with water, dried and newspapers spread on the cage floors. No litter or sand boxes were used. The diet for all cats was Purina Cat Chow fed ad lib., with free choice of water.

In instances where a general anesthetic was required, sodium pentobarbital was used and given by one of two different routes. It was administered either intravenously or intraperitoneally at 1 grain per 5 pounds. The anesthetic was administered intraperitoneally only when the cats were hard to handle.

Most trials involved clipping hair from parts of the body of the cats. This clipping was accomplished by using a Number 10 Oster blade, and always done with the hair stream.

The body area clipped for most of the experimental trials was usually quite extensive. It extended ventrally from the dorsal spines of the thoracic and lumbar vertebrae to the linea alba and cranially from the tuber coxae to the 6th rib (Plate I).* By utilizing these same anatomical landmarks, it

*All plates are in Appendix.

minimized variations which might have arisen due to size or age of the cat. This area provided variations in skin thickness as well as variations in density and texture of the hair. These considerations were of paramount importance to fully evaluate chemical depilation. On these areas, four primary sites were chosen to be used for most of the evaluations: (1) lateral thoracic wall, which gave an area where the topography of the skin was uneven and tightly attached to the underlying tissue; (2) the back, which provided an area where the skin was thick and the hair was coarse and dense; (3) the lateral abdominal wall, which was smooth in contour and loosely attached to the underlying tissue; and (4) the ventral abdominal wall, which gave an area where the skin was thin and the hair was sparse. These sites correspond to A, B, D, and D (Plate I). The foregoing sites were each 3x3 cm in area. The secondary areas were the feet, ears, neck, head, scrotums, preputial area, knees, hips, and over the point of the shoulders.

Part II

At the commencement of this experiment, Neet was purchased direct from a local pharmacy. However, as the investigation progressed it was furnished by the manufacturer in bulk form and stored in closed glass containers. Before each trial, it was transferred and used directly from 50 cc plastic syringes as partially-filled containers caused gradual loss of the depilatory efficacy.

Part II of this investigation included 5 horses, 4 cows, 9 pigs, 6 dogs, and 46 cats. This phase was initiated after the evaluation of Part I and was concerned chiefly with the clinical effectiveness of hair removal and possible side reactions.

Experimental Trial Number 1

Four major objectives were pursued for use in subsequent trials:

(1) whether it was more advantageous to use Neet in the lotion or the cream form; (2) what method of application was most effective; (3) what time periods were most efficient; and (4) what method of depilatory removal was most appropriate to the body area involved.

The lotion and the cream were evaluated for: (1) ease of application; (2) amount required to sufficiently cover a predetermined area of hair and skin; (3) neatness, in terms of efficiency of hair removal; and (4) ease of removal of the chemical from the skin.

The four methods of application tried were: (1) spreading the depilatory with a tongue depressor; (2) applying the depilatory directly from or with a roll-on applicator bottle; (3) distribution of the depilatory with the fingers; and (4) spreading the material with a nylon artist brush.

The depilatory was applied and allowed to remain in contact with the skin and hair for 2, 5, 10, and 15 minute intervals. The timing began after the entire area was exposed to the depilatory.

The methods of removal were: (1) wiping off with a wet sponge; (2) wiping off with a dry sponge; (3) scraping off with a tongue depressor; and (4) rinsing off under warm tap water while wiping lightly with a gauze sponge.

Four adult black cats were selected—2, short coarse-hair females, and 2, long fine-hair females. The only intended variable was the length and texture of hair.

This trial was divided into four testing periods each separated by a three-week interval or after the hair was back in and the areas were considered covered. Each period began with clipping both sides of each cat with a

Number 10 Oster blade, as outlined on Plate I. The lotion form of Neet was applied on the left side and the cream form was applied on the right side of the four designated areas, A, B, C, and D (Plate I).

In the first testing period, the depilatory was applied to all four areas with a tongue depressor, allowed to remain in contact for 2 minutes, and removed by wiping with a wet sponge. Three weeks later, in the second testing period, Neet was again applied to the same areas with or from a roll-on applicator bottle, remained in contact for 5 minutes, and was removed with a dry gauze sponge. In the third test, still using the same 4 cats, the depilatory was spread on the areas with the finger and in 10 minutes it was scraped off with a tongue depressor. For the last test, the depilatory was spread over the same areas with an artist brush and removed after 15 minutes by running warm water over the area while rubbing lightly with a gauze sponge.

Experimental Trial Number 2

Trial Number 1 results developed a pattern related to effectiveness of method of application, contact times, and form of Neet.

Four weeks were allowed to elapse, and the same 4 cats used in Experimental Trial Number 1 were used again to study 5 and 10 minute exposure periods of the lotion, applied with the finger and removed under running water while wiping with a gauze sponge. At this time it appeared that these two exposure periods were working best, if the depilatory was applied or spread over the areas with the finger tip and removed under warm running water. The four-week interval between the two testing periods allowed the cats to recover completely with a new growth of hair. This trial was to study the comparative efficiency for each of these contact times with the lotion and to further evaluate the aforementioned application and removal techniques.

Both sides of the cats were again clipped and areas A, B, C, and D (Plate I) were exposed to 5 minutes on the left side and 10 minutes on the right side. Secondary areas, such as the feet, ears, over the hip (trochanter major), over the knee (stifle joint), and the shoulders, were all exposed at this time to the depilatory for the same time periods. After a second four-week waiting period this same procedure was tried again.

Experimental Trial Number 3

From close observance of the results of the previous two trials, it was decided to investigate more thoroughly the respective efficiency of the 5 and 10 minute contact times. This was necessitated by the variance in hair removal effectiveness. Sometimes all the hair was removed, while in other instances very little was removed.

For this trial, 6 gray cats were selected for their specific length and texture of hair. There were 4 adult cats and 2 kittens (Table 1).

All cats were prepared as in previous trials, the left side receiving the 5 minute and the right side the 10 minute exposure to the depilatory lotion, applied with the finger, and removed with a gauze sponge under warm tap water.

The four primary sites A, B, C, and D (Plate I) were used to fully evaluate and rate the respective efficiency of hair removal. Each site was exposed four times, with a three-week interval between each application. Efficiency of hair removal of each area was rated by the neatness and by counting all primary hair remaining on each of the 3x3 cm plots. The total was divided by nine, and this number was then recorded as "primary hair remaining per square centimeter." This numerical value was transposed to denote the efficiency of hair removal. The three classifications of efficiency were

excellent, fair, and poor. A site was rated excellent when 0 to 2 primary hairs remained per square centimeter and if the general area was left clean and smooth. If 2 to 4 primary hairs remained per square centimeter and the area presented a clean smooth surface, it was considered fair. The classification of poor was used for sites on which the area was not clean and had 4 or more primary hairs remaining per square centimeter.

At the same time, the feet, scrotum, shoulders, ears, hips, and knees of all cats were also being depilated and rated. Again, the areas on the left received the 5 minute exposure to the depilatory and the areas on the right and scrotum received 10 minutes of contact.

Experimental Trial Number 4

A family of 6 white short-hair cats were utilized for this experimental trial. There were 5 kittens and 1 adult female (Table 1). The kittens were born while the female was being held in the isolation ward and were 10 weeks old and weaned before the trial began so that each could be held in a separate cage.

This trial was primarily designed to study both the immediate and the long-term effect on cats of repeated application and prolonged contact of the chemical depilatory on the skin and hair.

The left side of all 6 cats was clipped, and the depilatory was then applied to areas A, B, C, and D (Plate I) with an exposure period of 15 minutes. After 15 minutes the mass (depilatory and hair) was rinsed off, and after the sites were allowed to dry the areas were observed for any undue responses. If any side reaction was suspected or developed, skin sections were taken, fixed in 10% buffered formalin, and slides were prepared for microscopic study. This procedure was repeated 3 times with 10 day intervals

between tests, the depilatory being allowed to remain on the skin for each successive testing period for 30, 45, and 60 minutes, respectively.

The feet, ears, and scrotum were also observed for their respective sensitivity to the depilatory. The left front feet and left ears were subjected to the depilatory for 15 minutes. The right front feet, right ears, and the scrotums were all allowed a 30 minute exposure period. Cat number 4-1 had an ingrown toenail and this foot was not used until it was healed.

All applications during this trial were done without tranquilizers, sedatives, or anesthetics. When skin sections were taken, the cats were given a general anesthetic, the specimen surgically excised, and incisions were sutured with Number 36 stainless steel wire and removed on the ninth day, one day before each succeeding test.

Experimental Trial Number 5

This trial, using 6 adult cats, was to study the effects of the depilatory on surgical wound-healing (Table 1). The areas chosen were those which are most often encountered in surgical procedures: (1) midline abdominal, caudal to the umbilicus; (2) lateral abdominal wall; (3) lateral surface of pelvic leg; (4) thoracic wall, at the seventh intercostal space; and (5) the plantar and volar surfaces of the feet.

The effects on experimental incisions had been noted to a very limited extent where skin sections were taken during previous trials. All surgical procedures in this experimental trial were done under general anesthesia.

The surgical sites were then prepared by clipping with a Number 10 Oster blade. One half of the area was further shortened with a Number 40 Oster blade, and the remaining half was cleared of hair with the depilatory applied with the finger which was allowed to remain on the site for 10 minutes, and

then removed with a gauze sponge under warm tap water. The entire area was then scrubbed with a neutral Ph detergent (Phisohex),¹ and an alcoholic quaternary ammonium compound pack was applied to the surgical site. The pack remained in place for 10 minutes prior to making the incisions.

The incisions were made only through the skin and, whenever possible, were 3 inches in length, extending through both the clipped and the depilated areas. The incisions were sutured with Number 36 stainless steel wire and the stitches removed on the tenth day.

The one exception to the above described procedure was the clearing and incising of the planter and volar surfaces of the feet. In these instances, the feet were not clipped prior to depilation. The incisions were approximately $\frac{1}{2}$ inch long and were made vertically over the deep digital flexor tendons. These incisions were not sutured, but allowed to heal as open wounds.

This trial was divided into 3 testing periods, with 10 day intervals. In the first period, the plantar and volar surfaces of the feet were depilated, incised, and allowed to heal. Ten days later, the ventral abdominal and the thoracic walls were used for the second testing period. The lateral abdominal walls and the lateral surface of the legs were used for the third and final testing period.

Experimental Trial Number 6

Regrowth of hair following depilation had been noted throughout this study but it was considered necessary to observe the rate of growth to complete recovery with hair without the many variables in previous trials, such as different exposure times, surgical intervention, and repeated applications.

¹"Phisohex"; Wintrop Laboratories, New York, N. Y.

Twelve female adult cats were used in this trial (Table 1). Six were used in the spring and summer and 6 in the fall and winter, thus giving seasonal hair coat variations.

The hair on the sides of each cat was shortened with a Number 10 Oster blade, then depilated, using a constant 10 minute contact time at 7 day intervals. The area depilated and procedure corresponded to area explained on Plate II.

Regrowth of hair was checked daily, noting the day on which complete recovery was accomplished. For clarity, "recovery" in this study is defined as that time when the depilated area could no longer be differentiated from the surrounding area.

The data gained from this controlled study was compared and correlated with the results of previous trials to see if the same growth rate occurred. By utilizing different colors, ages, lengths of hair, and different seasons, an attempt was made to duplicate all conditions encountered in previous trials.

Experimental Trial Number 7

This trial included 7 cats which were used to examine advisability of using the depilatory over and around freshly made wounds, over abscessed areas tender to the touch and extremely painful if any pressure was applied, and around and over wounds of several days' duration giving indication that an infection was or had been present.

Four experimental wounds were made on 4 separate cats to study the most feasible method of using the depilatory to clear the edges and the immediate area surrounding fresh wounds. Sodium pentobarbital was given intravenously to effect, and without any further preparations a 3 inch incision was made on the lateral abdominal wall. The skin was loosened and separated from the

underlying tissue by blunt dissection until a flap of skin was apparent. The area beneath the skin was then packed with a sterile gauze sponge and the edges pulled in apposition with stay sutures placed an inch apart. At this time, a scissor was used to shorten the hair over the wound. The depilatory was then applied liberally upon and around the edges of the incision and allowed to remain on the area for 10 minutes. The depilatory and hair were then removed by flushing the area with warm water and wiping with a gauze sponge; the sterile gauze sponge was then removed and the site flushed with sterile saline. The incision was sutured with Number 36 stainless steel wire and allowed to heal for 10 days, at which time the sutures were removed. The cats were under very close scrutiny following arousal from the anesthetic. This step was taken to check any indication of discomfort. Excessive chewing, licking, or scratching post surgically was considered post application discomfort. With the sterile gauze pack omitted, this same procedure was repeated two more times using two different cats.

During this study period, 2 cats with old wounds around the head and neck were received. The age of the wounds was not determined, but at the time of arrival an active infection was present and the areas were heavily scabbed and matted with hair. Prior to any other cleaning, the depilatory was applied to the matted area and wound edge and allowed to remain on for 10 minutes, making sure that all hair was in contact with depilatory before starting the timing. The debris, depilatory, and hair were removed by rinsing under warm water and wiping with a sponge until the area was cleared and then dried. These areas were then flushed with sterile saline and allowed to heal as open wounds. This trial was used to determine the usefulness of the depilatory in a situation that is so often encountered in veterinary medical practice.

Two cats were received with paranal abscesses. In these cases, the

depilatory was applied to the area without clipping or shortening of the hair. It was left on the area for 10 minutes, again starting the timing after the entire area was exposed to the depilatory, and removed with a gauze sponge while flushing the area with water.

Along with judging hair removal efficiency, this trial was made to see if the cats would resist the manner of application and removal of the depilatory.

Experimental Trial Number 8

This trial was a long-term endeavor, using the cats from previous trials, that had demonstrated any type of side reactions, to determine post application effects which might occur to the skin and hair within a six-month waiting period. The effects looked for were change in hair texture, color, length, and density. Also, the skin was inspected at weekly intervals to see if any type of dermatitis appeared on or around any of the areas of depilation.

Part II

After a variety of techniques of application, time of exposure and removal had been tried, evaluated and rated in Part I, Part II was begun. In this Part, the depilatory was applied and evaluated for neatness, efficiency of hair removal, and sensitivity on four other species of animals and 46 additional cats.

If any local irritation occurred, skin sections were taken to be studied microscopically.

In every instance, except on the cats, the depilatory was applied with the finger without any previous shortening of the hair with a clipper or scissor, allowed to remain on the skin for 10 minutes, and removed with a gauze sponge or sponge while running warm water over the areas.

REVIEW OF LITERATURE

There was a very limited amount of literature available concerning chemical depilation and its use in preparing surgical patients. The literature available was most often from the field of human medicine. This literature review is intended to show the historic use of chemical depilation and its present use in both human and veterinary medicine. The most commonly used depilatories covered in this review are the sulphides and the thioglycollates and the transition from their intended use in the cosmetic field to the fields of surgery and medicine.

Just (28) in his review reported that chemical removal of hair has been known and practiced since ancient times. Methods were described showing that the primitives used mineral, vegetable, or animal matter in ointment and paste form to remove hair or prevent its regrowth. Singeing also was practiced, but not to the extent as was the abovementioned concoctions.

Ebell (6) lists in *The Papyrus Ebers*, a rich source of antique medical recipes and arts, items such as "burnt leaf of lotus in oil," "shell of tortoise with the fat of hippopotamus," and "the blood of oxen and goats mixed with malchite" to remove hair from the body.

Chaplet (3), Downing (4), and Friedman (9) disclosed that many authoritative religious orders, due to social customs among the civilizations of the Mediterranean and Orient between 2400 and 3000 B.C., subscribed to the removal of body hair. Methods of hair removal were not revealed for this period of history.

Piesse (18) and Volk and Winter (27) wrote of an early and well-known depilatory, *Rhusma Turcoctum*, a mixture of orpiment (a natural arsenic trisulphide), quick lime, and starch in paste form with water, which was used

extensively by Oriental harem women and is used today by certain African tribes.

Prigot and Froix (22) were of the belief that the main obstacle to the development of a safe chemical for depilation is the similar character of hair and skin in that both contain keratin and are subject to attack by the same chemical agents in approximately the same degree.

Moore and Koppenhoefer (17) and Janistyne (14) described how metallic sulfides were used for cosmetic depilation for a long time but that they had a bad or objectionable odor, were unreliable in their action, and had a high incidence of local irritation and systemic toxicity.

Gillespie (11) studied the depilatory activity of various chemical compounds, and stated that the metallic sulphides act on hair in the following manner: keratin is lysed with a reduction of the -S-S bonds and then by splitting of the keratin bundles by absorption of water.

Pitesky and East (19) described the hair of the cat as being "soft and luxuriant with the ability to quickly clog mechanical clippers." Shaving was described as being "slow and traumatic." Since cats are very popular as laboratory animals, there appeared a need for a better and a faster means of removing the hair, such as a chemical depilatory. With these shortcomings in mind, barium sulphide was tried and mixed with detergents such as Dreft, Tide, and Swirl. This mixture was applied not only to cats but also was investigated on dogs, monkeys, and mice. The results were very encouraging, showing very little irritation, and no delay in wound-healing when used prior to surgery.

Borum (2) observed the effects of barium sulphide on laboratory mice, and found that it increased hair growth, especially the darker hair, and caused considerable local irritation.

Flesch and Rothman (8) had found from previous investigations that various irritants influenced a new cycle of hair growth on mice. The irritants studied and evaluated were ultraviolet light, rubbing of the skin, and plucking of the hair.

Kim et al. (15) reported the use of barium sulphide for the preparation of human surgical patients. It was mixed with starch, zinc oxide, and powdered soap. Before each use, it was made into a paste-consistency with water and applied directly to the skin, using a tongue depressor, and removed by rinsing the area with water. Barium sulphide was also mixed with 10% glycerin and water and successfully used to prepare skin for autografting.

Stoves (24), Stoves (25), and Rosenthal and Oster (23) all mentioned the fact that as the thioglycollates were introduced into the depilatory field a reliable, relatively safe, and non-toxic chemical depilatory became available. Investigations with these preparations disclosed properties that suggested their use for preoperative hair removal in surgical practice.

Vestal (26) and his associates used a chemical depilatory as early as 1952, so this aspect is not new in the medical field. The preparation used was a thioglycollate, the proprietary name of which was not mentioned. His report represented experimentation with 460 human patients, and was used on surgery of traumatic wounds. In extensive wounds, the area was packed with sterile gauze and the skin covered with the depilatory cream, applied with a tongue depressor, and removed by wiping off with a wet sponge, which removed all the hair and cleared the area of all foreign material and detritus as well. Postoperative observation revealed no hair-follicle plugging, ingrown hair, or papule formation.

Fruton and Clark (10) and Mercer (16) described the action of the thioglycollates as a disintegration of hair by chemically rupturing the

-S-S linkage, converting the cystine in keratin to cysteine.

Dreyer (5) outlined the complete reaction of the thioglycollates in the following manner: calcium thioglycollate, in particular, specifically attacked the keratin of hair fiber and broke it down into its respective amino acids; calcium thioglycollate is water soluble, and because of this physical chemical property its action could be halted almost immediately with water at 50°C. Calcium thioglycollate would completely destroy hair fiber if left in contact for several hours. The intricate action of calcium thioglycollate was the dissolving of scleroproteins. The so-called intercellular cement was attacked first, with the result that fibers in the initial stages of breakdown could be separated into their constituent elements by light pressure. In the early stages, the cuticle blistered before separating into fragments which still showed the boundary markings of the scales. Even when the cuticle was still intact, the effect of the depilatory in the cortical cells could be observed through it. When the affected hairs were mounted in water and subjected to pressure under a coverslip, the cortical cells tended to divide and the medulla disintegrated or broke down into medullary discs. Hair from the body of the bulldog and tail of a horse were most resistant, whereas wool and the hair fibers from collies were broken down much faster.

In 1960, Irwin (13) evaluated thioglycollates on domestic animals as an adjunct to surgery. The product employed was another proprietary compound which was initially made for use in the cosmetic field. In the reported findings, it was found to cause some irritation when applied to the scrotum of dogs and cats. When applied to cats, bristle (primary-guard) hairs were hard to remove. It was recommended that cats should not be exposed to this preparation until a 1 hour patch test for sensitivity could be run. The skin of Friesen-Holstein calves reacted violently to this product, chiefly

on the non-pigmented areas. Microscopically, there was a tendency for local pustules formation, with disintegration of epithelial tissue, engorged capillaries, edema, and perivascular cuffing.

Prigot et al. (21) in 1962 reported his findings on a proprietary compound, Surgex,¹ containing calcium thioglycollate and specifically compounded for use in human medicine. This report evaluated 515 human patients. The surgical procedures necessitated depilation of all regions of the body. The superiority of the cream over shaving was established in 470 of the 526 applications. Hair was removed from body crevices, inflamed or sensitive areas, and around lacerations with rapidity and without discomfort. In plastic surgery and autografts of the skin, there was no interference with the "take" of the graft. A low order of allergenicity was found in 100 patients. Side reactions were reported in only 37 of 526 applications.

Price (20) in making suggestions for improvements in veterinary surgery, indicated that an effective, economical preparation for chemical depilation of surgical sites has long been sought.

Anony (1) and Finerty et al. (7) both in recent years have tried to evaluate several compounds with no sound recommendations.

Greenstein (12) in 1964 used the same product that Prigot et al. used in 1962 on human patients; in this instance, an attempt was made to evaluate its practicability when used on veterinary patients. He stated that it was chemically self-limiting and that the hair was removed to the base of the follicle. This depilatory was tried on orthopedic surgery, surgery of the face and eye, and ear surgery. No allergenic reactions were reported, but he still advised a patch test for patients, especially cats, with histories of allergies. The

¹"Surgex"; Crookes Barnes Laboratories, Inc., Wayne, N. J., U. S. A.

animals included in this study were dog, cat, rat, mouse, rabbit, monkey, and a cow. The number of each was not stated.

RESULTS

Experimental Trial Number 1

It became very apparent, after the first 128 applications, that the lotion form had more desirable features than the cream: The lotion spread with greater ease, was relatively easy to control and maintain within a pre-determined perimeter, and required a significantly less amount to cover the areas. It required approximately 4 ounces of lotion or 1 cc for each site, as compared to 7 ounces of cream for this experimental trial. In determining the most suitable method of application of the two forms of Neet, lotion and cream, it was decided that the prime factor would be their respective effectiveness in hair removal. Other points considered were ease of application, neatness of area following depilation, and time consumed to sufficiently cover an area. Spreading or distributing the depilatory with the finger was far superior to any mechanical means tried. It was noted that after repeated exposure the fingernails became soft. This was remedied by wearing a finger cot. With this method, a minimal amount of time was required to expose an area to the depilatory and following removal the area was outlined more distinctly, indicating better exposure of the hair to the depilatory with resulting greater efficiency of hair removal. In all instances, the cream form of Neet was more difficult to spread and consumed more time to sufficiently expose the hair, and the hair-removing efficiency was far below that of the lotion even though both forms were supposed to have the same percentage of calcium thioglycollate. Other means of application tried were

unsatisfactory and were not used in the remaining experimental trials. The tongue depressor was too large and cumbersome to work on the small testing sites; the roll-on applicator bottle did not dispense a sufficient amount of the depilatory; and the nylon artist brush was found to be too pliable to work the depilatory into the hair for sufficient exposure.

The 2 minute contact time was never adequate to remove hair without undue pulling or scraping of the mass with some mechanical device such as the fingernail, a tongue depressor, or a dry sponge. Even following these drastic measures, the areas were unclean and many patches of hair remained and received a poor rating. The 5 minute contact time with the lotion form of Neet was ample to remove the hair from all areas except on cats with a coarse hair coat. The cream form did not remove hair effectively in 5 minutes, regardless of hair coat or texture. Thus far, 10 and 15 minute applications of lotion or cream removed all secondary and most of the primary hair from all areas, although some primary hair stubble could be distinguished on sites where the hair was dense and coarse such as the thoracic wall and back. The 15 minute contact time was actually superfluous since it accomplished the same result as the 10 minute exposure.

At this time, it was also noted that both forms of the depilatory were removed with about the same ease but the most effective method was to flush off the mass of depilatory and hair with warm water and at the same time wipe over the area lightly with a gauze sponge. Since the mass always became slick and slimy, the roughened surface of the gauze sponge greatly facilitated the removal. This method also eliminated the possibility of irritating or damaging the skin by scraping with a tongue depressor or rubbing with a dry sponge. In this connection, it was also noted that water halted the action of Neet almost

immediately and was another safeguard for possible irritation from depilatory residues.

Experimental Trial Number 2

All areas were sharply outlined, signifying a high degree of effectiveness but again, as in Experimental Trial Number 1, the 5 minute exposure was not sufficient to remove all hair. The secondary hair was removed, but much primary hair and many guard hairs remained on dense areas. This was especially noticeable on cats with short-coarse hair.

The 10 minute application time removed enough hair to be rated as excellent, regardless of hair coat, texture, or length. The hair from the ears was removed easily and effectively with either exposure time. All additional areas tested in this trial also indicated that 5 minute exposure was not sufficient to effectively remove all hair.

Experimental Trial Number 3

All 10 minute exposure periods, regardless of area or hair coat, were rated excellent. When evaluating and rating the 5 minute exposure periods, 50 out of the 268 applications received a fair rating. The greatest difficulty was in removing hair from cats with short, coarse, dense hair. The depilatory cleared the sites of all secondary "wool" hair with both time periods, but was unable to completely remove all the guard hair.

Experimental Trial Number 4

Close observation of all areas after 755 applications revealed 4 major side-reactions. These include erythema, inflammation of the subcutaneous

tissue, inflammatory exudate, and physical discomforts (which include shaking of head and pruritus). It appeared that the feet, ears, and scrotum might have a greater susceptibility to the depilatory than other areas of the body, even though other areas of the body were involved (Table 4).

No acute reactions were noted when the depilatory was left on the skin and hair of the body wall for all the contact times included in this experiment. Cat number 4-1 exhibited erythema of the skin of feet and the rib cage, physical discomfort indicated by shaking of the head when the depilatory was in contact with the ears and ear canal indicating that this particular cat might be allergic to this compound. All of the above mentioned reactions were transitory and very slight. There was no licking, biting, or scratching, and within 15 minutes the redness disappeared from the feet and rib cage. The cat exhibited discomfort only as long as the depilatory was in or on the ears, and as soon as the depilatory was washed out and the ear canal was allowed to air dry, the head shaking ceased and the cat exhibited no further annoyance. The ears showed no redness or tenderness following removal of the depilatory.

Microscopic sections of skin from the rib cage were collected and studied with no pathology noted. The incisions made while collecting the skin sections were sutured, and all healed without any incidence. None of the kittens in this experimental trial exhibited undue sensitivity to any of the contact times.

Experimental Trial Number 5

All skin incisions healed without incidence except on two occasions when the incision site was found open on the night of the second day and several sutures were missing. These incisions were re-sutured and healed without undue delay. Regarding the effect of the depilatory on wound-healing, the

advantages and disadvantages of clipping and depilation compared favorably. It was noted that the area immediately surrounding each suture was always slower to re-cover with hair. The area which was depilated was always smooth and clean and apposition of the skin was made easy.

Experimental Trial Number 6

A very definite pattern was developing for return of hair following depilation depending on hair type and age of the cats.

There was a complete recovery of hair in 8 to 10 days on cats with fine hair, 12 to 20 days on cats with coarse hair, and kittens 7 to 8 days. The majority of cats were depilated in the spring months, during the natural shedding season. The fine hair was associated with long-hair breeds of cats, and the coarse hair was found on tabbies or short-hair cats. There were more primary hairs on tabbies than on long-hair cats. Primary hair was always slower to return to an area; on the average, it took about two days for the guard hair to indicate any regrowth. Hair removed during the fall and winter months returned to a complete re-cover approximately 3 days sooner than hair removed in the spring. Kittens demonstrated a shorter recovery period than the adults, regardless of season, hair, coat, or length.

Experimental Trial Number 7

When the depilatory was applied to and around the immediate edge of open wounds, packed first with a sterile dry sponge, and held in place with stay sutures, it caused no physical distress or discomfort to the cats. The hair was removed effectively, leaving the area free of hair, debris, and detritus. When the procedure was repeated, omitting the gauze sponge pack,

cats number 7-3 and 7-4 exhibited irritation by uneasiness and annoyance and by constantly licking the surgical sites. The exposure of the subcutaneous tissue to the depilatory was the probable cause of this irritation. Twelve hours post surgically, the signs of physical discomfort were no longer observed but the areas by then had become inflamed and edematous and subsequently healed about 48 hours slower than the areas which were protected from the depilatory and packed with the sponge.

When the depilatory was rubbed into and around open wounds which were dirty, heavily scabbed, and with an active infection present, the depilatory cleaned up these sites very satisfactorily. The removal technique was supplemented by using sterile isotonic saline as the rinsing agent. The wounds appeared to heal faster than normally, and the cats made no attempt to scratch the wound during exposure to or following removal of the depilatory.

The cats with the painful paranal abscesses did not resist the application, or exposure period, or handling, but opposed the removal very vehemently. The reason for this resistance cannot be explained except that the depilatory might have gained entrance to subcutaneous tissues.

Experimental Trial Number 8

No long-term post application effects were noted throughout this trial. The areas of depilation could not be detected by looking at the hair or the skin. There was no change in hair color, texture, length, or relative quantity. The skin showed no excessive dryness, moistness, or thickening.

Summation of Side-Reactions

All side-reactions were noted and followed as long as the cats involved

were used for experimentation. If any side-reaction occurred, it was allowed to heal or return to normal without any medication. Type of side-reactions, number of times each occurred, and area involved were tabulated on Table 3 under the following headings: erythema, inflammatory exudate, inflammation of the subcutaneous tissue, and physical discomfort (which includes pruritus and head shaking).

There were 5 instances of transitory erythema and all occurred on cat number 4-1; three of these were seen on the lateral thoracic wall when the depilatory was in contact for 30, 45, and 60 minutes respectively, and twice on the dorsal surface of the feet when the lotion was left on for 15 and 30 minutes. This skin redness disappeared within 15 minutes after removal of the depilatory and caused no damage to the areas involved.

Inflammatory exudate appeared on both feet of cat number 1-2 24 hours after the depilatory was applied and allowed in contact for 15 minutes. The scrotum of cat number 3-4 appeared dry 48 hours after removal of the depilatory. The lotion in this instance was left on for 10 minutes. All 3 instances of inflammatory exudate cleared up with no discernible discomfort to either cat.

Inflammation of the subcutaneous tissue was demonstrated on cats number 7-3 and 7-4 when the depilatory was allowed to come in contact with this tissue. The incision healed at a slower than normal rate but caused no detrimental aftereffects or discomfort to the cats. Both of these occurrences followed a 10 minute exposure to the lotion.

There were 5 instances of what was considered as outward physical discomfort. Ten minute contact times of the lotion to the shoulder of cat number 3-2, to the feet of cat number 3-5, and to the hip of cat number 3-4 all

showed signs of pruritus exhibited by intense scratching. Cat number 4-1 shook its head continuously while the lotion was left in the ear canals for 15 and 30 minute periods. The head shaking stopped as soon as the lotion was washed out.

Summary of Hair Removal Efficiency

This study also included a complete tabulation of the efficiency of hair removing ability, rated as excellent, fair, or poor. This appraisal included the area to which depilatory was applied, number of applications to each of these areas, and the total rating (Table 4). The rating of excellent was given all 10 minute exposures using either the lotion or cream, 5 minute exposures using lotion on cats with fine hair, and all applications for longer periods than 10 minutes. Fair ratings included 5 minute exposures of lotion on cats with coarse hair and 5 minute exposures of cream on short and long hair cats. The rating of poor was given to all 2 minute applications.

Part II

After completion of Part I, 80 additional applications were made on four different species of animals. Forty-six of this total were on cats presented for clinical treatment.

Seventy-six of the total received an excellent efficiency rating, leaving the skin smooth and free of hair and debris. There were four poor ratings (Table 5), all four occurring on a horse when the depilatory was applied on the extensor surface of the knee and pastern joint.

One Holstein cow very obviously reacted locally to the depilatory as it was being removed. It became obvious that some of the pigmented layer of the

epithelium was injured and being exfoliated. Fifteen minutes after removal of the chemical, the skin became moist and oozed tissue fluid and the area was warmer to the touch than the surrounding area. The following day, 24 hours following depilation, there was an accumulation of dehydrated exudate. The skin also appeared very much thickened on these areas. Specimens for microscopic examination were taken on the first day, immediately following depilation, and again on the third day as the dryness and scaliness were disappearing. On the fourth day the area appeared normal, hair was beginning to return, and the incisions were healing without interference. The hair was all returning by the ninth day, and by the twelfth day the area was considered recovered. The sutures were removed on the twelfth day, and the wounds were all healed with good apposition.

The depilatory applied to the ears of dogs left them clean, bright, and free of odor. No irritation resulted, nor was there any physical discomfort exhibited by the dogs.

DISCUSSION

Since Meel was available in a lotion and a cream form it was considered of major importance to find out which one would work the best. Several investigators had used the cream forms of depilatories but none had used the lotion.

Greenstein (12) and Irwin (13) both used a cream form with favorable results but it was noted that both prepared the area of depilation by first clipping it with a Number 40 Oster blade (surgical blade), which might have been the reason for such good results being reported. Clipping with a surgical blade followed by further depilation was actually wasted effort. The difficulties encountered when clipping an area was one of the main reasons

for trying a chemical depilatory. In modern veterinary surgery it is an accepted procedure to prepare an area by using a so-called "surgical blade" without any further shortening or hair removal methods.

In this study the hair was initially shortened with Number 10 Oster blades which were faster, did not clog up as easily, and were less expensive than Number 40 Oster blades. Following clipping, the depilatory was applied to the remaining hair and skin. Under these conditions, the lotion form of the depilatory Neet was more advantageous than the cream form. The lotion spread with greater ease because it was in a more liquid state and apparently had greater hair wetting ability. The lotion form, therefore, did not require as much time or effort to cover an area and there was greater control over the depilatory. In other words, in order to secure the same or equal results from the cream and remove the hair as well as the lotion, it had first to be converted to a lotion consistency by pressure, friction, and skin temperature. This study indicated that the lotion form was the more effective of the two forms when a Number 10 Oster blade was used to shorten the hair. Either form performed satisfactorily if a Number 40 Oster blade was chosen.

Irwin (13), Prigot et al. (21), and Greenstein (12) all suggested the best method of applying the depilatory was with a tongue depressor. This again might be true when using the cream form of a depilatory. In this investigation, however, it was found that the cream was difficult to spread evenly with a tongue depressor, especially on small areas. The areas in this study were small and this fact may have contributed to the difficulty. In using this instrument it was difficult to tell how much pressure was being exerted, thus increasing the danger of damage to the underlying tissue. In all instances it took more depilatory and time to cover similar areas. The

depilatory, whether it was the lotion or cream, was spread with the greatest ease and efficiency when using the finger. With the finger it was possible to control the pressure exerted so as not to damage the tissue. The dexterity of the finger made the application more sure and resulted in neater areas that were sharply outlined. The only disadvantage noted when using this method was that the fingernail became soft after prolonged exposure, but this was remedied by using a finger cot.

To guard against possible air exposure in partly filled containers, the depilatory was kept and dispensed from a 50 cc plastic syringe in order to preserve its hair removing capabilities and efficacy.

It has also been suggested by Prigot *et al.* (21), Prigot and Froix (22), Greenstein (12), and Irwin (13) that the depilatory should be removed with a tongue depressor or dry cotton-tipped applicator. It was found that in order to effectively remove all the depilatory and hair mass with a tongue depressor, the skin became reddened indicating a degree of irritation. The sharp hard edge and rough surface of a tongue depressor could scratch and excoriate the skin enough to possibly cause the irritation not present if a gentler method were used. The simplest, easiest, quickest, and gentlest method found in this study was to rinse off the entire mass of hair, debris, and detritus with a copious amount of warm water. To facilitate removal of the resultant slick slimy mass a gauze sponge was found to be very satisfactory. The gauze sponge supplied the adhering surface needed to grasp the mass and remove it. The flushing off with water also further cleansed the immediate area and removed the inevitable excess left in and around the edge of the area when the depilatory was applied. Dreyer (5) found calcium thioglycollate to be water soluble and readily inactivated by the presence of 50°C water. This is another

safeguard to insure against the possibility of a residue of the depilatory that might cause irritation when trying to remove the depilatory with a tongue depressor or dry cotton-tip applicator stick. The effectiveness of water in inactivation of the depilatory was useful when the depilatory was inadvertently applied to mucous membranes or other sensitive areas. Immediate washing off with warm water quickly inactivated the chemical and no immediate or later discomfort was discerned by the cat.

Prigot and Froix (22), Irwin (13), and Greenstein (12) all agreed that the depilatory should be left on the hair and skin for 10 minutes to attain optimum efficiency of hair removal. This time was also found to be effective in this study, with a few exceptions, when taking all variables into consideration and trying to arrive at one single exposure time for repeated excellence. The 10 minute contact was sufficient except under adverse conditions such as found when attempting to depilate the extensor surface of the carpal joint and the extensor surface of the metacarpal phalangeal articulation on a horse. On these areas, a tremendous number of coarse guard hairs are congregated into swirls and vortexes in the normal hair stream and on these areas 10 minute exposure to the depilatory did not remove the hair and was rated poor for the four attempts made.

The time could be shortened if the depilatory was continuously distributed over the area with a circular motion of the finger. This procedure seemed to expose the hair to new or unused depilatory and made possible a 5 minute contact time on an area where 10 minutes were needed before without this measure.

Five minutes of contact was just as effective as was the 10 minute contact on cats with fine textured hair and kittens. The time necessary to

remove hair appeared to be proportionate to the relative number of primary "guard" hair in the hair coat.

A tuft of hair was exposed to the depilatory on a slide, covered with a coverslip, and observed under a microscope. The secondary hair began to kink and curl within 30 seconds, broke into fragments within 2 minutes, and were completely disintegrated within 3 minutes. The primary hair in the same tuft of hair did not curl until 1 minute had elapsed, vacuoles appeared in the hair shaft (medulla) within 3 minutes, and it began to break into fragments but was not completely disintegrated until 6 minutes had elapsed. The potential effectiveness of depilation could be based upon the quantity of primary hair on the area concerned. This was very explicitly illustrated on fine hair cats where the most difficult areas to depilate were over the back where the greatest number of guard hairs exist. Even when these considerations were taken into account, the most difficult hair could still be removed with a second application of the same time duration, a longer initial contact time, or by continuously distributing the depilatory over the area. In Experimental Trial Number 4 where cats were exposed to several different contact times ranging from 15 to 60 minutes, it was noted that on none of the areas did even as much as stubble remain. Greenstein (12) claimed that the depilatory actually removed the hair to the base of the follicle without destroying the follicle. This was never verified in this study.

Skin sensitivity tests for this chemical was not deemed necessary even though this material had been incriminated in several allergic responses by previous investigators. Prigot et al. (21), Irwin (13), and Greenstein (12) even went so far as to say that all suspected patients with history of previous allergenic responses should be patch tested by applying a small amount

of the depilatory and allowing it to remain on the skin for at least one hour. Irwin (13) even stated that a depilatory containing calcium thioglycollate should not be used on cats. From the evidence of this study, after 875 applications on 41 different cats, there appears very little logic in his conclusions. Air reduces the activity of this chemical, and if a small amount were left on the skin for 1 hour, it would only dry and the cat could shake it off with normal exercise. In veterinary surgery the areas most often needed to be cleared of hair for surgery are small, and when exposed to the depilatory for 10 minutes, instead of an hour as suggested for a sensitivity test, this would suffice for both a sensitivity test and depilation making the area ready for surgery if no response occurred. Only 15 side-reactions were observed out of the total of 875 applications. Six of which occurred with 10 minute exposure and nine with more than 10 minutes. All reactions were mild, transitory, and caused no undue or noticeable aftereffects for up to 6 months following the reaction. Some patients were more sensitive than others. Occasionally it was the same cat that reacted, time after time. One violent local reaction occurred when the depilatory was applied to a Holstein cow. Irwin (13) also noted such an experience when he applied another calcium thioglycollate depilatory. Irwin (13) stated that in his observation it was the non-pigmented area which reacted most, but in this present study both pigmented and non-pigmented areas reacted equally (Plate IV). Even though a reaction did occur, the incisions made when collecting skin samples immediately following removal of the depilatory and three days hence healed without incidence and normal hair returned without any complications. But from the above experience it is recommended that this depilatory containing calcium thioglycollate should not be used on the Holstein breed.

When the depilatory was used to prepare sites for surgery, it was observed to free the areas of debris and hair and to leave the surface clean and smooth without cuts and nicks of the skin so often seen on clipped or shaved areas. All incisions healed without delay. Areas normally difficult (or inaccessible) to clip, especially the feet (Plate III), were cleared of hair and presented an area that could be made surgically ready without hair interference as would be true had the same area been clipped. The time involved was minimal when considering the hair removing excellence. The depilatory cleaned the edges of open wounds with ease but did cause some irritation when allowed to contact the subcutaneous tissue. It was therefore found hair removal was facilitated if the edges of an open wound were held in apposition with several stay sutures and the subcutaneous tissue protected with a gauze pack; this prevented its possible exposure to hydrogen sulfide, an inherent product produced by the depilatory when exposed to air and an agent which is a known tissue irritant possibly the cause of the irritation to the subcutaneous tissue. Another factor for this irritation might be due to the high alkalinity of this solution. The pH of this depilatory was 11.5 to 12.5.

The depilatory was also applied on and in the ears of cats and dogs. It was applied and worked into the area with the finger or with a cotton-tipped applicator if the canal was too small for the insertion of a finger. The depilatory and hair were always flushed out with a copious amount of water and then allowed to air dry. In all cases it did an excellent job, and surprisingly enough even reduced some of the odor associated with otitis externa. The animals resisted the removal more than they did the application especially if the water was cool and flushed too rapidly. Old wounds were also cleaned and cleared of hair, dirt, and other debris and there was some indication

that it might expedite healing.

After observing numerous applications the regrowth of hair on an area which was depilated could be forecast with a relative degree of accuracy. Cats with fine textured hair were completely and evenly re-covered in 8 to 10 days, 12 to 20 days for cats with coarse hair, and kittens re-covered in 7 to 8 days. The later days in each group was found when cats were depilated in the spring months which is the normal shedding season. The smaller numbers indicated the cats depilated during the fall and winter months. Many times the hair returned more luxuriant and denser than the hair immediately surrounding the depilated areas. Regrowth hair was again very decidedly linked with the season, and also the quantity of primary hair was a factor. Kittens were hard to forecast because the hair was always fine to the touch and the guard hair were not as thick or predominant.

SUMMARY

It was found that to attain the highest degree of excellence for removing hair with Neet, the hair was initially clipped with the hair stream using a Number 10 Oster clipper blade. The lotion was then applied and spread in a circular motion with the finger to evenly distribute and expose the hair. The depilatory was allowed to remain in contact with the hair and skin for 10 minutes and then removed by thoroughly flushing off the mass of hair and depilatory under warm running water. Other time periods were acceptable and did effectively remove the hair if the animal or case was well chosen. For example, 5 minutes effectively removed the hair from kittens and adult cats with fine textured hair, while an exposure time of 10 minutes would not effectively remove hair from a horse where vortexes and swirls occurred as on the extensor surface of the carpus.

In Part I of this study, of a total of 875 applications, only 15 reactions were noted which were considered due to the depilatory. These reactions were considered mild and transitory and included erythema, pruritus, inflammatory exudate, inflammation of the subcutaneous tissues, and shaking of the head when the depilatory was in the ear canal. No undue aftereffects were noted. In Part II there was one local acute skin reaction involving a Holstein cow. It was suggested that this chemical depilatory should not be used on the Holstein breed of cattle without further investigation.

No sensitivity tests were advised if the area to be cleared was small. It was suggested that it would be better to depilate an area with a short 10 minute exposure than to allow the depilatory to remain on an area for 1 hour as would be suggested if a sensitivity test were run.

The action of this depilatory could be halted immediately with warm water at 50°C.

The depilatory did not interfere with wound healing, unless the depilatory was allowed to come in contact with the underlying subcutaneous tissue and this contact or interference could be prevented by washing immediately with water if suspected. To guard against possible exposure to the subcutaneous tissue, the wounds were packed with a gauze sponge and the wound edges held in apposition with several stay sutures. The clearing of the hair from around open wounds was consistently rated as excellent and the wound was left clear of dirt and other debris, with no damage to the cut edge or skin if the above precautions were taken.

Regrowth of hair after an area was cleared of hair followed a very regular pattern. Areas were completely re-covered with an even growth of hair in 8 to 10 days on cats with fine textured hair, 12 to 20 days for cats with coarse

hair, and on kittens in 7 to 8 days. The longer period of days, in each group, occurred during the spring months, the natural shedding season, and the smaller numbers were noted during the fall and winter months when the coats were heavy and new hair was present. Kittens did not exhibit as much variation as did the adults.

No long-term aftereffects for the skin or hair were noted throughout this study. In fact, the hair over the depilated areas appeared to be more luxuriant than the bordering clipped areas.

Chemical depilation resulted in a field free of hair, cellular debris, and dermal excoriation, and in these respects appeared to be more advantageous and superior than mechanical removal techniques. The depilation was highly effective and did not interfere with the normal process of wound-healing. No systemic toxicity was noted. The transitory reactions were considered mild and of minor consequence. The depilatory was fast-acting, inexpensive, readily available, easy to apply and remove, and did not cause any damage to the hair coats of any animals investigated.

ACKNOWLEDGEMENTS

The author wishes to express his sincere appreciation and thanks to his major instructor, Dr. D. M. Trotter, Professor and Head of the Department of Anatomy, for his guidance, encouragement, and assistance offered, and to Dr. J. E. Mosier, Head of the Department of Surgery and Medicine, for providing most of the experimental animals.

Recognition and gratitude are due Mrs. Verna Burns for her help in preparing the many microscopic slides. Appreciation and thanks to Mr. Phillip Miller, junior in Veterinary Medicine, for his help whenever needed.

LITERATURE CITED

- (1) Anon.
Proprietary Depilatory Agent Proved Effective. *J. A. V. M. A.*, 139,
(Aug. 15, 1961):440.
- (2) Borum, K.
Influence of Clipping and Chemical Epilation on Hair Growth in Mice.
Acta path. et microbiol. Scand., 43(2), (1950):127-40.
- (3) Chaplet, H.
Epilatories. *Parfum Moderne*, 24, (1930):427,709,779,835.
- (4) Downing, J. G.
Cosmetics—Past and Present. *J. Am. M. A.*, 102, (1934):2089.
- (5) Dreyer, J. H.
The Effect of a Calcium Thioglycollate Preparation on Hair Fibre.
J. South African Vet. M. A., 31, (1960):397-403.
- (6) Ebell, B.
The Papyrus Ebers. Levin and Munksgaard, Copenhagen, Denmark, (1937):
63,76,80.
- (7) Finnerty, E. F., Hill, W. R., and Messina, S. J.
Modern Shaving Techniques in Relation to Lesions of the Skin. *G. P.*,
23, (March, 1961):86-93.
- (8) Flesch, P., and Rothman, S.
Physiology and Biochemistry of the Skin. Univ. of Chicago Press,
(1954):18-32.
- (9) Friedman, M.
Zur Geschichte der Entfernung Ungewuenschter Haare. *Dermat.*
Wochenschr., 90, (1930):451.
- (10) Fruton, J. S., and Clark, H. T.
Chemical Reactivity of Cystine and Its Derivatives. *J. Biol. Chem.*,
106, (1934):667.
- (11) Gillespie, J. M.
Studies on the Depilatory Activity of Sodium Sulfide and Some Related
Compounds. *Austral. J. Sci. Res.*, 4, (1951):187-209.
- (12) Greenstein, Edward T.
A Chemical Cream for the Presurgical Removal of Hair on Animals.
J. A. V. M. A., 144, (Aug. 15, 1964):858-63.
- (13) Irwin, D. H. G.
Chemical Depilation in Surgical Practice. *J. South African Vet.*
M. A., 31, (1960):391-95.

- (14) Janistyns, H.
Modern Depilatories. Soap, Perfumery, and Cosmetics, 11, (1938):
419.
- (15) Kim, J. H., Herman, F., and Sulzberger, J. B.
Hair Responses Following Depilation. J. I. D., 38, (1962):351.
- (16) Mercer, E. H.
Some Experiments in the Orientation and Hardening of Keratin in the
Hair Follicle. Acta Biochem. et Biophys., 3, (1949):161.
- (17) Moore, E. K., and Koppenhoefer, R.
The Influence of Various Sulfides on Unhairing With Calcium Hydroxide
Suspensions. J. Am. Leather Chem. Assn., 28, (1933):206.
- (18) Piesse, G.
The Art of Perfumery. 3rd ed. Longmans Green, London. (1892):313.
- (19) Pitesky, I., and Last, J. H.
An Effective Depilatory Formula for Use on Laboratory Animals.
Science, 108, (1948):657.
- (20) Price, D. A.
Wanted—A Veterinary Depilatory. J. A. V. M. A., 139, (Aug. 15,
1961):466.
- (21) Prigot, A., Garnes, A., and Nwagbo, U.
Evaluation of a Chemical Depilatory for Preoperative Preparation of
Five Hundred Fifteen Surgical Patients. Am. J. Surg., 104, (Dec.,
1962):900-06.
- (22) Prigot, A., and Froix, C. J. L.
A Chemical Compound for Hair Removal: Use on Surgical and Obstetrical
Patients. Hospital Topics, 41, (Feb., 1963):103-05.
- (23) Rosenthal, N. A., and Oster, G.
Recent Progress in the Chemistry of Disulfides. J. Soc. Cosmet.
Chem., 5, (1954):286.
- (24) Stoves, J. L.
Histochemical Studies of Keratin Fibres. Proc. Roy. Soc., 623,
(1945):132.
- (25) Stoves, J. L.
The Role of Disulfides and Mercaptans in Hair Chemistry. J. Soc.
Cosmet. Chem., 5, (1954):286.
- (26) Vestal, F. W.
Preoperative Preparation of the Skin with a Depilatory Cream and
Detergent. Am. J. Surg., 83, (1952):398.
- (27) Volk, R., and Winter, F.
Lexikon der Kosmetischen Praxis. J. Springer, Berlin, (1936):107.

- (28) Yust, W.
Depilatories. Encyclopedia Britannica, 14th ed., Chicago, 16,
(1949):33.

[Faint, illegible handwriting]

APPENDIX

Table 1. Part I. Description of the cats used in this study.

Trial No.	Trial and Cat No.	Hair Coat Description				Sex	Age
		Color	Length	Texture			
1	1-1*	black	short hair	coarse	F ¹	A ²	
	1-2	black	short hair	coarse	F	A	
	1-3	black	long hair	fine	F	A	
	1-4	black	long hair	fine	F	A	
2	1-1	black	short hair	coarse	F	A	
	1-2	black	short hair	coarse	F	A	
	1-3	black	long hair	fine	F	A	
	1-4	black	long hair	fine	F	A	
3	3-1	gray	short hair	coarse	F	A	
	3-2	gray	short hair	coarse	M ³	A	
	3-3	gray	long hair	fine	F	A	
	3-4	gray	long hair	fine	M	A	
	3-5	gray	long hair	**	M	K ⁴	
	3-6	gray	long hair	**	M	K	
4	4-1	white	short hair	coarse	F	A	
	4-2	white	short hair	**	F	K	
	4-3	white	short hair	**	F	K	
	4-4	white	short hair	**	F	K	
	4-5	white	short hair	**	M	K	
	4-6	white	short hair	**	M	K	
5	5-1	black	short hair	coarse	F	A	
	5-2	black and gray	tabby	coarse	F	A	
	5-3	orange and yellow	short hair	coarse	F	A	
	5-4	yellow	long hair	fine	F	A	
	5-5	orange and yellow	short hair	coarse	M	A	
	5-6	black and white	short hair	coarse	M	A	
6	6-1s ⁵	white	short hair	coarse	F	A	
	6-2s	calico	short hair	coarse	F	A	
	6-3s	calico	short hair	coarse	F	A	
	6-4s	gray	long hair	fine	F	A	
	6-5s	gray	long hair	fine	F	A	
	6-6s	white	long hair	fine	F	A	
	6-1f ⁶	calico	short hair	coarse	F	A	
	6-2f	black and gray	short hair	coarse	F	A	
	6-3f	calico	short hair	coarse	F	A	
	6-4f	orange and yellow	short hair	coarse	F	A	
	6-5f	orange and yellow	short hair	coarse	F	A	
	6-6f	white	short hair	coarse	F	A	

Table 1 (concl.)

Trial No. :	Trial and Cat No. :	Color	Hair Coat Description : Length :	Texture :	Sex :	Age
7	7-1	calico	short hair	coarse	F	A
	7-2	calico	short hair	coarse	F	A
	7-3	white	short hair	coarse	F	A
	7-4	gray	short hair	coarse	F	A
	7-5	orange and yellow	short hair	coarse	M	A
	7-6	orange and yellow	short hair	coarse	M	A
	7-7	white	long hair	fine	M	A
8	1-2	black	short hair	coarse	F	A
	3-2	gray	short hair	coarse	M	A
	3-4	gray	long hair	fine	M	A
	3-5	gray	long hair	**	M	K
	4-1	white	short hair	coarse	F	A
	7-3	white	short hair	coarse	F	A
	7-4	gray	short hair	coarse	F	A

¹f designates female cat

²A designates adult cat

³M designates male cat

⁴K designates kitten

⁵s designates a cat used in the spring and summer

⁶f designates a cat used in the fall and winter

* 1-1 designates trial number 1, cat number 1

** unable to determine accurately

Table 2. Part I. Summary of areas depilated, number of applications, and relative hair removal efficiency for each experimental trial.

Trial No. :	Areas Depilated :	No. of Applications :		Application Efficiency		
		Excell ¹	Fair ²	Poor ³		
1	lateral thoracic wall	16	16	18	6	8
	lateral abdominal wall	16	16	18	6	8
	ventral abdominal wall	16	16	18	6	8
	back (thoraco, lumbar)	16	16	18	6	8
	Total Trial No. 1	64 ^L	64 ^C	72 ^{d,e,f}	24 ^{b,c}	32 ^a
2	lateral thoracic wall	16		12	4	
	lateral abdominal wall	16		12	4	
	ventral abdominal wall	16		12	4	
	back (thoraco, lumbar)	16		12	4	
	feet (dorsal aspect)	32		16	16	
	ears (auricle, canal)	16		16		
	hip (over trochanter major)	16		12	4	
	stifle (lateral surface)	16		12	4	
	shoulder (dorsal lateral)	16		12	4	
	Total Trial No. 2	160		116 ^{d,h}	44 ^e	
3	lateral thoracic wall	48		40	8	
	lateral abdominal wall	48		40	8	
	ventral abdominal wall	48		40	8	
	back (thoraco, lumbar)	48		40	8	
	feet (dorsal aspect)	24		12	12	
	scrotum & prepuce	4		4		
	shoulder (dorsal, lateral)	12		10	2	
	ears (auricle, canal)	12		12		
	hip (over trochanter major)	12		10	2	
	stifle (lateral surface)	12		10	2	
Total Trial No. 3	268		218 ^{d,h}	50 ^e		
4	lateral thoracic wall	24		24		
	lateral abdominal wall	24		24		
	ventral abdominal wall	24		24		
	back (thoraco, lumbar)	24		24		
	feet (dorsal aspect)	47		47		
	scrotum & prepuce	8		8		
	ears (auricle, canal)	48		48		
Total Trial No. 4	199		199 ^E			

Table 2 (concl.)

Trial No. :	Areas Depilated	No. of Applications :	Application Efficiency		
			Excellent ¹	Fair ²	Poor ³
5	feet (dorsal aspect)	6	6		
	lateral thoracic wall	6	6		
	lateral abdominal wall	6	6		
	ventral abdominal wall	6	6		
	stifle (antero-lateral)	6	6		
Total Trial No. 5		30	30 ^h		
6a ⁴	rt. abd. & thor. wall	6	6		
6f ⁵	rt. abd. & thor. wall	6	6		
Total Trial No. 6		12	12 ^h		
7	lateral abdominal wall	4	4		
	tail-head	2	2		
	neck & head	2	2		
Total Trial No. 7		8	8 ^h		

¹rated excellent when 0 to 2 primary hairs remained per square centimeter and area was left clean and smooth

²rated fair when 2 to 4 primary hairs remained per square centimeter and area was left clean and smooth

³rated poor when 4 or more primary hairs remained per square centimeter

⁴a spring group of cats

⁵f fall group of cats

¹lotion form of Neet

^ccream form of Neet

^a2 minute contact time with the lotion or cream

^b5 minute contact time with the cream on fine hair cats

^e5 minute contact time with the lotion on coarse hair cats

^d5 minute contact time with the lotion on fine hair cats

^e10 minute contact time with lotion and cream

^f15 minute contact time with lotion and cream

^g15, 30, 45, and 60 minute contact times with lotion

^h10 minutes contact time with lotion

Table 3. Part I. Side reactions following the use of a depilatory.

Type of Side Reaction	No. of Occurrences	Area Involved
Erythema	5	3* - lateral thoracic wall 2* - feet (dorsal aspect)
Subcutaneous inflammation	2	2* - lateral abdominal wall
Inflammatory exudate	3	2* - feet (dorsal aspect) 1* - scrotum & prepuce
Physical discomfort**	5	1* - feet (dorsal aspect) ³ 2* - auricle and ear canal ¹ 1* - point of shoulder ² 1* - over trochanter major ³

* indicates number of occurrences on particular area involved

** includes shaking of the head,¹ scratching,² and licking³

Table 4. Part I. Effectiveness of a pre-surgical depilatory lotion.

Areas Applied	Species	No. of Applications	Effectiveness of Depilatory Lotion		
			Excellent	Fair	Poor
lateral thoracic wall	feline	126	100	18	8
lateral abdominal wall	feline	130	104	18	8
ventral abdominal wall	feline	166	140	18	8
back (thoracic, lumbar)	feline	144	118	18	8
feet (dorsal aspect)	feline	115	87	28	
ears (auricle, canal)	feline	76	76		
hip (trochanter major)	feline	34	28	6	
stifle (lateral surface)	feline	28	22	6	
shoulder	feline	28	22	6	
scrotum & prepuce	feline	12	12		
neck & head	feline	2	2		
right abdominal and thoracic wall	feline	12	12		
tail-head	feline	2	2		
Total		875	725*	118**	32***

*1-rated excellent when 0 to 2 primary hairs remained per square centimeter and area was left clean and smooth

2-rated fair when 2 to 4 primary hairs remained per square centimeter and area was left clean and smooth

3-rated poor when 4 or more primary hairs remained per square centimeter

#10 minute applications with lotion or cream, 5 minute applications of lotion on long, fine hair cats and kittens, and all applications' time over 10 minutes in duration

**5 minute applications of lotion on short, coarse hair cats, 5 minute cream on short, coarse hair and long, fine hair cats

***2 minute application time

Table 5. Part II. Clinical evaluation of effectiveness of hair removal and side reactions.

Species	No. of Animals	Area or Surgical Procedure	No. of Applications	Side Reactions	Efficiency	
				Excellent	Fair	Poor
feline	46	ophorohysterectomy	40	-	40	
		onycheotomy	6	-	6	
equine	5	carpus (dorsal surface)	2	-	2	2
		para lumbar fossa	2	-	2	
		stifle (anterior, medial)	2	-	2	
		volar neurectomies	2	-	2	
		volar digital neurectomies	2	-		2
bovine	4	rumenotomy	1	xxx	1	
		shoulder (antero-lateral)	1	xxx	1	
		thoracic wall (tenth rib)	1	xxx	1	
		eye enucleation	1	-	1	
		remove digit	1	-	1	
		fifth rib resection	1	-	1	
canine	6	ears (auricle and canal)	3	-	3	
		caudectomy	3	-	3	
		remove first digits	3	-	3	
porcine	9	gastrostomy	8	-	8	
		inguinal hernia	1	-	1	
Total	70		80	3	76	4

1-rated excellent when 0 to 2 primary hairs remained per square centimeter and area was left clean and smooth

2-rated fair when 2 to 4 primary hairs remained per square centimeter and area was left clean and smooth

3-rated poor when 4 or more primary hairs remained per square centimeter

-indicates no reaction occurred

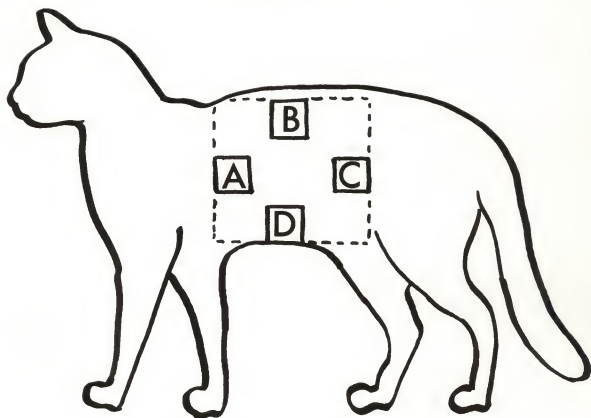
xxxindicates positive reaction and all reactions occurred on same Holstein cow

EXPLANATION OF PLATE I

Broken line indicates area initially shortened before each trial with a Number 10 Oster blade. Areas A, B, C, and D indicates the 3x3 cm areas of depilation.

- A. Lateral thoracic wall.
- B. Back (thoraco-lumbar area).
- C. Lateral abdominal wall.
- D. Ventral abdominal wall.

PLATE I




EXPLANATION OF PLATE II

The rate and evenness of hair regrowth and lines of demarcation between areas of depilation.

- a. Immediately after depilation.
- b. Seven days after depilation.
- c. Fourteen days after depilation.
- d. Fourteen days after initial clipping of areas (a) through (d) with a Number 10 Oster blade.
- e. Arrow indicates line of demarcation between 14-day clipped and 14-day depilated area.

PLATE II

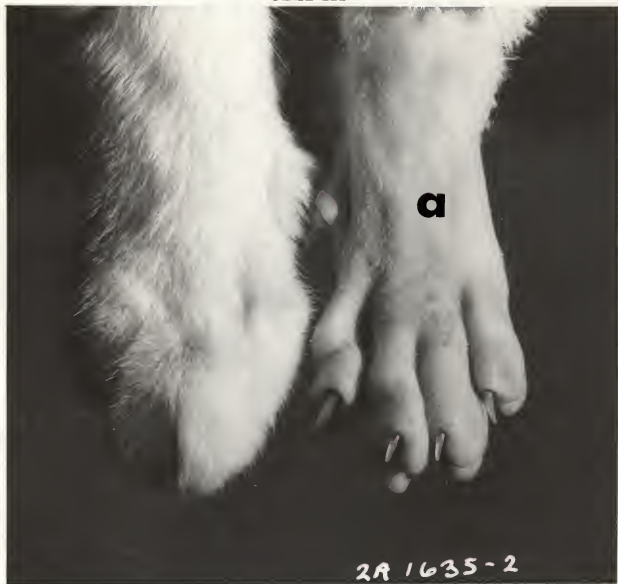

EXPLANATION OF PLATE III

Dorsal aspect of feet; difficult areas to clip or shave.

- a. Hair was removed from foot without any previous shortening of the hair. The depilatory was allowed in contact for 10 minutes before removal.

PLATE III



EXPLANATION OF PLATE IV

Histologic sections of bovine skin. H & E stain. x 150.

Fig. 1 illustrates an underlying acute local inflammatory reaction.

Fig. 2 illustrates superficial inflammatory exudate sloughing from skin surface.

PLATE IV

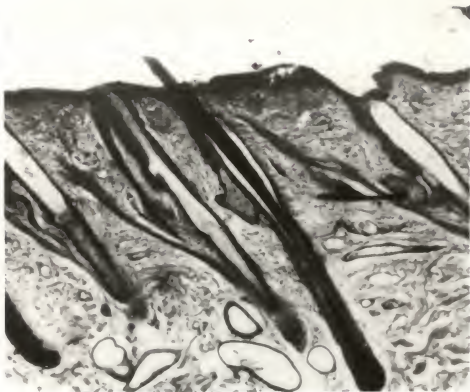


Fig. 1

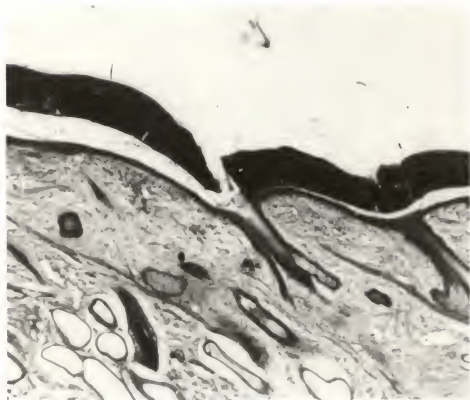


Fig. 2

AN EVALUATION OF A CHEMICAL DEPILATORY FOR PREPARATION
OF VETERINARY SURGICAL PATIENTS

by

GLENN THEODORE HARTKE

B.S., Kansas State University, 1958
D.V.M., Kansas State University, 1960

AN ABSTRACT OF A THESIS

submitted in partial fulfillment of the

requirements for the degree

MASTER OF SCIENCE

Department of Anatomy

KANSAS STATE UNIVERSITY
OF AGRICULTURE AND APPLIED SCIENCE

1965

Approved by:

Major Professor

The chemical depilatory, NEET*, containing calcium thioglycollate as the active ingredient, was evaluated for its feasibility as a hair removal agent for veterinary medical patients.

This study was divided into two parts. In Part I, Neet was applied on 41 cats. In Part II, it was applied to horses, dogs, pigs, cattle, and cats for an additional 70 animals.

The following items were evaluated in Part I of this study: methods of preliminary preparation of the body surface before the application of the depilatory; methods of application for both the lotion and cream forms; a constant and effective contact time; a method of removal of the Neet; hair removal effectiveness; effects to the skin and hair of repeated and prolonged contact time; rate of growth to complete recovery of hair following depilation; the useability of the product around open wounds and over swollen or painful areas; and long term post application effects on the hair and skin.

The areas of the body to which the depilatory was applied represented those areas most often encountered in clinical procedures.

The completion of 288 applications in the first two trials established the technique used in all succeeding trials. The hair was shortened with a number 10 Oster blade. The depilatory was applied directly to the areas from a plastic syringe and spread over the area with the finger tip. Both forms were removed easily by flushing the area with warm tap water while rubbing lightly with a gauze sponge.

At this stage a constant contact time had not been established. Two hundred sixty-eight additional applications utilizing 5 and 10 minute contact times were evaluated. This demonstrated that hair was removed most efficiently

Neet*--Whitehall Laboratories, New York, N.Y.

with the 10 minute contact time. Of the 268 applications 218 were rated excellent and 50 fair. All the fair ratings were within the 5 minute contact time group.

At the completion of Part I, the results in evaluating the 875 tests in terms of hair removal efficiency were excellent in 725 applications, fair in 118, and poor in 32. The variations that contributed to these results were different hair coats, contact times, and form of Nest used.

There were mild transitory local skin reactions observed in 15 of the 875 applications. The reactions observed were erythema, inflammation of the subcutaneous tissue, inflammatory exudate, physical discomfort shown by the shaking of the head, and pruritus.

Complete regrowth of hair after depilation followed a regular sequence. It occurred in 7 to 20 days depending on hair texture and age of the cats.

There were no post application effects noted to either the skin or hair when observed for 6 months following depilation.

Part II was designed to clinically evaluate the techniques and knowledge gained from Part I.

There were a total of 80 applications with depilation efficiency being rated excellent in 76 and poor in 4. The depilatory in all instances was in contact for 10 minutes and all the poor ratings were from the dorsal surface of the carpal joint and metacarpal-phalangeal articulation on the horse.

On one Holstein cow an (acute) local skin reaction occurred. Examined microscopically the skin lesions consisted of inflammatory exudate, cellular infiltration, erythema, edema and complete disruption of the epidermal layers.