

EFFECT OF ESTROGEN AND PROGESTERONE  
ON THE VAGINAL EPITHELIUM OF THE DAIRY COW

by

ADNAN OMRAN DARWASH

B. S., Baghdad University, 1958

---

A MASTER'S THESIS

submitted in partial fulfillment of the

requirements for the degree

MASTER OF SCIENCE

Department of Dairy Science

KANSAS STATE UNIVERSITY  
Manhattan, Kansas

1962

LD  
2668  
T4  
1962  
D37

TABLE OF CONTENTS

C.2  
*Documents*

INTRODUCTION . . . . .	1
REVIEW OF LITERATURE . . . . .	1
MATERIALS AND METHODS . . . . .	7
RESULTS AND DISCUSSION . . . . .	9
Normal Estrous Cycle . . . . .	9
The Effect of Ovariectomy on the Vaginal Epithelium. . .	15
The Effect of Estrogen and Progesterone Administration on the Vaginal Epithelium of Ovariectomized Cows. . .	19
SUMMARY AND CONCLUSION . . . . .	25
ACKNOWLEDGMENT . . . . .	28
LITERATURE CITED . . . . .	29
APPENDIX . . . . .	32

## INTRODUCTION

Cyclic changes in the vaginal epithelium of the bovine have been studied by a number of workers. In all of these investigations tissues were obtained at an abattoir after the animal had been slaughtered, and the findings were correlated with the stage of the reproductive cycle. Such interpretations are subjected to the errors resulting from variations that are evident in the vaginal epithelium of cows that supposedly represent similar stages of the reproductive cycle.

Vaginal smears from live animals are ineffective in showing the exact cellular changes because of the unique characteristics of the bovine vaginal epithelium.

The present study was undertaken to determine what changes occur in the vaginal epithelium of the live animal during the normal estrual cycle, after ovariectomy, and as a result of the administration of varying levels of estrogen and/or progesterone.

Special attention was given to determine the physiological level of estrogenic substances that normally bring a cow into estrus, and the level of progesterone that physiologically antagonizes the influence of estrogens.

## REVIEW OF LITERATURE

The adult bovine vagina is a tubular structure located in the pelvic cavity and is eight to ten inches long and three to four inches in diameter (Trotter and Lumb, 1958). Cole (1930)

referred to the vagina proper as the part between the vestibule and the cervical os. Perkin et al. (1954) measured the vagina proper of 95 parous cows and reported a length of  $6.9 \pm 0.72$  inches. Nibler (1957) reported the total length of the bovine vagina and vestibule as being 12 to 16 inches, and that the size of the vagina varied with the size and age of the animal.

Marion and Gier (1960) reported an average length of 8 to 14 inches and an average width of 2 to 5 inches, based on measurements obtained from 100 cows.

The histology of the bovine vagina has been studied by Trautmann (1957). He described the tissues as follows: (1) the mucosa - submucosa lining the cavity, comprised of a high columnar secretory epithelium in the cranial part, varying from low cuboidal to stratified columnar during metestrus; (2) the tunica muscularis, consisting of a thick inner circular layer and a thin outer longitudinal layer, the latter continued for a short distance into the wall of the uterus; (3) adventitia or cranially a serosa, with muscularis serosa, containing large vessels, nerves, and ganglia.

Concerning epithelial changes, it has been pointed out that the vaginal epithelium in the cow was not uniform throughout the length of the organ. Three areas have been studied: anterior, middle, and posterior (Murphey 1926, Hummon 1932, Cole 1930, Roark and Herman 1950, Mahmoud 1960, Marion and Gier 1960). The anterior portion of the vagina concerns the present study because the most marked changes took place in this region (Cole 1930, Brown 1944, Mahmoud 1960).

The epithelium in the anterior portion during proestrus and estrus was distinctly and characteristically bovine, which differed considerably from the vaginal epithelium of most species. Rather than epithelial cornification and desquamation as is common in most species, (mouse, Allen 1922; sheep, Sanger et al. 1958; human, Traut 1936; guinea pig, Sellar 1922; opossum, Risman 1947; dog, Gier 1960), the superficial vaginal epithelium of the cow was composed of tall columnar, highly active, mucous secreting cells. Below the superficial layer, the epithelium consisted of stratified polyhedral cells which varied with the stage of the estrous cycle (Marion and Gier, 1960).

Cole (1930) reported the epithelium to be composed of four layers of cells, varying from two to eight layers, with the superficial layer containing tall goblet cells during proestrus.

Mahmoud (1960) found that the vaginal epithelium in the anterior portion during the follicular phase, was comprised of a basal layer of polyhedral cells one or two cells thick and a superficial layer of tall, secretory cells, with an average height of 22.7 microns.

Marion and Gier (1960) found that during proestrus and estrus, the height of the epithelium and the number of cell layers was reduced, and the vaginal epithelium became progressively more secretory.

Cole (1930), Brown (1944), and Roark and Herman (1950) reported that the epithelium attained its greatest height at this time due to the enormous increase in height of the individual cells of the superficial layer. Mahmoud (1960) found a reduction

in the height of the epithelium during the follicular phase of the cycle.

Marion and Gier (1960) stated that during prolonged estrogen function, the height of the epithelium was reduced to a single layer of cuboidal cells. During the first day postestrus, Cole (1930), Brown (1944), and Roark and Herman (1950) found that the epithelium still resembles closely that of estrus; however, the superficial layer was reduced in height and the number of basal polyhedral cells of the epithelium had again increased.

At two days postestrus, the same authors reported that the superficial epithelium was reduced still further in height and was changed to cuboidal or polyhedral cells. Brown (1944) and Roark and Herman (1950) reported that the number of layers of the squamous cells reached a maximum at this stage of the cycle. Mahmoud (1960) found that shortly after ovulation the height of the superficial layer of the epithelium and its secretory activity were decreased.

According to Roark and Herman (1950), the superficial epithelial cells three days postestrus varied from low columnar to cuboidal and remained in that condition during diestrus. They also reported a decrease in cell activity and an increase in the stratification of the epithelium. Hansel (1949) found an increase in the percentage of the cornified cells in vaginal smears two and three days postestrus, but did not determine the source of the cells.

Brown (1944) and Roark and Herman (1950) found that during the luteal phase of the estrous cycle, the epithelium varied

from low cuboidal to large polyhedral cells, but they did not see a pattern of function. Mahmoud (1960) found a considerable increase in the number of the basal polyhedral layers. Marion and Gier (1960) reported that from 8 to 18 days postestrus the epithelium had returned to a high, nearly non-secretory condition. Hansel (1949) found the highest percentage of cornified cells in vaginal smears that were taken during the luteal phase.

Marion and Gier (1960) stated that during early pregnancy the epithelium became much thicker, with only a little secretory activity in the anterior half of the vagina. After the second month of gestation, the epithelium became secretory and by the end of the fourth month, and continuing until parturition, the entire vaginal epithelium was secretory, the anterior portion reduced to a single layer of nuclei.

Hummon (1932) stated that the epithelium decreased in thickness by 152 to 263 days gestation, and by the 253rd day, mucous and desquamated cells were seen on the surface of the vaginal epithelium.

Mahmoud (1960) found that the superficial cell layer reached its maximum height at five months gestation and remained high until parturition. He attributed this increase in height to the high level of estrogen secreted by the placenta.

Hansel (1949) found that the vagina of the ovariectomized cow was dry and vaginal smears contained a few cornified cells.

In the opossum, Risman (1947) found that the vaginal canal of castrated animals differed from that of anestrous animals in having a lower vaginal epithelium.

Rosa and Velardo (1959) found that the vaginal epithelium of the ovariectomized rat was reduced from a thickness of 8 to 10 cells to a thickness of four to five cells at ten days post-ovariectomy. An injection of .05 mcg. of 17 Beta estradiol to ovariectomized rats caused a mucification of approximately 50 per cent of the surface area of the vaginae epithalia. A 0.1 mcg. treatment of estradiol was found to cause a higher degree of cornification. Progesterone treatment resulted in no proliferative action.

Treatment with 0.1 mcg. estradiol and 0.05 mg. progesterone caused a more intense cornification than did estrogen alone. However, a level of 0.25 mg. progesterone, with 0.1 mcg. estradiol, could inhibit cornification and cause mucification.

Treatment with 0.5 mg. progesterone, with 0.1 mcg. estradiol, produced a greater mucification of the epithelium, but 4.50 mg. progesterone, in conjunction with 0.10 mcg. estradiol, tended to induce a lesser state of mucification.

Hansel (1949) found that the injection of 0.5 mg. stilbestrol into ovariectomized cows resulted in an increase in the percentage of cornified cells in vaginal smears, however, continuous injections until the onset of estrus resulted in a decrease in the percentage of cornified cells. After a few days, the smears reverted to postovariectomy type. He also reported that the injection of 35 mg. of progesterone daily for six days, after the cows have been brought in estrus, caused a marked increase in the level of the cornified cells, and there was a marked tendency for this level to be maintained. He concluded



that the growth of the epithelium caused a further removal of the superficial cell layers from their blood supply, thereby causing the cornification of the outermost cells.

Hisaw (1937), in his study on the monkey, found that estrogenic compounds could cause proliferation and cornification of the vaginal mucosa and edema of the sexual skin. However, progesterone was found to have little or no effect on the vaginal mucosa, but it did modify the action of estrin when both hormones were given. He also found that 0.5 rabbit unit of progestin daily could partially inhibit a daily dose of 100 rat units of estrin. Clarke (1942) tried 49 different steroid compounds on ovariectomized immature rats. He found that all hormonally active steroids (folliculoid, luteoid, corticoids, testoids) stimulated the vaginal epithelium to undergo stratification, cornification, and mucification, with cornification the common response to estrin derivatives. He concluded that local factors played an important role in determining the type of vaginal response caused by a certain steroid.

Risman (1947) found that injections of 0.8 - 0.9 estradiol to the opossum caused an increase in the number of the vaginal cell layers and an increase in the number of superficial cornified cells. Levels of 3.15 mg. caused greater cornification than lower levels. Progesterone injection alone caused no cornification.

#### MATERIALS AND METHODS

Two Holstein cows, 147C and 85B, with known reproductive

histories, were employed in this study. Vaginal tissues were taken, using a biopsy instrument, (Plate VIII, Fig. 1), during proestrus, estrus, metestrus, and diestrus of the normal cycle. After the vaginal changes, during the normal cycle, had been established, the cows were ovariectomized. Cow 147C was ovariectomized ten hours postovulation and the ovaries were removed from 85B just prior to ovulation. A vaginal biopsy was taken from each cow on the seventh day postovariectomy and at three-day intervals thereafter. Thirty-five days after ovariectomy, 147C received an intramuscular injection of 3 mg. of estradiolcyclopentylpropionate (E.C.P.). Twenty-seven days postovariectomy, 85B received a similar treatment. Vaginal biopsies were taken daily for the first seven days following treatment and then at three-day intervals.

Twenty-five days after treatment with E.C.P., both cows were treated with a single dose of 3 mg. of E.C.P. and with 5 mg. of progesterone daily for seven days.

Vaginal biopsies were taken daily the first seven days following treatment and then at three-day intervals. Fifty days after the last treatment, 147C was treated with 5 mg. of progesterone daily for seven days.

Biopsies were taken from the anterior portion of the vagina approximately two to three inches from the cervical os. The tissues were immediately fixed in ten per cent neutral formalin for 14 to 16 hours and dehydrated in a series of isopropyl alcohol.

The tissues were transferred to a five per cent xylol

solution in alcohol and placed in an oven maintained at 50° C. for 45 to 60 minutes, then paraffin was added to the solution.

Vaporization of alcohol and xylol required 16 to 18 hours in the 50° C. oven. After the preliminary infiltration, the tissues were transferred to a 57° C. oven and infiltration was completed with three changes of 54 to 56° C. paraffin over a 36-hour period. The tissues were then embedded in fresh paraffin, sectioned at eight to ten microns and mounted with Mayers' albumen on glass slides. Some tissue sections of each sample were stained with iron hematoxylin for 13 minutes for nuclear differentiation and three minutes in 0.25 per cent acid fuchsin and .1 per cent orange G. Other sections of the same tissue were stained with periodic acid Schiff (PAS) reagents in an effort to identify glycogen containing mucous droplets.

## RESULTS AND DISCUSSION

### Normal Estrous Cycle

Two days proestrus the epithelium in the anterior portion of the vagina of 147C consisted of a basal layer of polyhedral cells, two to three nuclei thick, and a superficial layer of low cuboidal to low columnar secretory cells. The epithelium height ranged from 19 to 32 microns (Plate I, Fig. 2).

The vaginal epithelium in the anterior portion of the vagina of 85B two days proestrus varied from 40 to 62 microns in height and consisted of two to four layers of polyhedral cells

and a superficial layer of cells ranging from cuboidal to squamous (Plate I, Fig. 1). The vaginal epithelium of both cows showed an increase in secretory activity over the previous day's cycle.

One day proestrus the vaginal epithelium of 147C consisted of basal polyhedral cells, one or two nuclei thick, and large cuboidal to tall columnar secretory superficial cells. The height of the epithelium was slightly lower and varied from 18 to 29 microns. The epithelium of 85B was somewhat higher, ranging from 45 to 65 microns, and contained two to four layers of basal polyhedral cells. Although mucous droplets were evident in the epithelium, secretory activity was not as pronounced as in 147C. The changes observed in the vaginal epithelium of 147C during proestrus are in agreement with those reported by Cole (1930), Mahmoud (1960), and Marion and Gier (1960). However, the vaginal changes occurring in 85B during this period of the cycle indicate the extent of variation between these two cows.

During estrus the vaginal epithelium of 147C was continually reduced as mucous was discharged from the superficial layer. The basal cell layers were reduced to two nuclei thick and the cells of the superficial layer increased in height and secretory activity. Some areas contained one layer of tall columnar cells with a row of round nuclei at the base of the cells (Plate I, Fig. 4).

This condition is similar to that reported by Cole (1930), Roark and Herman (1950), and Marion and Gier (1960). All the cells of the vaginal epithelium during a particular stage of the

estrous cycle are not in an identical stage of activity, since a highly functional epithelium may be apparent in one area while other areas contain a typical nonfunctional epithelium with cuboidal superficial cells. This phenomenon might be attributed to the difference between the cells in response to estrogen or to local factors, as suggested by Clarke (1932).

The total height of the epithelium decreased during high secretory activity. A tall columnar superficial layer was not commonly associated with a highly stratified epithelium. The height of the epithelium ranged from 16 to 32 microns, which varies from the findings of Cole (1930) and Brown (1944), who stated the height of the epithelium increases during estrum in spite of the reduction in the number of the cells. However, it is in agreement with the findings of Mahmoud (1960) and Marion and Gier (1960), who found a decrease in the height of the epithelium during estrum. The vaginal epithelium of 85B during estrus consisted of two or three layers of large basal polyhedral cells and a superficial layer of large secretory cuboidal cells. The height of the epithelium ranged from 50 to 72 microns, and the epithelium was generally more edematous and active than during proestrus, but not as active as in 147C (Plate I, Fig. 3). The condition found in 85B during estrus is in agreement with the work of Mahmoud (1960), who stated that the epithelium during estrum was at least two nuclei thick.

The increase in height of the epithelium during estrum in this cow is in agreement with the reports of Cole (1930) and Brown (1944).

The reason for this increase in height during estrum might be related to the low secretion of mucous that was evident in this cow during estrum, that resulted in a minimal cell loss. This low mucous secretion might be attributed to either a low level of estrogen in the body or to less sensitivity of the vaginal epithelium to the level of estrogen present. The level of estrogen present in 85B was apparently sufficient to stimulate the growth of the cells and the edematous condition of the vaginal epithelium, but not high enough to cause the extrusion of the cell contents. Cow 147C secreted a large amount of mucous during estrus, which resulted in the loss of the epithelial cells. One day postestrum the vaginal epithelium of 147C consisted of two to four layers of basal polyhedral cells and a highly functional superficial layer of columnar cells. The height ranged from 18 to 23 microns. This finding is not in agreement with that reported by Brown (1944) and Roark and Herman (1950), who stated that the height of the superficial layer decreases during this phase of the cycle. It is, however, in agreement with the reported increase in the number of basal polyhedral cells.

From estrum to one day postestrum, 85B showed no change in the height of the superficial vaginal layer. The number of basal polyhedral cells ranged from four to six, and the epithelial height varied from 45 to 70 microns.

Two days postestrum, the vaginal epithelium of 147C had increased in height and varied from 21 to 45 microns. It consisted of two to three layers of enlarged basal polyhedral cells and a

superficial layer of cuboidal to low columnar cells.

The vaginal epithelium of 85B during this stage of the cycle was composed of five to seven layers of polyhedral cells and a secretory superficial cell layer. The height of the epithelium ranged from 60 to 92 microns. This condition is in agreement with the findings of Brown (1944) and Roark and Herman (1950), who stated that the number of squamous cells was at a maximum two days postestrus.

Four days postestrus the vaginal epithelium of 85B consisted of six to eight layers of low polyhedral to squamous cells. The height of the epithelium ranged from 30 to 62 microns. Cornified cells on the superficial layer were present, which is in agreement with Hansel (1949), who reported an increase in the percentage of the cornified cells during the luteal phase of the estrous cycle.

Six days postestrus the vaginal epithelium of 147C ranged in height from 32 to 45 microns and was comprised of two to three layers of low polyhedral cells and a low cuboidal, secretory superficial layer. Eleven days postestrus the vaginal epithelium of 85B consisted of four to six layers of low polyhedral cells with evidence of cornification of some cells of the superficial layer. The height ranged from 45 to 62 microns. This condition is in agreement with the findings of Cole (1930), Brown (1944), and Roark and Herman (1950), that the number of the basal layers reached a maximum two days postestrus and decreased until the next proestrus. However, this condition is not in agreement with the findings of Marion and Gier (1960),

who found that the epithelium increases in height during the period from 8 to 18 days postestrum. The higher epithelium by two days postestrum in cow 85B may be attributed to the presence of a low level of estrogen and a rapid increase in the progesterone level secreted by the corpus luteum. The relative decrease in the height of the epithelium of 85B, 11 to 18 days postestrum, was apparently not due to the loss in the number of the cell layers. This might have been due to the action of progesterone which may have prohibited the secretory activity resulting from estrogen stimulation.

Thirteen days postestrum the vaginal epithelium of 147C was composed of four to seven layers of polyhedral cells and a superficial layer of cornified cells. The epithelium reached a maximum of 42 to 72 microns during this period.

The vaginal epithelium of the two cows during this phase of the cycle was very similar in height and cell numbers (Plate I, Figs. 5 and 6).

These observations are in agreement with the report of Hansel (1949) in regard to the increase in the percentage of cornified cells during this time. They are also in agreement with the findings of Mahmoud (1960) and Marion and Gier (1960), who reported a low activity of the epithelium during the luteal phase of the estrous cycle.

The observations of the vaginal epithelium of 147C are in agreement with the reports of Cole (1930) and Marion and Gier (1960), who reported that the number of polyhedral cells is higher during this time than two days postestrum.



This study is in disagreement with the report of Asdell (1960) in which he concluded that the level of estrogen during this period must be high because of the high percentage of cornified cells recovered by Hansel (1949) and because of the positive alkaline phosphatase reaction shown by the uterine tissue during this time. It is also in disagreement with the report of Trautmann (1957) that the level of estrogen in the cow is not high enough to cause cornification of the vaginal epithelium. This study indicates that vaginal epithelial changes in the bovine differ from those of the rodents, or other animals. A high level of estrogen does not cause a cornification of the vaginal epithelium of the bovine as it does in rodents. The vaginal epithelium was edematous and secretory when higher levels of estrogen were introduced. Cornification of the vaginal epithelial cell in the bovine is due to either the lack of estrogen or to higher levels of progesterone that antagonize the estrogen action.

This study indicates that differences in the hormonal balance of estrogen and progesterone between individuals is a possible cause for the difference found between the two cows. Plate VI, Fig. 1, shows the variation between the two individuals during the normal estrous cycle.

#### The Effect of Ovariectomy on the Vaginal Epithelium

Seven days after ovariectomy, the vaginal epithelium in the anterior portion of the vagina of 147C consisted of three to five layers of polyhedral cells and ranged from 15 to 30 microns

high with one or two layers of cornified cells on the superficial surface. There were small areas of secretory epithelium characterized by one layer of low columnar cells resting on a layer of polyhedral cells (Plate II, Fig. 2). The vaginal epithelium in the anterior portion of 85B was composed of two to three layers of basal polyhedral cells with a superficial layer of squamous to cuboidal secretory cells (Plate II, Fig. 1). The vaginal epithelium in both cows was low in comparison to the same stage of the normal cycle. This study suggests that without progesterone inhibiting the action of estrogen, the epithelial cells will develop secretion, lose their height, and become squamous with pycnotic nuclei after the extrusion of the cells' contents.

This work is not in agreement with the report of Hansel (1949) who suggested that the growth of the epithelium caused by either the presence or withdrawal of estrogen, will result in further pushing of the superficial layer out of its blood supply and cause the cornification of the outermost cells. In this study, it was found that not only the superficial layer showed cornification, but that cornified cells were also apparent in the basal layer. This might be attributed to the low level of estrogen after ovariectomy which cannot maintain a high and edematous epithelium.

Ten days postovariectomy, the vaginal epithelium of 147C was comprised of two to three layers of low polyhedral cells and a superficial layer of squamous to low cuboidal secretory cells. The height ranged from 22 to 32 microns. The epithelium of 85B,

during this time, showed similar changes. A lower epithelium of two to three polyhedral cells and a higher functional superficial layer ranging from low cuboidal to columnar in the vaginal crypts were apparent changes. The height ranged from 30 to 45 microns, which was lower than any stage during the normal cycle of this cow.

The fourteenth day after ovariectomy, 147C showed a very low epithelium, ranging from 12 to 25 microns high and consisting of one to three layers of low polyhedral cells. However, some areas contained a single layer of secretory cuboidal cells. The vaginal epithelium of 85B was lower, consisting of one to two layers of basal polyhedral cells and a layer of low cuboidal to tall columnar, secretory, superficial cells. The height of the epithelium ranged from 30 to 35 microns.

On the seventeenth day after ovariectomy, the vaginal epithelium of 147C was 21 to 29 microns high and contained a polyhedral layer, two to three cells thick, and a large number of cornified cells on the surface (Plate II, Fig. 4). During this time, 85B had a generally thicker vaginal epithelium, 15 to 32 microns high and three to five nuclei thick. This reduction in the height of the epithelium was a result of the increase in number of the cornified and squamous cells. However, the superficial layer of many areas consisted of secretory cuboidal cells (Plate II, Fig. 3).

On the twentieth day after ovariectomy, the vaginal epithelium of 147C was more functional and contained fewer cornified cells than on the seventeenth day. The height of the epithelium

ranged from 15 to 23 microns. In some areas, the epithelium consisted of a single layer of columnar secretory cells 15 microns high. The vaginal epithelium of 85B showed similar changes, except that the epithelium was at least two nuclei thick. The height ranged from 17 to 23 microns.

On the twenty-third day, the epithelium in both cows resembled the last stage except that in 85B it was somewhat lower, with only a few areas over 20 microns. Some secretory activity was still evident, particularly within the vaginal crypts.

On the twenty-seventh day after ovariectomy, the vaginal epithelium of 147C consisted of a low cuboidal secretory layer and a thin layer of polyhedral cells which ranged from 7.5 to 23 microns in thickness (Plate II, Fig. 6). The epithelium of 85B showed no changes and continued to show a PAS positive reaction in some areas. The epithelium of 147C at 30 to 36 days after ovariectomy was dry with many cornified cells and a very low secretory activity.

With the low level of estrogen present after the removal of the ovaries, the epithelium became lower and the cell size diminished with slight and variable cornification of the surface layer. The epithelium showed cyclic changes with the superficial layer ranging from low secretory cuboidal to cornified non-secretory cells. Glover (1960) reported comparable cyclic changes in cervical secretion of ovariectomized cows. These changes might be attributed to a cyclic secretion produced by the adrenal gland as proposed by Bourne and Zuckerman (1941), which was cited by Glover (1960).

The cyclic changes in the height of the epithelium and the variation between the two cows postovariectomy are shown graphically in Plate VII, Fig. 1.

The Effect of Estrogen and Progesterone Administration  
on the Vaginal Epithelium of Ovariectomized Cows

One day after an intramuscular injection of 3 mg. estradiol-cyclopentylpropionate (E.C.P.), the vaginal epithelium of 147C had increased from 15 to 24 microns in thickness, due to an increase in the number of polyhedral cells.

The superficial layer ranged from non-secretory cuboidal cells to secretory columnar cells, however, a few more cornified cells were apparent than were present one day before injection (Plate III, Fig. 2). The vaginal epithelium of 85B, which ranged from 25 to 55 microns, showed similar changes.

The appearance of cornified cells on the superficial layer during this time, is in agreement with the work of Hansel (1949) who found an increase in the percentage of the cornified cell recovered in smears taken one day after intramuscular injection of 0.5 mg. stilbestral. This study is also in agreement with Hansel's (1949) suggestion that cornification is due to the epithelium growth. The cells cornify and slough, while the epithelium thickens with no secretory activity.

On the second day after treatment, the vaginal epithelium of both cows was higher and thicker and exhibited more secretory activity. The epithelium of 147C consisted of three to four layers of high polyhedral cells and the height ranged from 30 to

60 microns. The epithelium of 85B was composed of four to eight layers and varied from 40 to 70 microns in height.

During the third day post treatment, the epithelium of 147C was reduced to one to four layers of large polyhedral cells. It ranged in height from 23 to 58 microns, and the superficial layer consisted of tall columnar, secretory cells (Plate III, Fig. 4). The vaginal epithelium of 85B during this time was thicker, 65 to 94 microns, and consisted of five to six layers of polyhedral cells and a secretory cuboidal to columnar superficial layer (Plate III, Fig. 3). During the fifth day post treatment, the epithelium was 18 to 28 microns in 147C and 30 to 62 microns in 85B. The epithelium of 85B contained more squamous cells; however, there appeared to be a higher secretory activity than in 147C. Cow 85B showed more external mucous than was normally present during estrus, while 147C did not show a visible mucous secretion until the sixth day, at which time she showed external mucous comparable to that of her normal estrous cycle. On the sixth day, the vaginal epithelium of 147C was slightly lower and ranged from one to three nuclei thick. The superficial layer contained squamous cells with pyenotic nuclei. The epithelium of 85B was higher than that of 147C and contained four to six layers of polyhedral cells and a superficial layer of secretory, cuboidal cells.

On the seventh day after injection, two days after the most profuse secretion, the epithelium of 85B was thick, 77 to 110 microns, and the superficial cells were lower. The polyhedral basal cells, however, were higher. The vaginal epithelium of

147C, after two days of maximum secretion, was reduced to 21 to 62 microns in height and two to three layers of basal polyhedral cells and a low superficial cell layer that showed a positive PAS reaction.

During the remainder of the post treatment period, the vaginal epithelium of 147C ranged from 18 to 40 microns in height and one to three basal polyhedral cells and the superficial cell layer was low cuboidal to squamous. Both squamous and cornified cells were evident on days 10, 15, 21, and 23 post treatment. A single layer of columnar secretory cells was present on days 10, 11, 17, and 20 after treatment.

The vaginal epithelium of 85B was highest on the seventh day after injection. Thereafter, the epithelium ranged from two to four nuclei thick and 22 to 60 microns high. Squamous and cornified cells were present on the seventh and ninth days.

On the twenty-fifth day after treatment with 3 mg. E.C.P., the vaginal epithelia of 147C and 85B were nearly non-secretory, however, some areas showed a PAS positive reaction.

It seems that 3 mg. E.C.P. caused the hyperplasia and hypertrophy of the vaginal epithelium in both cows. The degree of vaginal epithelium response to the treatment differs from one cow to another. The epithelium of 85B was higher than that of 147C, however, both cows showed the lowest epithelium on the fifth day after injection. The number of the cell layers is another example of individual variation in response to estrogen treatment. This study is in agreement with the findings of Gardner (1960) who found a variation in the vaginal sensitivity

of ovariectomized rats in response to estrogen treatment. The secretory activity of the vaginal epithelium was greater in 147C than it was in 85B, however, the secretory activity evident in 85B was greater than that observed during her normal cycle. The secretory activity of the vaginal cells of 147C was similar to that of the normal estrous cycle.

These findings indicate two things: First, a level of 3 mg. E.C.P. is more stimulatory than the normal physiological level of estrogen secreted by the ovaries of 85B during her normal estrous cycle, however, it may be comparable to the level secreted by 147C. Second, the weight of the cow is not associated with the response caused by a certain level of estrogen. The bigger cow showed higher response than the smaller one did. This is in agreement with the reports of Melampy (1957) and DeAlba (1945) who found no connection between the weight of the cow and the dose of estrogen needed to induce heat signs.

One day after intramuscular injection of 3 mg. E.C.P. and 5 mg. progesterone, the epithelia of 147C and 85B were thicker, and showed a considerable increase in the number of the squamous cells of the superficial layer. One day later, with the introduction of an additional 5 mg. progesterone, the epithelia of both cows were further increased in thickness. The epithelium of 147C ranged from 30 to 60 microns in height. The epithelium of 85B ranged from 55 to 85 microns and contained a layer of polyhedral cells ranging from five to seven nuclei thick.

After the introduction of another 5 mg. progesterone on the third day, the epithelium of 147C showed an increase in the



number of polyhedral cells. The epithelium showed only a slight secretory activity and ranged from 30 to 60 microns in height. The epithelium of 85B was comprised of six to eight cell layers and was 60 to 90 microns high. The superficial layer contained a number of secretory cuboidal cells.

After treatment with a total of 20 mg. progesterone, the epithelium of 147C consisted of five to eight layers averaging 35 to 72 microns in height. The superficial layer ranged from squamous to cuboidal. The epithelium was as thick as that observed by Mahmoud (1960) in the posterior portion of the vagina during proestrus.

The epithelium of 85B showed no increase in number of the polyhedral cells, although it was higher, ranging from 90 to 115 microns, due to an increase in the size of the cells. The epithelium at this stage was uniform in height and cell layers.

After the administration of the sixth 5 mg. dose of progesterone, the epithelium of 147C was composed of five to nine layers and ranged from 40 to 70 microns in height. The superficial layer showed an intense PAS positive reaction. The epithelium of 85B was higher, 35 to 90 microns, and four to eight layers in thickness. Low polyhedral to squamous non-secretory, with pyknotic nuclei, cells were present on the superficial surface.

One day after the total of 35 mg. of progesterone was injected, the epithelium of 147C ranged from 30 to 60 microns in height, and no secretory activity was evident. The vaginal epithelia of both cows greatly increased in thickness during the post treatment period (Plate IV, Figs. 3 and 4). By twenty-six

days after the last injection, squamous and cornified cells were showing at variable intervals on the superficial surface, however, in a number of areas one layer of tall columnar, secretory cells was observed. After the thirty-eighth day, the epithelium resembled that of the ovariectomy type (Plate IV, Fig. 6).

The epithelium of 85B was highest three days after the total injection was introduced. It ranged from 90 to 135 microns in height and eight to ten layers of large polyhedral cells thick. The height of the epithelium was variable, but generally was higher than it was in 147C (Plate IV, Fig. 4). Squamous cells with pycnotic nuclei were as variable as in 147C. The epithelium was lower after the nineteenth day of injection and ranged from 30 to 45 microns in height and three to five nuclei in thickness. The secretory activity was very low after 30 days of treatment.

This study indicates that the presence of estrogen and progesterone in adequate levels will cause the epithelium to undergo higher proliferation more than when estrogen was introduced alone. This might be attributed to the action of progesterone that inhibits further action of estrogen in causing mucous secretion and cell loss and hence maintaining the condition of the high epithelium. This is in agreement with the findings of Melampy (1957) who found a higher synergetic action of progesterone in estrogen conditioned ovariectomized cows. Glover (1960) stated that Moore and Robinson (1957) found that the smears were more abundant in ovariectomized ewes treated with estrogen and progesterone.

Fifty days after the last treatment with 3 mg. E.C.P. and 35 mg. progesterone, 147C was treated with 35 mg. progesterone in 5 mg. daily doses. The epithelium before treatment was comprised of a basal layer of polyhedral cells, two to four nuclei thick, and ranged from 15 to 41 microns in height and the secretory superficial layer varied from low cuboidal to low columnar (Plate V, Fig. 1).

The daily progesterone treatments resulted in a gradual decrease in the height of the superficial layer of cells and the loss of cell activity (Plate V, Figs. 2 and 3).

After treatment with a total of 20 mg. progesterone, the superficial layer generally was cornified and some areas showed more than one layer of cornified cells (Plate V, Fig. 4).

After a total of 35 mg. progesterone was administered, the epithelium was lower and no indication of secretion was observed (Plate V, Fig. 6). Approximately 20 mg. of progesterone thus completely inhibited the action of the endogenous secretion of estrogen assumed to be secreted by the adrenal gland.

#### SUMMARY AND CONCLUSION

The histological and the cytological changes which occur in the bovine vagina, and the probable endocrine cause for their variations, have not been as well established as they have been in the other animals. This study was undertaken to determine the cellular changes which occur during the normal estrous cycle, after ovariectomy, and as a result of the administration of estrogen and/or progesterone.

During the follicular phase of the normal cycle, and during the induced heat of the ovariectomized animals, the vaginal epithelium consisted of highly secretory columnar cells with or without large basal polyhedral cells. The height of the epithelium was lowest during one day postestrus and five days after treatment with 3 mg. of estradiolcyclopentylpropionate.

Estrogen causes hypertrophy and hyperplasia of the vaginal epithelium. The extrusion of the cell contents during mucin secretion results in a reduction in the thickness of the epithelium.

Progesterone, in adequate amounts, causes the non-secretory condition of the epithelium, and the cornification of the superficial cell layer during the luteal phase of the normal cycle.

Progesterone inhibited the stimulatory effect of the endogenous estrogen in ovariectomized cows, resulting in higher cornification of the vaginal epithelium. The cornification of the vaginal epithelium of the ovariectomized cow after the administration of 20 mg. progesterone was more intense than during the luteal phase of the normal cycle. This might be attributed either to low physiological level of estrogen or to the presence of abnormally high level of exogenous progesterone. The presence of both hormones in the ovariectomized cows resulted in higher and thicker vaginal epithelium than was evident during the normal cycle.

After withdrawal of both hormones by ovariectomy, reduction in the height of the epithelium resulted and the epithelium exhibited short cyclic secretory changes.

The variations in vaginal changes observed in the two cows were attributed either to the difference in the hormonal balance during the normal cycle, or to the difference in sensitivity of the vaginal epithelium. These variations were less evident during the postovariectomy period. No correlation was found between the weight of the animal and the response to the hormonal dose used.

## ACKNOWLEDGMENT

The author wishes to extend his most sincere thanks to Dr. G. B. Marion and Dr. H. T. Gier for their constant assistance and advice given throughout the course of this study.

Appreciation is extended to my colleagues, Edward P. Call, Eugene B. Krehbiel, and James S. Norwood, for the services they rendered in one way or another.

## LITERATURE CITED

- Allen, E.  
 "The estrous cycle in the mouse." Amer. Jour. Anat.,  
 30:297, 1922.
- Asdell, S. A.  
 "Growth in the bovine graafian follicle." Cornell Vet.,  
 Vol. L, No. 1, Jan., 1960.
- Brown, P. C.  
 "Physiological and histological changes in the vagina of the  
 cow during the estrual cycle." Amer. Jour. Vet. Res.,  
 5:99-112, 1944.
- Cole, H. H.  
 "A study of the mucosa of the genital tract of the cow with  
 special reference to the cyclic changes." Amer. Jour.  
 Anat., 49:261, 1930.
- DeAlba, J.  
 "The response of ovariectomized heifers to injection of es-  
 trogens and progesterone." Thesis, Cornell University,  
 Ithaca, N. Y., 1945.
- Gardner, W. V.  
 "Sensitivity of the vagina to estrogen: genetic and trans-  
 mitted difference." Annals of the New York Academy of Sci-  
 ences, Vol. 38, Art. 2, pp. 145-159, 1959.
- Gier, H. T.  
 "Estrous cycle in the bitch: vaginal fluids." Vet. Scope,  
 Vol. V, No. 2, 1960.
- Glover, F. A.  
 "The response to ovarian hormone administration in the cow  
 estimated from the physical properties of cervical secre-  
 tions." Jour. Endocrinology, 20:56, 1960.
- Hansel, W., S. A. Asdell, and S. J. Roberts.  
 "The vaginal smear of the cow and causes of its variation."  
 Amer. Jour. Vet. Res., 10:221, 1949.
- Hisaw, F. L., R. O. Creep, and H. L. Fevold.  
 "The effect of estrogen and progesterone on the sexual skin  
 of the monkey." Amer. Jour. Anat., 61:483, 1937.
- Hummon, Ormond J.  
 "Cellular changes occurring in the internal female genitalia  
 of bos. taurus during estrum including some observations  
 during pregnancy." M. S. Thesis, Iowa State College, 1932.

- Mahmoud, A. H.  
 "A study of the bovine vagina as related to reproductive performance." M. S. Thesis, Kansas State University, 1960.
- Marion, G. B., and H. T. Gier.  
 "Histological and cytological changes in the bovine vaginal epithelium." Abstract of paper presented at the Annual Meeting of the American Soc. of Animal Production, Chicago, Ill., Nov. 23, 1960.
- Melampy, R. M., M. A. Emmerson, J. M. Rakes, L. J. Hanka, and P. G. Eness.  
 "The effect of progesterone on the estrous response of estrogen-conditioned ovariectomized cows. Jour. Animal Sci., pp. 16, 967, 1957.
- Murphey, H. S.  
 "Studies of the estrous cycle in the ox." Vet. Practit. Bull., Iowa State College of Agri., Vol. 8, No. 1, pp. 153-163, 1926.
- Nibler, C. W.  
 "Factors influencing breeding efficiency in artificial breeding of dairy cattle." Nebr. Agr. Exp. Sta. Bull. No. 629, 1957.
- Perkins, J. R., Durward Olds, and D. M. Seath.  
 "A study of 1000 bovine genitalia." Jour. Dairy Science, 37:1158-1163, 1954.
- Risman, G. C.  
 "The effect of estradiol and progesterone on the reproductive tract of the opossum and their possible relation to parturition." J. Morph., 81:343, 1947.
- Roark, D. B., and H. A. Herman.  
 "Physiological and histological phenomena of the bovine estrous cycle, with special reference to vaginal cervical secretion. Mo. Agr. Exp. Sta. Res. Bull. No. 455, 1950.
- Rosa, C. G., and J. T. Velardo.  
 Histochemical localization of vaginal oxidative enzymes and mucins in rats treated with estradiol and progesterone. Annals of New York Academy of Sciences, Vol. 83, Art. 2, pp. 122-144.
- Sanger, V. L., P. H. Engle, and D. S. Bell.  
 "The vaginal cytology of the ewe during the estrous cycle." Amer. Jour. Vet. Res., 19:283-287, 1958.
- Seller, R. M.  
 "Changes in the vaginal epithelium of the guinea pig during estrous cycle." Amer. Jour. Anat., 30:429, 1922.



- Traut, H. F., P. W. Black, and A. Kuder.  
"Cyclic changes in the human vaginal mucosa." Surg. Gynec.  
Obstet., 7:63, 1936.
- Trautmann, Alfred, and Joseph Fiebiger.  
"Fundamentals of the histology of the domestic animals."  
Revised. Comstock Publishing Associates, Cornell University  
Press, p. 300, 1957.
- Trotter, D. M., and J. W. Lumb.  
Revised 2nd Ed. of late W. M. McLeod book, "Bovine Anatomy,"  
Burgess Publishing Co., Minneapolis, Minn., 1958.

## APPENDIX

## EXPLANATION OF PLATE ABBREVIATIONS

EP ---- Epithelium  
CC ---- Cornified Cells  
SC ---- Secretory Cells

## EXPLANATION OF PLATE I

- Fig. 1. A section from the anterior portion of the vaginal wall of 85B two days proestrus, showing an epithelium consisting of a basal layer of two to four polyhedral cells thick and a superficial layer of cuboidal to squamous cells. (X 750)
- Fig. 2. A section from the anterior portion of the vagina of 147C two days proestrus, showing an epithelium consisting of a basal layer of polyhedral cells, two to three nuclei thick, and a superficial layer of cuboidal to columnar secretory cells. (X 750)
- Fig. 3. A section from the anterior portion of the vaginal wall of 85B during estrus, showing an epithelium consisting of a layer of large basal polyhedral cells and a superficial layer of large secretory cuboidal cells. (X 750)
- Fig. 4. A section from the anterior portion of the vaginal wall of 147C during estrus, showing an epithelium comprising one layer of tall columnar secretory cells with a row of round nuclei at the base of the cells. (X 750)
- Fig. 5. A section from the anterior portion of the vagina of 85B eleven days postestrus, the vaginal epithelium consisting of a basal layer of four to six polyhedral cells thick and a superficial layer of polyhedral to squamous cells. (X 750)
- Fig. 6. A section from the anterior portion of the vagina of 147C thirteen days postestrus, the vaginal epithelium composed of a basal layer of four to seven polyhedral cells thick and a superficial layer of cornified cells. (X 750)

## PLATE I

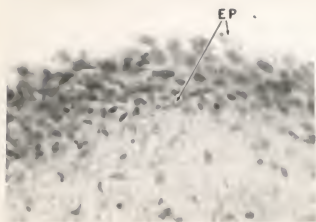


FIG. 1

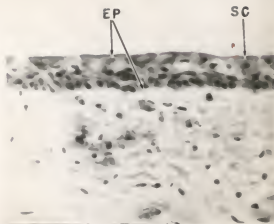


FIG. 2

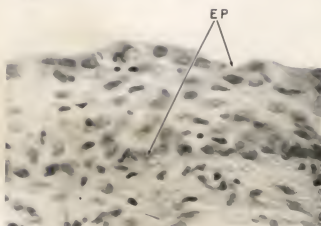


FIG. 3

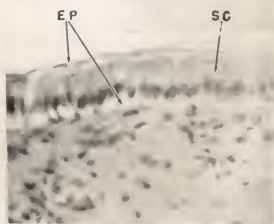


FIG. 4

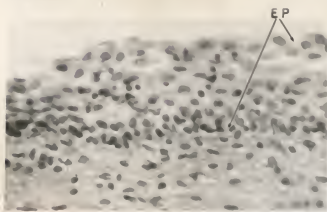


FIG. 5

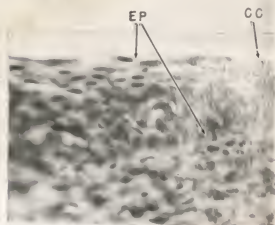


FIG. 6

## EXPLANATION OF PLATE II

- Fig. 1. A section from the anterior portion of the vaginal wall of 85B seven days after ovariectomy, showing an epithelium consisting of a basal layer of two to three nuclei thick and a superficial layer of low cuboidal to squamous cells. (X 750)
- Fig. 2. A section from the anterior portion of the vaginal wall of 147C seven days after ovariectomy, showing an epithelium consisting of a basal layer of two to three low polyhedral cells and a superficial layer of cornified cells. (X 750)
- Fig. 3. A section from the anterior portion of the vaginal wall of 85B seventeen days after ovariectomy, showing an epithelium consisting of three to five nuclei thick, the superficial layer consisting of cuboidal secretory to squamous cells. (X 750)
- Fig. 4. A section from the anterior portion of the vaginal wall of 147C seventeen days after ovariectomy, showing an epithelium consisting of two to three layers of polyhedral cells and a superficial layer of polyhedral to squamous cells. (X 750)
- Fig. 5. A section from the anterior portion of the vaginal wall of 85B twenty-seven days after ovariectomy, showing an epithelium consisting of a basal layer of one to two nuclei thick and a superficial layer of low cuboidal secretory to squamous cells. (X 750)
- Fig. 6. A section from the anterior portion of the vaginal wall of 147C twenty-seven days after ovariectomy, showing an epithelium consisting of a basal layer of two to three polyhedral cells thick and a superficial layer of low squamous to cornified cells. (X 750)

## PLATE II

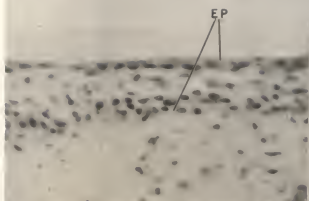


FIG. 1.




FIG. 2

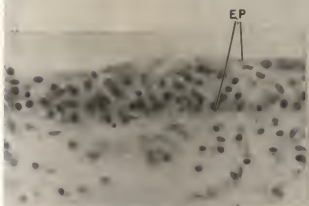


FIG. 3

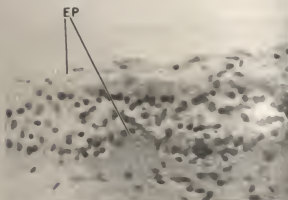


FIG. 4

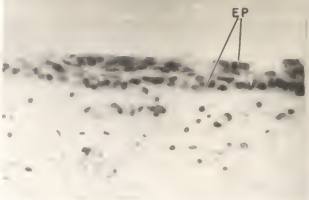


FIG. 5

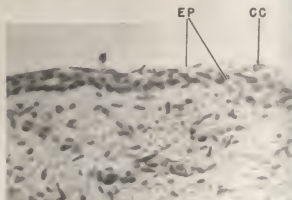


FIG. 6

### EXPLANATION OF PLATE III

- Fig. 1. A section from the anterior portion of the vaginal wall of 85B one day after treatment with 3 mg. E.C.P., showing an epithelium comprised of a basal layer of three to four nuclei thick and a superficial layer of low cuboidal to squamous cells. (X 750)
- Fig. 2. A section from the anterior portion of the vaginal wall of 147C one day after treatment with 3 mg. E.C.P., showing an epithelium consisting of a basal layer of two to three nuclei thick and a superficial layer of secretory cuboidal to low squamous cells. (X 750)
- Fig. 3. A section from the anterior portion of the vaginal wall of 85B three days after treatment with 3 mg. E.C.P., showing an epithelium consisting of a basal layer of five to six large polyhedral cells and a superficial layer of cuboidal to columnar secretory cells. (X 750)
- Fig. 4. A section from the anterior portion of the vaginal wall of 147C three days after treatment with 3 mg. E.C.P., showing an epithelium consisting of a basal layer of three to four nuclei thick and a superficial layer of columnar secretory cells. (X 750)
- Fig. 5. A section from the anterior portion of the vaginal wall of 85B five days after treatment with 3 mg. E.C.P., showing an epithelium consisting of a basal layer of one to three large polyhedral cells and a superficial layer of secretory to tall columnar cells. (X 750)
- Fig. 6. A section from the anterior portion of the vaginal wall of 147C five days after treatment with 3 mg. E.C.P., showing an epithelium consisting of one layer of columnar secretory cells. (X 750)



## PLATE III

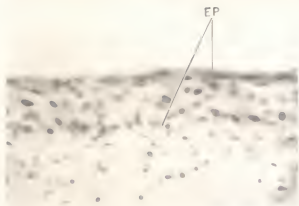


FIG. 1




FIG. 2

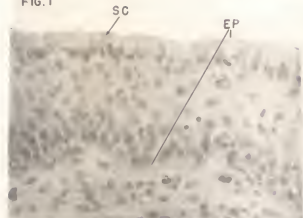


FIG. 3

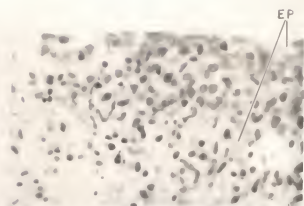


FIG. 4

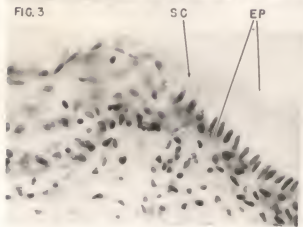


FIG. 5

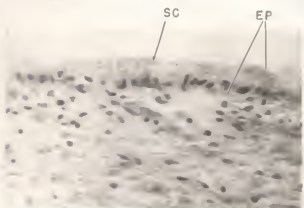


FIG. 6

#### EXPLANATION OF PLATE IV

- Fig. 1. A section from the anterior portion of the vaginal wall of 85B, after treatment with 3 mg. E.C.P. and 20 mg. progesterone, showing an epithelium consisting of a basal layer of six to eight large polyhedral cells thick and a superficial layer of polyhedral to cuboidal cells. (X 750)
- Fig. 2. A section from the anterior portion of the vaginal wall of 147C, after treatment with 3 mg. E.C.P. and 20 mg. progesterone, showing an epithelium consisting of a basal layer of polyhedral cells five to eight nuclei thick. (X 750)
- Fig. 3. A section from the anterior portion of the vaginal wall of 85B one day after treatment with a total of 3 mg. E.C.P. and 35 mg. progesterone, showing an epithelium consisting of a basal layer of polyhedral cells five to seven nuclei thick and a superficial layer of non-secretory polyhedral to cuboidal cells. (X 750)
- Fig. 4. A section from the anterior portion of the vaginal wall of 147C one day after treatment with a total of 3 mg. E.C.P. and 35 mg. progesterone, showing an epithelium consisting of a basal layer of polyhedral cells five to six nuclei thick and a superficial layer of squamous to low polyhedral cells. (X 750)
- Fig. 5. A section from the vaginal wall of 85B twenty-six days after treatment with a total of 3 mg. E.C.P. and 35 mg. progesterone, showing an epithelium consisting of a basal layer of two to three nuclei thick and a superficial layer of squamous to low cuboidal cells. (X750)
- Fig. 6. A section from the anterior portion of the vaginal wall of 147C forty-five days after treatment with a total of 3 mg. E.C.P. and 35 mg. progesterone, showing an epithelium consisting of two to three nuclei thick and a superficial layer of cuboidal to cornified cells. (X750)

## PLATE IV

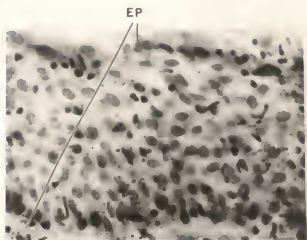


FIG. 1

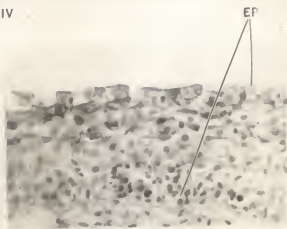


FIG. 2

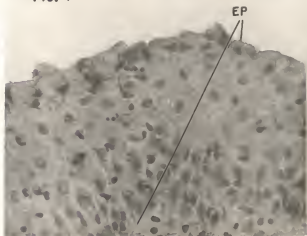


FIG. 3




FIG. 4

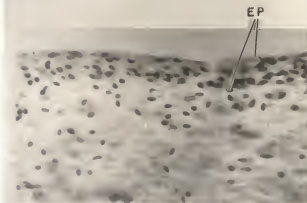


FIG. 5

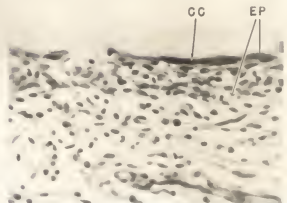


FIG. 6

#### EXPLANATION OF PLATE V

- Fig. 1. A section from the anterior portion of the vaginal wall of 147C fifty days after treatment with a total of 3 mg. E.C.P. and 35 mg. progesterone, showing an epithelium consisting of a basal layer of polyhedral cells two to four nuclei thick, the secretory superficial layer ranging from low cuboidal to columnar. (X 750)
- Fig. 2. A section from the anterior portion of the vaginal wall of 147C after treatment with 5 mg. progesterone, showing an epithelium consisting of a basal layer of low polyhedral cells one to two nuclei thick and a superficial secretory columnar cell. (X 750)
- Fig. 3. A section from the anterior portion of the vaginal wall of 147C after treatment with 10 mg. progesterone, showing an epithelium consisting of a basal layer of polyhedral cells two to three nuclei thick and a superficial layer of low cuboidal to squamous cells. (X 750)
- Fig. 4. A section from the anterior portion of the vaginal wall of 147C after treatment with 20 mg. progesterone, showing an epithelium consisting of a basal layer of low polyhedral cells one to two nuclei thick and a superficial layer of cornified cells. (X 750)
- Fig. 5. A section from the anterior portion of the vaginal wall of 147C after treatment with 25 mg. progesterone, showing an epithelium consisting of a basal layer of low polyhedral cells and a superficial layer of cornified cells. (X 750)
- Fig. 6. A section from the anterior portion of the vaginal wall of 147C after treatment with 35 mg. progesterone, showing an epithelium consisting of a basal layer of polyhedral cells one to two nuclei thick and a superficial layer of cornified cells. (X 750)

## PLATE V

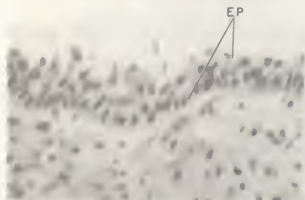


FIG. 1




FIG. 2



FIG. 3

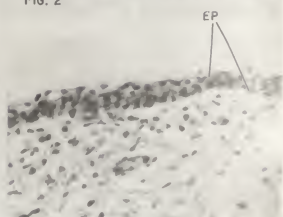


FIG. 4

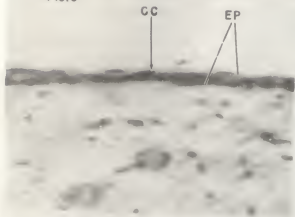


FIG. 5



FIG. 6

## PLATE VI

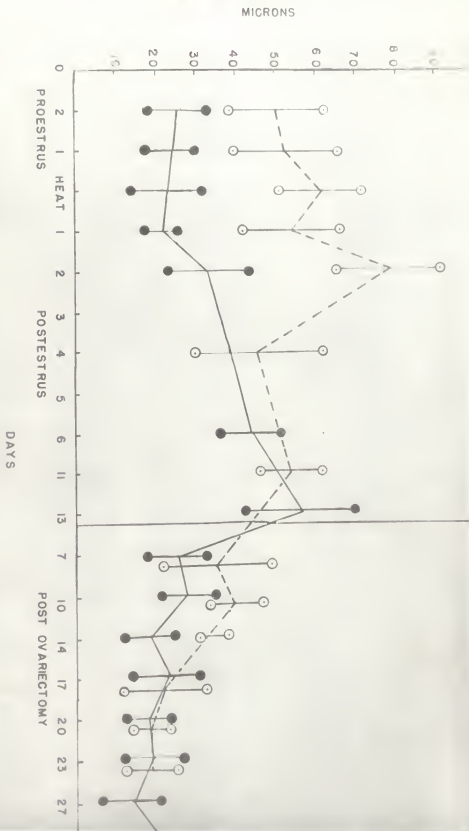


FIG. 2. HEIGHT OF THE VAGINAL EPITHELIUM DURING ESTROUS CYCLE AND AFTER OVARECTOMY

858

147C

## PLATE VII

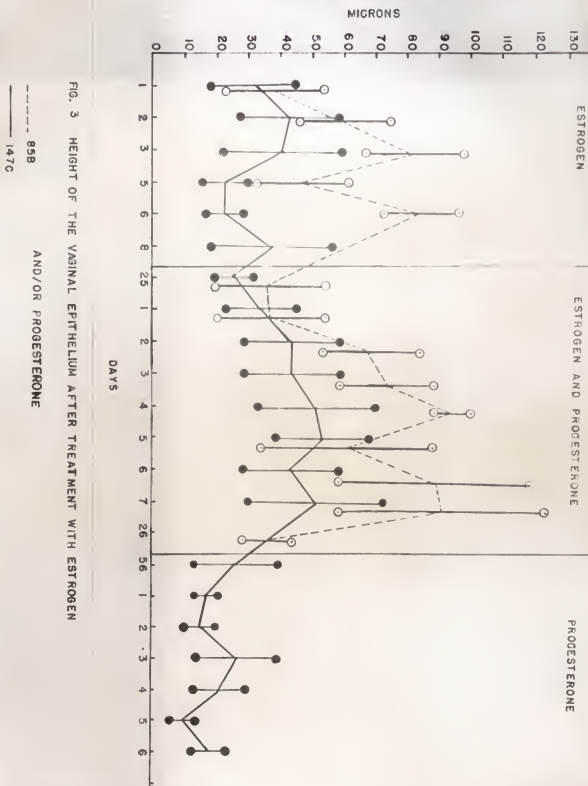


FIG. 3 HEIGHT OF THE VAGINAL EPITHELIUM AFTER TREATMENT WITH ESTROGEN

AND/OR PROGESTERONE

85B

147C

PLATE VIII



FIG. 1 BIOPSY INSTRUMENT



EFFECT OF ESTROGEN AND PROGESTERONE  
ON THE VAGINAL EPITHELIUM OF THE DAIRY COW

by

ADNAN OMRAN DARWASH

B. S., Baghdad University, 1958

---

AN ABSTRACT OF A MASTER'S THESIS

submitted in partial fulfillment of the

requirements for the degree

MASTER OF SCIENCE

Department of Dairy Science

KANSAS STATE UNIVERSITY  
Manhattan, Kansas

1962

The histological and the cytological changes that occur in the bovine vagina, and the probable endocrine causes for their variations, have not been well established. The present study was undertaken to determine the cellular changes which occur in the bovine vagina during the normal estrous cycle, after ovariectomy, and as a result of administering estrogen and/or progesterone to ovariectomized cows.

Two cows were employed, 147C and 85B. Vaginal tissues were removed by a biopsy instrument, from the anterior portion, two to three inches from the external os of the uterus. The biopsies were fixed in ten percent neutral formalin. Normal histological techniques were used in preparing the tissues for study. The height of the epithelium was measured and graphed, and cellular changes recorded. Photomicrographs of the prepared sections representing the various phases were taken.

After the histological changes occurring in the vaginal epithelium during the normal estrous cycle had been determined, the cows were bilaterally ovariectomized, and all changes were noted until the epithelium had become stabilized.

Both cows were treated, thereafter, with three mg. of estradiol cyclo pentyl propionate (E.c.p.) and/or 35 mg. progesterone. During proestrus of the normal cycle, the epithelium was reduced in height and showed PAS positive reaction in the superficial layer of columnar secretory cells. The epithelium reached its lowest height of 18 to 23 microns in 147C and 45 to 65 microns in 85B one day postestrus. Two to six days postestrus, the epithelium became thicker and secretory activity diminished.

During the luteal phase of the cycle, eight to 18 days postestrus, the epithelium was high in 147C and relatively low in 85B.

Individual variations evident between the two cows during the same stage of the normal cycle were attributed to differences in the hormonal balance and/or to differences in the vaginal sensitivity to this balance.

Withdrawal of both ovarian hormones after ovariectomy resulted in lower vaginal epithelium consisting of one to three cell layers which maintained three-day cyclic secretory changes, probably due to a low level of endogenous estrogen which is normally secreted by the adrenal gland.

Estrogen alone caused hyperplasia and hypertrophy of the vaginal epithelium of the ovariectomized cows. Both cows showed a lower epithelium containing columnar secretory cells on the fifth day after treatment. The epithelium after the fifth day post treatment continued to increase in height and in number of layers for a short time, then started to decline after the seventh day in 85B and after the eighth day in 147C as the hormone level in the body was reduced. After 20 days, the epithelium reverted to the ovariectomized type.

Estrogen and progesterone injected together caused greater effects than either hormone alone, resulting in a higher epithelium with a greater number of layers and low secretory activity.

The action of estrogen in causing hyperplasia and hypertrophy of the vaginal epithelium was not inhibited by 35 mg. progesterone. This dose of progesterone, however, partially

inhibited the estrogenic action of stimulating mucous secretion. The height of the epithelium was maintained during this phase because of the lack of cell loss that occurred during a high estrogenic phase.

Progesterone alone inhibited the action of the endogenous estrogen secretion and stimulated a highly cornified superficial epithelium.

This study indicates that estrogen caused hypertrophy of the cells, but that progesterone inhibited estrogenic stimulation. It may be that progesterone alone has a cornification influence on the vaginal epithelium.

Individual differences in response to similar hormonal treatment is attributed to the differences in sensitivity of the vaginal epithelium.