

A STUDY FOR CORRELATION OF STAGES
OF MAMMALIAN EMERYOS

by

PATRICIA ANNE HENRY

B. S., Kansas State College of Agriculture
and Applied Science, 1956

A THESIS

submitted in partial fulfillment of the

requirements for the degree

MASTER OF SCIENCE

Department of Zoology

KANSAS STATE COLLEGE
OF AGRICULTURE AND APPLIED SCIENCE

1956

LD
2668
T4
1958
H45
c.2
Documents

TABLE OF CONTENTS

INTRODUCTION	1
LITERATURE REVIEW	2
Ectoderm	2
Mesoderm	5
Nephric System	7
Endoderm	8
Ageing and Measurements	10
MATERIALS AND METHODS	15
OBSERVATIONS	16
Bovine	16
Dog	23
DISCUSSION	26
SUMMARY	31
ACKNOWLEDGMENTS	33
LITERATURE CITED	34
APPENDIX	37

INTRODUCTION

Mammalian external forms result from proliferation of the embryonic germ layers into organs and systems. The germ layers develop at different rates and into different structures, but the rate of development is characteristic of a species. The external form becomes characteristic of the species early in development.

Various stages of mammalian embryogeny have been described in detail and for several different animals, but little has been done in correlation and comparison of ages with sizes and weight. The most complete series so far described (Streeter, 1941, 1945, 1948) is a series of human embryos in the Carnegie Institute collection, between the estimated ages of 14 and 37 days of gestation. Maneely (1952) compared growth of crown-rump length and weight by plotting a curve, using embryos of known ovulation age of six different dairy breeds. Harman and Dobrovolny (1933) described external development of the Guinea pig between the ages of 21 and 35 days of gestation.

Various workers have given numerous descriptions of embryos during early and late stages of gestation and at parturition, but there is a noticeable lack of description of complete series from fertilization to parturition.

It was noted that although the gestation period of a Guinea pig and dog are similar and bovine and human are also similar, that there is a striking difference in rate of development between species requiring similar periods of gestation.

The literature is a guide for further work to be done but correlation of different species has never been made. Embryos from dogs of mixed breeds

collected for a study of embryology of the dog and bovine embryos obtained from a similar study of dairy breeds constitute the basis for the present report.

LITERATURE REVIEW

Ectoderm

Streeter (1926) described a "six-day" embryo, the youngest normal human embryo thus far known, as having just reached position in the uterus. An amniotic vesicle and cavity were recognized. An embryo in the bilaminar blastodisc stage of unknown age (Brewer, 1938) had a primitive ectoderm of a single row of tall columnar cells resting on a basement membrane.

A general description of a seven somite embryo, (Payne, 1925) indicated the neural tube was closed for a short distance and had no flexion. The anterior and posterior neuropores were open and the subdivisions of the brain were only indicated. There were definite neuromeres in the rhombencephalon and the neural crest appeared as early as the seven somite stage.

An eight somite embryo of unknown age (West, 1930), had a curvature just anterior to the point of closure of the neural tube. There appeared to be a thickened lip in the region of the forebrain.

Corner (1929) described an embryo with ten somites as having the beginning of the otic disc as an ectodermal thickening at the side of the neural tube opposite the anterior neuropore. Immediately behind the otic disc the wall of the neural tube spread out into the neural plate. The forebrain with the optic primordia did not yet have a differentiation between midbrain and the rhombencephalic regions.

By the 13 somite stage, the acoustico-facial region of the neural tube showed a definite thickening. Evagination of the optic vesicle began at the

seven to eight somite stage but a distinct optic stalk was not formed until the 14 to 16 somite stage. By the time there were 14 pairs of somites there were definite divisions of the brain into prosencephalon, mesencephalon, and rhombencephalon with the beginning of the ganglia of cranial nerves V and VII. A cranial flexure was present from the beginning of somite formation, and interpreted as being due primarily to rapid growth of the dorsal as compared to the ventral layers of the midbrain folds (Corner, 1929).

At 16 somites the telencephalon division may be present. The otic disc had invaginated at the 11 somite stage, and by 17 somites it was a hemispherical cavity (Atwell, 1930). The optic vesicles were in contact with the overlying ectoderm. The fifth, seventh, eighth, and ninth cranial nerves were present and there was a thickening of the ectoderm overlying the neural crests. The growth of pharyngeal pouches one and two had reached the ectoderm and formed closing membranes.

The anterior neuropore closed at the 20 somite stage (Davis, 1923); however, the neural tube was still open posteriorly. The infundibulum, the thalamus, and the tenth cranial nerve were recognized.

The posterior neuropore closed between 21 and 29 somites (Streeter, 1941). By 26 days the otic vesicles were almost closed in the human, and the arm buds had appeared. The neural tube was large, compact, and "C" shaped.

At about 28 days the embryo had both arm and leg buds. There was an ependymal zone and the beginning of the nervous system. There was a pigmented layer of the retina and a stalk on the eye. The otic vesicle was now closed and had an endolymphatic appendage (Streeter, 1945).

The arm buds were divided into distal arm and proximal arm and shoulder at about 32 days. The leg buds were beginning to show regional differentiation. The olfactory pit was a shallow depression with thickened margins. The lens was small and cup-shaped, and in the cavity of the eye cup. The brain was one-third larger in over-all dimensions. The hypoglossal nerve was distinct and the epiphysis appeared as a slight thickening on the roof of the brain.

At the estimated age of 33 days the brain was still increasing in dimensions. The olfactory pit could be seen in profile. The eyes showed a dark tinge due to pigmentation in the retina and the lens vesicle was free from overlying epithelium. The ear had the beginning of a cochlear pouch and semicircular ducts. The hand region had differentiated into carpus and digital plates. The leg bud exhibited proliferation of thigh, leg, and foot regions. There was a thickening of skin ectoderm.

Although the head was relatively larger at 35 days in the human, the main axis of the trunk was straighter and had a slight indication of a lumbar curvature. The limbs had definite digital rays in the hand plate. The foot was distinguished from the tarsus and the leg proper.

The primitive face was established and had a definite nose and upper jaw. The nasal wing formed the dorsolateral boundary of the olfactory pit and was separated by the nasal septum. The eye had definite retinal pigment. The endolymphatic appendage was a thin-walled fusiform sac. The cochlear duct was elongated at the tip of the labyrinth.

The shape of the human embryo at the estimated age of 37 days was a cuboidal bulk. There were rudiments of eyelids and grooves and a recognisable tip of the nose. The finger rays were distinct and the toe rays

were beginning to form. The mammary nipples had developed, but the sex of the embryo could not yet be determined.

Mesoderm

The primitive mesoderm surrounded the inner cell mass by six days in an embryo that had just reached its position in the uterus (Streeter, 1926). The primitive streak in the bilaminar blastodisc stage of an unknown age was the earliest described for man by Brewer (1938). There was a condensation of cells that marked the location of the future body stalk.

An embryo described by Ingalls (1918) at the estimated age of 17 to 18 days had a well defined primitive groove and Hensen's groove and Hensen's node. The head process was in association with the primitive streak. Blood cells were forming in the yolk sac.

There was a constriction between Hensen's node and the streak proper by 18 days (Heuser, 1932). The mesoderm joined the endoderm in the midline of the primitive streak at the posterior end only. There was a long notochordal process and the chorda canal extended anterior from the Hensen's node. The mesoderm of the germ-disc was closely applied to the lateral surfaces of the entire formation except entirely lacking in front of the Hensen's node. The forming blood vessels were found in the mesoblast of the chorion and the body stalk.

Payne (1925) described an embryo of unknown age, having seven mesodermal somites, that had a vascular system composed of a heart and one pair of aortic arches, dorsal aorta, umbilical and vitelline arteries and veins. The blood islands in the yolk sac were filled with blood cells, but there was no complete circulation of blood. The notochord extended from the primitive streak to the anterior end of the foregut.

A major change noticed by Corner (1929) in the ten somite stage was that the heart began to beat and circulation had begun. A capillary network connected with the dorsal aorta and there was an elaborate plexus of blood vessels lying upon the hindgut and caudal part of the midgut. There was also a plexus of umbilical veins before connecting with the embryo. The heart was an "S" shaped loop. There was a constriction between the atrium and the sinus venosus.

The heart had an endothelial tube by the 14 somite stage as described by Heuser (1930). A lumen appeared in the blood vessels and portions of the cardinal veins were visible. The primitive streak could still be identified.

The heart was still "S" shaped by the 20 somite stage and the first aortic arches were complete, the second was forming, and a tiny outgrowth indicated the third. The dorsal aortae were paired with the exception of an anastomosis between the 10th and 13th somites (Davis, 1923). The heart was enclosed by a contractile tissue which was the primordium of the myocardium. The sinus venosus rested upon the liver. The sino-atrial foramen was formed by 30 somites.

By 28 days the heart was distended with fluid to about the size of the head (Streeter, 1945). The fourth aortic arch was forming. The heart was becoming thicker and the epicardium was beginning to differentiate. The circulation was well established and moved by a pulsating rhythm of the heart. The blood from the yolk sac went through the liver plexus into the sinus venosus by means of the vitelline veins. The primordium of the right and left ventricle was noted by 32 days.

At 33 days there was still a common aorta-pulmonary trunk, but it was in the process of separating. The sites of the valves were seen but not

present at this stage. The sites of the valves were seen but not yet present at this stage. The pulmonary and aortic channels were separate by 35 days as was also the right and left atric-ventricular canals. The ventricular pouches and the semi-lunar valves were established.

By 37 days the heart was a four-chambered organ with separate pulmonary and aortic streams. The interventricular septum was fused to the opposing wall. The sinus venosus opened into the right atrium just posterior to the inferior vena cava. Practically all the incoming stream of blood appeared to arrive through the foramen ovale.

Nephric System

The nephric system is mesodermal in origin and is sometimes described with the formation of the mesoderm. Because this system is an internal system and little can be noted externally, it will be described separately.

Corner (1929) stated that there were promephric rudiments appearing as a ridge between the eighth and ninth somites.

Heuser (1930) described a 14 somite embryo that had a three part nephric system. The first part began at the fifth and sixth somite region. The second part reached maximum size at the tenth somite and showed a slight glomerous in that region. The third nephric part had a primitive excretory duct and tubules in the region of the 14th somite.

Atwell (1930) described the nephric system of a 17 somite embryo as consisting of a rudimentary or degenerative cephalic portion, a more highly differentiated middle portion, and a caudal part showing little differentiation. The primary excretory duct terminated in the middle of the 13th somite on the right side and the top portion of the 14th somite on the left.

The urogenital or nephric system of an embryo of 20 somites, consisted of a series of pronephric tubules, mesonephric bar, and a primary excretory duct, which had not yet reached the cloaca.

Streeter (1941) described an embryo of an estimated age of 26 days that had a mesonephros and duct with tubules from the eighth somite to the 20th. This was continuous with the nephrogenic cord at the 24th somite. There were two tubules opposite each pair of somites.

By 28 to 30 days (Streeter, 1945), the developing mesonephros was not yet functional. Tubules had ducts and capsules. There were collecting ducts, secretory segments, and glomerular capsules or Bowman's capsules.

The mesonephros thickened by 38 days (Streeter, 1948) and invaginated to form the female genital duct, or Mullerian duct. An infolding of the Mullerian duct, which was straight, became the tubal ostium. The gonadal tissue was separated from the mesonephric tissue and was oval shaped. A dense framework of epithelial tissue was intermixed with the primary germ cells in the gonad tissue.

Endoderm

An embryo of six days estimated age, that had just reached position in the uterus and had not started destruction of the uterine wall, had a yolk sac mass (Streeter, 1926). The primitive endoderm was made up of cuboidal cells arranged in a single row beneath and parallel to the primitive ectoderm. It did not extend to the borders of the primitive ectoderm, in the bilaminar blastodisc stage, in an embryo described by Brewer (1938).

By three somites the foregut was well defined and connected to the midgut and hindgut and allantois (Ingalls, 1920). The primordium of the thyroid was noted.

In the primitive streak stage as described by Jones and Brewer (1941), there was an allantois and the cloacal membrane was formed by a fusion of the ectoderm at the caudal end.

Besides the divisions of the fore-, mid-, and hindguts, the thyroid pouch, laryngo-tracheal groove and the primordium of the lung appeared by the time the tenth somite was formed (Corner, 1929).

The first pair of pharyngeal pouches was clearly defined and the second and third pouches were beginning (Streeter, 1941). By the 14 somite stage the three pouches were definite. By 20 somites the fourth pouches were formed and the allantois consisted of three completely separate segments.

The liver, lung, stomach, and dorsal pancreas were developed by 30 somites or about 26 days (Streeter, 1945). The thyroid projects ventrally into the concavity of the aortic bulb. The parathyroid glands appeared bilaterally. There was not a sharp transition between gut and yolk sac. In association with the liver were the cystic duct, gall bladder, and a plexus of blood vessels.

By 28 days the lungs had developed primary bronchi. The trachea and esophagus had a common lumen. The gut tract became more slender and by 32 days the esophagus had elongated. The caecum marked the junction of the ileum and colon. The dorsal pancreas was in communication with the gut. The median thyroid was still connected to the floor of the pharynx.

By 33 days there was a definite mesentery beginning at the caudal end of the duodenum (Streeter, 1948). The dorsal pancreas was attached to the duodenum in front at the pyloric region. The vermiform appendix was present as such, by 35 days. Ducts had developed for the gall bladder and pancreas. The ventral and dorsal pancreatic portions had fused, but each still had its own duct. The liver was functional and remained attached to the gut wall.

By 37 days the lung had branched into a trachea and secondary bronchi. The esophagus was now supported by a muscle coat.

Ageing and Measurements

The age of human embryos was estimated from the last menstrual period as the exact ovulation and fertilization cannot be determined in humans, as it can in other animals such as the bovine and dog which show a definite heat period (Streeter, 1920). Weights and measurements of known ages were plotted on graphs and the ages of unknown could be estimated from the graphs.

Weights were taken before and after injection and fixation with formalin or alcohol, and indicated some shrinkage after fixation as demonstrated by Melton, et al. (1951) for bovine embryos and Schultz (1919) for human and other primates. The average weight in grams gave a curve as shown in Plate I (Winters, et al., 1942). Swett et al. (1948) cited the weights from five breeds of dairy cattle plus a mixed breed. The data were plotted and showed a similar curve as was demonstrated by Winters et al. (1942). Mansely (1952) compiled data of bovine embryos from several different workers and found the plotted curve following the pattern shown in Plate I.¹

Measurements were taken of human embryos by Streeter (1920) of the crown-rump or sitting position, eye-ear line perpendicular to the axis of the head and the feet length. Streeter (1948) plotted the greatest length in millimeters of human embryos between the ages of 22 and 36 days of gestation (Plate II). Data by Winters et al. (1942) from embryos of known age from grade beef heifers plotted on semi-log graphs produced a curve as shown in Plate III. The data by Streeter (1948) replotted on a semi-log graph would show a curve similar to that in Plate III.

¹ All Plates in the Appendix.

Table 1. Number, weight, and measurements of dog embryos.

Dog No.	Somite No.	Age	Weight grams	Contour	Crown- rump	Trunk	Chest	Girth	Length	Head	Feet	Hands	Ear	Tail	Sex
43L	1								1.5	1	1	1	1	1	N
100L	13								2.5	1	1	1	1	1	N
173	13								3	1.5	1	1	1	3	N
26OR-B	6								5	1.5	1	1	1	3	N
144L	15								5	1.5	1	1	1	4	N
120L	17								5	1.5	1	1	1	2.5	N
121L	17								5	1.5	1	1	1	2.5	N
77L	10								3	1.5	1	1	1	1	N
121R	29		.002	8	6				3	1.5	1	1	1	1	N
254	20		.05	6	6				5	3	3	3	3	5	N
81R	26		.02	6	6				5	5	5	5	5	5	N
241	47		.03	7	7.5				3	2	2	2.5	1	1	N
206	24		.07	9	9				5	3	3	3	3	3	N
206	24		.05	29	7.5				5	2	2	2.5	1	1	N
26	24		.05	30	9				5	3	3	3	3	3	N
47L	43		.203	32	11				5	5	5	5	5	5	N
122L	26			32	11				5	5	5	5	5	5	N
35L-C	54			35	13				5	5	5	5	5	5	N
279	54		1.0	50	18				8	6	4	4	4	1	N
46	28			38	12				6	6	6	6	6	6	N
9L	30		.7	49	19				6	6	6	6	6	6	N
9L	30		.8	47	20				6	6	6	6	6	6	N
54	30		.45	43	16				6	6	6	6	6	6	N
54	30		.62	42	17				7.5	5	5	5	5	5	N
128L	30			42	17				8	6	6	6	6	6	N
124R	31		1.02	54	20				9	6	6	6	6	6	N
229-I	31			54	20				9	6	6	6	6	6	N
127L	32		.85	58	24				9	6	6	6	6	6	N
46R	33			64	32				13	10	10	10	10	10	N
33R	33		2.5	71	37				12	9	9	9	9	9	N
127R	35		2.30	72	37				10	10	10	10	10	10	N
127R	35		2.65	79	38				10	10	10	10	10	10	N
281	36		4.50	78	43				15	10	10	10	10	10	N

Table 1. (Concl.).

Dog No.	Sex	Age	Weight : grams	Contour	Crown- : rump	Trunk	Chest	Girth	Length	Head : Length	Width	Fore : Hind	Ear : Tail	Sex
283L		38	10		57				20	13				
82R		43	28.5	125	78	47	22	75	25	17	15	13	5	M
252		44	70	122	97	65	33	105	33	24	16	18	7	F
280		44	50	183	103		31	95	32	23	18	15	7	M
155		52	186		140				45	35	27			
92		53	230	285	150	43	96	145	50	30	24	30	12	F
25		54	250	277	154	110	37	157	51	31	23	31	12	M
225		55	370	315	180	120	50	160	53	37	29	36	14	F

N---neutral sex

M---male sex

F---female sex

Table 2. Number, weight, and measurements of bovine embryos.

No. Dairy:	Age :	Weight :	Contour :	Trunk :	Chest :	Girth :	Length :	Head :	Fore :	Feet :	Sex :
No. :	:	grams :	:	:	:	:	:	:	:	:	:
51	1										N
147	4										N
17	20	2.2									N
117	25	4.5									N
113	26	3.5									N
12	26		12				1.5				N
83	26	.080	24				2		1	1	N
103	27	.062	22				2		1	1	N
135	29	.032	20				3		2	2	N
119	29						25		1.5	1	N
120	31	.0882	22.4				4		2	2	N
154	31	.505	34				4		2.5	2	N
4	34	.290	34				4		3	2	N
87	33									1.5	N
50	34	.145	31				4		3	1	N
96	34	.435	38				4		3	2	N
73	38	1.4	56				8		5	5	N
4	38						7		5	4	N
75	43	2.1	55				9		8	5	N
97	45	8	98				17		12	8	N
144	52	8	260				13		13	10	N
30	53		68				11		7	5	N
42	53	8.2	110				29		11	15	N
60	64	79	135				20		19	10	N
7	69	17.2	180				70		29	17	N
10	72	58	160				37		19	15	N
86	76	89.2	194				35		22.5	24	N
138	79	109	202				42		25	24	N
133	82	90	205				42		26	39	N
24	83	129	215				46		30	32	N
9	85	227	270				46		33	27	N
2	90	226.2	275				56		33	31	N
							59		38	39	N
							59		36	38	N
							145		44	44	N
							145		47	47	N
							31		1	1	N
							29		2	2	N
							32		5	5	N
							46		4	4	N
							17		8	8	N
							54		14	10	N
							33		7	5	N
							50		11	15	N
							22		10	10	N
							70		19	17	N
							84		24	24	N
							87		22	24	N
							109		26	39	N
							107		30	30	N
							105		26	32	N
							118		27	35	N
							145		28	31	N
							145		38	39	N
							145		36	38	N
							35		35	35	N
							84		4	4	N
							87		4	4	N
							103		5.5	5.5	N
							130		7	7	N
							134		7	7	N
							181		7	7	N
							170		9	9	N
							175		11	11	N

Table 2. (Concl.).

Gow No.	Dairy No.	Age	Weight in grams	Crown-ump	Contour	Trunk	Chest	Girth	Length	Head	Fore	Stail	Sex
88	250B	92	266.4	180	270	60	37	115	60	39	46	11.5	M
13	212B	93	233	250	250	56	42	140	56	41	46	11	F
109	453B	106	450	330	330	200	60	175	70	48	60	15	F
115	210B	108	600	395	395	155	66	215	72	51	64	14	F
151	310C	108	550	360	360	160	67	180	72	48	65	15	F
116	35A	110	750	395	395	140	75	215	80	52	70	17	M
39	45A	115	880	410	410	77	51	225	90	53	61	17	M
23	396B	116	750	380	380	150	72	212	81	52	60	18	M
158	132B	119	1070	482	482	205	82	240	92	52	70	22	F
85	350B	127	1485	328	328	120	60	185	68	45	61	15	M
155	319C	128	1170	480	480	200	64	245	93	60	75	24	M
119	195B	134	1700	550	550	230	98	262	110	68	90	30	F
152	393B I	143	2205	550	550	240	105	280	111	68	98	36	M
152	393B II	143	1500	525	525	23	57	250	106	55	78	32	M
6	423B	148	2600	605	605	215	104	320	122	68	98	35	F
148	314C	150	2725	600	600	270	120	330	125	73	100	42	M
160	161B	153	3178	690	690	300	150	352	150	76	100	44	F
156	391B	156	3632	715	715	285	81	364	143	71	130	50	F
136	2240C	182	12605	888	888	230	134	500	177	90	152	58	M
106	127B	192	12605	1010	1010	390	200	570	200	122	190	70	M
137	1740C	204	14982	1011	1011	305	210	625	218	127	190	268	M
53	163A	210	18614	1090	1090	430	240	650	210	105	255	330	F

M---neutral sex
 M---male sex
 F---female sex

MATERIALS AND METHODS

Fifty embryos (Table 1) of known ages were obtained from dogs of mixed breeds during a study of canine reproduction and 60 bovine embryos (Table 2) obtained from a similar study for dairy breeds. Ovulation time was considered to occur three days before the end of standing heat in the dog and 12 hours after the end of standing heat in the cow.

The reproductive tracts of dogs were removed in the laboratory by surgery. The dog embryos were weighed and measured in the embryonic membranes, fixed in ten per cent formalin or Bouin's fluid, and stored in 70 per cent alcohol. Additional measurements and observations were taken from the stored specimens.

The reproductive tracts were removed from the cow as soon as possible, about 15 minutes after slaughter of the animal. The tracts were packed in ice and removed to the laboratory. The embryos, with the embryonic membranes, were dissected from the uterus, weighed, measured, and photographed. The membranes were stripped off and the embryo was weighed, measured, and fixed in 10 per cent formalin.

Weights were taken in grams and milligrams and measurements in millimeters. Straight measurements were made with vernier calipers; curved surfaces were matched with a thread which was then measured on a millimeter ruler. Measurements for both bovine and dog include:

Contour---length from the tip of the nose over the forehead, along the mid-dorsal line, to the tip of the tail.

Crown-rump---greatest length in a straight line from the tip of the head to the rump (Plate IV, a).

Trunk---length from the anterior tip of the scapula to the posterior-most point of the thigh (Plate IV, b).

Chest---depth of the thorax dorsoventrally behind the forelegs (Plate IV, c).

Girth---circumference of the thorax behind the forelegs (Plate IV, c).

Head length---distance from the tip of the nose across the eye region to the top of the forehead, above the horn buttons in the bovine, (Plate IV, d).

Head width---lateral width of the head directly above the eyes (Plate IV, f).

Forefoot---length from the tip of the longest toe to the wrist (Plate IV, f).

Hindfoot---length from the tip of the longest toe to the back of the heel (Plate IV, g).

Ear---length from the notch to the tip of the external flap (Plate IV, h).

Tail---length from the base of the tail to the tip of the caudal bones (Plate IV, i).

Additional data was noted on other features of development such as the appearance of pharyngeal pouches, differentiation of limb buds, development of hair, pigmentation, and external genitalia.

OBSERVATIONS

Bovine

Measurable characteristics of bovine embryos were plotted on semi-log graph paper in Plates V-X.

The freshly ovulated ovum (496A) showed no sign of cleavage during the first day. The embryo (102B) contained three or four cells by the fourth day.

20 days (392A, 177A). The primitive streak had appeared with a well-defined Hensen's node. There was a head process made up of a notochord and head mesoderm. The newly formed head fold was accompanied by the splanchnopleuric fold. The tail fold had also begun, and the extra-embryonic somatopleure already formed a complete amnion over the embryo. The total length of the embryo including the primitive streak and head process was 2.2 mm. The yolk sac connection corresponded closely with the body fold. Somite formation and neural tube closure began during the twenty-first day (Plate XI, Fig. 4).

25 days (327C). The neural tube was closed posteriorly and was differentiated anteriorly into brain regions. The roof of the myelencephalon was relatively thin. There were three pharyngeal grooves. The mandibular arch was heavy. The manillary process showed dorsal to the oral cavity. A dorso-lateral mesonephric ridge .5mm. wide was present lateral to the 12th somite, decreasing posteriorly. Total length of the embryo was 4.5 mm.

26 days (313C). This embryo was unique in that it had four pharyngeal arches. It was "C" shaped with an overall length of 8 mm. The limb buds were present as thickened ridges and a tail region was definable. The heart and liver were distended into a mass about the same size as the head. The eye was visible as a small ring and the otocyst as a saucer-shaped depression. The yolk stalk connected to the gut through a ring of the body fold while the allantoic stalk was enclosed in the heavy mass of the body stalk.

27 days (326C). The embryo was very similar to 313C except that it had but three pharyngeal arches. There were $4\frac{1}{2}$ pairs of somites at this stage. The mammary ridge appeared latero-ventral to the somites and extended between the anterior and posterior limb buds which now appeared as flattened pads.

29 days (105G). Three pharyngeal grooves were still observed. The limb buds projected posteriorly as cylindrical flippers. The heart and liver mass were increasing in bulk and about equal in size. The head, although also increasing, was still about the same size as the heart. The body stalk and yolk sac were still separate. The overall length of the embryo was 10.5 mm.

31 days (244B). The pharyngeal arches were heavy, and the fourth arch was beginning as a tiny projection. The fore limb had a flattened pad distally but the proximal portion remained cylindrical. The metencephalon appeared as a thickened triangular mass anterior to the thin-roofed myelencephalon. There was pigmentation in the retina and the lens was fully formed. The olfactory placodes were beginning as invaginations in the region of the telencephalon. The otocyst was closing, developing an endolymphatic duct dorsally. The heart and liver mass was greatly distended and the head, curled under ventrally, rested upon the mass. The embryo with a total length of 13.5 mm. had 52 paired somites.

34 days (144B), (Plate XI, Fig. 2). The cerebral hemispheres were becoming evident seeming to divide the telencephalon into two lateral bulbs. The head itself was enlarging to about the size of the liver mass. The olfactory placodes were distinctly invaginated. The pharyngeal arches were projected toward the oral cavity. The hyoid arch was quite massive. The fore limb had a shoulder, a cylindrical central portion, and a flattened

distal pad. The hind limb was beginning differentiation of a distal flattened pad on a cylindrical proximal portion. Sixty pairs of somites were present in this 13-mm. embryo.

38 days (265B). The head was about one-third the bulk of the embryo. The thin roof of the myelencephalon was a transverse crescent behind the developing cerebellum. The maxillary processes were between the mouth and the eyes. The nasal process was visible at this stage. The mammary ridge was as broad as it was thick. The closure of the body wall around the heart and liver was a definite ring about one millimeter medial to the mammary ridge, beginning to compress the heart, which was still completely outside the body cavity. The ribs were visible through the overlying tissues. The external ear appeared as a crescentic slit with a tiny triangular flap. The toe bones were visible in the fore limb. The hind limb had divided into thigh, tibia and foot regions, and the toe bones were barely visible through the surface of the skin. The genital papilla appeared as a tubular structure about one millimeter long. The somites were no longer visible in the 21-mm. embryo.

41 days (482A), (Plate XII, Fig. 4). The mesencephalon was bulged dorsally. The eyelids were forming as a ring dorsal and ventral to the eye ball. The body wall had extended further over the heart and liver mass forming a definite chest region. The triangular flap of the external ear was bending over but not closing the ear opening. Total length was 19 mm.

43 days (168B). The nose was observed as a definite structure. There was a row of hair follicles over the eye and the eyelids were beginning to close. The mammary ridge was not visible. There were two toes on both fore and hind limbs and the beginning of rays three and four. The embryo length was 26 mm.

45 days (398B). The embryo at this stage appeared as a bovine. The head was still tucked under the ventral surface. The mouth was open and the tongue could be seen. The pinna was folded ventrally closing the ear opening. Hair follicles appeared scattered over the upper lip as well as in a row over the eye. The body wall had closed around the body stalk. Total length was 45 mm.

52 days (134B). The sex of the embryo could be determined by external genitalia. The scrotal sac was developing and the mammary glands were also evident as tiny papillae. The head was about one-third the total bulk of the embryo. The eyelids were two-thirds over the eye. The neck region was beginning to elongate. The toes were beginning to appear as hooves. The embryo was 50 mm. in length.

64 days (300C). The head, legs, and tail were approximately the same length. The ribs were still visible through the skin. Hair follicles appeared on the chin.

69 days (51A). The length had increased to 113 mm. at this stage. The eyelids were almost closed. The horn buttons were visible as circles anterior to the ears.

72 days (183A). The head plus the elongatine neck were about one-third the total length of the embryo. The horn buttons appeared as circular depressions with raised centers. The ear flap completely covered the ear opening. The mouth was closing. The vulva appeared as a tubercle. The distal half of each hoof was curled upward.

76 days (231B). The eyelids were closed. Vibrissae appeared over the eye and around the nose, mouth, and chin. The horn buttons increased slightly in diameter. The embryo was 125 mm. long.

79 days (39G), (Plate XIII, Fig. 2). The neck region had thickened dorso-ventrally and the head had elongated slightly. There was a whitish projection from the center of the horn buttons. The pinnae were laid back against the head dorsally, revealing closed auditory canals. The tubercle-like structure of the vulva protruded about four millimeters. The mammary glands were paired, the anteriormost pair being spaced further apart than the posterior pair. Cornification was evident in the upper half of the hooves. The overall length of the embryo was 130 mm.

83 days (147B). There appeared to be no changes in the embryo from the last stage except an increase in size proportionately. The head was about one-fourth the overall length of the embryo of 152 mm. The scrotal sac was well developed.

90 days (290B). The vulva continued to appear as a tubercle. There was no noticeable increase in size of the horn buttons. The embryo continued to increase proportionally to a length of 175 mm.

108 days (240B). The embryo continued to increase in weight and to a length of 225 mm. The tooth buds appeared as smooth bumps on the lower jaw. The mammary nipples were 1.5 mm. long.

110 days (35A). There was no noticeable change from 108 days; the total length was 245 mm.

116 days (396B). The pinnae were thickening and becoming broader at the base. The hooves were not so curled as before and were hardening in the proximal half.

119 days (132B). There were vibrissae around and over the nose and mouth. The hooves were yellowish except for the ends which were still slightly curled and white. The length had increased to 298 mm.

128 days (319C). Vibrissae appeared over the eye and scattered over the nose around the mouth and over the chin. The nose pad epithelium was toughening. The neck was thick and the legs appeared too long for the body. The hooves were hardening due to cornification. The scrotal sac was prominent. Overall length of the embryo was 350 mm.

134 days (195B). There was no noticeable change in the embryo except a double row of vibrissae over the eye.

150 days (314C). The lower lip and chin were well covered with fine hair. The nose epithelium had darkened. The mammary glands were prominent in both male and female. Total length at this stage was about 400 mm.

153 days (161B). Long hair was observed in eyebrows, eyelashes, and the chin. The pattern of pigmentation was showing on the skin. The length was 450 mm.

156 days (391B). Hair follicles had appeared on the tip of the tail. The hooves and dewclaws were becoming hard due to cornification.

182 days (224GG). The horn buttons were covered with hair. There was some hair around the mouth and on the tip of the tail. The length of the embryo was 573 mm.

192 days (127B). The chin was completely haired. In addition to hair development described at 182 days, there was also hair lining the inner side of the ear, patches around the hooves to the knees and more on the tail. Hair follicles appeared over the rest of the body.

204 days (174GG). As more hair appeared, the eyelids were covered. There were additional patches from the edge of the ear and the top of the head down the side and around the eyes. Hair had developed around the umbilical cord and the tail had a switch at the tip. The length increased to 712 mm.

240 days (163A). The embryo was near term and fully haired and appeared to have all the characteristics of a newborn calf.

Dog

Measurable characteristics of dog embryos were plotted on semi-log graph paper in Plates XII-XVIII.

15 days (100L). A primitive streak was seen in the three-millimeter blastocyst.

16 days (260L-B). The edges of the neural plate were coming together, forming a tube from the anterior neuropore to the posterior portion of the somites. The endocardial tubes were forming lateral to the rhombencephalon. There were six pairs of mesodermal somites formed (Plate XIX, Fig. 3). The primitive streak was still visible with a definite Hensen's node. The total length was five millimeters.

17 days (116). The neural plate had formed a tube to the eighth somite. The tube had differentiated into the three primary brain regions. The head fold was accompanied by the splanchnopleure lateral to the mesencephalon. Eight pairs of somites were counted. The head fold of the amnion extended over the prosencephalon, and the tail fold of the amnion appeared as a crescent posterior to the unsegmented somitic mesoderm. The total length from head fold to tail fold was six millimeters.

20 days (121R). The cephalic flexure had developed on the embryo at this stage. Two pharyngeal arches were formed. The outline of the neural tube was observed in relationship to the eye, otocyst, and cranial nerves of the myelencephalon. The telencephalon was bulblike. The heart tube was looped back on itself and protruded from the right side of the embryo. Twenty-nine pairs of somites were counted. The tail was cylindrical and

was curling under the embryo. The allantois was visible as a balloonlike projection from the hind gut region. The greatest length was six millimeters.

22 days (81R). The embryo had a general "C" shaped appearance. The first and second pharyngeal arches were becoming larger and the third was beginning. The epiphysis was seen on the roof of the diencephalon. The myelencephalon had a thin roof. The olfactory placodes were seen as invaginations at the front of the bulbular telencephalon. The limb buds had developed into flattened pads. The tail length had increased as the posterior portion of the embryo had twisted, projecting the tail under the embryo. The overall length of the embryo was still six millimeters due to the curling, but the contour length had increased. There were 36 pairs of mesodermal somites.

24 days (47L), (Plate XX, Fig. 1). The head was becoming massive. The cerebral hemispheres were differentiating on the telencephalon. The eyes and otocysts appeared as circles below the surface epithelium, the diameter of the otocyst being greater than that of the eye cup. Three pharyngeal arches present were projecting toward the oral cavity. The limb buds were growing and becoming cylindrical. The length increased to seven millimeters and 43 paired somites.

26 days (122L). The head size had increased to about the size of the heart and liver mass. The myelencephalon was large and still showed a thin bulging roof. The olfactory placodes had become pits under the telencephalon. The pharyngeal arches were extending toward the oral cavity; the fourth pouch was beginning. The fore limb was divided into an undifferentiated proximal portion and distal pad. The hind limb was still flipperlike. There were about 42 paired somites counted in the 11-mm. embryo.

28 days (279). The nasal septum had formed between the nasal pits. The head was about two-fifths the length of the embryo. A dorsal ridge over the ear had developed a triangular projection over the ear opening. Pigmentation in the retina was definite and the eyelids were forming. There were four toe rays seen in both fore and hind limbs. The tail was still curled ventrally as the embryo no longer showed torsion in the tail region. The genital papilla was now visible ventrally to the tail, as a tubercle. The total length was 18 mm.

30 days (9L), (Plate XXI, Fig. 3.). The nose was well formed and the face appeared flattened. The mammary nipples were visible below the skin of the venter. The body wall was beginning to enclose the heart and liver mass. The fore limb had differentiated showing an elbow. The tibia was forming on the hind limb. The overall length had increased to 20 mm.

32 days (127L). The face was formed and the mouth was slightly open. The triangular ear flap was bent over the ear opening, but not yet closing. The head size was about one-third the length of the 24-mm. embryo. The six mammary nipples appeared as buttonlike structures on the abdomen. The body wall had extended over the heart and liver mass to the body stalk.

35 days (127R). The eyelids were closed except for a slit over the middle of the eye. The ear opening was closed by the triangular ear flap. The jaw had lifted from the chest. The neck was elongating. The body was straight except for slight bends in the head and rump regions. The fore limb was well formed. The hind limb had a knee dividing the regions of the thigh and tibia. The toes were separated and spread on both limbs. The embryo appears as a canid.

43 days (82R), (Plate XII, Fig. 1.). The face was well formed. The head was about one-fourth the body size and the neck region appeared in

normal perspective. The body itself was straight. Toe nails and foot pads were forming. Hair follicles appeared over the body. The overall length was 78 mm. The sex was determined by the external genitalia at this time.

53 days (92). The fetus was fully haired. The mouth was open with the tongue visible. The total length was 150 mm.

56 days (225). The fetus appeared fully developed and had the appearance of a newborn pup.

DISCUSSION

The human embryo differentiated within the blastocyst by delamination of the inner cell mass forming the amniotic ectoderm dorsally and the endoderm ventrally during the tenth day postovulation (Patten, 1952). The body fold was thus formed as the line of junction between the amniotic ectoderm and the embryonic disc around the edge of the original inner cell mass.

In the bovine, Greenstein and Foley (1955) observed the 17-day embryo as being in the early primitive streak stage with a body fold forming around the edge of the embryonic disc and an amniotic fold in the extraembryonic somatopleure around the embryonic disc. The body fold was complete all the way around the embryo during the 18th day and the amnion was complete by the 19th day while the embryo was still in the presomite condition.

In the dog the head fold appeared first during the late 16th day at approximately five somites with the neural tube already forming. The formation of somites and neural plate in the three species appeared to be closely parallel. The first pair of somites in the human developed at 17 days with an average increase in somites slightly over three pairs per day. In the cow, the first pair of somites developed during the 20th day (Plate XI, Fig. 4) with an average of 4.5 pairs of somites per day for the next ten days.

There was an accelerated rate of development of the dog. The first somites appeared in the 16th day with an average increase of 6.5 per day for the first five days, then the rate of formation decreasing to two per day from 26 days until the full number of 55 was reached.

The head began to form with the development of the cephalic flexure and took shape with the enlargement of the mandibular arch. The posterior limit of the head was established with the completion of the cervical flexure. There was no essential difference between the three animals except in time intervals.

The maxillary arches approached the median line by 28 days in the bovine, 27 days in the dog, and by the 35th day in the human.

The lower jaw was forming and began to protrude at the same time as the nasal processes met, forming the nose by 38 days in the bovine, 30 days in the dog, and 48 days in the human. The snout protruded and jaws were distinguished at 45 days in the bovine, 38 days in the dog, and 69 days in the human.

The main difference up to this time in head development was protrusion of the forehead in the human and the greater elongation of the snout in the bovine and dog.

Constriction and elongation of the neck appeared first in the bovine by 45 days, the dog by 25 to 27 days, and the human by 45 to 50 days.

The ear appears as a remnant of the first pharyngeal groove pushed dorsally by the development of the mandible after 40 days in the bovine, 27 days in the dog, and 45 days in the human. The pinna appears as a ridge over the dorsal edge of the first pharyngeal groove at 38 days in the bovine, 28 days in the dog, and 45 days in the human. In both the bovine and the dog, the pinna developed as a triangular flap bent ventrally

covering the meatus, while in the human the ridge continued to form as a half cup which typically extended dorsally.

In the bovine the pinna straightened out dorsally at approximately 70 days of gestation. In the dog the pinna enlarged but remained over the ear opening until after parturition.

In all three types there was a fleshy closure of the external auditory meatus from a time shortly after the beginning of the pinna until after the reopening of the canal at 100 days in the bovine, 45 days in the dog, and 90 days in the human.

The first pharyngeal groove showed in the dog embryo of 20 somites during the 19th day; the second appeared by 20 days, and third by 22 days.

In the cow the first groove had appeared by 23 days, the second groove showed by 24 days, the third by the 25th day.

In the human the first pharyngeal groove was present at the 12th to 14th somite stage or 22 days. The second groove appeared by the 24th day, and the third by 26 days.

The outward appearance of the grooves and arches was essentially the same for the three different animals.

During the fifteenth and sixteenth days of gestation, the dog embryo essentially fits the contour of the uterus (Plate XI, Fig. 1, 3). The cephalic flexure appeared in the neural tube at the 12th somite stage when the neural tube was closed in the mid-brain region and posteriorly to the somites. The flexure continued until by the end of the 18th day it had reached a full 90-degree flexure and the cervical flexure had begun. Late in the 19th days the caudal flexure began, and the combined flexures had bent the embryo into a full "C" by the 20th day.

In the cow, both cephalic and caudal flexures were present in the 20th day as the neural plate began to close anterior to the somites. The cow at 26 days was essentially the same as the 20-day dog.

In the human at 20 somites there was a portion of the cephalic flexure and the cervical flexure had begun. The cephalic flexure began before the closure of the neural tube (three somites). The caudal flexure began by 17 days or the seven-somite stage. The cervical flexure began at approximately 28 days.

The limb buds were first observed as thickened ridges ventro-lateral to the somites developing into flattened circular pads in the bovine at 27 days, the dog at 22 days, and the human by 26 days. With the appearance of the limb buds the trunk region can be established and the tail area determined. The tail already, about one-third as wide as long, was beginning to curl ventrally. The limb buds elongate and become more cylindrical, projecting posteriorly. The distal pads had differentiated beyond the cylindrical proximal portions in the bovine at 31 days, the dog at 26 days, and the human at 38 days. The distal pad of the anterior appendage showed digital rays and the proximal portion an indication of an elbow at 38 days in the bovine, 30 days in the dog, and 45 days in the human. The fore limbs showed projections of five rays at 48 days for human, two rays at 45 days for the bovine, and four rays at 33 days for the dog. At the same time the hind limb showed tibia and thigh regions, but no hip as yet, and the distal pad digital rays characteristic of the species.

Both limbs had differentiated and the fingers and/or toes were separated and widely spread by 53 days in the bovine, 43 days in the dog, and 56 days in the human. Soles and palms and finger nails were developing on the human, hooves and dewclaws on the bovine, and claws and pads on the dogs.

The tail continued to elongate about the same rate and approximate length of the limb buds in the bovine and dog. The human tail, however, begins to regress about 35 days and remains only as a stump by 64 days.

Hair follicles first appeared scattered over the upper lip, around the nose, and a single row over the eye at 64 days in the bovine and 30 days in the dog. Follicles appeared on the chin of the bovine by 64 days and the chin and thoracic region by 33 days in the dog. Vibrissae appeared where the follicles were previously seen in the bovine by 76 days and the dog at 38 days. Eyebrows were observed on the human by 150 days. At 150 days in the bovine, the eyebrows and the area around the nose had long hairs, and the chin was well covered with shorter hair.

Hair follicles appeared over the body by 192 days on the bovine and 43 days on the dog. Hair appeared on the head of the human by 180 days. The bovine by 240 days and the dog by 53 days appeared fully haired.

As the animal increases in size and complexity, the weight increases proportionately. Weights less than 0.1 gram in the dog and 1.0 gram in the cow were subject to too great an error due to adhering water, so they were omitted from present consideration.

Maneely (1953) compiled data of bovine weights from five different workers and found the rate of development makes a regular regression curve. Two workers (Maneely, 1953) recorded data that differed greatly from all other records. It was assumed that these aberrant data were probably due to miscalculated ovulation time. Data from the present study were found to follow closely, data cited by Maneely. It was noted for the bovine that the weight at 30 days, when the first weight was significant, was doubled after a period of only six days. The weight again doubled in the next period of six and a half days. Time required for doubling the weight

increased then to 10 days, then 18, and finally 38 days just before parturition.

In the dog there was a linear regression in the weight increase as shown by the weight plotted against days on semi-log paper, with the weight doubling each day at 22 to 25 days, then decreasing to two days around 40 days and finally to a period of six days before parturition.

In the human the weight was first determined at the third lunar month and had increased five times by the next month. The weight increase was doubled about every 28 days until the last month during which there was only a slight increase until parturition. Records of human weights are inadequate for satisfactory comparison.

SUMMARY

A review of the literature was made for the rate of development in the human and bovine embryos. No such literature was available on the dog.

A series of 60 bovine embryos and 50 dog embryos was studied and measurable characteristics plotted. A comparison was made in time of appearance and rates of development of certain characteristics.

The characteristics studied were: weight, contour, crown-rump, trunk, chest and girth, head length and width, fore and hind limbs, and ear and tail.

The development of the mammalian embryo was similar, in the three different species studied, during early embryogeny. The difference being in the rate of growth. The embryos had the same general appearance until the establishment of the face and differentiation of the appendages.

As the embryo increased in size and complexity, the weight increased proportionately. There was a progressive regression in rate of development particularly noticed during the later part of gestation in the three species.

The dog in 40 days after the first appearance of the somites, had differentiated as much as the bovine in 200 days after the first somite formation and more than the human in 260 days. This occurred by differences in rate of differentiation and rate of growth, and was illustrated especially by somite formation and weight increase.

ACKNOWLEDGMENTS

Special gratitude is extended to Dr. H. T. Gier for his supervision, encouragement, and patient understanding throughout this study.

Acknowledgment also is given for the facilities and the excellent series of both bovine and dog embryos used during the study.

LITERATURE CITED

Atwell, Wayne J.

A human embryo with seventeen pairs of somites. Carnegie Institute Publication No. 118. Contrib. to Embryol. 21: 1-24. 1930

Brewer, John I.

A human embryo in the bilaminar blastodisc stage (the Edwards-Jones-Brewer ovum). Carnegie Institute Publication No. 162. Contrib. to Embryol. 27: 85-93. 1938.

Corner, George W.

A well-preserved human embryo of 10 somites. Carnegie Institute Publication No. 112. Contrib. to Embryol. 20: 81-102. 1929.

Davis, Carl L.

Description of a human embryo having twenty paired somites. Carnegie Institute Publication No. 72. Contrib. To Embryol. 15: 1-51. 1923.

Greenstein, Julius S. and Richard C. Foley.

Preliminary observations on the development of the normal bovine embryo from late blastocyst stage to the differentiation of organ primordia. Jour. Animal Sci. 14(4): 1174-1262. 1955.

Harman, Mary T. and Marjeris Prickett Dobrovolsky.

The development of the external form of the guinea pig (Cavia cabaya) between the ages of 21 days and 35 days of gestation. Jour. of Morph. 54(3): 1933.

Heuser, Chester H.

A human embryo with 14 pairs of somites. Carnegie Institute Publication No. 131. Contrib. to Embryol. 22: 135-154. 1930.

A presomite human embryo with a definite chorda canal. Carnegie Institute Publication No. 138. Contrib. to Embryol. 23: 251-267. 1932.

Heuser, C. H. and G..L. Streeter.

Early stages in the development of pig embryos, from the period of initial cleavage to the time of the appearance of limb-buds. Carnegie Institute Publication No. 109. Contrib. to Embryol. 20: 1-30. 1929.

Ingalls, H. William.

A human embryo before the appearance of the myotomes. Carnegie Institute Publication No. 23. Contrib. to Embryol. 3: 111-134. 1918.

A human embryo at the beginning of segmentation, with special reference to the vascular system. Carnegie Institute Publication No. 52. Contrib. to Embryol. 11: 61-90. 1920.

Jones, H. O. and John Brewer.

A human embryo in the primitive streak stage (Jones-Brewer, Ovum I).
Carnegie Institute Publication No. 185. Contrib. to Embryol.
29: 157-165. 1941.

Maneely, R. B.

Note on the aging of bovine embryos. Vet. Rec. 64: 509-511. 1952.

Melton, A. A., R. O. Berry, and O. D. Butler.

The interval between the time of ovulation and attachment of the
bovine embryo. Jour. of Animal Sci. 10(4). 1951.

Patten, Bradley M.

Human Embryology. Philadelphia: Blakiston Company. 1952.

Payne, F.

General description of a 7-somite human embryo. Carnegie Institute
Publication No. 81. Contrib. to Embryol. 16: 115-124. 1925.

Schultz, A. H.

Changes in fetuses due to formalin preservation. Amer. Jour. Phys.
Anthropol. 2: 35-41. 1919.

The technique of measuring the outer body of human fetuses and of
primates in general. Carnegie Institute Publication No. 384.
Contrib. to Embryol. 20: 213-258. 1929.

Streeter, George L.

Weight, sitting height, head size, foot length, and menstrual age of
the human embryo. Carnegie Institute Publication No. 55. Contrib.
to Embryol. 11: 143-170. 1920.

The "Miller" Ovum--The youngest normal human embryo thus far known.
Carnegie Institute Publication No. 92. Contrib. to Embryol.
18: 31-48. 1926.

Developmental horizons in human embryos. Description of age group XI,
13 to 20 somites and age group XII, 21 to 29 somites. Carnegie
Institute Publication No. 197. Contrib. to Embryol. 30: 211-245. 1941.

Developmental horizons in human embryos. Description of age groups
XIII, embryos about 4 or 5 mm. long, and age group XIV, period of
indentation of the lens vesicle. Carnegie Institute Publication
No. 199. Contrib. to Embryol. 31: 27-63. 1945.

Developmental horizons in human embryos. Description of age groups XV,
XVI, XVIII, being the third issue of a survey of the Carnegie collec-
tion. Carnegie Institute Publication No. 211. Contrib. to Embryol.
32: 133-203. 1948.

Swett, W. W., C. A. Matthews, and M. H. Fohrman.

Development of the fetus in the dairy cow. U. S. Dept. Agri. Tech. Bull. No. 964: 1-34. 1948.

West, Cecil M.

Description of a human embryo of eight somites. Carnegie Institute Publication No. 119. Contrib. to Embryol. 21: 25-35. 1930.

Winters, L. M., W. W. Green, and R. E. Comstock.

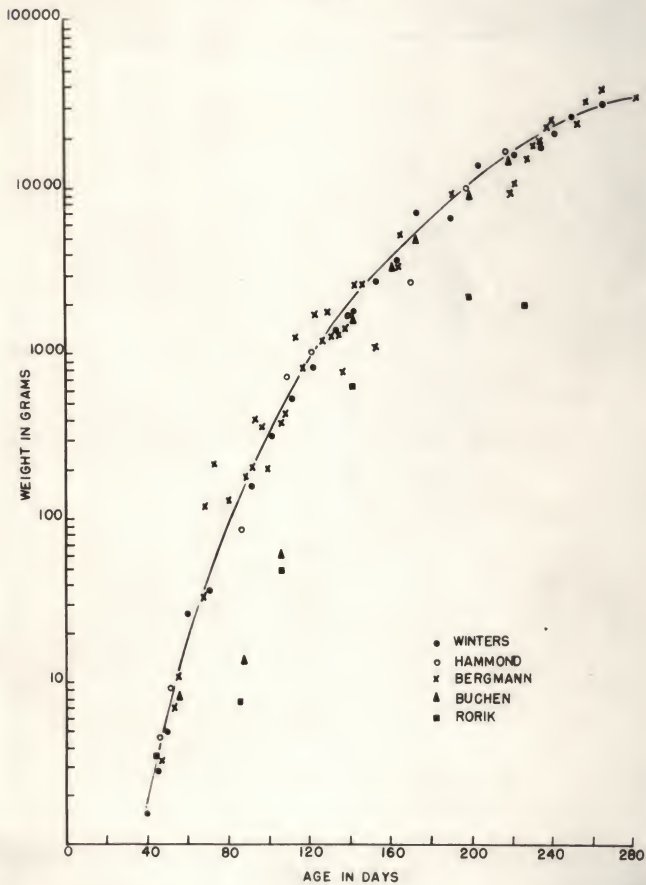
Prenatal development of the bovine. Minn. Agri. Exp. Sta. Bull. No. 151. 1942.

APPENDIX

EXPLANATION OF PLATE I

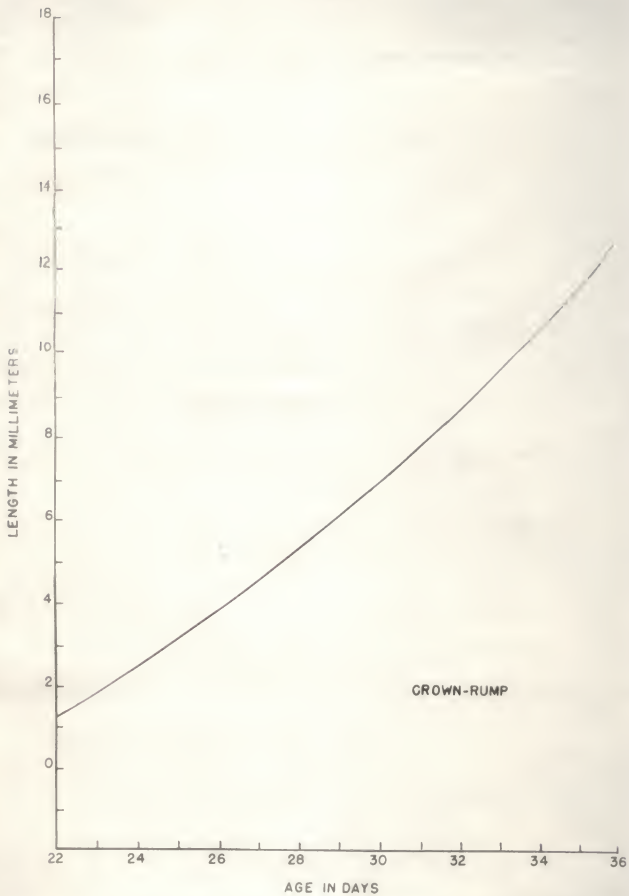
Compiled data by Maneely (1952) for weight of bovine embryos from five workers. The abnormal specimens by Rorik and Buchan were probably due to miscalculation of heat periods.

PLATE I



EXPLANATION OF PLATE II

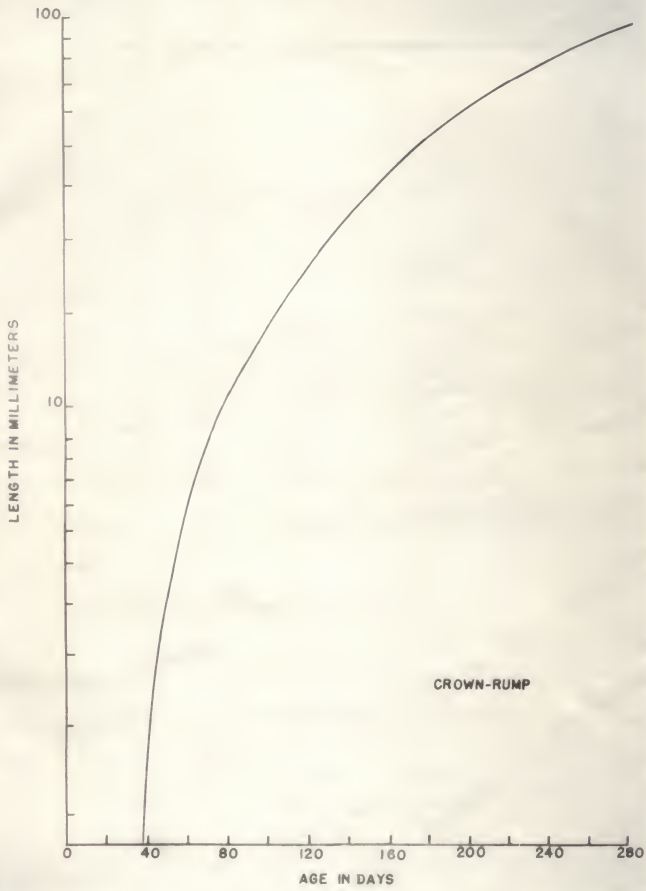
Crown-rump length for human embryos cited from Streeter (1948).



EXPLANATION OF PLATE III

Crown-rump length for bovine embryos cited from Winters, et al. (1953).

PLATE III

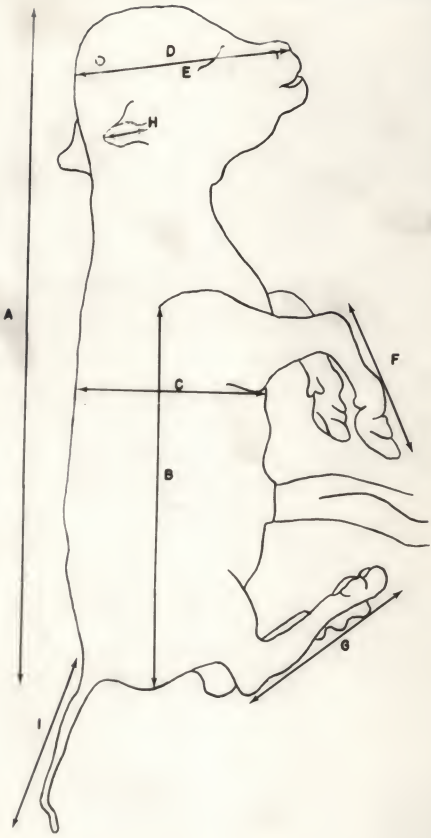


EXPLANATION OF PLATE IV

Diagram of bovine embryos to show linear measurements for both bovine and dog embryos:

- a. crown-rump
- b. trunk
- c. chest
- d. head length
- e. head width
- f. fore foot
- g. hind foot
- h. ear
- i. tail

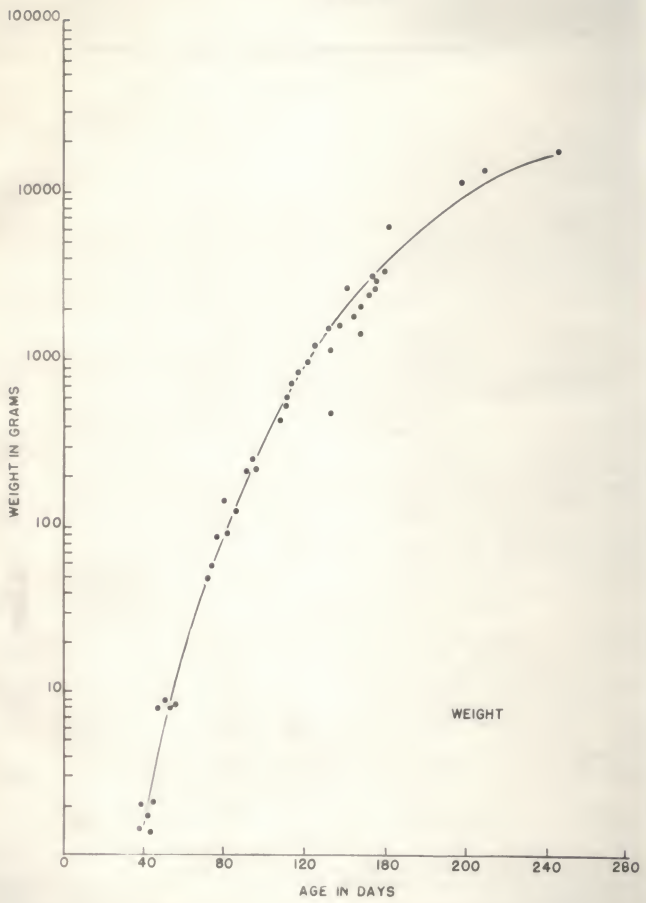
PLATE IV



EXPLANATION OF PLATE V

Weight curve for bovine embryos.

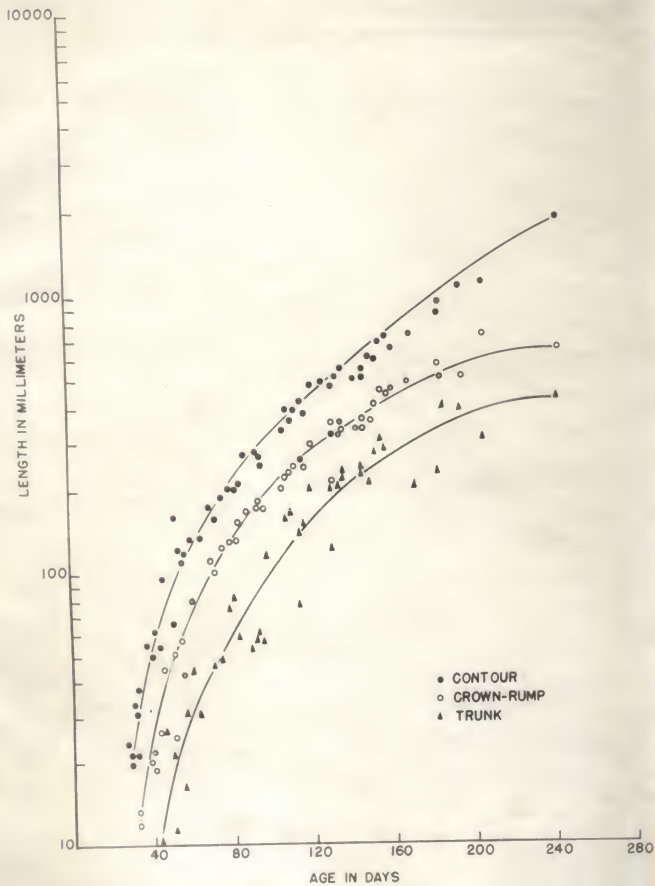
PLATE V



EXPLANATION OF PLATE VI

Contour, crown-rump, and trunk lengths of bovine embryos.

PLATE VI



EXPLANATION OF PLATE VII

Girth and chest curves from measurements of bovine embryos.

PLATE VII

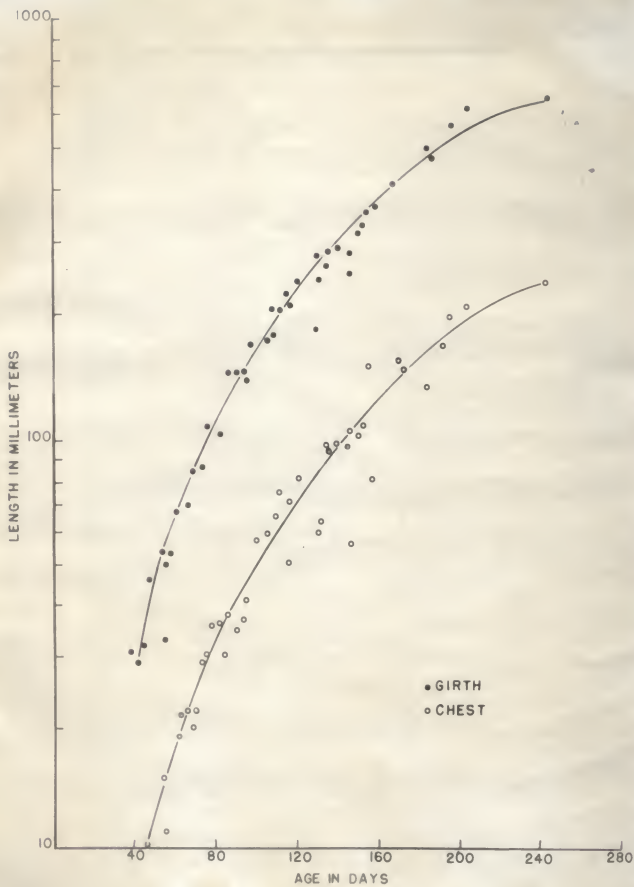
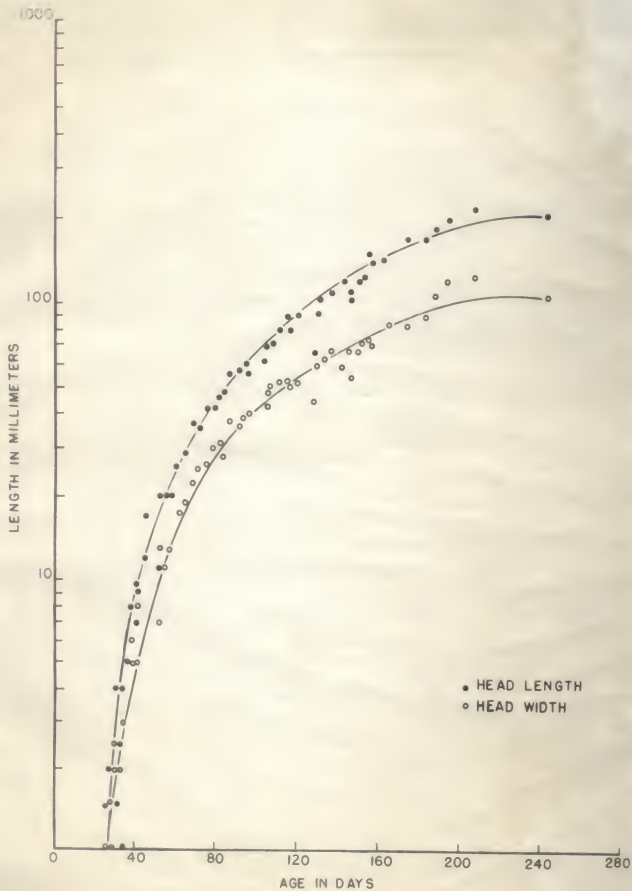


PLATE VIII
HEAD LENGTH AND WIDTH CURVES
FOR BOVINE EMBRYOS

EXPLANATION OF PLATE VIII

Head length and width curves for bovine embryos.

PLATE VIII

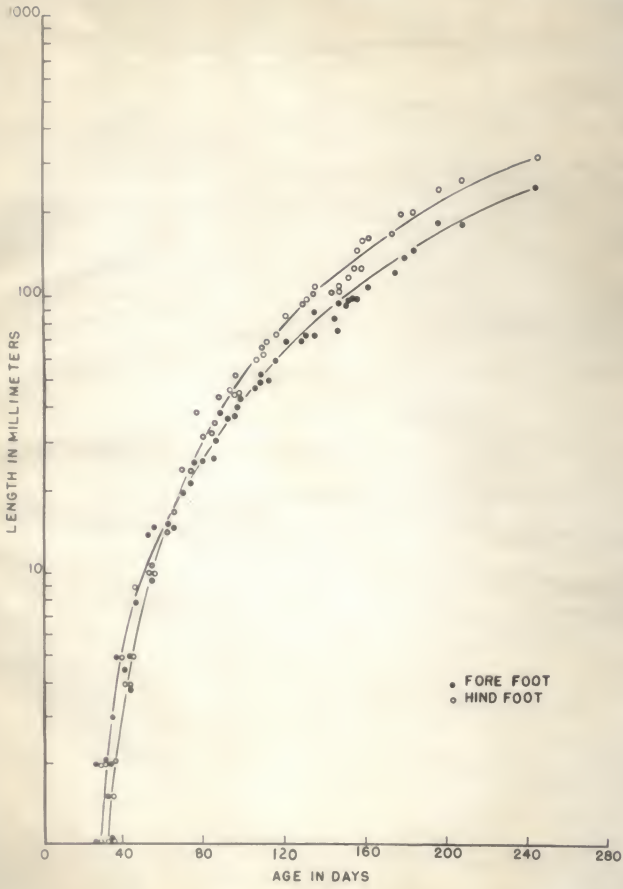


EXPLANATION OF PLATE IX

Hind and forefeet lengths curves for bovine embryos.

UNIVERSITY OF CALIFORNIA
LIBRARY
DIVERSITY
PLATE IX

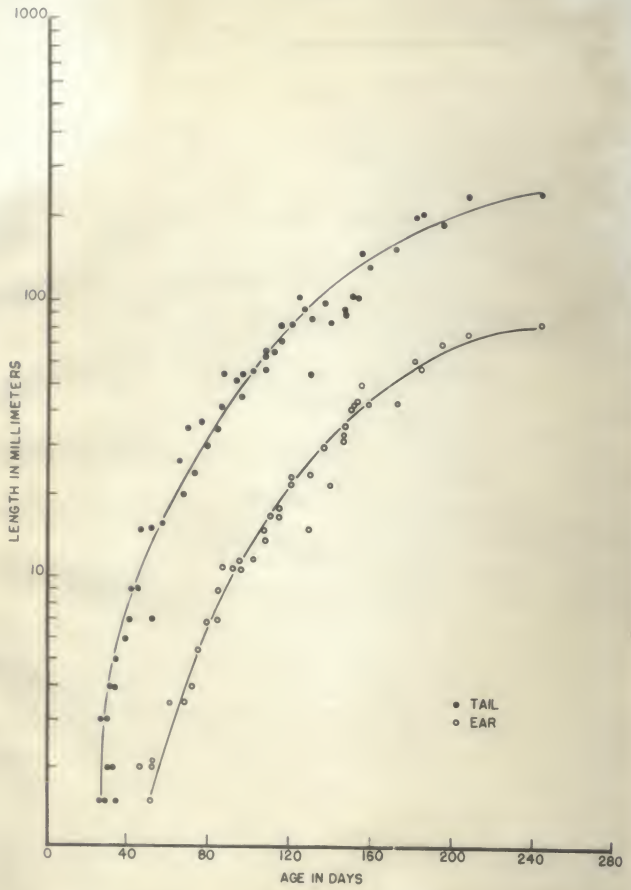
PLATE IX



EXPLANATION OF PLATE X

Tail and ear lengths curve for bovine embryos.

PLATE X



EXPLANATION OF PLATE XI

- Fig. 1. Dog blastocyst showing the inner cell mass.
- Fig. 2. Bovine blastocyst from Winters et al. (1953), p. 8, similar to Fig. 1.
- Fig. 3. Dog embryo showing closure of the neural tube, somites, and beginning of the folds.
- Fig. 4. Bovine embryo similar to Fig. 3, from Winters et al. (1953), p. 14.

PLATE XI

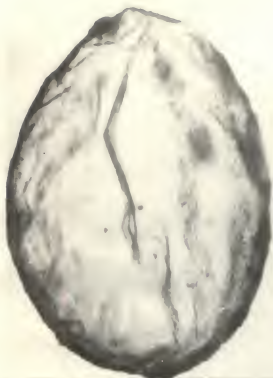

FIG. 1

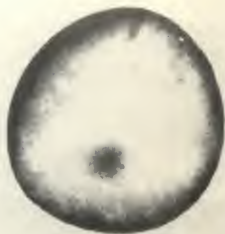

FIG. 2



FIG. 3

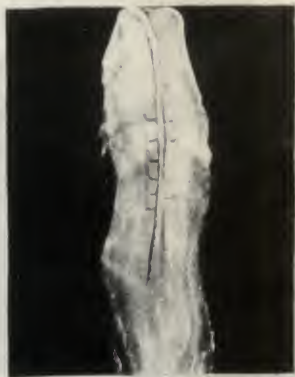

FIG. 4

EXPLANATION OF PLATE XII

- Fig. 1. Dog embryo about 25 days, showing development of flexures and pharyngeal arches.
- Fig. 2. Cow embryo still in amnion, 34 days of age. Similar to Fig. 1.
- Fig. 3. Dog embryo about 30 days. Toe rays, eyelids, and body wall are forming.
- Fig. 4. Cow embryo about 41 days at similar development as Fig. 3.

PLATE XII



FIG. 1

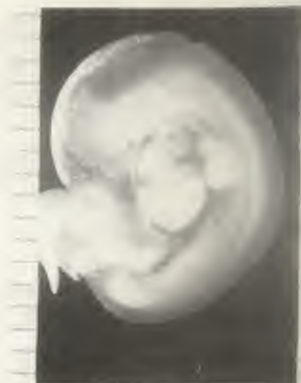

FIG. 2

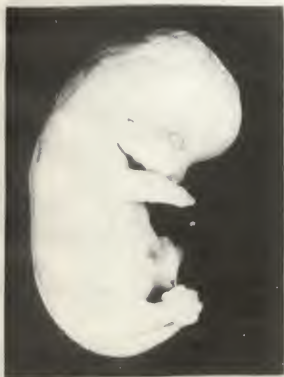

FIG. 3

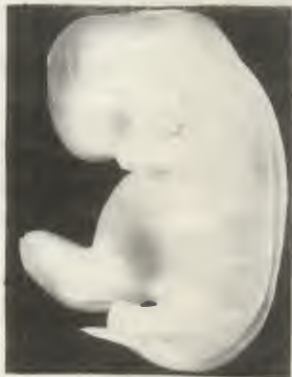

FIG. 4

EXPLANATION OF PLATE XIII

Fig. 1. Dog embryo about 44 days. Development of feet, ear and hair follicles appear over the body.

Fig. 2. Cow embryo about 79 days at a similar stage as Fig. 1.

PLATE X



FIG. 1

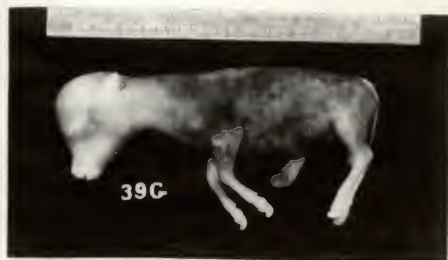
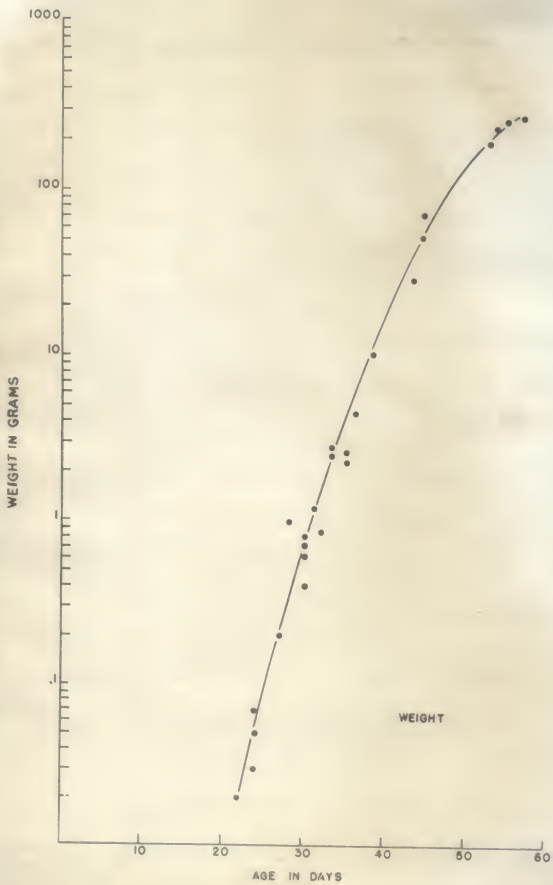


FIG. 2

EXPLANATION OF PLATE XIV

Weight curve for dog embryos.

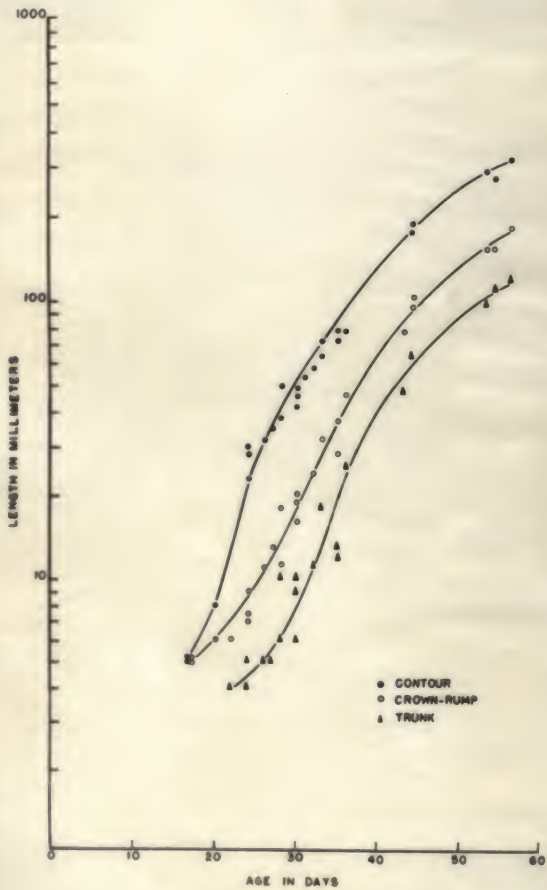
PLATE XIV



EXPLANATION OF PLATE XV

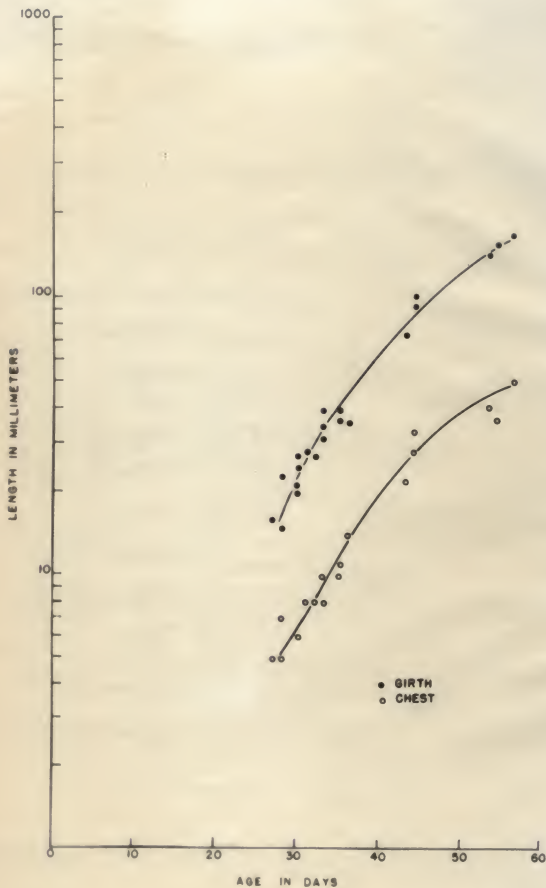
Contour, crown-rump, and trunk length curves for dog embryos.

PLATE XV



EXPLANATION OF PLATE XVI

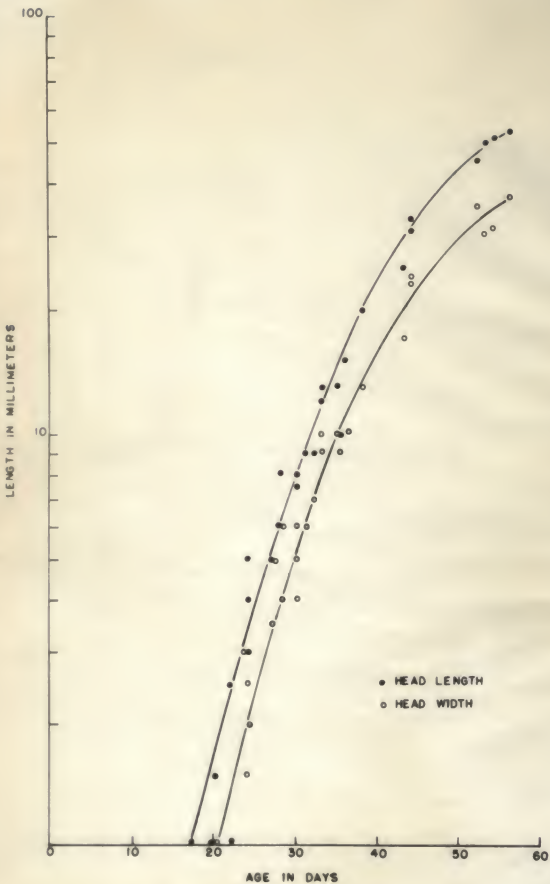
Girth and chest measurements curves for dog embryos.



THE UNIVERSITY OF CHICAGO
LIBRARY
540 EAST 57TH STREET
CHICAGO, ILL. 60637

EXPLANATION OF PLATE XVII

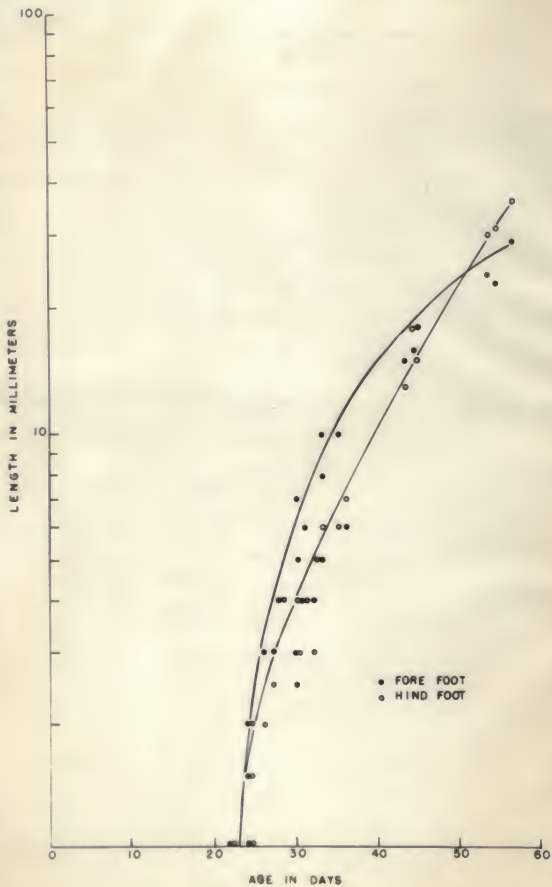
Head length and width curves for dog embryos.



EXPLANATION OF PLATE XVIII

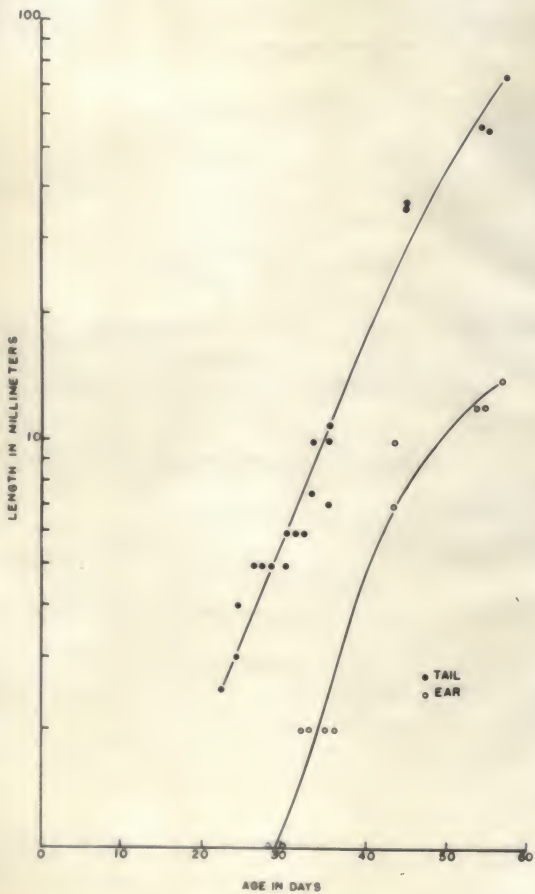
Lengths of fore and hind feet for dog embryos. Length of the fore foot exceeds the hind foot length until about fifty days.

PLATE XVIII



EXPLANATION OF PLATE XIX

Tail and ear length curves for dog embryos.



EXPLANATION OF PLATE XI

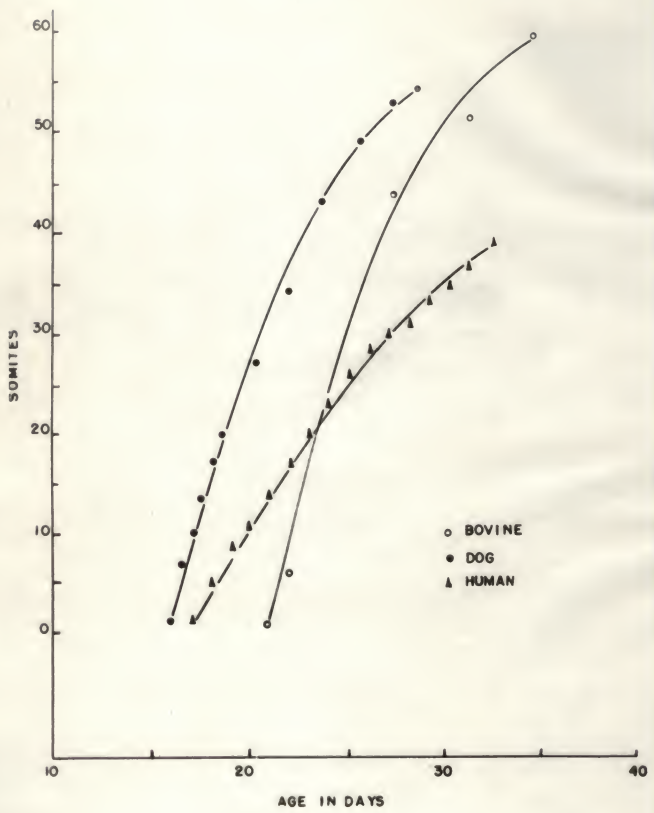
Number of somites plotted against time to show rate.

Number in dogs was counted from the series of embryos of known ages.

Cow series consists of a 20-day embryo in late pre-somite condition and a 22-day embryo (Winters et al., 1953) and three embryos with somite numbers nearing completion.

Human series from Patten (1946).

PLATE XX



A STUDY FOR CORRELATION OF STAGES
OF MAMMALIAN EMBRYOS

by

PATRICIA ANNE HENRY

B. S., Kansas State College of Agriculture
and Applied Science, 1956

AN ABSTRACT OF A THESIS

submitted in partial fulfillment of the

requirements for the degree

MASTER OF SCIENCE

Department of Zoology

KANSAS STATE COLLEGE
OF AGRICULTURE AND APPLIED SCIENCE

1958

A review of the literature was made for the rate of development in the human and bovine embryos. No such literature was available on the dog. Published descriptions of both human and bovine embryos were inadequate for comparison. A series of 60 bovine embryos and 50 dog embryos was studied and measurable characteristics plotted. A comparison was made in time of appearance and rates of development of: weight, contour, crown-rump, trunk, chest and girth, head length and width, fore and hind limbs, and ear and tail.

The weight curve was a typical growth curve from .1 to 250 grams in the dog in 40 days. One gram to 36,320 grams in the bovine in 260 days. In the human, from one gram to 3,100 grams in 265 days. Thus the curves differed only in pitch. The linear measurements essentially followed the same form of curve as established for weight, but the increase was slower. In all cases, available data on human embryos were inadequate. The development of the mammalian embryo was similar, in the three different species studied, during early embryogeny. The difference being in the rate of growth. The embryos had the same general appearance until the establishment of the face and differentiation of the appendages. As the embryos increased proportionally, there was a progressive regression in rate of development particularly noticed during the later part of gestation in the three species. The dog in 40 days, after the first appearance of the somites, had differentiated as much as the bovine in 200 days after the first somite formation and more than the human in 260 days. This occurred by differences in rate of differentiation and rate of growth, and was illustrated especially by somite formation and weight increase.