

COMPARISON OF FOUR TREATMENTS ON
FULL THICKNESS SKIN WOUNDS OF THE HORSE

by

Neal E. Woollen

DVM, Kansas State University, 1985

A MASTER'S THESIS

submitted in partial fulfillment of the

requirements for the degree


Master of Science

Department of Veterinary Pathology

Kansas State University
Manhattan, Kansas

1987

Approved by:



Major Professor

LD
21068
174
MNH
1967
W60
C. 2

Acknowledgements

I would like to thank Dr. H.W. Leipold, Dr. R.M. DeBowes, and Dr. R.A. Frey for their valuable guidance and support as committee members. I would like to thank members of the KSU equine surgery crew for their assistance. I would like to thank Mr. Duane Kerr, Mr. Frank Leatherman, and Mr. Lloyd Willard for their technical assistance. I would like to thank veterinary students Karen Eyer, Scott Shell, and Mike Cohn for their special interest and assistance. I would like to thank Dr. G.R. Clark for sharing his office and equipment. Finally, I would like to thank my parents for supporting me throughout my education, and a special thanks to Dr. Lew Ann Schneider for the extensive time and assistance that she put into this project.

TABLE OF CONTENTS

	<u>Page</u>
ACKNOWLEDGEMENTS	i
INTRODUCTION	1
LITERATURE REVIEW.	2
Inflammatory Stages	4
Debridement	5
Repair.	7
Maturation.	9
Endogenous and Exogenous Variables.	14
LITERATURE CITED	26
MATERIALS AND METHODS.	33
RESULTS.	37
DISCUSSION	45
SUMMARY.	46
FIGURES.	47
ABSTRACT	

Introduction

Every year hundreds to thousands of dollars are spent on wound dressings by equine owners and veterinarians. This money is spent with hope that such therapy will minimize healing time, minimize scar tissue production, and result in restoration of a strong surface continuity not subject to reinjury.

Despite the number of various therapeutic products and techniques available, there is a paucity of information that gives comparative guidance as to the strengths and weaknesses of these techniques. Little data is available to provide rational direction for the clinician's choice of wound dressings. Reliable information regarding histology of the healing wound does not address the effects of exogenous wound dressings or medicaments.

In this study it was not our intent to show a product comparison. It was our intent to provide comparative data of four basic approaches to treatment of full thickness skin wounds. The four therapeutic approaches were hydrotherapy, furacin cream, a furacin under wrap dressing, and a wrap with no cream.

Several articles define and describe the importance of wound contraction and re-epithelialization in wound healing. A well known hinderance to equine wound healing is the production of exuberant granulation tissue. These parameters are used to compare the different treatment techniques. Correlation of these parameters with histologic findings will also be addressed.

Literature Review

In man and other animals an intricate process, involving a variety of cells, renews injured tissue. The liver and surface skin layer are among the few mammalian tissues that can regenerate; otherwise man must rely on wound healing.⁷⁴

The process of wound repair differs little from one kind of tissue to another and is generally independent of the form of injury. Healing begins in the dermal layer when a clot is formed from post wound hemorrhage.⁷⁴

After clot formation, the damaged tissue produces substances that cause blood vessels in nearby uninjured tissue to leak. This fluid merely provides a sustaining environment for white blood cells that follow.⁷⁴

Fibroblasts later appear, and begin to repair the injury by secreting collagen and protein polysaccharides that form scar tissue. Scar tissue begins to form when the collagen molecules aggregate into fibrils. Synthesis of connective-tissue proteins then decreases and a process of remodeling takes place. It is this process that gives scar tissue its great strength.⁷⁴

As scar tissue renews the dermis the epidermal cells begin to close the surface.⁷⁴ Epithelial regeneration occurs simultaneously with the fibroplastic stage, and it begins within hours of the wound. The epithelium advances from each edge of the wound until it meets in the center.^{11,12}

Before discussing healing of skin wounds in more detail, we need to look at the anatomy of the organ being dealt with.

Skin is the largest and one of the most important organs encountered. It is derived from two embryonic germ layers, the epidermis from ectoderm and the dermis (corium) from mesoderm. Thickness varies from area to area within and between species. In the horse, skin thickness varies from 1.0 to 5.0 mm.^{13,44} The skins primary function is to protect the underlying structures from environmental temperature changes, dehydration, and penetration by bacteria, chemicals, and other noxious substances.^{44,65,87}

The epidermis is made up of a basal lamina and 5 stratified squamous cell layers. The 5 layers are divided into the stratum basale, stratum spinosum, stratum granulosum, stratum lucidum, and stratum corneum. Epidermal nourishment is derived, by diffusion of fluids, from the capillary beds in the reticular layer of the dermis.^{24,44} The stratum basale constitutes the deepest layer of the epidermis, and is responsible for the production of the cells that overlay, it.^{44,65,87}

The dermis (corium) can be divided into the papillary layer, which lies below the epidermis, and the reticular layer, which extends from the papillary layer down to the subcutaneous tissue.^{44,87,184} The 3 major cell types present in this layer are the fibroblasts, histiocytes, and mast cells.^{41,44,87} Fibroblasts are responsible for the production of Tropocollagen fibrils (immature collagen fibers) and elastic and reticular fibers. The histiocytes possess a phagocytic capability, and the mast cells are responsible for the production of heparin and histamine, which are released during injury to dermal tissues.^{44,65,87}

Wound healing is classically divided into separate, but continuous and overlapping, stages: the inflammatory stage, the debridement stage, the repair stage, and the maturation stage.^{44,88} In general skin restores its surface continuity by epithelialization, synthesis of dense connective tissue, and contraction.^{46,88} By the 5th to 8th day, fibroblasts from the subcutaneous tissue are active in connective tissue proliferation. This upward proliferation is met by downward proliferation from the papillary layer. Over this connective tissue proliferation, surface continuity is being restored by epithelialization aided by wound contraction.^{4,76,88}

Inflammatory Stages

Within limits, the inflammatory response observed follows a dose-response curve, which is usually dictated by the severity of the injury.^{44,69} It is characterized by a vascular and cellular response that protects the wound against excessive blood loss and invasion of foreign substances. This stage is thought to last from 0 to 6 hours after wounding. Of course, it can be prolonged depending on the degree of trauma.⁴⁴

Venule drainage, of fibrinogen and other clotting factors, tends to effectively block lymphatic drainage resulting in a very localized inflammatory response.^{16,88} The response can become less localized in the presence of fibrinolytic bacteria (i.e. streptococcus). These infections can prevent or cause dissolution of the lymphatic clots.⁸⁸

Ideally, there is enough hemorrhage into the area that the

resulting clot will hold the tissues together, fill the deadspace, and act as a framework for further healing. Excess blood in the area results in pain, ischemia (due to pressure), necrosis, and delayed healing.⁸⁸ It may also serve as a bacterial and nutritional medium for cells that will result in large scar formation.^{37,78,88} Contraction and dehydration, of the clot, results in scab formation.⁸⁸ Scabs offer limited protection from contamination, maintenance of internal homeostasis, and a protective layer under which epithelialization and contraction can occur.^{46,47,88} It is evident that they are helpful, but not a prerequisite to healing.^{88,74}

Debridement

This stage begins approximately 6 hours after wounding.^{44,46,47,88} Some feel the neutrophil is the first migratory cell followed by the monocyte.^{4,44,46,47,58,88} The presently more accepted theory is that the two cells migrate at the same time in the same ratio as they are found in peripheral blood. The short lifespan of neutrophils results in a later apparent increase in mononuclear cell numbers.^{16,44,61,69,88} These cells begin to function during this stage, however, they were chemotactically drawn to the area during the inflammatory stage.⁴⁴

Neutrophils are necessary to clean up infected wounds. Without infection, healing could progress without their presence.^{69,88}

Monocytes, however, are essential for wound healing. As macrophages they phagocytize dead and necrotic tissue and debris. They also attract fibroblasts. Some feel they have influential affects on maturation and maximal collagen synthesis.^{69,88}

This stage is also a vascular and cellular response, as was the inflammatory stage. The main goals now are to dispose of microorganisms, foreign materials, and devitalized tissue.⁸⁸ After the initial vasoconstriction, vasodilation occurs. Rounding up of endothelial cells results in increased permeability of capillaries and venules. Initially plasma escapes into the tissues with or without vessel wall gaps.^{16,46,69,88} The fluid contains enzymes, proteins, antibodies, and complement.⁸⁸ Leukocytes escape the vessels by way of the intracellular gaps, and by diapedesis and active movement they force their way through the basement membrane.⁸⁸ An immunologic response has also been proposed due to the presence of lymphocytes.^{16,88} During this stage purulent exudate may be seen, even without sepsis. It results from the lysis of dead neutrophils. Septic or nonseptic, pus will inhibit wound healing. Therefore, adequate wound drainage is essential to remove the associated protease and collagenase enzymes from the area of healing.⁸⁸

The key cell in wound healing appears to be the macrophage, which is responsible for a number of activities. It binds to attract more macrophages to the scene. It removes injured tissue and foreign debris. It is responsible for the trapping and elimination of infection, particularly if this is of a

persistent nature. It may provide the signal for neovascularization. It secretes lactate, which is bactericidal, and may well "activate" fibroblasts to undergo division and synthesis.⁸² It is not difficult to see that the macrophage is truly a multipotential and necessary component of wound healing.

Repair

This stage consists of fibroblast proliferation, capillary infiltration, and epithelial migration. The process is assisted by wound contraction.^{46,88} It begins almost immediately. Most of the debris is usually removed by the 3rd to 5th day. A characteristic of this stage is the formation of granulation tissue. It is recognized as fibroblast proliferation and capillary infiltration.⁸⁸

Fibroblasts move into a wound by advancing along fibers of the clot.^{16,58,69,88} They also migrate along infiltrating capillaries.^{58,87} They follow a ruffled membrane until they encounter another fibroblast. By contact inhibition cell migration ceases. If the fibroblast still has a free edge, it will send out another ruffled membrane, the cell adhesion will break, and it will move in a different direction.^{1,61,69,76,88}

Fibroblasts appear in the wound at approximately the third day, and they multiply from day 14 to 21.^{69,88} Initially, the collagen is laid down in a vertical pattern. At the 6th day the orientation of the fibers changes gradually to a pattern parallel to the surface. Formation of the collagen begins on day 4 or 5 by the fibroblasts.⁸⁸ Eventually a balance between collagen

synthesis and destruction is met. Fibroblast numbers decrease as collagen production becomes sufficient.⁸⁸ Collagenase is being produced by proliferating epithelium and fibroblasts that come in contact with the new epithelium.^{46,67,88} There is apparently no regeneration of elastin fibers. Their lacking presence in scar tissue explains its lack of elasticity.⁸⁸

There are two theories concerning fibroblast origin. One opinion is that all new fibroblasts come from precursor cells in the bone marrow, which may emerge from the vasculature as monocytes. The opposing theory is that all new fibroblasts originate locally, and are probably derived from the perivascular pleuripotential mesenchymal cells. The balance of the theory is now that the second one is correct.⁸²

Neovascularization is a prominent feature of all forms of connective tissue growth, and is an important feature in wound healing. New vessels arise from pre-existing endothelium in the adult and originate as capillaries. Later the capillaries become modified into arterioles or venules. Presumably there is some chemotaxis or other attraction between endothelial cells that helps guide them to join their fellows.

Vascular regeneration is a delicate process that can easily be stopped by various chemical or physical agents. Histamine, radiation, and excess bandage pressure have been incriminated. Lymphatic vessels regenerate in much the same way as capillaries.

Epithelialization is actually the first sign of repair, and is recognized at about 12 hours post wounding. It is evidenced by

a flattening of the rete pegs of the epidermis.^{44,69} This flattening forces adjacent cells toward the wound edges. Simultaneously, the basal cells of the epidermis begin to separate, duplicate, and migrate toward the area of cell deficit.^{44,69} Some of the new cells near the edge of the wound loosen their attachment to the basement membrane and migrate across their fellow on to the wound surface, but they stop moving before losing contact with the last fixed cell. Another cell then leapfrogs over the previously migrating cell and so forth. Under normal circumstances epithelial cells do not wander freely in tissue; they always maintain contact with the last cell in line.⁸² However, it has been reported that some cells do migrate independently to the center of the wound.

The repair stage is generally considered to last for 2-4 weeks.⁸⁸

Maturation

This stage is signaled by a decrease in fibroplastic activity to a rate that equals collagen destruction⁸⁸ As stated earlier collagenase is produced by fibroblasts and epithelial cells. It is also produced by white blood cells.⁸² Collagen content stabilizes at 3 weeks. Fibrils increase slightly in thickness and compactness and tend to become grouped into bundles that present a whorled appearance. Wound strength is due to increased inter and intramolecular cross-linkage of collagen fibers⁸⁸

There is an early rise in wound tensile strength followed by

a slower increase that takes place over a long period of time. This correlates with increased collagen deposition and subsequent maturation and remodeling. Based on hydroxyproline concentration, a rapid increase begins on day 4 with highest rate occurring between day 5 and 12, lesser rate between day 12 and 21, markedly lower rate between day 21 and 60, and an imperceptible gain occurs for 2 years. Scar tissue never reaches the strength of skin or fascia.⁸⁸ Only 80% of the original tensile strength is reached at one year.^{44,87}

When fibroblasts are active in wounds they produce Type III collagen and this is subsequently removed or modified and replaced by Type I collagen over a period of weeks or months. In the horse replacement is relatively slow and scars, especially in tendons, show persistent Type III collagen for periods up to 15 months.⁸²

Granulation tissue makes its appearance in a wound by days 3 to 6. It consists of capillary loops growing into the wound from endothelium of the cut capillaries. These loops grow at a rate of 0.4-1.0/mm/day.⁸⁸ They grow behind the fibroblasts and form multiple anastomoses.^{44,87} Vascular endothelial cells that migrate into the wound contain plasminogen activators responsible for fibrinolysis of the fibrin network.^{16,44,46,61,69,87,88} A granular appearance develops on the surface resulting from raised capillary loops being surrounded by fibroblasts, macrophages, and other wandering cells.⁸⁸ Lymphatic migration occurs similar to but a little later than capillary migration.^{44,88} When healthy, granulation tissue is red, firm, flat, and

non-exuberant.⁸⁸ Wound healing realizes four benefits from its presence. It is resistant to infection. Epithelium migrates over it. The mechanism for wound contraction may center in it. And, fibroblasts necessary for collagen synthesis are supplied by it.

In some individuals, collagen synthesis and epithelial cell growth appear to be out of balance, since there is a very frequent occurrence of excessive production of granulation tissue. Once granulation tissue has proliferated above the surface of a wound the epithelium forms an inactive ring around the base. This so-called "proud flesh" occurs in all species but it is a well known problem in the horse.⁸²

It has been accused of being due to collagen deposition exceeding capillary formation, and it appears as dusky unhealthy tissue.^{69,88}

Wound contraction is a cellular process, rather than fibrous.⁵⁹ Wound size is reduced as a result of full thickness skin movement toward the wound center.^{44,69,88} A hybrid myofibroblast is responsible.⁵⁹ The theory that peripheral fibroblasts migrate inward pulling on the wound margin has not been disproven, but the myofibroblast in granulation tissue theory is more accepted. Also there is pharmacologic evidence that these cells have smooth muscle properties.^{60,88}

Myofibroblasts are found free in the connective tissue space without a plasmalemma and have a well-developed system of rough endoplasmic reticulum, both features characteristic of fibroblasts. In addition myofibroblasts possess deeply indented nuclei, a highly developed system of cytoplasmic microfilaments,

dense bodies, and desmosomes, all features typical of smooth muscle cells.⁵⁹ Other smooth muscle properties include surface differentiations adapting them for cell-to-cell and cell-to-stroma attachments, demonstration of immunofluorescent labeling of their cytoplasm with human antismooth muscle serum, and reaction to smooth muscle stimulants and inhibitors.^{60,88} They have also been shown capable of collagen production.^{69,88}

Literature points out a lag period for contraction, but there is a lot of variance in the number of days. One source reports a 2-3 day latent period with 30% reduction in wound size by 10 days.⁶⁰ Contraction ceases due to contact inhibition, skin tension that equals or exceeds contraction force, or a lack of myofibroblasts.⁸⁸

Contraction is a naturally occurring phenomenon that greatly facilitates management of large skin defects, and results in animal scarring.⁸⁸ Animals with a well developed cutaneous striated muscle and large areas of mobile skin are very tolerant to contraction without subsequent deformity.⁸⁸

Epithelialization is labeled as the first sign of healing. It can occur before connective tissue regeneration.^{69,88} An open wound that fully penetrates the dermis needs a layer of granulation tissue before it can occur.^{4,79,88} Migration often follows a 4 or 5 day latent period. It is then rapid, slowing considerably as the margin becomes a monolayer. For approximately 8 days epithelial cell layers multiply at the margin preparing for migration, thus a reservoir of cells is ready.^{76,88} Rate of epithelial migration is variable. The work of Walton and Neal (1972) has been cited, reporting a rate of

0.2/mm/day in the flank and a rate of 0.09/mm/day on the lower limb.⁴⁴ Epidermal epithelial mitosis has a diurnal rhythm, being greatest during rest and inactivity.^{69,88} Cells migrate in a monolayer; further back mitosis, upward migration, and stratification are occurring. Differentiation and keratinization occur in thickened areas. Hyperplastic thickening occurs at the original wound edge.^{46,69,88} Cells can also come from newly developed stratum spinosum.⁸⁸ At 10-12 days prominent downgrowth occurs and is complete at 17-21 days, producing pseudorete pegs of epithelial spurs. In dogs these regress until day 36. This regression leaves a smooth undersurface that leaves the new epidermis easily traumatized. In addition to regression, separation can occur resulting in internally keratinized epithelial pearls, nests, or islands.⁸⁸ Moist environments tend to enhance epithelialization.²⁰ The process follows a contact guidance and inhibition process, it shouldn't stop until surrounded on all sides by epithelium⁸⁷

Sometimes the process stops prematurely.^{31,88} This results in a partially contracted and epithelialized wound with a center of granulation tissue. Several factors can be responsible: infection, mechanical damage by repeated dressing changes, inadequate O₂, and extreme hypothermia.

The healed surface lacks adnexal structures of normal skin and is referred to as scar tissue epithelium.⁴⁴ However, research with rabbits has shown that adnexal neogenesis can occur after surface epithelialization is complete. Epithelial buds mature into hair follicles and their associated sebaceous glands.^{10,46,50,68,}

69,76,88 Hair along wound margins may grow in thicker. This results from hairs that are cut leaving undamaged bulbs in site. Areas of damaged bulbs will result in alopecia.

Endogenous and Exogenous Variables

Up to this point we have reviewed the normal principles involved in restoring integrity to full thickness skin wounds. Variables may interact to either enhance or delay the processes already discussed.

Lets first discuss endogenous factors affecting wound healing. Increase in animal age slows healing due to decreased fibroplasia. Anemia, primarily hypovolemic types, are responsible for delayed wound healing. This is due to a decrease in tissue perfusion and a decrease in oxygenation.⁸⁸ Wound oxygenation probably qualifies both as an endogenous and exogenous factor. However, we will discuss it here.

Oxygen is necessary for cell migration, cell multiplication, protein synthesis, and collagen synthesis.⁶⁹ Fibroblasts can synthesize collagen only within about 60um of an intact capillary, and they require a pO_2 level of 15-30 mm mercury. Therefore, collagen synthesis depends on rate of neovascularization.⁸⁸ Following a wound there is a marked gradient of O_2 within the wound, the center being most deficient. It is theorized that this deficiency stimulates neovascularization. Support of the theory comes from normal O_2 levels following neovascularization.⁸⁸ Anything that improves O_2 transport to tissues should promote

healing. Mild acidification of a wound may substantially hasten healing by enriching the supply of oxygen to the tissue.⁵⁵ Dr. Stoner of Squibb Animal Health Division states, "It is possible that normal wounds would get ample oxygen from the blood."⁸⁶ However, atmospheric oxygen availability is important for acceleration of healing.

Denervation, for unknown reasons, has been associated with increased collagenase activity in the dermis, thus retarding healing.^{69,88} Also known to delay healing is dehydration and edema. Moderate edema has little or no effect, and marked edema has a slight and temporary inhibitory effect.^{69,88} Patient condition whether it be nutritional deficiency, dehydration, endocrine imbalance, and cardiac, renal, or liver disease can complicate and delay healing.⁴

Movement acts as a mechanical disturbance. Wound edge movement can rupture new capillary sprouts, disrupt organizing reparative cells, and disturb the growth pattern of new fibers. The disturbance may lead to excess collagen deposition.^{76,89}

Wound fluids have been labeled as ideal culture medium that would increase chance of infection.⁸⁹ Investigators have shown a heat labile bactericidal activity in blood and serum. Two theories exist as to its origin. It has been labeled as a serum protein in the properdin system, and also as antibody in the presence of complement. Gram-negative bacilli showed the greatest susceptibility. Blood serum from mammals also has shown heat stable antimicrobial activity against a variety of bacteria. These active substances are called beta-lysins. Gram positive organisms

are the most sensitive.^{76,88} A study showed a bacteriostatic or a weak bacteriocidal effect by wound fluids against *Staphylococcus aureus*, and striking antibacterial activity against *Escherichia coli*. The effect of blood sera was not as marked. Human thoracic duct lymph has shown complement dependant antibacterial activity. Leukocytes in wounds have also shown bactericidal activity.^{16,89} Despite the positive aspects noted, fluid accumulation in dead spaces of a wound is still not advised.⁸⁹

Now we'll take a look at the exogenous factors that affect healing. Due to caring and well meaning owners and veterinarians, this becomes the largest group of factors. Whenever a wound occurs, we have to do something to it. There also are many environmental factors that affect wounds.

Anabolic steroids are alleged to increase the rate of healing. They do stimulate protein synthesis, thus the inference that they also stimulate wound repair.^{76,88} Anti-inflammatory drugs such as phenylbutazone, indomethacin, and aspirin are shown to affect wound healing. A study on horses showed significant reduction in inflammation and granulation tissue formation when oxyphenbutazone was given for 7 days.⁸⁸ Chronic stress or repeated high level doses of steroids, especially if given just prior to or at the time of injury, may inhibit wound healing. All processes occur but at a slower rate.^{61,69,88} Acute stress or a low dose of cortosone has no effect on healing.^{68,69,88} Epinephrine, as an adjunct to local anesthetics, can be deleterious due to its vasoconstrictor qualities.^{27,89} Electroincision wounds are bloodless but surrounded by devitalized tissue.^{27,89} It is

recommended that debridement is conducted by sharp scalpel.^{27,43}
57,89 A study has shown wound strengths are significantly
stronger following sharp blade incision vs. electroincision.⁸⁹

Wounds will not heal until foreign bodies are either extruded
or removed.^{69,88} Contamination can come from soiling during
injury and from in-hospital contaminations.^{2,89} Whether an
organism is a contaminant or a pathogen depends on what
happens to the host tissue in response to their presence. A
contaminant becomes a pathogen when infection occurs.^{15,89}
Pasteur stated, "The germ is nothing, it is the terrain in which
it grows which is everything."¹⁵ A locally effective blood supply
is a very important natural defense mechanism against infection,
and damage to a tissue's blood supply greatly favors the
development of infection.^{15,27,89} The generally accepted critical
level of bacteria within a wound is 10^5 bacteria/gram of tissue
or ml of fluid. Beyond this level infection occurs, and the
bacterial count must be at this level or below before a delayed
closure or graft will be successful.^{71,89} Wounds with excessive
soft tissue damage are more susceptible to infection than
incisions made by sharp instruments.^{27,89} Excising devitalized
tissue will enhance healing by exposing the wound margins to
viable tissue with a good blood supply.⁸⁹ Surgeons have been
more concerned with the nature and control of bacteria rather
than with the management of the tissues. Thus, a dependence on
bacteriostatic and bactericidal agents rather than the body's
natural defense mechanism has developed.^{15,89}

To assist the healing process, and prevent contamination

from becoming infection, we practice many principles all in the hope of reducing bacterial numbers. Lavage is a technique whereby irrigation floats away debris and separated tissue particles, in addition to either removing, diluting, or reducing the number of bacteria.^{21,89} A study has shown that increasing the volume of irrigating solution decreases the incidence of infection. The addition of antibiotics exposes surface bacteria that are not washed away.⁸ It has been stated that wound lavage significantly increases in incidence of infection when compared to lavage at 1 hour. The incidence was lowered by first freshening the wound edges before saline irrigation.^{70,89}

Successful decontamination by lavage seems to rely on the pressure that irrigating fluids are delivered under.^{64,89} Heavily contaminated wounds need increased pressure to remove sufficient numbers of bacteria to prevent infection.^{74,89} A study has shown that fluids disseminate into adjacent tissues, but bacteria did not accompany the fluids. They were apparently filtered by surface tissues. Some tissue injury does occur. However, this is outweighed by the superior cleansing.⁸⁹ The water pik has been shown to be 3 times more effective than a bulb syringe in removing tissue fragments and seven times more effective in removing bacteria.^{43,89}

Soaps and detergents are generally accepted as damaging to tissues.⁸⁹ They cause delayed healing in wounds with muscle tendon, or blood vessels visible.^{49,89} The harmful effect they have on cartilage, synovia, and other soft tissues may lead to susceptibility of infection, poor wound healing, and loss of joint

function.^{32,89} Even surgical scrub is more damaging than helpful. The detergent compounds are toxic to tissues and impair their defenses.^{22,72,89} Pluronic F-68, a poloxalene polyol, has no antibacterial activity but will protect tissues from the abrasiveness of sponges. Combined with elemental iodine it becomes a cleansing agent with antibacterial properties and no side effects.^{72,89}

Disinfectants usually cause deep tissue injury delaying cell division and vascularization, with delayed healing time to twice the normal length of time.^{14,89} Hydrogen peroxide is beneficial from the standpoint of its mechanical foaming action, but microvascular blockage may occur.^{14,43,89} A 25% solution of povidone iodine is recommended for wound irrigation.⁸⁹ A 1:100 dilution in distilled water produces only very slight microscopic reaction.^{14,89} Povidone iodine is not without advantages; it controls sepsis and may augment wound healing, it has a broad antimicrobial spectrum and is effective in the presence of blood, pus, serum, and necrotic debris, it has no untoward effects when used on mucous membranes or conjunctiva, and its brown color acts as an indicator.^{23,89} Chlorhexidine has good antibacterial activity as well as being effective against dermatophytes.^{52,89} Reports show that it is nonirritating to wound tissues, and animal wounds have been reported to heal quickly when exposed to it.^{89,91} Single irrigation of contaminated wounds with 70% ethyl alcohol, benzalkonium chloride, 0.25% chloramine-T, aqueous iodine, povidone iodine, or gentian violet has overwhelmed bacteria with minimal tissue damage.^{25,89}

There are differing opinions with regard to wound scrubbing. It is said to be beneficial by removing bacteria and disrupting the fibrous coagulate covering.^{26,89} Others say that it impairs the wounds ability to resist infection, being directly proportional to the coarseness of the sponge.^{25,89} Infection rate has been shown to be significantly less, when used with pluronic F-68.^{72,89}

Chemical debridement is described as being nondiscriminatory. Viable cells may be damaged in conjunction with the removal of the nonviable tissue. This damage may lead to separation and delayed wound closure.^{5,89} Powder forms may lead to excessive dehydration.⁸⁹

Enzymatic agents are indicated under two conditions. One is if the patient is a poor anesthetic risk, and the other is if surgical debridement could result in injury to vital tissue.^{78,80,80} They assure healthy tissue and granulations will not be disturbed.^{80,89} However, they are expensive, time consuming, and insufficient in debriding action.^{43,89}

Infection is the one thing we hope to avoid. It delays wound healing by mechanically separating wound edges with exudate.^{4,88} Hyaluronidase, collagenase, fibrinolysine, coagulase, and hemolysin are all enzymatic toxins produced that delay healing.^{3,4,88} Enzymes affecting oxygen carrying capacity of hemoglobin are also produced.^{3,88} The wound is considered infected when bacterial concentration reaches 10^6 /gram of tissue.⁸⁸

Predisposing factors to infection include poor blood supply,

tissue injury, contamination, deadspace with fluid accumulation, foreign bodies, dehydration, shock, malnutrition and hypoproteinemia, exhaustion, uncontrolled diabetes, anemia, systemic steroids, irradiation and cytotoxic drugs, tissue tension, and poor surgical technique.^{15,27,34,57,89}

Factors that increase resistance to infection are correction of above problems, early ambulation, primary or delayed closure, and time.

In 1955, Metzger and Prigot proposed a theory for antibiotic use in wound treatment. It stated that topical therapy must be considered an adjustment to the routine management of wound infections and not a replacement mechanism. For maximum benefit, topical therapy should be used in conjunction with mechanical or chemical debridement or both.^{63,89} An agent should be chosen that has little or no effect on host cells, but still has antibacterial capabilities.^{34,89} Hydrophilic ointments are disadvantageous because they liberate the antibiotic slowly, which reduces its effectiveness. The ointment may also provide an environment for anaerobic organism growth.⁶² With proper debridement this has not been a big problem.⁸⁹ Powders reduce tensile strength and cake up causing a foreign body reaction.^{6,89} Both powders and ointments will hinder debridement and lavage if placed into the wound prematurely.⁸⁹ Aqueous solutions are preferred.⁶² Bacitracin, polymyxin-B sulfate, and neomycin sulfate are all bactericidal. They also pose minimal hazards at the time of administration or subsequently.⁸⁹ Pseudomonas has been shown to pose special problems in both man and animals.^{67,}

⁸⁹ These infections are successfully treated with 0.1% gentamicin sulfate ointment.⁸⁹ DMSO has been reported to potentiate topical antibiotics.⁴² Infection was prevented in feces contaminated wounds by lavage with 1% kanamycin and 1% neomycin.⁸³

Topical antibiotics have no effect on progressive tissue necrosis caused by proteolytic enzymes or on hemotoma and dead tissue dissolution. Nor can they sterilize dead tissue. They should be used only to limit invasive infection and to protect against septicemia.^{21,89} Time is important. They have little effect once the bacteria has invaded the tissue, and the wound is classified infected.⁸⁹ To be effective, immediate application is necessary.⁶²

Systemic antibiotics have shown differing effects. Penicillin did not effect wound strength.⁷⁰ Intravenous chloramphenicol inhibited healing.¹⁹

Insulin is shown to have beneficial effects when applied topically.^{7,29} Being an anabolic hormone, it should increase metabolism and protein synthesis, and thus the cell multiplication rate. Harper reports that insulin acts to increase uptake (by tissues) of amino acid, glucose, nucleosides, potassium, and phosphate.^{29,37} Its use topically has shown no side effects.^{7,29} Effectiveness has not been altered, even in the presence of bacteria.⁷ The initial action of insulin is enzymatic and then hormonal. Clinical evidence indicates that insulin in a cream base normalizes cell permeability, increases vascularization, reduces exudation, arrests bacteria, enhances phagocytosis, stimulates proliferation, decreases tissue hypoxia, eliminates

edema, and increases wound contraction.⁷ The most effective concentration is 30 units per gram of base.⁷

Bandaging is a controversial subject. Occlusive dressings are said to speed the healing process.^{88,94} They benefit migration rather than mitosis.⁷⁹ Preventing wound desiccation is considered a major benefit.^{31,88} Epithelial migration is more rapid between two surfaces (i.e., scab, nonadherent dressing), rather than over one.⁶⁸ Adherent dressings are detrimental. A layer of epithelial cells is usually removed with each bandage change. Research has also shown an increased incidence of exuberant granulation tissue under both wraps and casts.³³ In contrast, many colleges of veterinary medicine are teaching that pressure wraps and casts will help minimize exuberant granulation tissue.

Nutrition has already been labeled as an endogenous effect on wound healing. Now we'll look at some specific nutritional factors involved.

Protein deficiency is deleterious due to a lengthened repair stage. It is responsible for lowering number and activity of fibroblasts, slow collagen development, with reduced tensile strength. This allows wounds to disrupt more readily.^{4,57,58,66,69,76,88} Patient starvation has been reported to cause a failure of collagen production in granulation tissue. High protein diets have been shown to increase both rate of healing and finished strength.⁶⁶ Supplementation of methionine and cystine will return the lag phase to normal with increased fibroplasia, in protein depleted animals.^{4,39,57,58,61,69,76,88}

Vitamins A, B, E, K, and C all have a role in wound

healing. Vitamin A is essential for epithelial health.^{57,88} It also has the ability to override membrane stabilizing effects of vitamin E and corticosteroids.^{69,88} Vitamin B is needed for normal cellular and enzymatic functions. It also is utilized in carbohydrate metabolism.^{39,57,88} The membrane stabilizing property of vitamin E retards healing. Collagen production is also slowed by it.^{69,88} Blood clot formation is dependent on adequate levels of vitamin K.^{57,88} Epithelial regeneration as well as vessel wall formation rely on vitamin C.^{56,88} However, its main function lies in collagen production. Due to body loss of ascorbic acid during surgery and stress, vitamin C supplementation may be advised after wounding or before surgery.^{3,10,79,88} Vitamin A has also been shown to stimulate fibroblasts and accelerate local collagen accumulation in wounds.³⁰

Zinc, an essential element to all animals, has an influence on healing. It is known that slight to moderate deficiencies can retard growth, lower feed efficiency, and inhibit general well being.⁸⁸ Zinc levels are subject to change. Levels rely on stress and traumatic conditions.^{69,88} Deficiencies affect healing by decreasing wound tensile strength and decreased DNA activity, resulting in a lack of epithelial and fibroblast proliferation.^{69,88} High levels of zinc interfere with collagen cross-linking by antagonistic effects on copper in lysyloxidase synthesis. This enzyme is necessary for cross-linking of collagen. Lysosomal enzymes and cell membranes may be stabilized by it, and high levels have been shown to immobilize macrophages.^{69,88}

The ultimate goal in wound healing is the finished scar. It

should be minimal and cosmetic as possible. Wound shape has been labeled as an important factor in the pattern of wound contraction.^{44,69,87,88} This takes on importance due to the fact that the more contraction a wound experiences results in a lesser scar. Rectangular and square wounds will contract to form 4 point stellate stars. Triangular wounds result in a 3 point star. Circular wounds are unpredictable and result in a crumpled uncosmetic appearance. Also, contraction is about 30% slower than square, rectangle, or triangle wounds.^{44,87,88}

Literature Cited

1. Abercrombie, M. 1957. The directed movements of fibroblasts: A discussion. Proceedings of the Zoological Society of Calcutta: The Mookerjee Memorial Volume. pp. 129-1400.
2. Altermeier, W.A., and Gibbs E.W. 1944. Bacterial flora of fresh accidental wounds. Surg. Gynecol. Obstet. 78:164.
3. Altemeier, W.A. 1970. Wound healing in surgery. Proceedings of A Panel Discussion. Somerville, NJ, Ethicon Inc., p. 5.
4. Archibald, J., and Blakely C.L. 1970. Basic procedures and preoperative considerations, in Archibald, J. (ed.): Canine Surgery, ed. 2. Santa Barbara, Calif., American Veterinary Publications, Inc., pp.22-24.
5. Archibald, J., and Blakely C.L. 1974. Basic procedures and preoperative considerations, in Archibald, J. (ed.): Santa Barbara, Calif., Canine Surgery, ed. 2. American Veterinary Publications, Inc., pp.17-106.
6. Baker, C.E. 1978. Physicians's Desk Reference, ed. 32. Oradell, N.J., Medical Economics Co.
7. Belfield, W.O., Golinsky, S., Compton, M.D. 1970. The use of insulin in open-wound healing. Veterinary Medicine/Small Animal Medicine. May pg 455-460.
8. Bergman, A. 1983. Honey for wound healing. Veterinary Medicine/Small Animal Clinician, Medical Briefs. December. Pg. 1821-1822.
10. Bertone, A.L. The effect of zyderm collagen implant on exuberant granulation tissue formation in the horse. Unpublished.
11. Bojrab, M.J. 1981. A handbook on veterinary wound management. chapters 1-7.
12. Bojrab, M.J. 1982. Wound management. Modern Veterinary Practice. October. Pg. 791-874.
13. Boyd, C.L. 1967. Equine skin autotransplants for wound healing. JAVAMA. 151:1618.
14. Branemark, P.I., Ekholm, R., Albrektsson, J., etal. 1967. Tissue injury caused by wound disinfectants. J. Bone Joint Surg. Am. 49A:48.
15. Brown, P.W. 1973. The prevention of infection in open wounds. Clin. Orthop. 96:42.

16. Bryant, W.M. 1977. Wound healing. Clin. Symp. 29:2.
17. Cantu, J. Wound healing in horses. Department of Equine Surgery and Medicine. Kansas State University. Unpublished.
18. Cantu, J. Comparative Study of various suture materials buried in the soft tissues of the horse. Department of Equine Surgery and Medicine. Kansas State University. Unpublished.
19. Caulfield, J.B., and Burke, J.E. 1971. Inhibition of wound healing by chloramphenicol. Arch. Pathol. 92:119.
20. Collier, M. 1984. Treatment of wound and joint infection. Paper presented at Eastern States Veterinary meeting in Orlando, Florida. Eq. Vet. Data. 5(4):213.
21. Committee on Trauma, American College of Surgeons. 1976. Early care of the injured patient, ed. 2. Philadelphia, W.B. Saunders Co.
22. Connell, J.F. Jr., and Rousselot, L.M. 1953. The use of proteolytic enzymes in the debridement of the burn eschar. Surg. Forum. 4:422.
23. Dedo, D.D., Alonso, W.A., and Ogura, J.H. 1977. Providone-iodine: An adjunct in the treatment of wound infections, dehiscences, and fistulas in head and neck surgery. Trans. Am. Acad. Ophthalmol. Otolaryngo. 84:68.
24. Doering, G.G., Jenson, H.E. 1973. Clinical dermatology of small animals: A stereoscopic presentation. St. Louis: C.V. Mosby.
25. Edlich, R.F., Custer, J., Madden, J. et al. 1969. Studies in management of the contaminated wound: III. Assessment of the effectiveness of irrigation with antiseptic agents. Am. J. Surg. 118:21.
26. Edlich, R.F., Madden, J.E., Prusak, M., et al. 1971. Studies on the management of the contaminated wounds: VI. The therapeutic value of gentle scrubbing in prolonging the limited period of effectiveness of antibiotics in contaminated wounds. Am. J. Surg. 121:668.
27. Edlich, R.F., Rodeheaver, G.T., Thacker, J.G., et al. 1977. Management of soft tissue injury. Clin. Plast. Surg. 4:191.

28. Edlich, R.F., Rogers, W., Kasper, G., et al. 1969. Studies in the management of the contaminated wound: I. Optimal time for closure of contaminated open wounds: II. Comparison of resistance to infection of open and closed wounds during healing. *Am. J. Surg.* 117:323.
29. Edmonds, T. 1976. Evaluation of the effects of insulin on wound-healing in the distal limb of the horse. *Veterinary Medicine/Small Animal Clinician.* April. pg. 451-460.
30. Ehrlich, H.P., Tarver, H., and Hunt, T.K. 1973. Effects of vitamin A and glucocorticoids upon inflammation and collagen synthesis. *Ann. Surg.* 177:222.
31. Epstein, E.H., Jr. 1977. Wound healing in Epstein, E., and Epstein, E. Jr. (eds.): *Skin surgery*, ed. 4. Springfield, Ill., Charles C. Thomas, Publisher.
32. Faddis, D., Daniel, D., and Boyer, J. 1977. Tissue toxicity of antiseptic solutions: A study of rabbit articular and periarticular tissues. *J. Trauma* 7:895.
33. Fretz, P.B., Martin, G.S., Jacobs, K.A., McIlwraith, C.W. 1983. Treatment of exuberant granulation tissue in the horse: Evaluation of four methods. *Veterinary Surgery*, 12,3. pg. 137-140.
34. Furneaux, R.W. 1975. Management of contaminated wounds. *Canine Pract.* 2:22.
35. Gabbiani, G., and Majno, G. 1972. Dupuytren's contracture: Fibroblast contraction? *Am. j. Pathol.* 66:131.
36. Grant, J.C., and Findlay, J.C. 1957. Local treatment of burns and scalds using chlorhexidine. *Lancet* 272:862.
37. Harper, H.A. 1971. Review of physiological chemistry. 13th ed.
38. Hohn, D.C., Granelli, S.G., Burton, R.W., et al. 1977. Antimicrobial systems of the surgical wound: II. Detection of antimicrobial protein in cell-free wound fluid. *Am. J. Surg.* 133:601.
39. Hunt, T.K. 1970. Wound healing in surgery: Proceedings of a Panel Discussion. Somerville, NJ., Ethicon, Inc. pp. 11-13.
40. Jacobs, K.A., Leach, D.H., Fretz, P.B., Townsend, H.G.G. 1984. Comparative aspects of the healing of excisional wounds on the leg and body of horses. *Veterinary Surgery*, 13,2. pg. 83-90.

41. Jacobs, K.A. A review of incisional wound healing in the horse. Unpublished.
42. Jennings, P.B. 1977. Use of dimethylsulfoxide as an adjunct of topical antimicrobial therapy. Proceedings of the 12th annual meeting of the American College of Veterinary Surgeons: Advances in Veterinary Surgery and Surgical Education. Des Moines, Iowa. February 2, 1977.
43. Jennings, P.B. 1975. Surgical techniques utilized in the presence of infection. Arch. Offic. J. Am. Coll. Vet. Surg. 4:43.
44. Jennings, P.B. 1984. The skin and subcutaneous tissue. Large Animal Surgery. Chapter 11. pg. 254-294.
45. Johnston, D.E. 1974. Wound healing. Arch. Offic. J. AM. Coll. Vet. Surg. 3:30.
46. Johnston, D.E. 1977. The processes in wound healing. J. Am. Anim. Hosp. Assoc. 13:186.
47. Johnston, D.E. 1974. Wound healing. Arch. Am. Coll. Vet. Surg. 3:30.
48. Jones, E.W., Hamm, D. 1977. Steroidal and non-steroidal anti-inflammatory drugs for wounds nad traumatic inflammation. New Zealand Veterinary Journal. 25:317-319.
49. Jones, R.C., and Shires, G.T. 1969. Principles in the management of wounds, in Schwartz, S.I., Hume, D.M., Lillehei, R.C., et al. (eds.): Principles of Surgery. New York, McGraw-Hill Book Co., pp. 162.
50. Joseph, J., and Townsend, F.J. 1961. Experimental surgery - the healing of defects in immobile skin in rabbits. Br. J. Surg. 48:557.
51. King, C.G. 1968. Present knowledge of ascorbic acid (vitamin C). Nutr. Rev. 26:33.
52. Lawrence, C.A. 1961. Antimicrobial activity, in vitro, of chlorhexidine. Ft. Dodge Biochem. Rev. 30:3.
53. Lee, A.H., Swaim, S.F., Yang, S.t., Wilken, L.O. 1984. Effects of gentamicin solution and cream on the healing of open wounds. AM. J. Vet. Res., Vol. 45, No. 8. August. Pg. 1487-1492.

54. Lee, A.H., Swaim, S.F., Yang, S.T., Wilken, L.O. 1986. The effects of petrolatum, polyethylene glycol, nitrofurazone, and a hydroactive dressing on open wound healing. *Journal of the American Animal Hospital Association*. July 1 August Vol. 22. page 443-450.
55. LeVeen, H.H. 1972. Acidity: Key to wound healing? *Medical World News*. December 15, page 25.
56. Levenson, S.M., Geever, E.F., Crowley, L.V., et al. 1965. The healing of rat skin wounds. *Ann. Surg.* 161:293.
57. Lewis, J.R. 1963. *The surgery of scars*. New York, McGraw-Hill Book Co.
58. Longacre, J.J. 1972. *Scar tissue: Its use and abuse*. Springfield, Ill., Charles C Thomas, Publisher.
59. Madden, J.W. 1974. Muscle drug slows wound contraction. Reported at the 35th annual meeting of the society of University Surgeons in St. Louis *Medical World News*. March 15, pg. 74A.
60. Madden, J.W., Morton, D. Jr., Peacock, E.E. Jr. 1974. Contraction of experimental wounds. I. Inhibiting wound contraction by using a topical smooth muscle antagonist. *Surgery*, vol. 76, No. 1., pag. 8-15.
61. Madden, J.W. 1977. Wound healing: Biologic and clinical features, in Sabiston, D.C. (ed.): *Davis-Christopher: Textbook of Surgery*, ed. II. Philadelphia, W.B. Saunders Co.
62. Matsumoto, T., Dobek, A.S., Kovaric, J.J., et al. 1968. Topical antibiotic spray in contaminated crush wounds in animals. *Milit. Med.* 133:869.
63. Metzger, W.I., and dPrigot, A. 1955. The effect of topical antibiotic therapy upon the survival of wound bacteria. *Antibiot. Chemother.* 5:423.
64. Miller, R. 1977. Wound-healing practice tips. *Utah Veterinary Extension Newsletter*, Utah State University. December.
65. Muller, G.H., Kirk, R.W. 1976. *Small animal Dermatology* 2nd ed. pg. 3-20.
66. Noffsinger, G.R., McMurray, B.L. and dJones, T.J. 1957. Proteins in wound healing. *J. Am. Vet. Med. Assoc.* 131:148.

67. Noyes, H.E., Chi, N.H., Linh, L.T., et al. 1967. Delayed topical antimicrobial as adjuncts to systemic antibiotic therapy of war wounds: Bacteriologic studies. *Milit. Med.* 132:461.
68. Peacock, E.E., 1977. Repair and regeneration in Converse, J.M. (ed.): *Reconstructive Plastic Surgery, Principles and Procedures in Correction, Reconstruction, and Transplantation*, ed. 2. Philadelphia, W.B. Saunders Co., vol. 1.
69. Peacock, E.E., and Van Winkle, W. 1976. *Wound Repair*, ed. 2nd. Philadelphia, W.B. Saunders Co.
70. Pohl, B. and Hunt, T.K. 1970. Penicillin G and wound healing. *Arch. Surg.* 101:610.
71. Robson, M.C., Duke, W.F., and Krizek, T.J. 1973. Rapid bacterial screening in the treatment of civilian wounds. *J. Surg. Res.* 14:426.
72. Rodeheaver, G.T., Pettry, D., Thacker, J.G., et al. 1975. Wound cleansing by high pressure irrigation. *Surg. Gynecol. Obstet.* 141:357.
73. Rodeheaver, G., Turnbull, V., Edgerton, M.T. et al. 1976. Pharmacokinetics of a new skin wound cleanser. *Am. J. Surg.* 132:67.
74. Ross, R. 1969. Wound healing: In man and other higher animals as intricate, three-step process involving a variety of cells renews injured tissue. Studies of this process could yield ways of controlling several diseases. *Scientific American.* 220(6):40-50.
75. Roush, J.C. 1975. Trauma to the extremities. *Canine Pract.* 2:38.
76. Russell, P.S., and Billingham, R.E. 1962. Some aspects of the repair process in mammals. *Prog. Surg.* 2:1.
77. Salisbury, R.E., Carners, R. McCarthy, R. 1980. Comparison of the Bacterial clearing effects of different biological dressings on granulating wounds following thermal injury. *Plastic and Reconstructive Surgery.* October, Vol. 66, No. 4 page 596-598.
78. Sather, M.R., Weber, C.E., and George, J. 1977. Pressure sores and the spinal cord injury patient. *Durg Intelligence Clin. Pharmacol* 11:154.
79. Schwartz, P.L. 1970. Ascorbic acid in wound healing: A review. *J. Am. Diet. Assoc.* 56:497.

80. Shelby, R.W., Taylor, L.E., Garnes, A.L., et al. 1958. Enzymatic debridement with activated whole pancreas. *Am. J. Surg.* 96:545.
81. Sidebar, Wound gunk. Unpublished.
82. Silver, I.A. 1982. Basic physiology of wound healing in the horse. *Equine Vet. J.* 14(1):7-15.
83. Singleton, A.O., and Julian, J. 1960. An experimental evaluation of methods used to prevent infection in wounds which have been contaminated with feces. *Ann. Surg.* 151:912.
84. Sisson, S. 1975. Common integument. In Sisson and Grossman's *The Anatomy of the Domestic Animals*, Vol. I, 5th ed. page 247-249.
85. Stashak, T.S. 1982. Wound management in the horse. Presented to Wisconsin Veterinary Medical Association. February.
86. Stoner, J. 1984. Keeping wounds moist aids healing, *Research Indicators.* DVM. November page 8.
87. Swaim, S.F. 1980. Anatomy and physiology of the skin. In *surgery of traumatized skin.* page 3-39.
88. Swaim, S.F. 1980. Wound healing. In *surgery of traumatized skin.* Chapter 3. page 70-115.
89. Swaim, S.F. 1980. Management of contaminated and infected wounds. In *surgery of traumatized skin.* Chapter 4.
90. Troutmann, A., Fiebiger, J.F. 1957. The fundamentals of the histology of domestic animals.
91. Trueta, J. 1976. Reflections of the past and present treatment of war wounds and fractures. *Milit. Med.* 141:255.
92. Walton, G.S., Neal, P.A. 1971. Observations on wound healing in the horse: The role of wound contraction. *Eq. Vet. Journal.* page 93-96.
93. Winstanley, E.W. 1975. The epithelial reaction in the healing of excised cutaneous wounds in the dog. *J. Comp. Pathol.* 85:61.
94. Winter, G.D. 1977. Epidermal regeneration studied in teh domestic pig, in Maiback, H.I., and Rovee, D.T. (eds.): *Epidermal Wound Healing.* Chicago, Year Book Medical Publishers, p. 71.

Materials and Methods

For this study, 8 horses of various breed and skin color, ranging in age from 2-12 years, were selected. There were 4 mares and 4 geldings. All horses were subjected to physical exam, and determined to be disease free. They were dewormed using Eqvalan paste, and they were vaccinated against tetanus, equine influenza, and eastern and western equine encephalomyelitis.

This study included identical trials on the 8 different horses with each horse serving as its own control. Wounds were induced on the medial and lateral cannon, craniomedial and craniolateral fetlock, and bilateral midcervical neck. On horses with rear legs designated for treatment without wraps, craniomedial and craniolateral hock wounds were also induced.

Wounds consisted of full thickness sections of skin removed by surgical excision. A square stainless steel template 2.5 cm x 2.5 cm was used for consistency. The templates were sterilized by pressurized steam.

For the wounding procedure the horses were placed in lateral recumbency under general anesthesia. Induction was accomplished by intravenous administration of Xylazine (1.1 mg/kg) and Ketamine HCL (2.2 mg/kg). The animals were maintained on Halothane vaporized in oxygen and delivered by a semiclosed circle system. Each wound site was aseptically prepared in routine fashion. Wounds were placed on all exposed surfaces. The horses were then rolled, and wounds were induced to remaining

designated areas. Initial wounds were protected from contamination by sterile drapes. One wound was placed at each location except on the neck. The neck location received two wounds on each side. Hemorrhage, encountered during sharp excision, was controlled by direct pressure and hemostats.

Limb treatments were randomized to insure that all similar legs did not receive the same treatment. Horse #1 received hydrotherapy to the left front, furacin to the right front, furacin wrap to the right rear, and wrap only to the left rear. This sequence remained standard rotating by 1 leg on each subsequent horse. The rotation resulted in pairs of horses receiving identical treatment. Paired horses were numbers 1 and 5, 2 and 6, 3 and 7, and 4 and 8.

Neck wound treatments were also randomized between hydrotherapy and topical furacin with horse #1 receiving furacin on the cranial wound and hydrotherapy on the caudal wound (bilaterally). Treatment locations were switched with each subsequent horse.

Wounds treated with wraps were changed every three days. Furacin wrap legs received administration of fresh furacin with no cleansing at the time of wrap changes. Legs treated with wraps only were subjected to hydrotherapy prior to application of the new wrap. Leg wraps consisted of nonadherent telfa pads covering the wound sites. Over these an army-navy wrap was applied. This wrap consists of a thick cotton pad with 6" stretch gauze.

Hydrotherapy was handled in two different phases. The first

11 days consisted of a sterile saline flush. From day 12 on therapy was switched to tap water. The saline flush consisted of 300 ml sterile saline delivered with gentle pressure from a 60 cc syringe. Tap water hydrotherapy consisted of gentle pressure from a garden hose for 5 minutes per wound. These treatments were performed once a day, lasting until epithelialization was complete.

Evaluation of the healing wounds consisted of gross observation and histologic observation. The gross evaluation was facilitated by photography, and histologic evaluation was performed on samples harvested with a 4 mm punch biopsy instrument.

Photography was performed with a Kodak Instatech X close up camera with Kodak Ektachrome 64 ER126 color slide film. Black and white prints were produced from the color slides. Areas were calculated from prints of these slides, using a Hewlett Packard Digitizer. Tracings were made, of the outer zone (hairline), to determine decrease in area due to contraction. Tracings were made, of the inner zone (epithelium/granulation tissue interface), to determine size of remaining granulation bed. The difference between these two values gave us the area of re-epithelialization. Standard photographs were taken on days 0, 3, 6, 9, 15, 21, 30, 39, 51, 63, 78, and 96. Additional photographs were taken to record unusual developments occurring on unscheduled days. Day 0 photographs were taken immediately after horses returned to a stable standing position. All

distance arm. Lateral leg and right side neck wounds were used for photography.

Biopsies were taken from the medial leg and left side neck wounds. They were harvested under xylazine/ketamine general anesthesia with horses in lateral recumbency. Samples were taken on days 0, 3, 6, 9, 15, 21, 30, and 39. The entire section of skin removed on day 0 was submitted for evaluation. Tissue samples were fixed in 10% BNF and submitted for routine histologic preparation. All samples were sectioned and stained with hematoxylin and eosin. Selected sections were recut and stained with trichrome for collagen evaluation.

Histologic parameters evaluated were inflammation, fibroblastic activity, collagen production, and new epithelial growth and migration. These parameters were assessed qualitatively.

Granulation tissue was considered exuberant when it protruded above the level of the surrounding skin. It was controlled by sharp excision with a scalpel blade. Care was taken not to disrupt the epithelial growth, and enough tissue was trimmed away leaving a slightly concave surface. Each trimming was recorded. The number of trimmings necessary for each wound were to determine the incidence of exuberant granulation tissue.

Results

As a result of post-anesthetic myositis, it was necessary to remove horse #1 from the data comparison. The horse was unable to rise for 2 days. During this time period all lesions were grossly contaminated. When she could stand, predetermined treatments were initiated. Even though data from this horse will not be used in the general comparison, it offers an interesting comparison with the data gathered from the 7 noncontaminated horses.

On day 3 the wraps were changed according to the original schedule, and the first set of photographs were taken. Predetermined treatments were carried out as scheduled for the remainder of the trial.

On day 3 lesion sites on all 4 legs were suppurative, with the nonwrapped legs showing the most severe response. Open lesions, on day 4, showed marked heat (calor), pain (dolor), and swelling (tumor). There was moderate loss of function due to discomfort. The lesions treated by wrap only soaked through on day 5. This indicated excessive exudation by these lesions. Both legs treated with wraps revealed decreasing discomfort up through day 10. At this time nonwrapped legs also revealed no pain or heat, with only moderate swelling in the fetlock lesions. Fetlocks treated with hydrotherapy and topical furacin showed an increase in lesion size, during the first 10 days. There was gross evidence of local necrosis around the lesion margins during this time. Lesions treated by topical furacin revealed the

greatest degree of necrosis and enlargement. Healthy looking granulation tissue appeared in the nonwrapped lesions by day 11. Even though wrapped legs showed an apparent greater discomfort, during this early time period, necrosis and lesion enlargement was markedly less. Exuberant granulation tissue was present, on day 12, in all wrapped lesions.

Normal healing progressed from day 12 on, with no further complications. Dry wraps indicated reduced exudation of covered lesions, while open lesions showed no further signs of suppuration. Apparent infection, present in these lesions, had resolved with no administration of systemic antibiotics. The only treatments administered were the predetermined topicals.

Exuberant granulation tissue was first evident at day 12. It was more severe in lesions under wraps. This trend continued with proud flesh trimming necessary a total of 10 times under the furacin wrap and 11 times under the dry wrap. Trimming was necessary from days 12 through 39. Hydrotherapy treated lesions needed 2 trims, one necessary on day 12 and one on day 21. Furacin treated lesions needed 2 trims also, both necessary on day 12.

Lesions covered by wraps healed faster than lesions left open, 63 days vs. 96 days. However, with wraps discontinued at this time, the healing was inadequate to protect against the environment. All lesions ulcerated centrally, where only a thin covering of new epithelium existed. Ultimately, all lesions healed at approximately the same time.

Resultant scar size of the fetlock lesions reveals some

interesting data (figure 1). During the period of suppuration and necrosis the hydrotherapy and furacin treated wounds enlarged to 19.5 cm² and 22.7 cm², respectively. Furacin wrapped and wrapped lesions enlarged to 11.4 cm² and 11.2 cm² respectively, during this same time period. The hydrotherapy lesions resulted in a 2.80 cm² scar. The lesion covered by a wrap only resulted in a 3.98 cm² scar. These were followed by the furacin wrap treated lesion and furacin treated lesion with respective scar areas of 4.82 cm² and 5.57 cm².

All horses in the trial developed similar trends worth noting, that were typical of each treatment regimen. Wounds being irrigated with saline all revealed a marginal zone of edema ranging from 1 to 2 cm. Degree of edematous swelling reached a peak at day 4 and was only slightly noticeable at day 7. The edematous change was most noticeable on loose skinned neck wounds. By day 12 no edema was noticed, and the switch to tap water stimulated no noticeable reaction.

Topical furacin treated wounds consistently were contaminated with bedding and debris. Lower leg wounds, exposed to this treatment, showed a slight increase in inflammation (calor and tumor) over the other limb treatments. Horse #1 showed the greatest degree of suppuration from this treatment.

Wraps, either dry or with furacin, consistently showed less signs of inflammation during the early treatment period. Scabs developed under the dry wrap, but maintained a very thin and soft consistency. No scabs were noted with furacin wrap treated

wounds. Contamination was controlled and unremarkable with these treatments. When new epithelium had completely covered the granulation bed, it was very thin and subject to trauma. If uncovered at the initial point of complete epithelialization, most lesions ulcerated.

Scabs were consistently characteristic of the treatment they were exposed to. Lesions treated by hydrotherapy produced a dry relatively thick scab. During the treatment this scab would usually soften and either partially or completely wash off. Topical furacin treated lesions produced a soft but thick scab. Scabs produced under the wraps have already been described.

Wound healing rate was calculated by dividing the original area of skin deficit by the number of days taken to close that deficit (figure 3). This calculation was complicated by the incidence of traumatic ulceration of wrapped wounds on horses 2 through 6. Wraps were maintained on horses 7 and 8 slightly longer, until epithelialization appeared thick enough to withstand environmental exposure.

Comparing furacin and water treated wounds to wrapped wounds, we see an apparently more rapid rate of healing in the wrapped legs. If only horses 7 and 8 are compared the difference becomes much less remarkable.

Cannon lesions healed at a faster rate than fetlock lesions in all but the furacin wrap treated lesions (figure 3).

Instead of wrap vs. no wrap, rate of epithelialization appears to correlate more with furacin vs. no furacin. (figure 4). Epithelialization was derived by dividing the area of new

epithelium by the number of days taken to achieve a complete epithelial covering.

Treatment by water had the slowest rate at $.035 \text{ cm}^2/\text{day}$. Dry wrapped wounds were next with a rate of $.043 \text{ cm}^2/\text{day}$ for horses 2 through 8, and $.037 \text{ cm}^2/\text{day}$ for horses 7 and 8 alone. Topical furacin treated wounds and furacin wrap treated wounds were very similar. Topical furacin yielded a rate of $.044 \text{ cm}^2/\text{day}$ and furacin wrap treatment yielded values of $.045$ and $.043 \text{ cm}^2/\text{day}$. Differences between fetlock and cannon locations are noted, but there is no pattern.

Percent of healing by contraction was calculated by dividing the difference between wound size and scar size by the original wound size, and multiplying by 100. Furacin treated wounds contracted by an average of 39%. Water treated wounds contracted by an average of 53%. Dry wrap treated wounds contracted by average values of 55% (horses 2-8) and 54% (horses 7 and 8). Furacin wrap treated wounds contracted by average values of 53% (horses 2-8) and 45% (horses 7 and 8). Using wrap values from horses 7 and 8, we see a correlation based on furacin vs. no furacin. Similar to the wound healing rate we see differences existing between fetlock and cannon locations, with percent contraction of the cannon exceeding fetlock values in all treatments except furacin wraps (figure 5).

Incidence of exuberant granulation tissue was based on the number of trims necessary to maintain a flat bed of granulation tissue not exuding above the skin surface. Once again we see a strong correlation between wrapped wounds vs. nonwrapped

wounds (figure 2). Wounds treated with topical furacin averaged .6 trims per horse. Wounds treated by hydrotherapy averaged 1.7 trims per horse. Wounds treated with furacin wraps averaged 9.0 trims per horse. Wounds treated with dry wraps averaged 9.1 times per horse. Nonwrapped wounds produced exuberant granulation tissue from days 12 through 21. Wrapped wounds experienced proud flesh problems from days 9 through 45.

The hydrotherapy treated fetlock of horse #8, along with data from horse #1, was not used in our comparison of the four treatments. A keloid developed in #8 horse's fetlock. Since only fetlock and cannon lesions were exposed to all four treatments, only data from these sites is used in the comparisons.

There were no proud flesh trims noted on wounds of the hock. Hock wounds treated by topical furacin healed at an average rate of $.100 \text{ cm}^2/\text{day}$. They averaged 60% contraction and a $.039 \text{ cm}^2/\text{day}$ epithelialization rate. Hock wounds treated with water healed at an average rate of $.085 \text{ cm}^2/\text{day}$. They averaged 59% contraction and a $.035 \text{ cm}^2/\text{day}$ rate of epithelialization.

On day 15 horse #4 required proud flesh trims of both the water treated and furacin treated neck wounds. Furacin treated neck wounds healed at a rate of $.197 \text{ cm}^2/\text{day}$. They averaged 83% contraction and a $.031 \text{ cm}^2/\text{day}$ rate of epithelialization. Water treated neck wounds healed at a rate of $.207 \text{ cm}^2/\text{day}$. They averaged 85% contraction and a $.032 \text{ cm}^2/\text{day}$ rate of epithelialization.

Histologic difference between treatments was relatively unremarkable. Edema was a consistent early sign of

surface in many day 3 biopsies. The wound margin epidermis became markedly thickened and as healing progressed, a thin layer of epithelial cells were noted migrating across the granulation bed. Occasionally, furacin treated wounds revealed intraepidermal pockets of eosinophilic amorphous material. The lead edge of migrating epithelium always showed a zone of collagen necrosis around it. Hydrotherapy wounds usually revealed a thicker blunter lead edge of epithelium. Epithelium encountering exuberant granulation tissue would layer itself into a thick epidermal mass, but showed no signs of migration over the exuberant mass. Occasional islands of epithelial cells on the granulation tissue surface were noted.

Day 3 biopsies revealed a basically normal dermis with mild neutrophil activity in some. Those that included subcutaneous tissue, revealed a thickened appearance to the normally loose connective tissue. As healing progressed a bevel shaped reaction occurred in the dermis progressing inward from the epidermal edge traveling deep to the subcutis. There was a loss of normal dermal architecture giving way to the newly developing thick fibrous scar tissue. Collagen bundles first gave way to inflammatory cells, then fibroblasts, and finally new collagen.

Discussion

The development and control of exuberant granulation tissue becomes a major concern in the treatment of equine skin wounds. To more effectively keep it from becoming a hinderance to wound contraction and epithelialization, we need to look at what is stimulating its production. Although results of this project do not indicate why wrap covered wounds promote it, exuberant granulation tissue is more of a problem with a wrap covering than without. Both as a horseman and as a veterinary student, I was told furacin stimulated granulation tissue and would ultimately lead to exuberant production. Furacin was not shown to possess this property in this wound healing trial. There were only subtle differences in the histology of granulation tissue biopsies. The granulation tissue formed in hydrotherapy treated wounds appeared to show an earlier increase in collagen production and organization.

Due to the fact that wounds covered by wraps were easily traumatized, I will use horse 7 and 8 data to discuss the healing rate of wrapped legs. The furacin average ($.076 \text{ cm}^2/\text{day}$), water average ($.074 \text{ cm}^2/\text{day}$), furacin wrap average ($.080 \text{ cm}^2/\text{day}$), and wrap average ($.079 \text{ cm}^2/\text{day}$) are all very comparable. We see from the rate of epithelialization and percent contraction data that this comparability results from strengths and weaknesses in each area. Hydrotherapy and wrap treatments encourage wound contraction. Furacin and furacin wrap treatments encourage a higher rate of epithelialization.

Location of the wound also is shown to be an important factor in wound healing rate. The loose skin of the neck region was most rapid. Hock wounds displayed the next highest rate, and they were followed by wounds of the cannon and fetlock region.

To yield the most cosmetic end product we would want our treatment of choice to heal predominately by contraction, and present minimal problems with exuberant granulation tissue. Water treated wounds showed us an average of 53% healing by contraction. They also produced a low incidence of granulation tissue. From this study hydrotherapy appears to yield the most cosmetic healed wound.

Summary

The early control of environment and inflammation makes wrapped wounds appear advantageous at this point. This benefit is notably worthwhile. Especially the contaminated horse reveals a benefit from their use.

To minimize exuberant granulation tissue production and minimize scarring, a switch to hydrotherapy appears to be beneficial at the sixth or ninth day. This switch would also minimize cost to the horse owner and labor to the veterinarian.

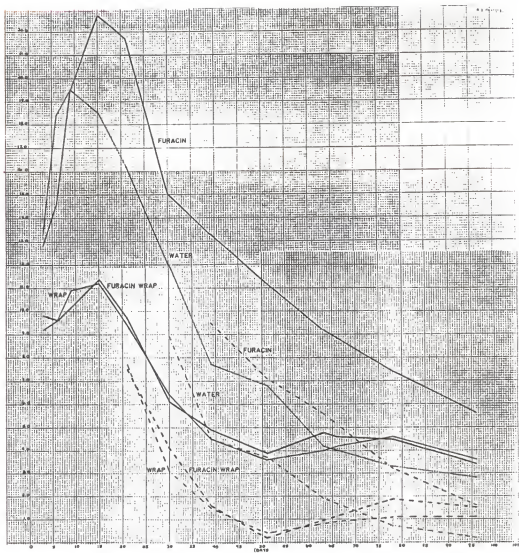


fig. 1 Change in wound area, as related to time, for the four treatments of fetlock wounds on animal #1. Wound area is in cm^2 . Solid lines portray the original wound margin. Dashed lines portray inner zone of epithelialization.

2

3

4

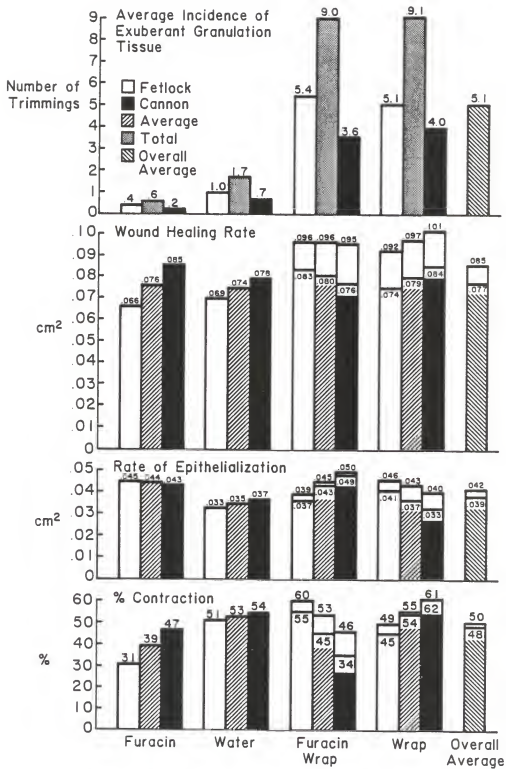
5

Fig. 2 Incidence of exuberant granulation tissue as portrayed by number of trimmings for each treatment. Values represent the average of data from horses 2-8.

Fig. 3. Wound healing rate in cm^2/day . Values above each bar represent the average for horses 2-8. Values within the bar represent the average between horses 7 and 8 only.

Fig. 4. Rate of epithelialization in cm^2/day . Values above each bar represent the average for horses 2-8. Values within the bar represent the average between horses 7 and 8 only.

Fig. 5 Percent contraction noted for each treatment. Values above each bar represent averages for horses 2-8. Values within the bar represent the average between horses 7 and 8.



A COMPARISON OF FOUR TREATMENTS ON
FULL THICKNESS SKIN WOUNDS OF THE HORSE

by

Neal E. Woollen

DVM, Kansas State University, 1985

AN ABSTRACT OF A MASTER'S THESIS

submitted in partial fulfillment of the
requirements for the degree

Master of Science

Department of Veterinary Pathology

Kansas State University
Manhattan, Kansas

1987

Data, derived from healing wounds induced on 8 horses subjected to 4 differing treatment regimens, was analyzed to provide insight into more effective means of treating full thickness skin wounds. Variables considered were incidence of exuberant granulation tissue, wound healing rate, rate of epithelialization, and percent contraction. This data revealed a higher incidence of exuberant granulation tissue in lesions covered with wraps. Wound healing rates were all comparable. This comparability was due to offsetting values for rate of epithelialization and percent contraction. In the interest of making treatments efficacious as well as economical, this data helps us derive that wraps show early benefit by controlling the environment and thus the degree of inflammatory response. However, chronic use of wraps will lead to a high incidence of exuberant granulation tissue, which will retard healing unless properly controlled. Therefore wraps should be discontinued when a granulation bed has formed and hydrotherapy should be supplemented. This switch will decrease treatment cost, decrease owner and veterinarian labor, decrease production of exuberant granulation tissue, and stimulate healing with a higher percentage of contraction that will minimize scar production.