THE POST-OPERATIVE EFFECTS OF FEMUR SHORTENING IN THE MATURE DOG

by

DIETRICH FRANCZUSZKI

Dr. med. vet., Ludwig Maximilians University
Munich 1978

A MASTER'S THESIS

Submitted in partial fulfillment of the
requirements for the degree

MASTER OF SCIENCE

Department of Surgery and Medicine
Kansas State University
Manhattan, Kansas

1986

Approved by: Hugh C Butler
Hugh C. Butler, DVM, MS
Major Professor

TABLE OF CONTENTS

Page

ACKNOWLEDGEMENTS

I would like to thank Dr. Jerry R. Gillespie and the Department of Surgery and Medicine for the funding and support necessary to undertake this project. Special thanks are due to my major professor Dr. Hugh C. Butler, to Assistant Professor James A. Chalman and to Dr. Richard M. DeBowes for their ideas, guidance and support throughout my Masters Program.

I would also like to express my sincere appreciation to Dr. Horst Leipold and Dr. Mark M. Guffy for a abetter understanding of the histology of joint cartilage and for the help and guidance in the science of radiology.

I would like to thank Dr. Boyer, Department of Statistics, in the evaluation and interpretation of my data and Mal Rooks for her artistical skills.

Finally a special thank you for the members of the Surgery staff, Dr. J. A. Chalman, Dr. C. E. Layton, Dr. S. D. Wagner and Dr. R. Rudd for support and help needed to complete this thesis.

INTRODUCTION

One of the most common fractures in the dog is a fracture of the femur.[1,2] Most of these fractures occur from violent direct trauma, automobiles being the most frequent etiological cause. Most femoral fractures are comminuted or multiple[3] and involve the diaphysis.[2]

If a femoral fracture is not repaired and the fragment stabilization achieved, abnormal angulation of the limb is likely to occur and malfunction of the limb will result. Additional damage to the surrounding soft tissues is likely to occur, which can result in loss of function; if it be a nerve, fibrosis if it be a vessel or muscle.

Closed reduction with external coaptation does not provide sufficient fragment stabilization of the femur. Open reduction and internal fixation is the surgical treatment of choice.[2,3,4] Plate fixation is generally recommended for repair in comminuted fractures of the femoral diaphysis.[2,3,4] Severe comminution or bony loss such as results from a high velocity missile may require bone shortening or bone grafting.[3]

There is a general belief that considerable bone loss and resultant shortening of a limb can occur, particularly in animals that have an angulated stifle, without effecting the gait or ambulation to any great degree. Shortening of 1 to 2 cm can be tolerated by most dogs and cats.[3] If shortening of greater magnitude is required a cortical bone graft should be considered.[3] To date, no substantiated findings are published regarding this generally accepted hypothesis. The decision whether to remove bone or to place a bone allograft in position is an arbitrary one in cases of major bone loss. The question is how much of the femoral diaphysis can be removed without affecting ambulation to any substantial degree.

The purpose of the present study is to determine if it is possible to remove a certain percentage of bone from the mid-femoral diaphysis via ostectomy and yet preserve normal locomotor function. The percentages chosen for this study are 10, 15, and 20%. Additional objectives are: 1. To describe the changes in the standing angles of the hip, stifle, and hock with the above percentages of bone loss from the femoral diaphysis. 2. To examine and describe any changes in the articular surfaces of the joints following diaphyseal shortening by ostectomy.

LITERATURE REVIEW

1. Frequency and cause of femoral fractures

Several review studies of bone fractures in the dog and cat list the femur as the most commonly affected long bone.[1,2] Road accidents are the main cause of these fractures followed by falls from heights. The amount and direction of force will vary from accident to accident and the type and direction of the force will determine the type of fracture.

Results of a study at the Ludwig Maximilians University revealed that 61% of fractures of the femur involved the diaphysis of the bone.[2] The canine femur at its immediate proximity to the mid-diaphysis is least resistant to direct trauma because this is the area of smallest diameter.[6] Approximately 50% of the patients presented with femoral shaft fracture, cited in the above review, were skeletally immature dogs.[2] Large breeds were more frequently traumatized than small dogs.[2] Thimel assumed that the femur in large breed dogs is more affected, due to the immediate impact of a crushing force.[5]

2. Additional injuries

With accidents being the most common cause of femoral fractures, the patients are also frequently polytraumatized. Tamas reports that 52% of the patients have pulmonary contusions, 15% have pneumothorax and 10% have pleural effusion. In addition femoral fractures are often associated with fractures of the pelvis.[2] Small dogs frequently evidence coxofemoral luxations of the ipsilateral hip, and other ligamentous injuries. Along with the above mentioned injuries, trauma to the abdominal viscera are common, particularly the urinary bladder, liver and spleen.

Diaphyseal fractures of the femur are noted for the complexity of comminution of the bone and extensive damage to the surrounding soft tissue. Common soft tissue injuries include laceration of the quadriceps and biceps, tearing or severance of the femoral artery or vein, and last but not least is laceration or stretching of the sciatic nerve. Infrequently penetration of the skin occurs resulting in contamination of the fracture. This, however, is rare due to the heavy musculature surrounding the femoral diaphysis.[3]

Extensive soft tissue damage and damage to the periosteal and medullary blood supply frequently predisposes the affected cortical bone to delayed revascularization, thus enhancing the possibilities of postoperative complications.

The complications of fractures and fracture healing have been recognized for many years. Delayed union, non-union, malunion and osteomyelitis are the most common sequelae observed. Instability of the fracture postoperatively is the most common cause of failure. The second most common cause is infection.[3] It has been shown that even in the presence of infection it is possible to get union if the fracture site is absolutely stable.[3]

Complications will frequently occur as a result of overuse of the leg prior to healing, causing the fixation device to fail; thus the importance of owner instruction and cooperation cannot be overlooked.

3. Methods of Reduction and Fixation

Adequate muscle fatigue must be achieved prior to any attempt to reduce the fracture. Proper application of a Schroeder-Thomas splint for a short period of time will assist in achieving muscle fatigue, and subsequently aid in the reduction.

a.) Closed Reduction and External Fixation

The Schroeder-Thomas splint may be used to stabilize femoral shaft fractures if the distal portion of the ring is proximal to the fracture line; thus it's use is limited to those fractures distal to the midshaft of the femur. In addition it is frequently necessary to combine this with a spica cast by bandaging.[3] Complications such as muscle tie down and joint stiffness and splint sores frequently occur.

Plaster of Paris or fiberglass casts when used must immobilize the hip in the form of a spica. These disadvantages outweight the advantages; there is a constant threat of ulceration, cast sores and moisture from urine. These casts are heavy and prevent the animal from walking.

b.) Closed Reduction and Internal Fixation

A single intramedullary pin may be used as a method of fixation in immature dogs with good osteogenic potential or in small to medium sized dogs lightly muscled.[3] This technique does not supply rotational stability unless the pin tightly fits the medullary cavity of the bone. The more the pin fills the medullary cavity and binds on the inner cortex, the more accurate the anatomical alignment and the greater the resistance to rotation and shear.[9] As a rule the pin should comfortably fill the medullary cavity at it's narrowest point.[9] This technique when used by a properly experienced surgeon can save time and trauma. The patient needs to be carefully selected and only jagged transverse or short oblique fractures should be attempted.[3] If an intramedullary pin has been inserted and the fracture is still rotationally unstable it can be combined with a half Kirschner to gain rotational stability.

c.) Open Reduction and Internal Fixation

Today the open reduction and subsequent internal fixation is the method of choice in most femoral fractures because most of them are comminuted. Use of intramedullary Steinmann pins with or without orthopedic wire is the most traditional method of fixation. Frequently this does not adequately stabilize the fracture. If the narrowest of portion of the diaphysis is larger than the largest pin, one can use the Hakental technique by stacking numerous pins in the cavity until it is filled, and rotational stability is achieved.[3]

Bone plates and screws when properly applied, provide excellent stabilization against all forces that one normally expects to be acting on the bone.[9] Though plates are applicable for most femoral fractures in the dog, they are especially useful in the repair of comminuted fractures.[9]

Femoral diaphyseal fractures that are comminuted beyond anatomical reconstruction may be handled in other fashions. Severely comminuted fractures with subsequent bone loss may require shortening of the bone prior to fixation. Shortening of 1 cm to 2 cm can be tolerated by most dogs and cats.[3] If shortening of greater magnitude is required a cortical bone graft should be considered.[3] Another method of repair in such cases is to reconstruct the bone to proper length, using a bone plate, and to fill the gap with autogenous cancellous bone.[3,9,11]

Comminuted femoral shaft fractures have a high percentage of postoperative fixation device failure. Thus the selected surgical technique, implant selection, and postoperative patient management are all of equal importance.[9]

Nowhere in the literature is there a definitive study that reveals what percent of the femoral diaphysis can be removed without compromising the movement and gait of the animal.

MATERIAL AND METHODS

Eighteen mature dogs (12 females, 6 males) weighing from 12.2 to 20.5 kg (mean ± variations) of nonchondrodystrophic breeds were utilized in this study. Three dogs were Mongrel dogs, four were Coonhounds, five German Shorthair Pointers and six were Brittanys. All dogs were of sound general health and free of any metabolic bone disease, osteoarthrosis or previous hind limb injuries.

The dogs were individually housed and fed a commercial canine diet with water provided ad libitum. The dogs received a complete physical examination, hemogram, urinalysis and heartworm check (Knott's test) prior to the initiation of the study. All dogs were subjected to a two week conditioning period during which there were vaccinated and dewormed.

To restate the objective of the study, the purpose was to determine, in a definitive method, what percentage of the femur could be removed from the mid-diaphysis without significantly affecting ambulation or the gait of the dog. The arbitrary selection to ostectomize 10%, 15% and 20% of total femoral length was established.

The dogs were randomly divided into three equal groups of six dogs each. Group 1 - mid-diaphyseal ostectomy of 10 percent of total femoral length; Group 2 - 15 percent of the femoral diaphysis were removed; Group 3 - 20 percent mid-femoral ostectomy. All ostectomies were performed by the same surgeon and on the left femur of all dogs. The right femur was used as a control in all animals.

Prior to initiation of the experiment, each dog was radiographically checked for signs of degenerative joint disease in the two joints adjacent to the femur. With the dog under general anesthesia ventrodorsal radiographs of their pelvi were made. Dogs with degenerative joint disease were eliminated from the study.

In each dog (presurgically) the standing height was measured, this being the distance from the cranial dorsal aspect of the iliac crest to the floor. The joint angles of the hindlimbs were measured with a goniometer while the dog in a standing weight-bearing position.

The mid-thigh circumference was determined by a tape measure, pre-operatively at three and at six weeks after the surgery. Photographs of the dog with the limbs in a normal weight-bearing position, respectively when ambulatory, were taken.

The surgeries were ordered in a manner that one dog from each of the groups was done, and then the sequence was repeated until all the surgeries were completed.

The dogs were fasted for 12 hours pre-operatively but were allowed access to water until the time of surgery. Each dog was premedicated with 0.04 mg/kg atropine sulfate* subcutaneously. Anesthesia was induced using thiamylal sodium# (16mg per kg intravenously) and was maintained with halothane vaporized into oxygen using a semiclosed system. Intravenous lactated Ringer's solution was administered intravenously at a rate of 20 ml/kg/hr throughout the surgical procedure.

Each dog was placed in right lateral recumbency. The left hindlimb was clipped from the dorsal midline to the mid-tibia and from the lumbar fossa to the perineum, circumferentially. Surgical scrubbing was done using povidone iodine scrubs$, alcohol rinses and povidone iodine solution¢ was sprayed on the leg as a final preparation for surgery.

---

* Atropine Sulfate Injection U.S.P. Med-Tech, Inc., Elwood, KS 66024

\# Bio-tal, Bio-Ceutic Division, Boehringer Ingelleim Animal Health, Inc. St. Joseph, Missouri 64502

$ Betadine Surgical Scrub, The Purdue Frederick Company, Norwalk, CT 06856

¢ Betadine Solution, The Purdue Fredrick Company, Norwalk, CT 06856

SURGICAL PROCEDURE

Standard towel in draping and limb stockinette procedures were used to isolate the left femur for aseptic surgery. An incision of the skin overlying the lateral aspect of the femur was made exposing the tensior fascia lata muscle. The fascia lata was incised anterior to the muscle belly of the biceps femoris. The femoral shaft was exposed by retracting the biceps femoris muscle caudally, the vastus lateralis cranially and reflecting the adductor magnus muscle from the medio-caudal aspect of the femoral diaphysis (Fig. 1).

The total length of femur was measured by inserting one K-wire perpendicular to the long axis of the bone at the superior prominence of the greater trochanter and a second K-wire parallel to the first wire, between the femoral condyles and the tibial plateau (Fig. 2). The distance between the K-wires was measured and the midpoint of the femoral diaphysis was determined (Fig. 2). This point was marked on the periosteum of the femoral diaphysis (Fig. 2). A dynamic compression plate (DCP) was precisely contoured and prestressed to the form of the lateral aspect of the femur (in cases of 10 and 15 percent of mid-diaphyseal ostectomies). In dogs where 20 percent of diaphyseal shortening was performed no plate precontouring was performed. A transverse osteotomy of the femur was made (Fig. 2). A second osteotomy was performed in such a manner as to allow removal of the predetermined percentages of bone. All osteotomies were made using a power driven oscillating saw.*

Following the ostectomy, the bone plate was centered on the ostectomy site and temporarily fixed to the bone with two Verbrugge bone holding forceps (Fig. 2).# Prior to fixation the ends of the bone were allowed to collapse and come into contact creating a single osteotomy incision line. With a good fracture

---

* 5052-02 Orthair Oscillator, Zimmer, Warsaw, Indiana 46580

\# Verbrugge bone holding forceps, Aesculap Instruments, Independence, MO 64051 fragment alignment the plate was affixed to the femur using cortical bone screws. The first screw was inserted nearest to the midpoint, using a neutral guide. The second screw was inserted in the hole on the opposite side of the midpoint using a load guide and seated completely. All remaining screws were seated using the neutral drill guide and placed on opposite ends alternately (Fig. 3).

Closure of the incision was performed in routine manner. The fascia lata was sutured to the cranial border of the biceps femoris muscle using #2-0 chromic catgut in a simple interrupted suture pattern. The subcutaneous tissues were apposed in a similar fashion where as the skin was closed using #3-0 monofilament nylon in a simple interrupted horizontal mattress suture pattern. Postoperative radiographs were taken to evaluate fracture fragment alignment and implant placement.

POSTOPERATIVE CARE

Following the surgical procedure each dog was carefully monitored and walked twice a day for ten minutes (after the initial postoperative period of 14 days). The rectal temperature, pulse and respiration of each dog was recorded daily. Each dog was evaluated daily for attitude, evidence of discomfort, swelling, drainage excessive redness and integrity and appearance of the suture line. In cases where the dog started to lick and/or chew at the incision site an Elisabethan collar was placed on the dog.

Data collection (weight bearing, thigh circumference, standing angles, total limb length) was performed at three and six weeks postoperatively. The clinical results of the lameness examination were categorized according to the following classification.

A. Excellent (1): dog can run and jump, turn without lameness. Each animal has a full range of motion in adjacent joints. There is no evidence of pain on palpation.

B. Very good (2): dog can run and jump but may limp after prolonged strenuous exercise. Each animal has a full range of motion in adjacent joints. Pain is not evident on palpation. There is minimal evidence of muscle atrophy.

C. Good (3): animal can walk and run bearing full weight. Will on occasion favor the limb when standing. Pain is not evident on palpation. There is evidence of moderate muscle atrophy.

D. Fair (4): animal shows continual lameness some evidence of pain on palpation and marked muscle atrophy.

E. Poor (5): toe just touches the ground bears weight periodically or not at all. May be painful on palpation. There is evidence of marked muscle atrophy.

Photographs were taken of each dog preoperatively, at three and six weeks after the surgery, with the dog being ambulatory, respectively with the dog standing, with its limbs in a normal weight bearing position. All dogs were euthanized six weeks postoperatively. Immediately after euthanasia total hind limb length (iliac crest to pads) with the hindlimbs being maximally extended, was established. Left limb length was compared to right limb length. At the same time radiographs of both femurs (ventrodorsal and lateral) were taken.

MACROSCOPIC AND HISTOPATHOLOGICAL EVALUATION

The coxofemoral, stifle, and tibiotarsal joints with their synovial membranes along with the femurs (left and right) were inspected for changes and articular wear. The two femurs were compared and evaluated.

The femurs were split longitudinally with a band saw in a sagittal plane through the screw holes. Photographs were taken of the whole and split specimens. The femurs along with the corresponding acetabuli, tibiae and fibulae were placed in 10% buffered neutral formalin until histopathological examination could be done. The bones were then decalcified, sectioned and studied histologically with hematoxylin and eosin stain.

STATISTICAL ANALYSIS

Statistical analysis of the data was performed using a randomized complete block design. Since not all surgical procedures could be performed at the same time, the time intervals were treated as blocks.

The severity of surgery was the treatment variable in a one-way treatment structure. Analysis was performed on the Kansas State University's computer using version 82.3 of the Statistical Analysis System (SAS) package. Observed levels of significance $p<0.05$ were considered to be significant. The data studied, included the postoperative values at three and six weeks after surgery, being compared to the preoperative values and between each other (within each group). Additionally, response variables studied included each of the left (ostectomized) side measurements at both three and six weeks postoperative periods, and differences between left and right side measurements for each location of interest. Finally, covariance analyses were run on each left side postoperative measurement using the corresponding left side preoperative measurement as a covariate.

RESULTS

Clinical Evaluation

All dogs recovered from anesthesia within two hours (alert and ambulatory). Analgesic therapy was not necessary after surgery. Following surgery, the dogs having had 10 and 15% of their femurs ostectomized, were fully weight bearing within 1-4 days. In dogs with a 20% ostectomy, full weight bearing did not start before 5-10 days after surgery. Two dogs developed a moderate postoperative swelling at the incision line along with some serous discharge. After hot packing the surgery site (b.i.d., for five minutes, for three days) and applying an Elisabethan collar on the dog, the swelling and discharge resolved within 48-72 hours.

In the first-dog a six hole 4.5mm dynamic compression plate was used. The dog was weight bearing on its left hindlimb the day following surgery. The dog was left unsupervised for four days postoperatively while its pen was cleaned.

On the fifth day a deterioration in weight bearing was noticed. The dog started to limp, and was not weight bearing on the left hindlimb when standing. Radiographs, revealed loose screws in the distal fragment. The screws (4.5mm) were replaced with 6.5mm cancellous bone screws and no further complication occurred. Following this incident the dogs were continuously supervised when outside their pen and kept on a hand leash when walked.

The remaining fifteen dogs were free of complications. Results of the average goniometric measurements of the standing angles in all groups at the hip, stifle and tarsus at 0, 3 and 6 weeks are reproduced in Table 1.

TABLE 1. Mean standing angles in hindlimbs (^{o}) in all groups

Time	Left Hip	Right Hip	Left Stifle	Right Stifle	Left Tarsus	Right Tarsus
Week 0	98.22	99.27	140.11	139.72	132.77	132.27
Week 3 (postop.)	100.94	99.05	144.44	136.27	145.16	136.27
Week 6 (postop.)	98.16	98.33	144.11	133.66	141.94	135.44

Comparing (using the paried sample student t-test) the preoperative values of group 1 (10% femur ostectomy) to the postoperative values at 3 respectively 6 weeks after surgery, of statistically significance ($p<0.05$) was the increase (2.7^0) in the standing angle of the hip at three weeks postoperatively. The standing angle of the left stifle was marginally significant ($p<0.05$) and increased 2.4^0 at six weeks postoperatively. Statistically insignificant was an increase with 2.12^0 in the left tarsus. A marginal statistical significance in the second group (15% - ostectomy) was an increase of the angle of the left tarsus ($p<0.05$) with 2.3^0 at three weeks postoperatively. In the third group (20% ostectomy) of significance ($p<0.05$) was an increase in the standing angle of the left stifle with 4.2^0 at three weeks postoperatively. At six weeks postoperatively a decrease in the standing angle of the right stifle with 3.07^0 ($p<0.05$) was noted.

An increase in the standing angle of the tarsal joint with 1.98^0 at three weeks and 1.48^0 at six weeks postoperatively was not statistically significant ($p<0.05$).

Comparing statistically the standing height (iliac crest to floor) of significance ($p<0.05$) was the decrease with 3.22cm on the left hindlimb in the 20% group six weeks after surgery. Marginally significant was the decrease in the contralateral femur at this time (six weeks after surgery) with 2.44cm. When comparing the operated to the unoperated limb at three weeks after surgery of statistical significance ($p<0.05$) was the standing height difference between the left and right hindlimb.

Mean thigh circumference in the left hindlimb decreased from 28.88cm to 27.20 at three weeks postoperatively, and was at 27.51cm at six weeks after the surgery (Table 2).

TABLE 2. Mean thigh circumference of hindlimbs (cm) in all groups

Time	Left	Right
Week 0	28.88	28.88
Week 3 (postop.)	27.20	29.09
Week 6 (postop.)	27.51	29.35

The contralateral thigh increased overall from 28.88cm preoperatively to 29.35cm, at six weeks after the surgery. Thigh circumference decrease in the left hindlimb at three and six weeks after surgery was statistically significant in all three groups. The mean standing height measured from the iliac crest to the floor in the left hindlimb, did decrease to some extent from 49.83cm to 48.82cm at six weeks postoperatively (Table 3). Of statistical significance was the decrease in the standing height of the left hindlimb at six weeks postoperatively (20% group) with 3.22cm. Marginally significant ($p<0.05$) was a decrease in the contralateral (right) standing height with 2.44cm.

TABLE 3. Mean standing height of hindlimbs (cm) in all groups

Time	Left	Right
Week 0	49.83	49.86
Week 3 (postop.)	49.43	49.79
Week 6 (postop.)	48.82	49.29

Total left hindlimb length (iliac crest to pads) measured at euthanasia (six weeks postoperatively) and compared to total right hindlimb length was statistically significant (right = 52.79cm, left = 50.92cm). Overall gait evaluation, considering 1 = normal, varied significantly ($p<0.05$) to 2.05 at three weeks after surgery, and was at 1.22 ($p<0.05$) six weeks after surgery. When comparing each group to its preoperative gait values (n = 1) there was a statistical significant difference between the normal gait and the gait at three respectively at six weeks after surgery (Fig. 4,5,6). A statistical significant improvement in gait is observed when comparing the gait at three weeks to the gait at six weeks postoperatively (Table 4).

TABLE 4. Visual gait evaluation values*

Case #	% Ostectomy	Gait at 3 weeks	Gait at 6 weeks
1	10	2	1
2		2	1
3		2	1
4		1	1
5		1	1
6		3	2
7	15	2	1
8		2	1
9		1	1
10		1	1
11		2	1
12		2	1
13	20	4	3
14		2	2
15		2	1
16		2	1
17		2	1
18		3	1

* See page 10 lameness categorization

RADIOGRAPHIC FINDINGS

Radiographs immediately after surgery verified correct implant positioning, respectively loose implants in dog 1, five days postoperatively. Radiographs made at six weeks after surgery revealed no implant migration, signs of osteomyelitis, osteopenia or degenerative osteoarthrosis.

Five fractures had contact healing, six fractures healed by gap healing whereas in seven cases healing occurred with varying amounts of callus formation (Fig. 7,8,9). An incidental finding was anterior bowing of the contralateral femur (Fig. 10), being more pronounced in the 20% ostectomy group.

PATHOLOGICAL FINDINGS

Macroscopic Findings

At necropsy, there was sufficient healing in all femurs to maintain bone shape after removing the plates. Bone shape though was fairly altered in the 20% ostectomy group. Gross examination of the joints on the operated limb did not reveal any cartilagenous defects. There was no excessive joint fluid formation within the hip, stifle and tarsal joints.

When compared to the contralateral limb it was noticed that in 50% of the the 20% ostectomy group there was anterior bowing of the right femur (Fig. 12). In the second group (15% ostectomy) in two dogs anterior bowing was noticed (Fig. 11) to a lesser extent.

HISTOLOGIC FINDINGS

Microscopical findings corresponded largely to the results on gross examination. Examination of the histologic sections of the adult articular cartilage showed a smooth cartilagenous surface with a sparse cellularity and heterogeneity of cell population and distribution. The specimens were evenly stained and showed normal zones of adult articular cartilage.

In two sections to the left hindlimb the aceta bulum in one dog respectively the proximal tibia in the other dog, showed early signs of degenerative joint disease. A disturbed arrangement of cells, within the sliding zone of the tangential layer was noted along with some cell cluster formation in the tangential layer. No other changes such as fibrillation of the articular cartilage with subchondral capillary penetration or subchondral bone sclerosis all compatible with early osteoarthritis were seen.

The synovial membrane specimens to the stifle were all of normal conformation. No thickening of the synovium, cellular infiltrates or living cell abnormalities were found.

DISCUSSION

No substantiated data in the veterinary literature is available that indicates how much the femur in a mature dog can be shortened without significantly affecting ambulation. Shortening of 1 to 2cm can be tolerated by most dogs and cats.[3] Thus there is a general belief that a considerable amount (?) of bone loss with resultant shortening of the limb can occur, particularly in animals that have an angulated stifle and tarsus, without affecting their gait to any great degree.

This study showed that unilateral ostectomies of 10%, 15% and 20% of the mid-femoral diaphysis did not have a long term significant effect on ambulation in mature dogs. The dogs (18) used in this study were German Shorthair Pointers (5), Brittanys (6), Coonhounds (4) and three medium size Mongrel dogs. Different results could have been possible upon selecting dogs with a straighter angulation in their hindlimbs (Boxer, Chow-Chow).

Overall there was an increase in all three groups in the standing angles to the left hindlimb. The most significant was an increase in the standing angle of the left stifle (4.2) in the 20% ostectomy group at six weeks postoperatively. Interestingly the dogs accommodated partly by decreasing the standing angle of the right stifle with 3.07°.

A decrease in muscle mass to the thigh on the operated limb was due to postoperative disuse atrophy. A decrease of 3.22cm in the standing height of the left hindlimb at six weeks after surgery (20% group) along with a decrease in the contralateral standing height with 2.44, at the same time, shows again accommodation to the new shorter left hindlimb. Total left hindlimb length (iliac crest to pads) measured at euthanasia was with 1.87 cm shorter in the left hindlimb.

The dog's gait improved continuously throughout the experiment. At six weeks postoperatively all dogs (Groups 1,2 and 3) had usage of their left hindlimb. Every dog was weight bearing. All dogs but three (all groups) had excellent usage of their limb. The dogs were able to run, jump and turn without lameness. Each animal had full range of motion in all the joints to the hindlimb. There was no evidence of pain and/or crepitation upon palpation of the left hindlimbs. Two dogs started to limp after exercising longer than five minutes. These two dogs had full range of motion to the hindlimb joints and there was no evidence of pain or crepitation on palpation. Slight evidence of muscle atrophy was present. In one dog of the 20% ostectomy group lameness was evident while walking though the dog was bearing full weight. When standing the dog would on occasion favor the leg. Pain and/or crepitation was not evident upon palpation. Moderate muscle atrophy was present. No explanation for the third degree lameness in this dog was found. The dog's gait improved from three weeks postoperatively to six weeks postoperatively and evidence of lameness was present only in the above mentioned dog with a 20% ostectomy.

Radiographic, gross and histopathological evaluation of the joints and the bones to the hindlimbs revealed an anterior bowing of the unoperated femur in the 20% ostectomized dogs (Fig. 11) and to a lesser extent in the 15% ostectomy group (Fig. 10, 11). The bowing was the most in the dog showing the third degree lameness at six weeks postoperatively (Fig. 10, 12). Signs of mucoid degeneration to the sliding layer of the tangential zone were present in two dogs. In one dog the changes involved the acetabular cartilage where as in the other dog the proximal tibia was involved. Signs of cell cluster formation within the tangential layer in these two specimens suggested early degenerative joint disease.

Whereas unilateral surgical procedures can produce angular and torsional deformities in the contralateral limb in growing animals[12,13] it has not yet been reported in healthy skeletally mature dogs. It was suggested that altered load bearing and posture were instrumental in producing the observed bone deformities.[14]

The suggestion that functional limb loading can modify developing bone is exemplified by femoral studies.[15,16,17] In these studies, post fracture torsional deformities appeared to undergo degrees of spontaneous correction following resumption of normal weight bearing. Further studies are needed to complement and expand our findings. Platform scale measurements (force plate measurements) along with a longer follow up time period. We conclude that unilateral mid-diaphyseal femoral shortening with 10, 15 and 20% in skeletally mature dogs does not significantly alter locomotor function.

BIBLIOGRAPHY

1. Phillips IR. A survey of bone fractures in the dog and cat. J Sm Anim Pract 20:661-674; 1979.
2. Schurrle G. Femurschaftfrakturen beim Hund. Behandlung und Ergebnisse in den Jahren 1970-1977. Doctoral Dissertation, Munich; 1979.
3. Newton CD. Fracture of the femur. In: Textbook of Small Animal Orthopaedics. Edited by Charles D. Newton, David M. Nunamaker. J.B. Lippincott Company, Philadelphia; 1985.
4. Hohn RB. Plate fixation of comminuted femoral shaft fractures in the dog. JAVMA 162:646-647; 1973.
5. Thimel H. Die Femurfraktur beim Hund, Behandlung, Komplikationen und Ergebnis in den Jahren 1959-1969. Doctoral Dissertation, Munich; 1971.
6. Luiggi A. Die Brunchfestigkeit des Knochen des Hundes. Doctoral Dissertation, Zurich; 1951.
7. Tamas PM, Paddleford RR, Krahwinkel, Jr. DJ. Thoracic trauma in dogs and cats presented for limb fractures. JAAHA 21:161-166; 1985.
8. Hunt JM, Aitken ML, Denny HR, et al. The complications of diaphyseal fractures in dogs: A review of 100 cases. J Sm Anim Pract 21:103-119; 1980.
9. Milton JL, Newman ME. Fractures of the femur. In: Textbook of Small Animal Surgery. Edited by Douglas H. Slatter. W.B. Saunders Company, Philadelphia; 1985.
10. Braden TD, Brinker WO. Radiologic and gross anatomic evaluation of bone healing in the dog. JAVMA 169:1318-1323; 1976.
11. Key JA. The effect of a local calcium depot on osteogenesis and healing of fractures. J Bone Joint Surg 16(A):176-184; 1934.
12. Duff SRI. Histopathology of growth plate changes in induced abnormal bone growth in lambs. J Comp Path 96:15-23; 1986.

13. Duff SRI. Excision arthroplasty of the canine hip joint. A clinical and experimental study. M.V.M. Thesis. University of Glasgow, Scotland; 1975.

14. Duff SRI. Morphological and radiological findings in induced abnormal bone growth in lambs. J Comp Path 96:3-13; 1986.

APPENDIX

Figure 1

A. Patient positioned in right lateral recumbency.

B. Lateral approach to the femoral shaft

1. biceps femoris m.
2. vastus lateralis m.
3. adductor magnus m.

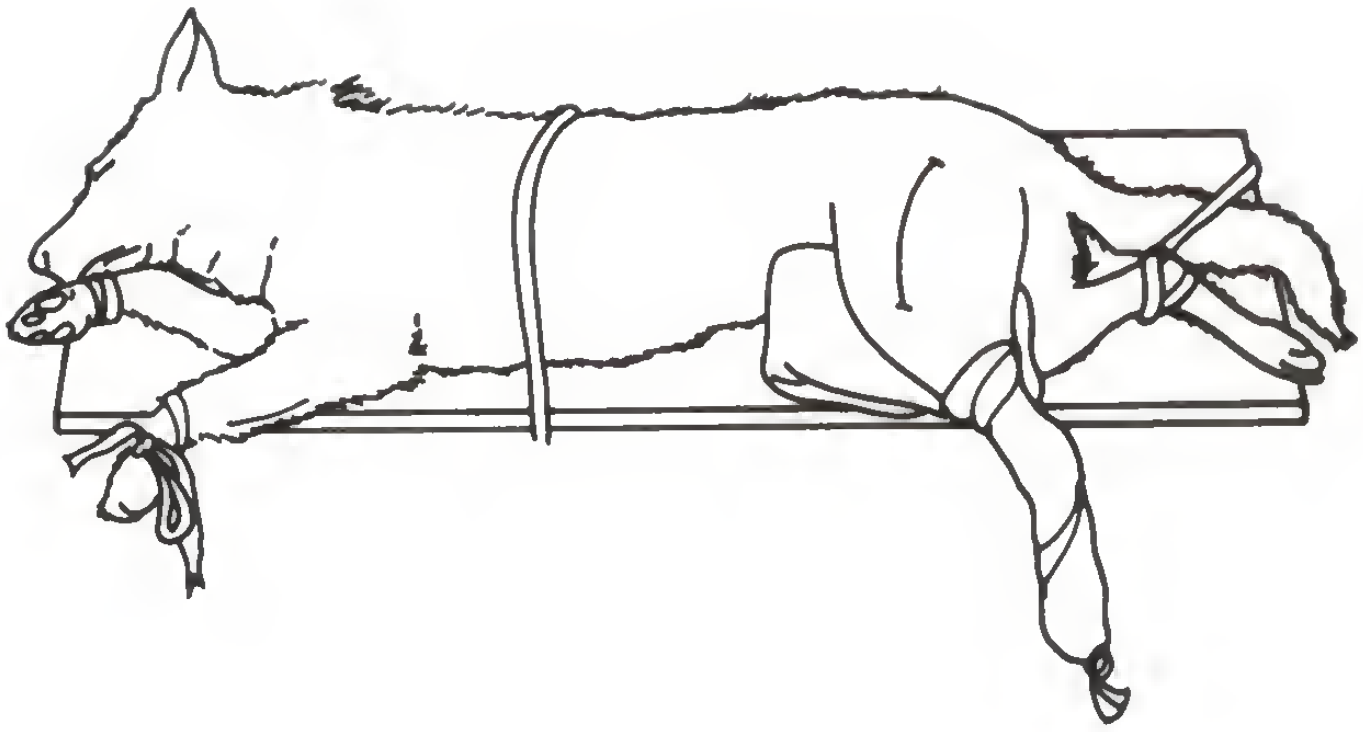

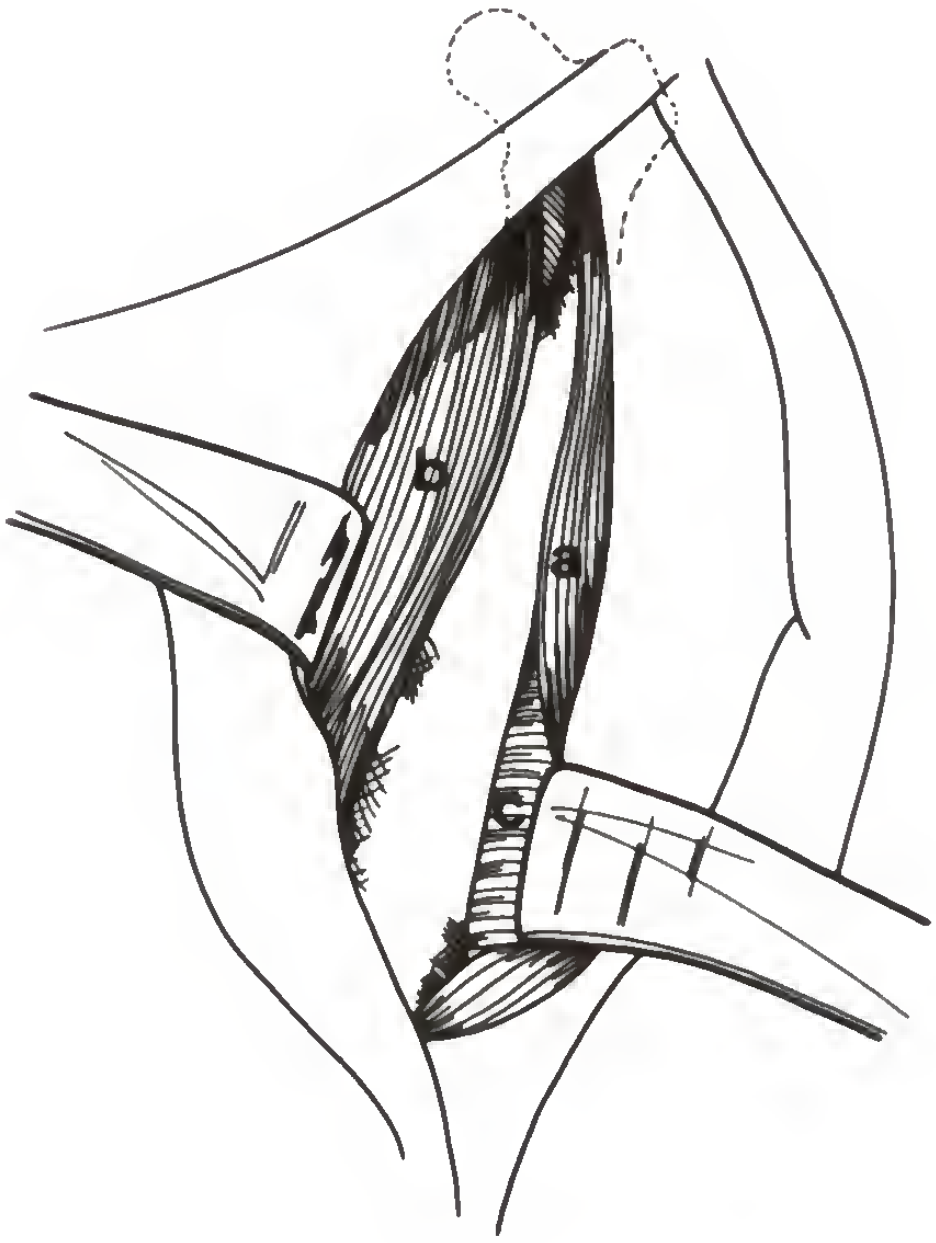
b
a
c

Figure 2

A	B
C	D

A. Measurement of total femoral length. Placement of K-wires (perpendicular to femur and parallel to each other) in the most proximal part of greater trochanter and in between condyles and tibial plateau. Ruler is elevated from bone for "graphic" purposes.

B. Marking of mid-diaphyseal point.

C. Mid-diaphyseal osteotomy. Using a power driven oscillating saw.

D. Lateral plate application, with Verbrugge bone-holding forceps, following diaphyseal alignment, post-segmental ostectomy.

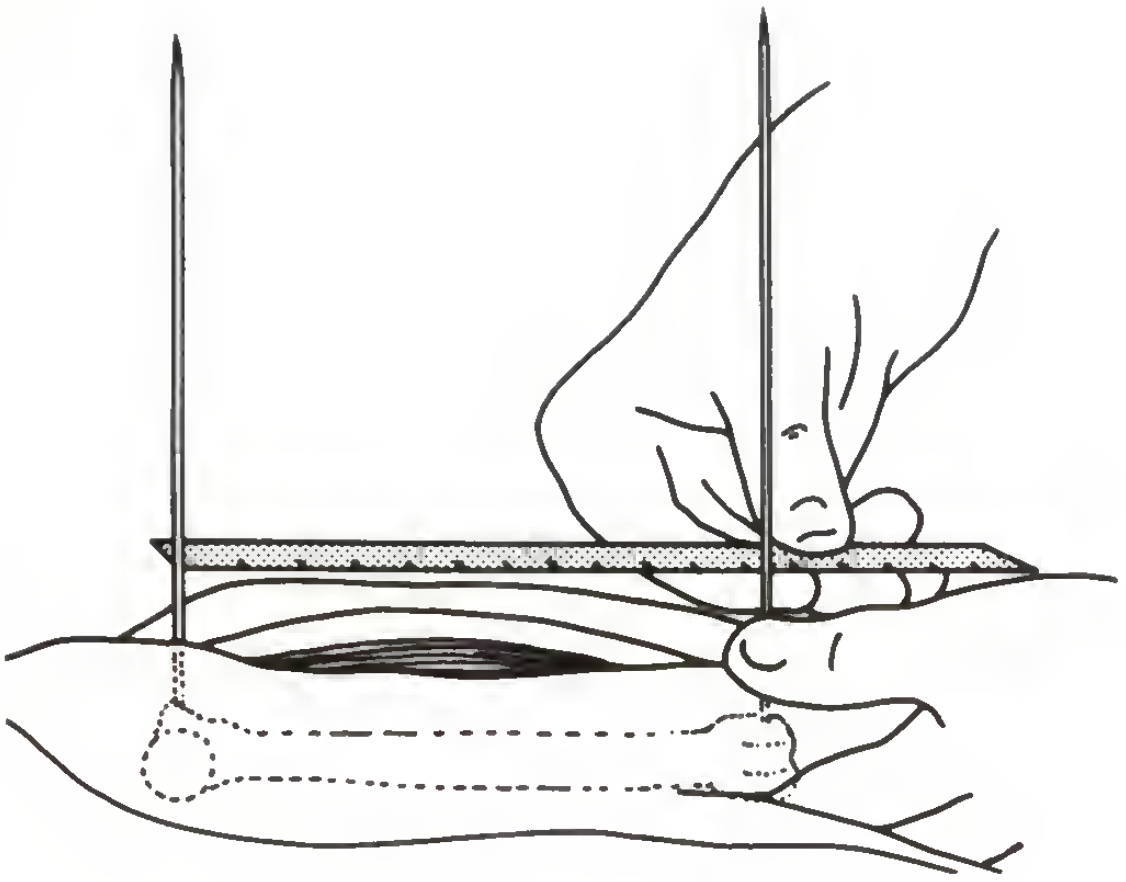

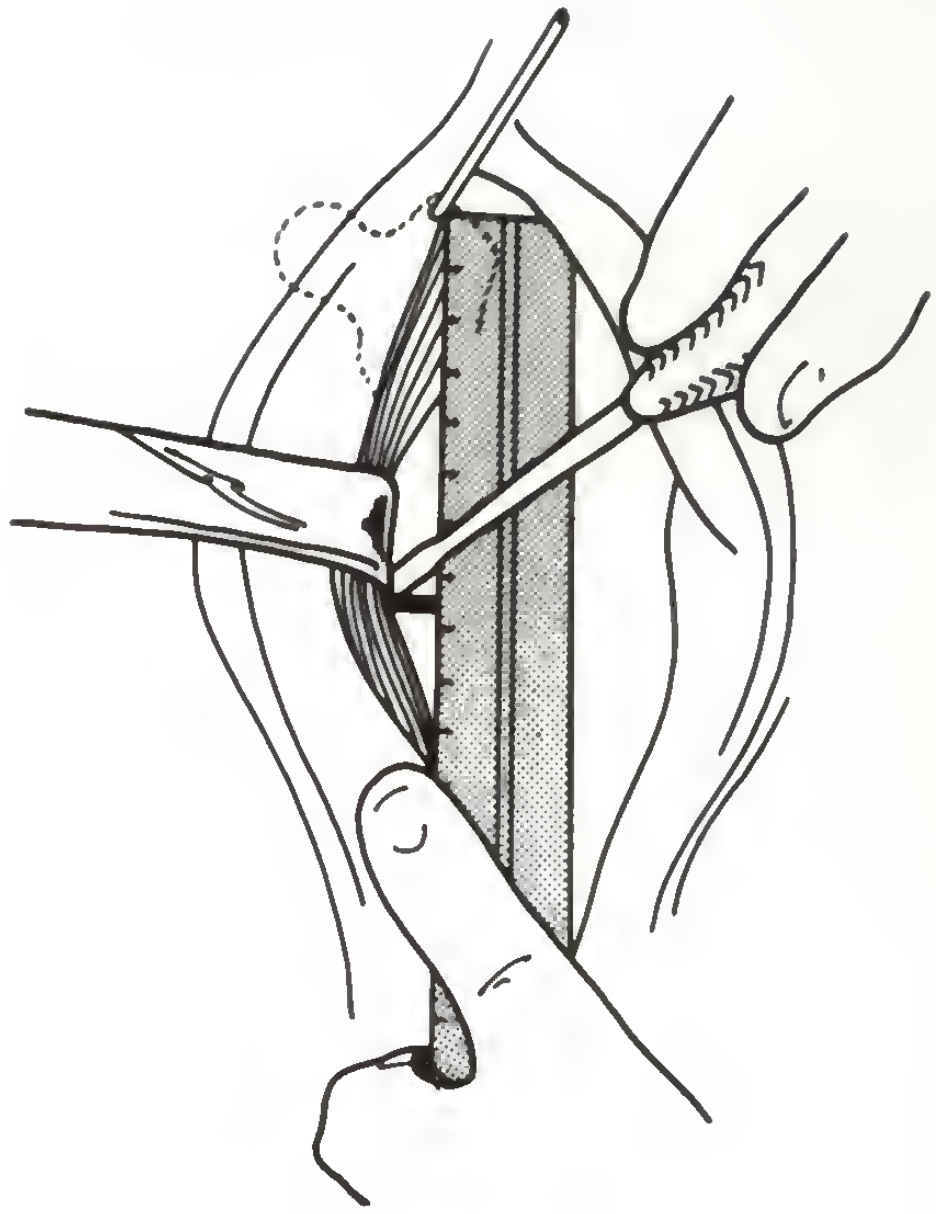

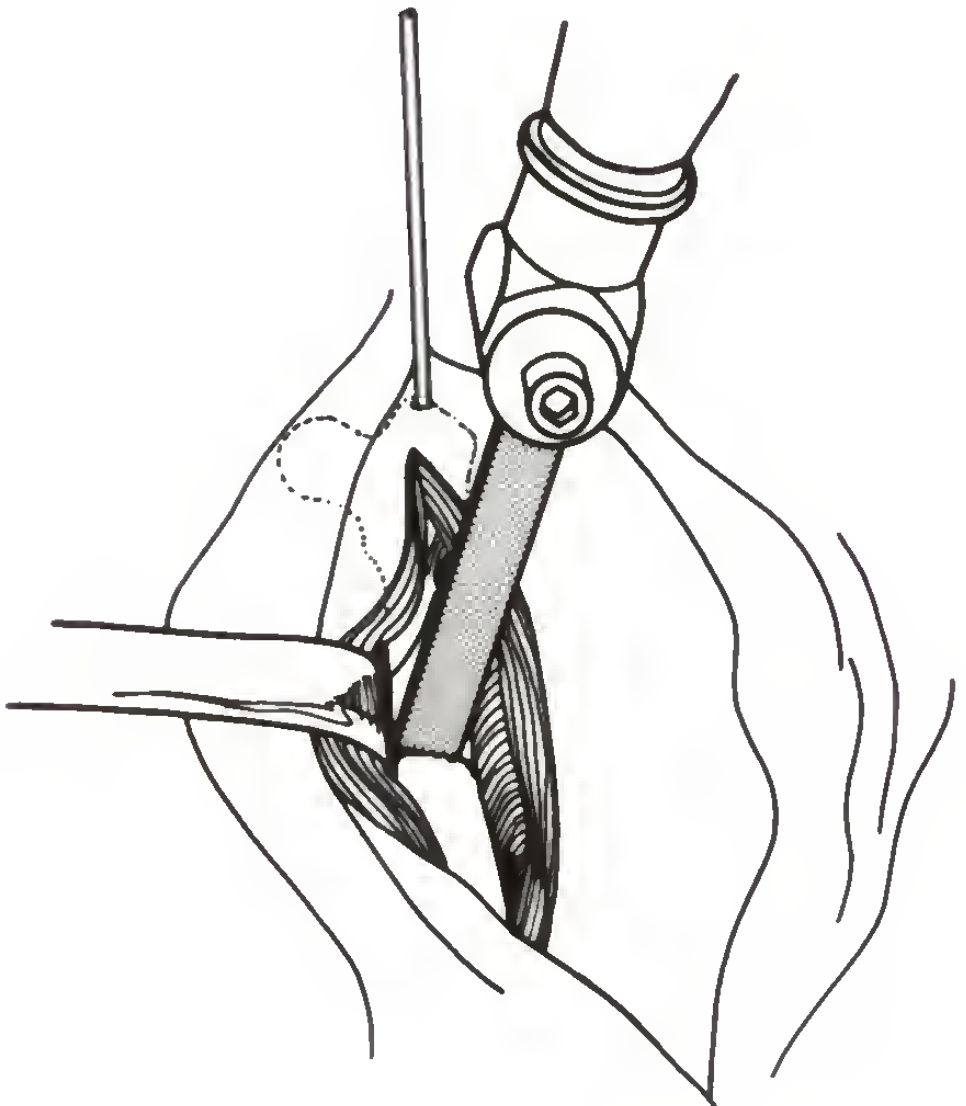

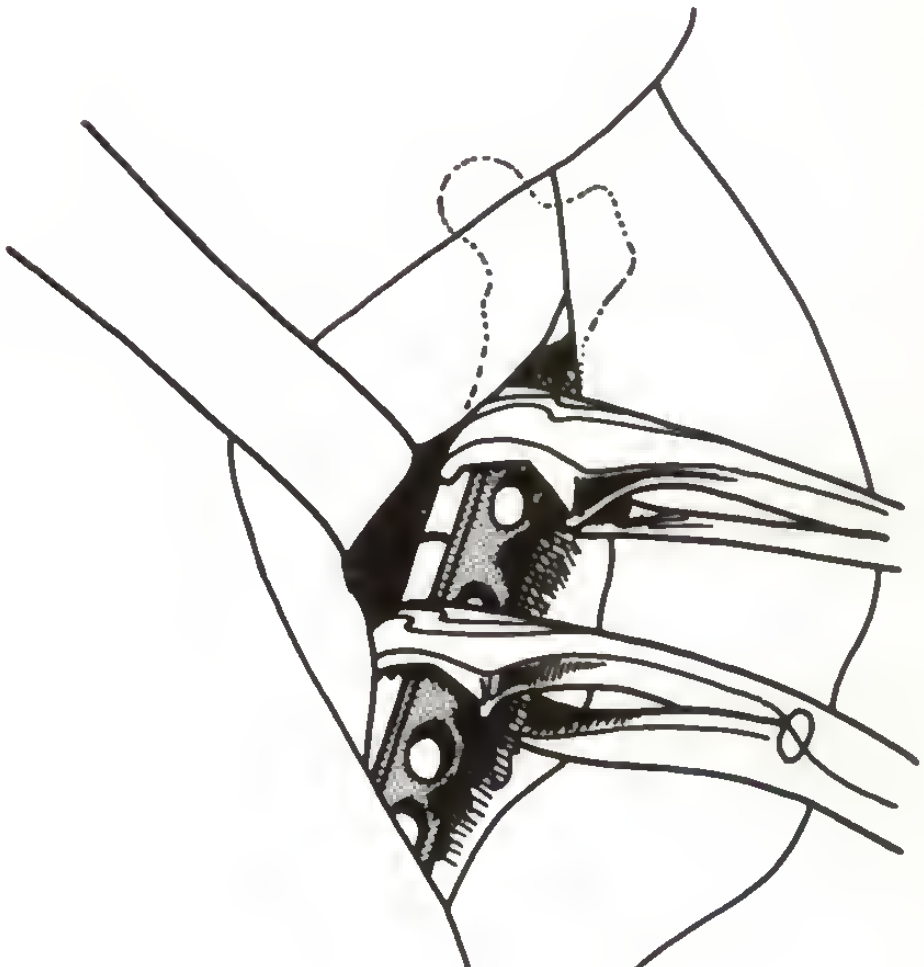

Figure 3

Plate and screw placement used in all ostectomized femurs.



Figure 4

Group 1 (10% ostectomy)

A	B
C	D
E	F

A. Dog in normal weight bearing position three weeks after surgery.

B. Dog walking three weeks following surgery.

C. Weight bearing stance six weeks postoperatively.

D. Normal walk six weeks following ostectomy.

E. Shortened limb (when standing on hindlegs) is more extended and less weight bearing. Three weeks after surgery.

F. Operated leg is shorter and standing angles are wider when compared to unoperated limb. Six weeks post femurostectomy.

Figure 5

Group 2 (15% ostectomy)

A	B
C	D
E	F

A. Dog in weight bearing stance prior to surgery.

B. Dog in weight bearing stance six weeks after surgery.

C. Walking dog prior to ostectomy.

D. Full weight bearing walk three weeks postoperatively.

E. Ostectomized limb is more extended and less weight bearing.

F. Normal, full weight bearing walk six weeks after surgery.

Figure 6

Group 3 (20% ostectomy)

A	B
C	D
E	F

A. Weight bearing stance three weeks after surgery. Left hindlimb with standing angles more extended than right hindlimb.

B. Same as A. six weeks after surgery. Left hindlimb with wider standing angles at stifle and tarsus.

C. Normal walk before surgery.

D. Full weight bearing walk at three weeks postoperatively.

E. Note shorter and less weight bearing left hindlimb, at six weeks postoperatively.

F. Full weight bearing at six weeks after surgery. No lameness.

Figure 7

(10% ostectomy)

A	B
C	D

A. Preoperative ventrodorsal radiograph of pelvis, femurs and stifles.

B. Ventrodorsal projection at six weeks postoperatively. Healed ostectomy site. Observe shorter left limb.

C. Lateral, postoperative surgery radiograph.

D. Six weeks after surgery. Lateral projection.

Figure 8

(15% ostectomy)

A	B
C	D

A. Preoperative ventrodorsal radiograph of pelvis, femurs and stifles.

B. Ventrodorsal view of healed ostectomy site at six weeks after surgery.

C. Postoperative (lateral) survey radiograph.

D. Lateral view of healed ostectomy site at six weeks postoperatively.

Figure 9

(20% ostectomy)

A | B
C | D

A. Preoperative ventrodorsal radiograph of pelvis, femurs and stifles.

B. Six weeks postoperatively.

C. Postoperative (lateral) survey radiograph.

D. Lateral view of ostectomy site, six weeks after surgery. Ostectomy gap still evident.

Figure 10

A	B
C	D
E	F

A. Lateral view of contralateral femur at 10% ostectomy.

B. Lateral view of contralateral femur at 10% ostectomy.

C. Lateral view of contralateral femur at 15% ostectomy.

D. Lateral view of contralateral femur at 15% ostectomy with evidence of anterior bowing. See arrow.

E. Lateral view of contralateral femur with anterior bowing (at 20% ostectomy).

F. Lateral view of contralateral femur with some anterior bowing (at 20% ostectomy).

Figure 11

A

B|C

D

E|F

A. Comparison of femoral shaft shape, after 10% ostectomy between right (R) and left (L) femur. Six weeks postoperatively.

B. Ventrodorsal view of right femur.

C. Lateral view of right femur.

D. Right and left femur, six weeks after 15% ostectomy.

E. Ventrodorsal view of right femur.

F. Lateral view of right femur.


L
R
0 cm 1 2 3 4 5 6 7 8 9 10 11 12 13 14 15
2818


R
2818


R
0 cm 1 2 3 4 5 6 7 8 9 10 11 12 13 14 15 16
2818


L
R
0 cm 1 2 3 4 5 6 7 8 9 10 11 12 13 14 15 16
2820


R
2820


R
2820

Figure 12

A
B | C
D
E | F

A. Comparison of femoral shaft shape after 20% ostectomy between right (R) and left (L) femur.

B. Ventrodorsal view of right femur.

C. Lateral view of right femur. Note anterior bowing of femur.

D. Comparison of femoral shaft shape after 20% ostectomy.

E. Ventrodorsal view of right femur.

F. Lateral view of right femur.


L
R
2669


R
2669


R
2669


L
R
2821


R
2821


R
2821

POST-OPERATIVE EFFECTS OF FEMUR SHORTENING
IN THE MATURE DOG

by

DIETRICH FRANCZUSZKI

Dr. med. vet., Ludwig Maximilians University
Munich 1978

AN ABSTRACT OF A MASTER'S THESIS

Submitted in partial fulfillment of the
requirements for the degree

MASTER OF SCIENCE

Department of Surgery and Medicine
Kansas State University
Manhattan, Kansas

1986

ABSTRACT

This study was undertaken to determine whether 20% of the mid-femoral diaphysis can be removed, in mature dogs, without significantly affecting weight bearing. Eighteen mature dogs were used. The arbitrary decision to ostectomize 10%, 15% and 20% of the mid-femoral diaphysis was selected. The midpoint of the femoral diaphysis was established by measuring total femoral length in a lateral projection allowing to make the proper conclusion as to the number of centimeters of bone to be removed (thus assuring the adequate percentage of bone to be resected). Following the ostectomy a dynamic compression plate* was used to repair the "fracture". Four cortical screws being placed in the proximal and four in the distal fracture fragment.

The dogs were studied for six weeks postoperatively. The standing height thus being the distance from the craniodorsal aspect of the iliac crest to the floor was measured. Each joint angle (hindlimbs) was measured with a goniometer the dog being in a standing weight bearing position. Additionally the thigh circumference of both femurs was measured. To document gait and/or weight bearing photographs of the dogs were taken while walking and standing. Following euthanasia total hindlimb length was established (from craniodorsal aspect of the iliac crest to the palmar surface of the pads) with the limb being maximally extended.

The progress of healing along with joint surfaces to the shortened limb were assessed clinically, radiographically and followed with gross and histological examination. The contralateral hindlimb served as a control in each dog. Results indicate that dogs having had 10, 15 and 20 percent of their femoral diaphysis removed accommodate well by an increase in the standing angles of the shortened limb. Gait evaluation at three, respectively six weeks after surgery indicate full usage of their shortened limb.

* Dynamic Compression Plate, Synthes, Synthes Ltd., Wayne, PA 19087.