

This is the author's final, peer-reviewed manuscript as accepted for publication. The publisher-formatted version may be available through the publisher's web site or your institution's library.

Preliminary findings of a previously unrecognized porcine primary immunodeficiency disorder

Ada Giselle Cino Ozuna, Raymond R. R. Rowland, Jerome C. Nietfeld, Maureen A. Kerrigan, Jack C. M. Dekkers, Carol R. Wyatt

How to cite this manuscript

If you make reference to this version of the manuscript, use the following information:

Cino Ozuna, A. G., Rowland, R. R. R., Nietfeld, J. C., Kerrigan, M. A., Dekkers, J. C. M., & Wyatt, C. R. (2013). Preliminary findings of a previously unrecognized porcine primary immunodeficiency disorder. Retrieved from <http://krex.ksu.edu>

Published Version Information

Citation: Cino Ozuna, A. G., Rowland, R. R. R., Nietfeld, J. C., Kerrigan, M. A., Dekkers, J. C. M., & Wyatt, C. R. (2013). Preliminary findings of a previously unrecognized porcine primary immunodeficiency disorder. *Veterinary Pathology*, 50(1), 144-146.

Copyright: © The Author(s) 2012

Digital Object Identifier (DOI): doi:10.1177/0300985812457790

Publisher's Link: <http://vet.sagepub.com/content/50/1/144>

This item was retrieved from the K-State Research Exchange (K-REx), the institutional repository of Kansas State University. K-REx is available at <http://krex.ksu.edu>

Preliminary findings of a previously unrecognized porcine primary immunodeficiency disorder

Ada Giselle Cino Ozuna¹, Raymond R. R. Rowland¹, Jerome C. Nietfeld¹, Maureen A. Kerrigan¹, Jack C. M. Dekkers², Carol R. Wyatt¹

¹ Department of Diagnostic Medicine/Pathobiology, Kansas State University, Manhattan, KS

² Department of Animal Science, Iowa State University, Ames, IA

Corresponding author: C. R. Wyatt, Department of Diagnostic Medicine/Pathobiology, College of Veterinary Medicine, 1800 Denison Ave, Manhattan, KS 66506-5606, Phone number: 785-532-4407, Fax: 785-532-4039, e-mail: cwyatt@vet.k-state.edu

Abstract

Weaned pigs from a line bred for increased feed efficiency were enrolled in a study of the role of host genes in the response to infection with Porcine Reproductive and Respiratory Syndrome Virus (PRRSV). However, 4 of the pigs were euthanized early in the study due to weight loss with poor body condition and illness; 2 pigs, before PRRSV infection, and the other 2, approximately 2 weeks after virus inoculation. The 2 inoculated pigs failed to produce PRRSV-specific antibodies. Gross findings included pneumonia, absence of a detectable thymus, and small secondary lymphoid tissues. Histologically, lymph nodes, spleen, tonsils, and Peyer's patches were sparsely cellular with decreased to absent T and B lymphocytes.

Keywords

Clinical pathology, immunohistochemistry, lymphoid tissues, pig diseases, primary immunodeficiency

One hundred pigs from each of 2 Yorkshire lines divergently selected for feed efficiency¹ were enrolled, at 2-4 weeks of age, in a study of the genetic influence on response to Porcine Reproductive and Respiratory Syndrome virus (PRRSV) infection. Pigs were arbitrarily distributed into pens of 16-18 pigs, with 1 week's acclimation before inoculation with PRRSV isolate NVSL97-7985.⁵

Four pigs from the increased feed efficiency line developed poor body condition and illness, and were euthanized prematurely. Pig No. 4, a gilt, weaned at 16 days of age, was infected with PRRSV at 38 days, and euthanized at 54 days. Pig No. 6, a barrow, weaned at 27 days of age, was infected with PRRSV at 36 days and euthanized at 47 days. Pig Nos. 109 and 124 were barrows that had been weaned at 21 and 28 days of age, respectively, and were euthanized at 34 and 41 days of age, respectively, before they could be inoculated with PRRSV. The pigs were from 4 different litters, but pig Nos. 4, 6, and 124 had the same sire.

At necropsy, each of the 4 pigs had a rough hair coat and was smaller than other pigs in the study. Thymus was not visible, lymph nodes were small, and ileal Peyer's patches were inconspicuous. Pig No.4 had fibrinosuppurative bronchopneumonia, pig No. 6 had fibrinous synovitis in both tarsal joints, and pig No. 124 had dermatitis. *Streptococcus suis* was cultured from lung of pig No. 4.

Lung, heart, kidneys, stomach, liver, lymph nodes, spleen, tonsils, nasal turbinates, and intestine were submitted to the Kansas State Veterinary Diagnostic Laboratory for histopathology. The lymph nodes (Fig. 1) and spleen (Fig. 2) from the 4 pigs had abnormal architecture with decreased numbers of lymphocytes and absence of lymphoid follicles. The tonsils and Peyer's patches also had markedly reduced numbers of lymphocytes and absence of follicles. Pig Nos. 6 and 109 had interstitial pneumonia and pig No. 109 had cytomegaloviral inclusions in epithelial cells of nasal submucosal glands and renal tubules.

T and B lymphocytes were identified by immunohistochemistry (IHC) using rabbit anti-human CD3 polyclonal antibody, or mouse anti-human CD79 α monoclonal antibody, respectively, followed by biotinylated goat anti-rabbit or anti-mouse immunoglobulin with avidin-HRPO and DAB chromagen (Ventana Medical), and counterstained with hematoxylin. CD3⁺-positive lymphocytes were markedly

decreased in number in lymph nodes (Fig. 3), and were nearly absent from the spleen (Fig. 4). CD79a⁺-positive lymphocytes were few in the lymph nodes (Fig. 5) and absent from the spleen (Fig. 6).

Histiocytic cells comprised the predominant cell population in lymphoid tissues. Hemosiderin-laden macrophages were identified by positive reaction with Prussian blue staining in lymph node sections.

Viremia was quantified by standardized RT-PCR assays (Applied Biosystems, Foster City, CA or Tetracore, Rockville, MD). Results were reported as copies of RNA per PCR reaction volume. On Day 0, all pigs were PRRSV-negative by RT-PCR. By Day 4 post inoculation, all pigs were PRRSV-positive by RT-PCR, and remained positive through Day 11 post inoculation (Table 1). PRRSV-specific serum antibodies were detected using a standardized ELISA test (PRRS X3, IDEXX Laboratories, Westbrook, ME). Results were reported as a sample/positive (S/P) ratio. On Day 4 after inoculation, all pigs were seronegative by ELISA. On Day 11, pig Nos. 4 and 6 remained negative, whereas all other infected pigs had an antibody response to PRRSV. These data suggest that the affected piglets were incapable of initiating an antibody response after PRRSV inoculation.

Infection by porcine circovirus Type 2 (PCV2) can result in lymphocyte depletion in lymphoid tissues. Co-infection with PCV2 and PRRSV can result in post-weaning multisystemic wasting syndrome.^{3,4} Although all inoculated pigs were positive for PRRSV by RT-PCR, PCV2 antigen was not detected by IHC in lymph node or lung sections from the 4 affected piglets, indicating that they did not have PCV-associated disease. There were no clinical signs or morphologic lesions to suggest infection by any other pathogens known to cause lymphoid depletion in pigs, indicating that lymphoid hypoplasia was not a result of infection. Subsequent matings of the parents of these pigs have produced approximately 22% of piglets per litter with similar histologic lesions, suggesting that the affected pigs had a primary immunodeficiency.²

Although the PRRSV isolate used in this study normally results in seroconversion within 11 days post inoculation, the 2 inoculated pigs failed to mount a measurable antibody response. All 4 pigs had a near absence of T and B lymphocytes in undersized secondary lymphoid tissues. No pathogens known to cause secondary immunodeficiencies were detected, and subsequent matings of the parents of the affected

pigs produced offspring with similar lesions. Collectively, these findings are consistent with an inherited primary immunodeficiency disorder.

Acknowledgements

The feed efficiency lines of pigs were developed with funds from the Iowa Agriculture and Home Economics Experiment Station, Ames, Iowa, U.S.A. (Project No. 3600) and from the ISU Center for Integrated Animal Genomics, and supported by Hatch Act. The PRRSV infection trial was part of Agriculture and Food Research Initiative Competitive Grant no. 2011-68004-30336 from the USDA National Institute of Food and Agriculture. The authors thank Dr. Amanda Beck (KSU) for in-house review of the manuscript for accuracy of the pathology descriptions.

References

1. Cai WD, Casey DS, Dekkers JCM. Selection response and genetic parameters for residual feed intake in Yorkshire swine. *J Anim Sci.* 2008;86:287-298.
2. Fischer A, Cavazzana-Calvo M, de Saint Basile G, et al. Naturally occurring primary deficiencies of the immune system. *Annu Rev Immun.* 1997;15:93-124.
3. Ladekjaer-Mikkelsen AS, Nielsen J, Stadejek T, et al. Experimental reproduction of postweaning multisystemic wasting syndrome (PMWS) in pigs experimentally infected with porcine circovirus type 2 (PCV2). *Vet Microbiol.* 2002;89:97-114.
4. Nielsen J, Vincent IE, Botner A, et al. Association of lymphopenia with porcine circovirus type 2 induced postweaning multisystemic wasting syndrome (PMWS). *Vet Immunol Immunopathol.* 2003;92:97-111.
5. Truong HM, Lu Z, Kutish GF, Galeota J, Osorio FA, Pattnaik AK. A highly pathogenic porcine reproductive and respiratory syndrome virus generated from an infections cDNA clone retains the in vivo virulence and transmissibility properties of the parental virus. *Virology.* 2004;325:308-319.

Reprint requests should be sent to Dr. C. R. Wyatt, 1800 Denison Ave., Manhattan, KS 66506. E-mail: cwyatt@vet.k-state.edu

Figures

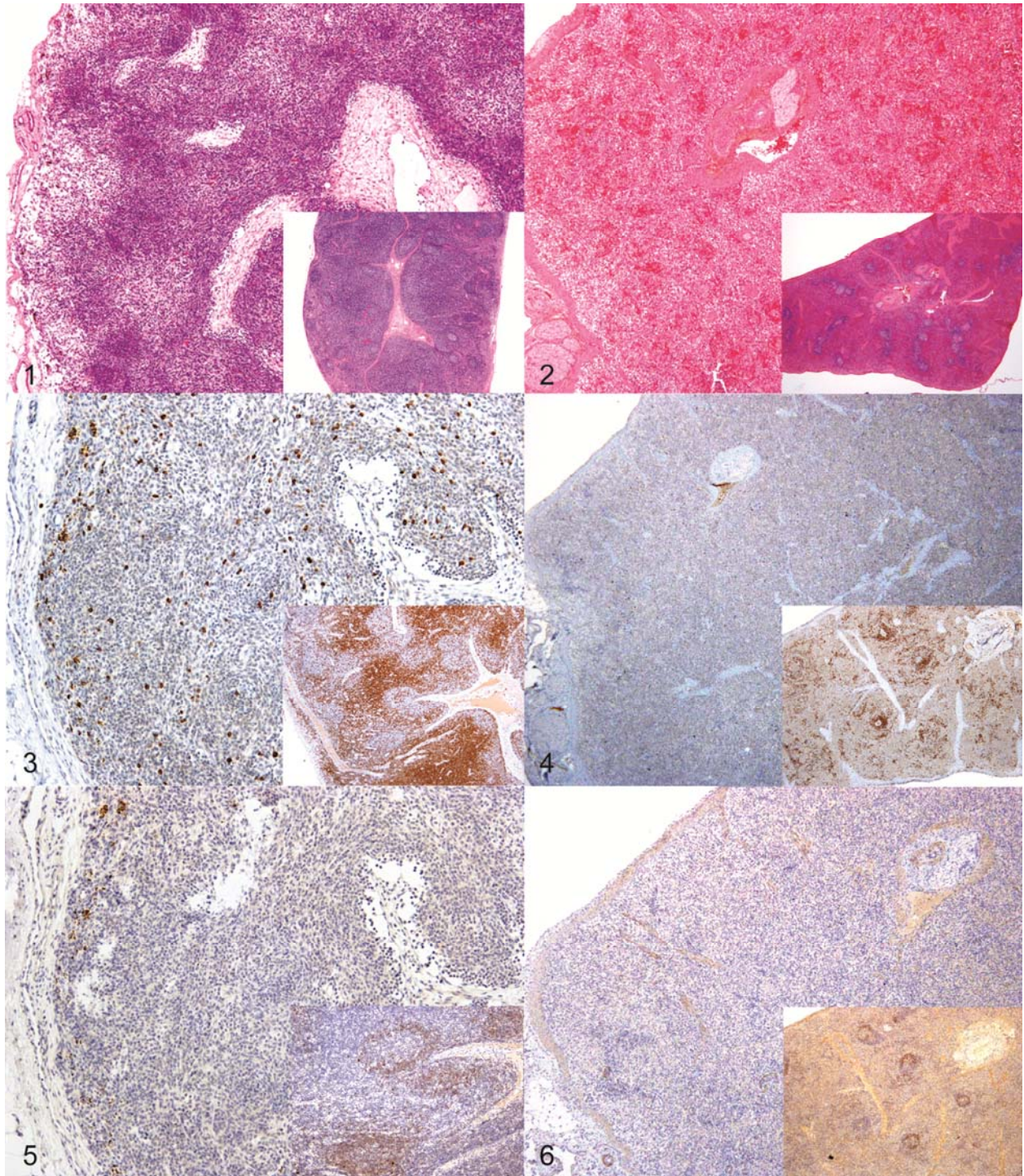


Figure 1. Lymph node; pig No. 6. The paracortex is hypocellular due to a markedly reduced number of lymphocytes; follicles are absent. Inset: Lymph node; control pig No. 87. HE.

Figure 2. Spleen; pig No. 6. The white pulp is hypocellular due to a markedly reduced number of lymphocytes; periarterolar lymphoid sheaths and follicles are absent. Inset: spleen; control pig No. 87. HE.

Figure 3. Lymph node; pig No. 6. There is marked reduction in the number of CD3⁺ T cells. Inset: Lymph node; control pig No. 87. CD3 immunocytochemistry with hematoxylin counterstain.

Figure 4. Spleen; pig No. 6. CD3⁺ T cells are absent in the section. Inset: Spleen; control pig No. 87. CD3 immunocytochemistry with hematoxylin counterstain.

Figure 5. Lymph node; pig No. 6. There is marked reduction in number of CD79 α ⁺ B cells in the section. Inset: Lymph node; control Pig No. 87. CD79 α immunocytochemistry with hematoxylin counterstain.

Figure 6. Spleen; pig No. 6. CD79 α ⁺ B cells are absent in the section. Inset: Spleen; control pig No. 87. CD79 α immunocytochemistry with hematoxylin counterstain.

Table 1. ELISA and RT-PCR results at different days after infection with PRRSV

Pig ID	Day 4		Day 7		Day 11	
	ELISA* ^a	PCR* ^b	ELISA	PCR	ELISA	PCR
Pig 4	0.0	3.3	0.0	5.8	0.0	5.9
Pig 6	0.0	3.3	ND	3.8	0.0	6.7
Normal pigs* ^d	0.0	5.4	0.25	6.2	2.0	6.0
	(0)	(100)	(19)	(100)	(100)	(100)

^a ELISA results are reported as an S/P ratio. An S/P ratio greater than 0.39 is considered positive for PRRSV

^b PCR results expressed as log₁₀ quantity of viral RNA per reaction

^c ND, not done

^d PCR results for normal pigs represent the mean of 8 pen mates. ELISA results are the mean for 190 pigs. The number in parentheses is the percent pigs that were PCR positive or seropositive (S/P ratio > 0.39)