

HISTOLOGICAL CHANGES IN COWPER'S GLANDS AND THE SEMINAL  
VESICLES OF WETHER LAMBS TREATED WITH STILBESTROL  
AND ESTRADIOL-PROGESTERONE

by

ROBERT DAHLMEIER VATNE

B. A., Augustana College,  
Sioux Falls, South Dakota, 1956

---

A THESIS

submitted in partial fulfillment of the

requirements for the degree

MASTER OF SCIENCE

Department of Zoology

KANSAS STATE COLLEGE  
OF AGRICULTURE AND APPLIED SCIENCE

1958

## TABLE OF CONTENTS

INTRODUCTION .....	1
LITERATURE REVIEW .....	1
MATERIALS AND METHODS .....	6
EXPERIMENTAL RESULTS .....	11
Cowper's Gland	
Control Group .....	12
Oral Stilbestrol Group .....	13
Stilbestrol Implant Group .....	15
Estradiol-Progesterone Implant Group .....	16
Seminal Vesicle	
Control Group .....	17
Oral Stilbestrol Group .....	18
Stilbestrol Implant Group .....	20
Estradiol-Progesterone Group .....	20
DISCUSSION .....	21
SUMMARY .....	23
ACKNOWLEDGMENTS .....	25
REFERENCES .....	26
APPENDIX .....	29

## INTRODUCTION

Enlargement of the secondary sexual structures of wether lambs treated with estrogenic hormones has been frequently reported in recent years. This study was to determine the histological changes involved in the enlargement of Cowper's glands and the seminal vesicles. Also, the effects of diethylstilbestrol implants, estradiol-progesterone implants, and orally administered diethylstilbestrol were compared.

This work comprised a portion of a Kansas Agricultural Experiment Station project undertaken by the Zoology and Animal Husbandry Departments of Kansas State College. The sexual structures were collected and over-all size increases evaluated by the Department of Animal Husbandry.

Considerable experimentation has been conducted on the histological changes induced by estrogens on Cowper's glands and the seminal vesicles in castrate rats and mice. There are few references, however, relating to similar studies in wether lambs.

## LITERATURE REVIEW

Heller (1932) reported no significant change in Cowper's glands of castrate rats injected daily with 12 units of estrin for 20 days. The tubules were merged together much the same as in the untreated castrate animal.

Korenchevsky and Dennison (1935) found injected estrone caused the seminal vesicles of castrate rats to increase in size due to

fibrosis in certain areas of connective tissue. The connective tissue of the outer capsule of the gland showed no response but the same tissue between the epithelial and muscular layers of the lobules greatly increased. No changes were reported in epithelial cell size or in thickness of the muscular layer surrounding the individual lobules.

Entire ovaries were grafted in ears of castrate mice by Hill (1937). Seminal vesicle tissues were changed to a condition comparable to tissues of non-castrate animals. No hypertrophy in smooth muscle or connective tissue resulted. The author attributed the changes to production of an androgenic hormone by the ovaries.

Clausen (1942) reported androgenic effects on the seminal vesicles of castrate guinea pigs following the subcutaneous injection of one mg. of crystalline progesterone in oil. Twelve days after treatment the glands had regenerated from the castrate condition to a secretory state. A statistically significant increase in height of the epithelium was recorded.

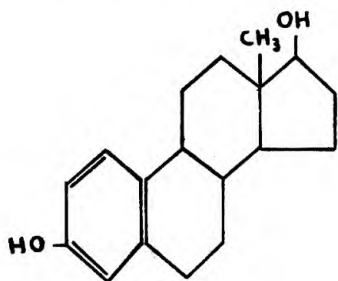
Lamar (1940), working with castrate rats, found no androgenic response of the seminal vesicles to progesterone. Animals were injected with one to four Rb.U. daily for 15 days. The seminal vesicle histology and cytology were unchanged from the castrate controls. Cowper's glands of the same animals, however, showed a definite response. Higher secretory cells, more numerous acini, and less interacinous connective tissue were marked changes.

Greene, et al. (1940) reported no significant weight changes

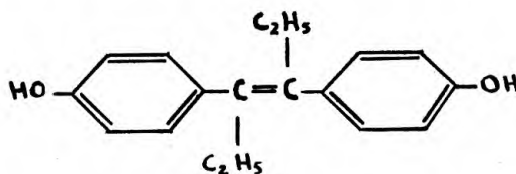
in seminal vesicles of castrate male rats following daily subcutaneous or intraperitoneal injections of two mg. crystalline progesterone in oil. Initial treatment immediately followed castration and continued for ten days.

Following the synthesis of stilbestrol (4,4 dihydroxy-A, B-diethyl stilbene) by Dodds, et al. (1938) a completely new phase of estrogenic therapy was opened. Shorr, et al. (1939) attributed the wide use of stilbestrol to its high estrogenic activity, its cheapness, and its oral efficacy.

Although diethylstilbestrol did not structurally resemble natural estrogens, its estrogenic potencies were soon shown.



Estradiol



Diethylstilbestrol

Dodds, et al. (1938) revealed that by injection it possessed two and one-half times the activity of estrone. Sondern and Sealy (1940) reported the synthetic compound to have a potency up to 80 times as much as estrone when given orally.

Early reports concerning the side reaction of stilbestrol varied greatly. Bishop, et al. (1939) reported occasional side reactions of nausea and vomiting while Varangot (1939) published that severe gastro-intestinal reactions resulted in nearly 45

per cent of treated patients. Krietman and Sieckmann (1939) reported paralysis and death occurred in rats within an hour after receiving one and one-half to five mg. per gram of body weight. Kleiner (1948), p. 556, however, states that side effects usually do not occur if the dosage is carefully regulated.

Morrill and Hart (1941) subjected castrate mice to both natural estrogen and stilbestrol treatments. Stilbestrol daily dosages varied from one to 250 gamma while 500 gamma of natural estrogens were given. Macroscopically both groups of treated animals showed hypertrophy of the seminal vesicle lobules. An increase in smooth muscle and connective tissue was evident. No correlation was found between this effect and the choice of estrogen, the size of dose, or the duration of treatment. The epithelial tissue was not stimulated, the cells remained small and cuboidal in form, non-secretory, and often sloughed into the lumen.

Bennetts, et al. (1946) reported abnormalities in the urogenital systems of sheep feeding on subterranean clover pastures in Australia. The clover, later proved to contain an estrogen, caused a breeding problem by incapacitating certain sexual structures. A more or less marked metaplasia of epithelial tissue occurred in the prostate, Cowper's glands, and terminal portions of the vasa deferentia and urethra.

Further investigations by Bennetts (1946) confirmed his original observations. Cowper's glands and the prostate gland were constantly affected. The seminal vesicles were reported entirely unaffected, however, except for the terminal parts of



the ducts. Epithelial changes in affected glands began with a loss of secretory activity as indicated by reduction in bulk of cytoplasm and chromophilia. Hyperplasia of the epithelial tissue was followed by metaplasia. These changes resulted in the conversion of the original single layer of columnar cells into a heavily stratified epithelium, which in some cases was observed highly keratinized.

Desquamation of the surface layers of metaplastic epithelium in certain animals tended to convert the acini into cysts filled with concentrically arranged sheets of shed epithelial cells. The foregoing condition was especially well marked in Cowper's glands.

Bennetts (1946) injected subcutaneously two wethers with stilbestrol. The animals received 100 mg. of the hormone in peanut oil three times weekly for a period of four weeks. The wethers were sacrificed five days after the last injection. Although no keratinization of metaplastic tissues was observed, marked metaplasia of epithelial tissue was noted. The epithelial tissue of the seminal vesicles was found unaffected.

A similar experiment by Bennetts (1947) involved intramuscular administration of stilbestrol. A dosage of 50 mg. three times weekly was given over a period of three months. Changes similar to those following the subcutaneous injections resulted.

Henneman, et al. (1957) observed hyperplasia, cystic dilation, and keratinization of the epithelium in the secondary sexual structures of wethers 42 days after implantation of estradiol-progesterone pellets. The implants, placed subcutaneously

in the submaxillary region, consisted of a combination of 100 mg. progesterone and ten mg. estradiol or 250 mg. progesterone and ten mg. estradiol.

#### MATERIALS AND METHODS

The experimental animals were predominantly fine wool wethers purchased near Casper, Wyoming. After being shipped to the Garden City Branch of the Kansas Agricultural Experiment Station, the animals were randomly allotted into four experimental groups on October 22, 1955. Animals of group I each received a subcutaneous implant of six mg. diethylstilbestrol under the lower jaw. Animals of group II each received a pellet containing ten mg. estradiol and 200 mg. progesterone (Synovex) administered in a similar manner as the first group. Each animal of group III received two mg. of diethylstilbestrol per day mixed in the ration. A fourth group acted as the control.

All groups were fed a similar standard ration until March 7, 1956. At that time ten animals from each group, selected on the basis of average final weights, were shipped to the meats laboratory at Kansas State College where they were slaughtered. Only 18 of the Cowper's glands recovered were prepared for histological examination. Glands were examined from three animals of the control group and five animals from each of the other groups.

One seminal vesicle from each of thirty animals was recovered for study. Glands in this group were from the following animals; six receiving oral stilbestrol; eight receiving implants



of estradiol-progesterone; seven receiving implants of stilbestrol; and nine controls.

Tissues were placed in Bouin's fixative, infiltrated by the dioxan method, embedded in paraffin, and sectioned at a thickness of eight microns. Serial sections were made of a representative area of each gland. A modification of Mallory's triple stain was employed in staining the sections.

In addition to general microscopic observations of the sectioned glands, measurements of specific tissues and cells were recorded. All measurements were taken using high power magnification. An ocular micrometer was employed as the measuring device.

Twenty representative areas of each Cowper's gland were examined in detail. Each area, 2.89 sq. mm., constituted the region within an ocular net micrometer. The areas observed followed a definite pattern. Initial observations of each slide were taken from the section in the upper left hand corner. A field of view at the extreme right edge of the section and two-thirds of the distance from the bottom was the first area checked. Using a mechanical stage, the slide was then moved to the right so that the width of the microscopic field on high power separated the original area studied from the second area. Recording data from the net micrometer area of every other microscopic field continued until the complete width of the tissue had been covered. Identical procedure was followed across the slide again, this time beginning one-third of the distance from the bottom.

The serial section to the right was next examined. Instead,

however, of a similar pattern of checked areas, the areas originated at the top of the section one-third and two-thirds of the way across the section from the right edge. The areas checked were alternate fields of view in vertical columns. Single lines of alternating fields across the next successive sections were checked. Observations began from the center on the right side and from the top center in these sections. If twenty areas had not been examined due to the small size of certain sections the pattern was repeated until the appropriate number had been observed.

The number of alveoli and conducting tubules were counted in each field within the net micrometer. Only alveoli and tubules with more than one-half of their areas in the field were included in the count.

The lumen width and epithelial lining thickness of all conducting tubules were recorded. Measurement of the lumen was taken at the narrowest point in order to compensate for sections cut at an angle less than 90 degrees to the axis of the tubule. Since the thickness of the conducting tubule lining varied, the thinnest portion was recorded in each case.

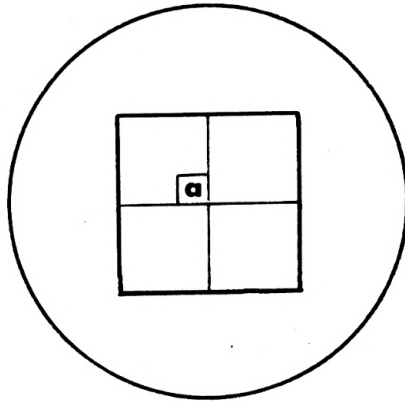
Interstitial material separating the alveolus nearest the net center point from other epithelial tissue was noted. Measurements were taken from the periphery of the tubule at intervals of 90 degrees with imaginary lines leading from the epithelial tissue being as nearly vertical and horizontal as possible. The interstitial material surrounding the conducting tubule nearest the

## EXPLANATION OF PLATE I

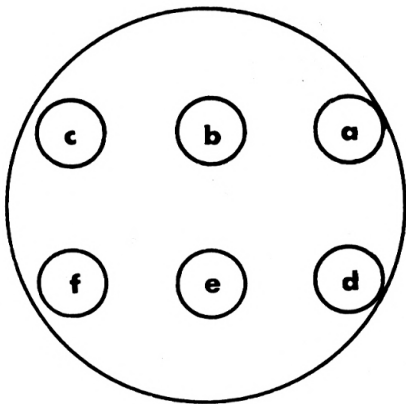
Figure 1 represents a single field of view of the microscope. The large square represents the net micrometer. The small square designated by figure a represents the portion of the net micrometer in which the number and size of individual secreting epithelial cells were tabulated in the study of Cowper's gland.

Figures 2, 3, 4, and 5 represent serial sections of Cowper's gland. The circular numbered areas represent fields of view of the microscope. The alphabetized sequence of fields follows the sampling pattern employed in checking 20 areas of the gland.

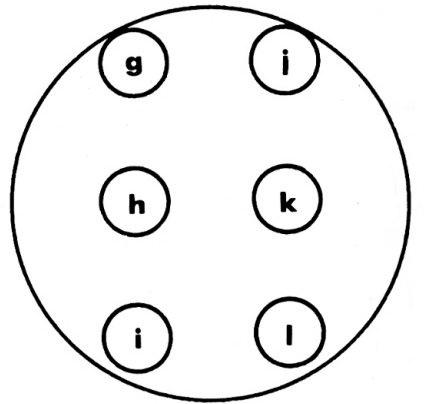
PLATE I



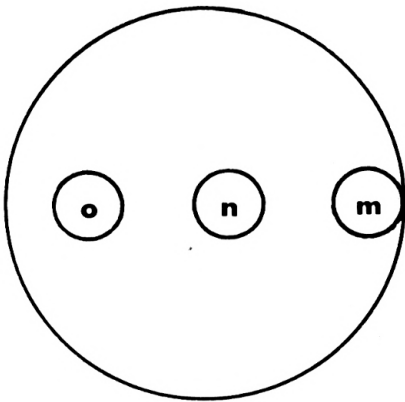
1



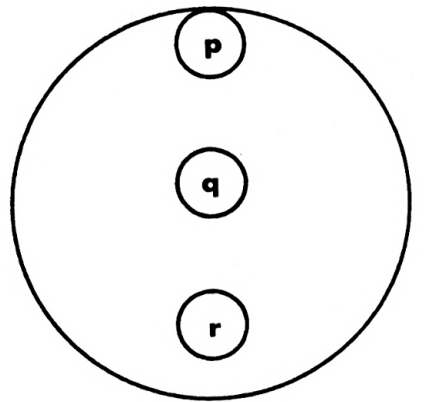
2



3



4



5

center of the net micrometer was similarly measured.

The height, width, and number of the secreting cells found within a particular region of the net micrometer were recorded from the first ten areas checked. This region occupied an area one-twenty fifth of the entire net micrometer or .116 sq. mm.

The largest seminal vesicle section from the slides of each animal was microscopically examined. The diameter of each lobule at its narrowest point was recorded. The width of the muscular covering of each lobule also was measured at its most narrow region. Data concerning incomplete lobules encountered occasionally at the periphery of the section were not recorded.

The distance from the muscular coat to the secreting epithelial cells nearest to that covering was measured in each lobule as a criterion for increased interstitial material in the treated animals.

Height and width of individual secreting epithelial cells were measured with the areas checked following much the same pattern as used in the analysis of Cowper's gland. A region parallel to the length of the slide across the central portion of the section was swept. The ten simple columnar cells nearest the center point of the net micrometer of every other field were measured. Five different areas were counted from each slide. In an effort to obtain more accurate readings, the width of several cells was taken as a single measurement whenever possible.

#### EXPERIMENTAL RESULTS

Cowper's glands are a pair of pea-sized structures, one



gland situated on each side of the urethra near the ischial arch. Each gland empties into the urethra through a single duct. The glands are surrounded by a fibrous and muscular covering.

#### Control Group

The glands of the castrate controls showed a branched tubulo-alveolar design. Dendriiform tubules coursed throughout the gland with numerous outpocketings or secreting acini located on all tubules except the ducts opening into the urethra.

Although the acini usually ended blindly, occasionally they appeared connected with one another by anastomoses. Each acinus was surrounded by a thin stroma. Groups of acini were often separated from other groups by a much thicker stroma.

Despite castration of the animals four and one-half months prior to the removal of the glands, the secreting epithelium was definitely columnar in shape. There was a gradual decrease in cell height from the epithelial cells of the alveoli to the conducting tubules. The smaller tubules tended to be comprised of cuboidal epithelial cells found in a simple arrangement. Arrangement of a single layer of cells, a double layer of cells and transitional epithelium were found lining large tubules. In some instances one wall of a tubule was comprised of a single epithelial layer and the tubule wall directly opposite this area showed a stratified condition. No correlation was observed between the size of the conducting tubules and the occurrence or degree of stratification.

### Oral Stilbestrol Group

By the analysis of variance method animals receiving stilbestrol orally showed the following significant differences from the castrate condition (Table 1): increase in intercellular stroma, decrease in the number of secreting alveoli and decrease in the number of secreting cells found within sampled areas.

The increased intercellular material manifested itself by crowding alveoli together so that in many instances the typically spherical alveoli were distorted.

Although the lumen diameter of the conducting tubules in this group was actually less than that of the controls, no significant difference between this and any other group was shown (Table 1).

The height and width of individual secreting epithelial cells and the thickness of the conducting tubule wall were not significantly different from those in other groups (Table 1). The thickness of the tubule wall, however, showed an inconsistency in its cellular arrangement. Sections running lengthwise through large tubules disclosed changes from areas of stratification to single layers of cells and then back to regions of stratification as the tubule was followed.

One slide from this group showed a sloughing of the lining cells of the tubule into the lumen.

As in the control group, no correlation between the size of the tubule and the occurrence or degree of stratification was noticeable.

Table 1. Measurements of cells and tissues of Cowper's gland.

	:No. of Alveoli :Within Net Mi- :crometer Area :(5% Level)	:No. of Secreting :Epithelial Cells :Within Area :34.16 Microns :(1% Level)	:Thickness of :Interstitial :Material Sur- :rounding Con- :ducting Tubules :(Not Significant)	:Thickness of :Interstitial :Material :Surrounding :Alveolus :(1% Level)	:Thickness of :Conducting :Tubule Wall :(Not :Significant)	:Lumen :Diameter :(Not :Significant)	:Height of :Secreting :Epithelial :Cells :(Not :Significant)	:Width of :Secreting :Epithelial :Cells :(Not :Significant)
Control Group	9.47*	8.23*	9.63	7.60*	7.5	17.86	4.32	2.07
Oral Stilbestrol Group	4.53*	5.48	26.73	18.37	7.43	13.75	4.35	2.12
Implant Stilbestrol Group	1.60	3.79	32.28	21.80	11.37	25.13	4.15	2.00
Estradiol-progesterone Group	2.41	5.14	26.73	21.00	11.29	27.13	4.96	2.48

\*Statistically significant.

Numbers represent ocular units (one ocular unit equals 2.44 microns).

### Stilbestrol Implant Group

The glands of this group contained fewer secretory alveoli than any other group. A significant difference was found between this and the group treated by oral administration as well as between this and the control group (Table 1). A significant difference existed, however, only between this and the control group, in the number of epithelial cells in the sampled areas.

Despite moderate variations shown by individual animals, hypertrophy and metaplasia of epithelial tissue were more prominent in this group than in the control group or that given stilbestrol orally (Table 1). Although lumen widths and thicknesses of the conducting tubules were not remarkable when compared with those of the other groups, the percentage of tubules affected appeared greater than in the control group. The tubule linings were composed primarily of transitional epithelium.

No significant variation was noted in the size of the secretory cells from similar cells in other groups (Table 1).

Table 1 shows a significant increase over the control group of interstitial material surrounding the alveoli. The increased interstitial material coupled with the hypertrophy of the conducting tubules caused the alveoli and tubules to be crowded in a fashion similar to that in glands of animals treated orally with stilbestrol.

Three of the five animals of this group showed the presence of sloughed epithelial cells in the lumen of the conducting tubules.

### Estradiol-Progesterone Implant Group

This group showed a general response quite similar to that of the group given implants of stilbestrol. Considerable variation was found within the group.

A significant difference in the number of secreting alveoli existed between this group and the control and orally administered groups (Table 1). Also, a significant difference exists between this group and the controls both in the amount of interstitial material surrounding the secreting acini and the number of secreting cells in the sample areas (Table 1).

The height and width of the secreting cells exceeded those of the other groups but it was not statistically significant (Table 1).

Hypertrophy and metaplasia of lining of the conducting tubules were prominent. Despite considerably greater thickness of the tubule and greater lumen diameter, no significant difference exists between this group and any other group (Table 1).

One gland of this group showed excessive hypertrophy and some metaplasia of the epithelium. The hypertrophy appeared to have progressed to such a degree that only epithelial tissue separated the lumina. Finally the epithelial tissue appeared to have broken down allowing the tubules to fuse.

Sloughed epithelial cells in the lumen of conducting tubules were found in tissues from three different animals.

The seminal vesicles are a pair of elongated glandular struc-



tures each having a lobulated appearance. Each vesicle has an approximate diameter of eight millimeters and a length of twice the diameter. One vesicle lies on each side of the dorsal surface of the bladder near the origin of the urethra. The main excretory duct from each vesicle enters into the sides of the colliculus seminalis.

### Control Group

The glands of castrates appeared to consist of lobules separated by muscular septa. Each lobule consisted of a central lumen continuous with extensive branching passages. The epithelial cells lining the branched passageways were found directly in contact with connective tissue as no basement membrane was present. The major passageway of each lobule opened into the main excretory duct located in the caudal portion of the gland.

The arrangement of epithelial tissue showed much variation. Most glands possessed primarily pseudostratified epithelial tissue although single and double rows of columnar epithelium were also noted. No keratinization of the epithelial tissue was observed.

Sections cut parallel to the axis of the central lumen of a lobule failed to show any change in epithelial cell arrangement of the tubule wall regardless of the distance from the main conducting tubule.

The epithelial-lined passageways were evenly distributed throughout the lobule. A relatively thin layer of smooth muscle

surrounded each lobule. The majority of lobules were subdivided so that bud-like smaller lobules had branched from the original lobule.

#### Oral Stilbestrol Group

An overall increase in connective and muscular tissue and a mild metaplasia distinguished this group from the control group.

An analysis of variance test (Table 2) shows a near significant increase over the control group in the amount of interstitial material between the most peripheral epithelial cells of the lobule and the muscular covering. This region seemed to show the greatest increase in interstitial material, the overall addition of this tissue caused considerable bunching of the branching tubules. In many instances the tubules were crowded to such a degree that epithelial linings of adjacent tubules were in contact.

Epithelial cells found lining the branching tubules were arranged in a single uniform layer, a double layer or pseudo-stratified.

Three of the six vesicles from this group of animals showed metaplasia in the central lumen of some lobules. Lobule diameter in this group was significantly larger than that of the control group or that of the estradiol-progesterone treated animals (Table 2).

No significant variation in height or width of the columnar epithelial lining was noted in comparison with the other groups (Table 2).

Table 2. Measurement of cells and tissue of seminal vesicles.

	: Distance From : : Most Peripheral: : Epithelial Tis- : sue to Muscular: : Coat of Lobule : : (0.1% Level)	: Thickness of : : Muscular Cov- : : ering Surround- : : ing Lobule : : (0.1% Level)	: Diameter : : of Lobules : : (0.1% Level)	: Height of : : Secreting : : Epithelial : : Cells : : (Not : : Significant)	: Width of : : Secreting : : Epithelial : : Cells : : (Not : : Significant)
Control Group	12.11*	17.10*	57.04*	7.05	2.60
Oral Stilbestrol Group	21.63	37.87	101.45	7.01	2.41
Implant Stilbestrol Group	34.20	37.05	82.38	* 7.09	2.56
Estradiol-progesterone Group	31.70	32.07	69.64	7.45	2.58

\*Statistically significant.

Numbers represent ocular units (one ocular unit equals 2.44 microns).

### Stilbestrol Implant Group

Vesicles of this group were also marked by interstitial and muscular tissue increases. Significant differences between these animals and the controls were noted for both the amount of intestinal tissue between the most peripheral epithelium of a lobule and the muscular coat, and the width of the muscular coat (Table 2).

The increase in interstitial tissue appeared to cause greater crowding of the branching tubules than that in the group given stilbestrol orally or that found in the control group.

The various types of arrangement of epithelia in the branching tubules were again encountered. A metaplastic condition of epithelium was evident about the central lumen of lobules in two animals of this group.

Lobule diameter showed a significant increase over that of the controls but epithelium height and width was not significantly changed (Table 2).

### Estradiol-Progesterone Group

With the exception of smaller lobule size and lack of metaplasia in the epithelial lining of the central lobule, the vesicles of this group closely resembled the groups which received stilbestrol orally and by implant.

A statistically significant difference exists between animals of the control group and this group in respect to increase of

interstitial substance between the most peripheral epithelium of the lobules and the muscular coat and in the width of the lobule muscular covering (Table 2).

Only the lobules of the group treated orally with stilbestrol are significantly larger than this group (Table 2).

Epithelial cells lining the branching and central passages of lobules were not significantly different from other groups although the average height of the cells in animals of this group was higher than those found in other treated groups (Table 2).

Epithelial cells found lining the tubules were arranged in a single uniform layer, a double layer, or in a pseudostratified condition.

#### DISCUSSION

Results of this experiment are basically in agreement with those obtained by Bennetts (1946), Bennetts et al. (1947), and Henneman et al. (1957).

Bennetts et al. (1946), however, reported the occurrence of metaplasia only at the terminal portions of the seminal vesicle ducts in wethers. These lambs had fed on clover which contained an estrogen. Bennetts' experimentation involving intramuscular injection of wethers with stilbestrol produced no epithelial change in the seminal vesicles. Frequently, in this study, metaplasia had occurred in the lining of central ducts in several lobules.

Burrows (1935), working with castrate mice treated with



estrone, reported that metaplasia spreads from the urethral end of Cowper's gland. Bennetts (1947) agreed with this observation. In this work, sections cut parallel to the axis of the central lumina of lobules revealed that metaplasia was not continuous.

The secreting epithelial cells of animals treated with estradiol-progesterone implants were larger in both Cowper's gland and the seminal vesicle. The enlargement may be attributed to the androgenic effect of the progesterone portion of the implant. This effect of progesterone would tend to agree with results obtained by Clausen (1942) and Lamar (1940). Clausen reported subcutaneous injections of crystalline progesterone in oil maintained secretion of the epithelial cells in auxilliary sex structures of castrate male guinea pigs. Lamar observed an androgenic response to progesterone in castrate male rats. The secretory cells of Cowper's gland were found intermediate in height between normal and castrate conditions.

The explanation for a decrease in the number of secreting alveoli in Cowper's gland probably involves two factors. First, the increased interacinar material would decrease the acini per unit area. Second, metaplasia occurring within the acini would make their appearance unrecognizable. Metaplasia progressed to a lesser degree in the animals treated orally with stilbestrol. Consequently, the number of acini recorded was greater than the animals receiving implants.

Variable effects within similarly treated groups of animals can probably be attributed to differences in the rate of absorp-

tion of the pellets and the amount of food consumed containing stilbestrol. Although a portion of the implanted substance from all animals was recovered at the time of slaughter, there was a slight variation in the size of the implanted mass recovered. Since animals receiving stilbestrol orally were fed as a group, the dosage obtained in this manner could fluctuate to an even greater degree.

A definite correlation exists between the overall size of both Cowper's glands and the seminal vesicles from these animals as reported by Bell et al. (1956). Bell reported that both glands of treated groups were considerably larger in overall size. In this study a similar relationship was found in fibrosis of the glands and vesicles.

#### SUMMARY

Cowper's glands and the seminal vesicles were studied from wether lambs which had been treated with estrogenic hormones. Results from three treated groups and a control group were evaluated.

Animals of group I each received a subcutaneous implant of six mg. diethylstilbestrol. Animals of group II received an implant of 3.5 mg. estradiol and 200 mg. of progesterone. Each animal of group III received two mg. of diethylstilbestrol per day in the feed.

After four and one-half months of treatment, the animals were slaughtered. The desired tissues were recovered, sectioned,

stained, and examined.

The following results were observed:

1. Cowper's gland and the seminal vesicles of the three treated groups showed hypertrophy. The enlargement was primarily due to increased connective and muscular tissue.

2. Metaplasia of epithelial tissue was observed in Cowper's glands of all treated animals. Animals administered stilbestrol orally, however, showed less extensive changes than the other treated groups. The number of secreting alveoli seemed inversely proportional to the degree of metaplasia.

3. Although the majority of the epithelial tissue in the seminal vesicles of treated animals was unaltered, occasional metaplasia of a portion of major tubule linings was observed in both groups receiving implants.

4. Variation in cell size of secretory epithelium unaffected by metaplasia was not statistically significant. In both glands, however, a slight height increase was found in the animals receiving estradiol-progesterone pellets. This change was possibly caused by the androgenic effect of progesterone.

5. Sloughed epithelial cells in the lumen of conducting tubules from Cowper's glands were found in approximately one-half of the animals treated with either of the implants.

### ACKNOWLEDGMENTS

To Dr. E. H. Herrick for suggesting this problem and for his advice during this study; to Prof. C. H. Lockhart for his advice, criticism, and encouragement; and to Prof. W. H. Smith for supplying pertinent information, sincere thanks are given.

Appreciation is expressed to the Chemical Specialties Company of New York, N. Y., which furnished the estradiol-progesterone (Synovex) pellets; to the Norden Laboratories of Lincoln, Nebr., for the stilbestrol pellets; and to the Eli Lilly Company of Indianapolis, Ind., for the stilbestrol premix used in the oral administration.

## REFERENCES

- Albrieux, A., W. Bruno, P. Engel and A. Morato.  
Effect of progesterone on seminal vesicle. *Klin Wehnschr.*  
15:206. 1936.
- Bell, T. D., W. Smith and A. B. Erhart.  
The effect of stilbestrol upon lamb performance in the feed-  
lot. *Jour. An. Sci.* 13:425-432. 1954.
- Bell, T. D., W. H. Smith, A. B. Erhart, and D. L. Mackintosh.  
Lamb feeding experiments. Supplement report concerning the  
use of hormones. Kansas Agricultural Experiment Station  
Bulletin 335. May 5, 1956.
- Bennetts, H. W.  
Metaplasia in the sex organs of castrated male sheep maintained  
on early subterranean clover pastures in Western Australia.  
*Australian Vet. Jour.* 22:70. 1946.
- Bennetts, H. W., E. J. Underwood, and F. L. Shier.  
A specific breeding problem of sheep on subterranean clover  
pastures in Western Australia. *Australian Vet. Jour.* 22:2.  
1946.
- Bennetts, H. W.  
A further note of metaplasia in the sex organs of castrated  
male sheep on subterranean clover pastures in Western Australia.  
*Australian Vet. Jour.* 23:10. 1947.
- Bishop, P. M., M. Boycott and S. Zuckerman.  
Estrogenic properties of "stilbestrol": clinical and experi-  
mental investigation. *Lancet.* 1:5. 1939.
- Burrows, H.  
Leucocytic invasion as an accompaniment of epithelial meta-  
plasia. *Jour. Path. and Bact.* 41:43-49. 1935.
- Burrows, H.  
Response to oestrogen compounds. *Jour. Path. and Bact.* 41:  
423-429. 1935.
- Burrows, Harold.  
Changes induced by oestrone in the bulbo-urethral (Cowper's)  
gland of the male mouse. *Jour. of Path. and Bact.* 44:481-483.  
1937.
- Clausen, H. J.  
Effect of progesterone and desoxycorticosterone on accessory  
sex organs of the castrate male guinea pig. *Endocrinol.* 31:  
187-191. 1942.



- Cowdry, E. V.  
Special Cytology. Vol. III. New York: Paul B. Hoeber, Inc.
- Dodds, E. C., L. Goldberg, W. Lawson and R. Robinson.  
Estrogenic activity of certain synthetic compounds. *Nature*.  
141:247. 1938.
- Emmens, C. W.  
Rate of absorption of androgens and estrogens in free and  
esterified form from subcutaneously implanted tablets.  
*Endocrinol.* 28:633-642. 1941.
- Forbes, T. R.  
Absorption of pellets of crystalline testosterone, progesterone,  
desoxycorticosterone and stilbestrol. *Endocrinol.*  
29:70-77. 1941.
- Gaarenstrom, J. H. and S. E. de Jongh.  
The effect of diethylstilbestrol in the male organism. *Acta  
brev. Neerland.* 9:178-181. 1939.
- Greene, R. R., M. W. Burrill and D. M. Thomson.  
Further studies on the adrogenicity of progesterone. *Endo-  
crinol.* 27:469. 1940.
- Heller, R. E.  
Cowper's gland and its reaction to castration and to differ-  
ent sex-hormone conditions. *Amer. Jour. Anat.* 50:73. 1932.
- Henneman, H. A., R. E. Ruse, and J. Meites.  
The effect of steroid hormones on fattening lambs. *Jour. An.  
Sci.* 12:283. 1957.
- Hill, R. T.  
Ovaries secrete male hormone. *Endocrinol.* 21:495-502. 1937.
- Jordan, R. M.  
The effect of various levels of stilbestrol and nor-testos-  
terone implants on lambs. *Jour. An. Sci.* 16:840-844. 1957.
- Kleiner, Israel S.  
Human Biochemistry. St. Louis: The C. V. Mosby Co. 1948.
- Korenchevsky, V.  
Estradiol dipropionate. *Jour. Path. and Bact.* 52:268. 1940.
- Korenchevsky, V. and M. Dennison.  
Histological changes in organs of rats injected with oestrone  
alone or simultaneously with oestrone and testicular hormone.  
*Jour. Path. and Bact.* 41:323. 1935.

- Krietmair, H. and W. Suckmann.  
 Uber 4,4' dioxy-alpha-beta diathylstilben, eine synthetische  
 verbindung mit der wirkung des follikelhormons. Klin.  
 Wchnschr. 18:156. 1939.
- Lamar, J. K.  
 Some effects of corpus luteum extracts and of synothelic  
 progesterone on young male albino rats. Physiol. Zool.  
 13:251. 1940.
- Maximau, Alexander A. and William Bloom.  
 Textbook of Histology. Philadelphia: W. B. Saunders Co.  
 1953.
- May, Neil D. S.  
 The Anatomy of the Sheep. Brisbane: The University of  
 Queensland Press. 1955.
- Morrell, J. A. and G. W. Hart.  
 Studies on stilbestrol III. Some effects of continuous  
 injections of stilbestrol in normal and castrate adult  
 rats. Endocrinol. 29:995-1002. 1941.
- O'Mary C. C., A. L. Pope, G. D. Wilson, R. W. Bray and L. E.  
 Casida. The effects of diethylstilbestrol, testosterone and  
 progesterone on growth and fattening and certain carcass  
 characteristics of western lambs. Jour. An. Sci. 11:656-  
 676. 1952.
- Parkes, A. S. and Zuckerman.  
 Experimental hyperplasia of the prostate. Lancet. 1:925.  
 1935.
- Shorr, E., F. H. Robinson and G.N. Papanicolaou.  
 A clinical study of the synthetic estrogen stilbestrol.  
 Jour. Amer. Med. Assoc. 113:2312-2318. 1939.
- Sondern, C. W. and J. Leon Sealey.  
 The comparative estrogenic potency of diethylstilbestrol,  
 estrone, estradiol and estriol. Endocrinol. 27:670-672.  
 1940.
- Varangot, J.  
 Clinical use of stilbestrol. Lancet. 1:296. 1939.
- Zuckerman, S. and S. R. Groom.  
 The etiology of benign enlargement of the prostate in the  
 dog. Jour. Path. and Bact. 44:113. 1937.

APPENDIX

#### EXPLANATION OF PLATE II

- Fig. 1. Photomicrograph of Cowper's gland taken from wether lamb. X 325.
- Fig. 2. Photomicrograph of Cowper's gland taken from wether lamb which received 2 mg. diethylstilbestrol daily in the ration for four and one-half months. Note increased interstitial material between alveoli in comparison with the control. X 90.

PLATE II

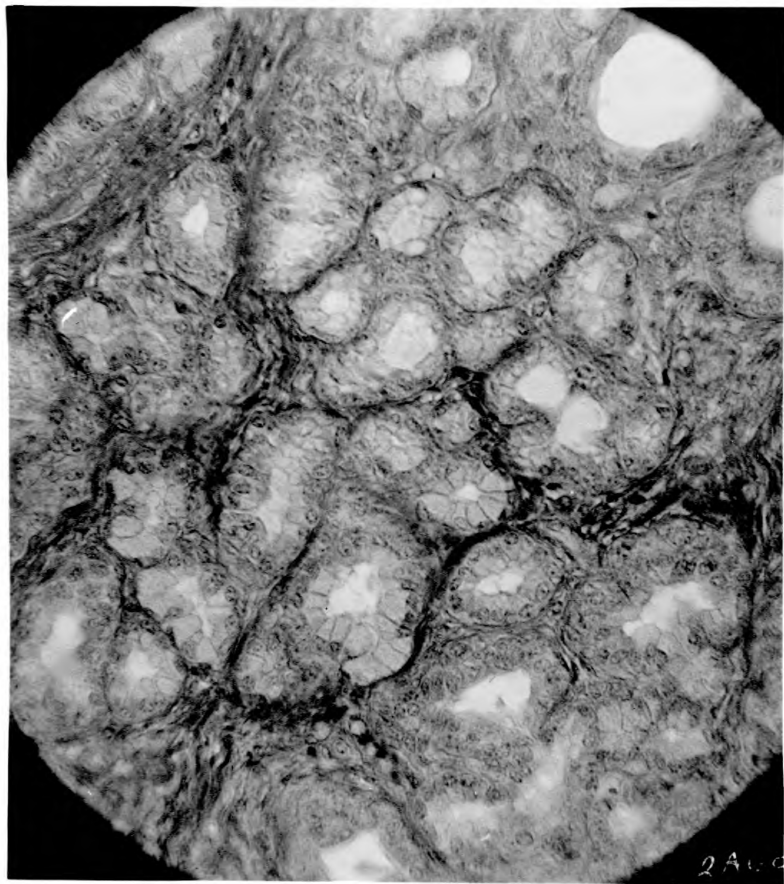


Fig. 1

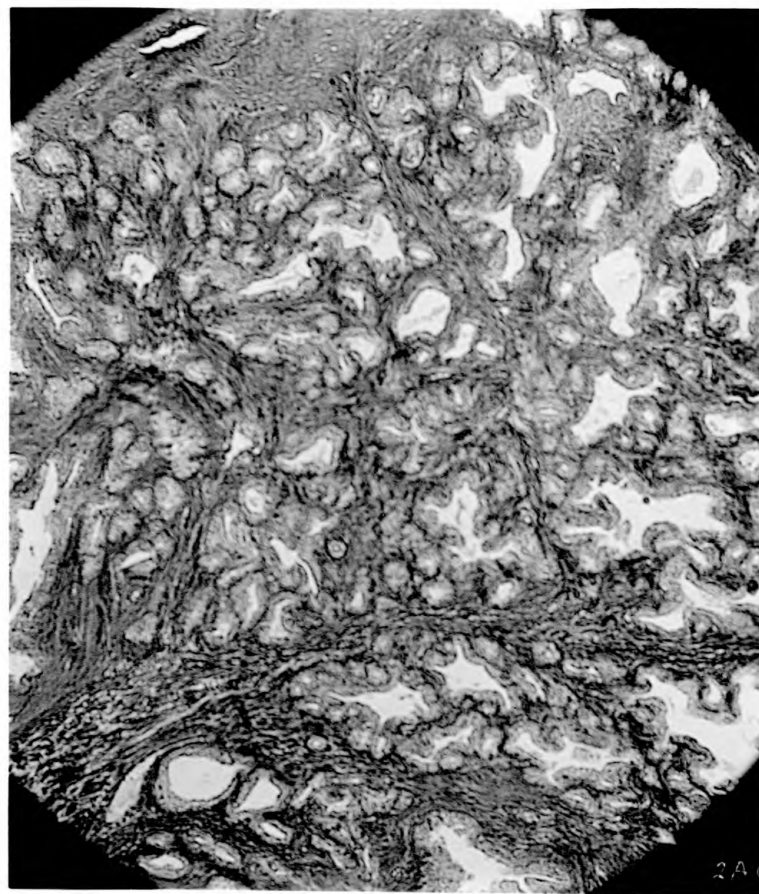


Fig. 2

### EXPLANATION OF PLATE III

- Fig. 1. Photomicrograph of Cowper's gland taken from wether lamb four and one-half months after receiving an implant of estradiol-progesterone. Note encroachment of metaplasia near acinus. X 325.
- Fig. 2. Photomicrograph of Cowper's gland from the same animal as mentioned in figure 1. Note extensive metaplastic condition and lumen containing sloughed epithelial cells. X 90.



PLATE III

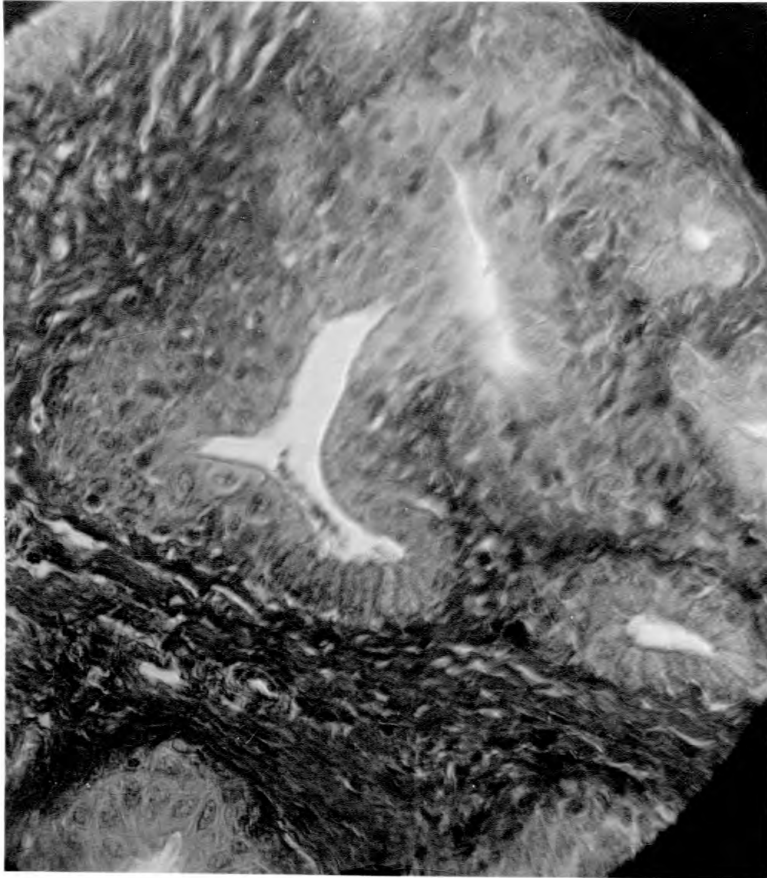


Fig. 1

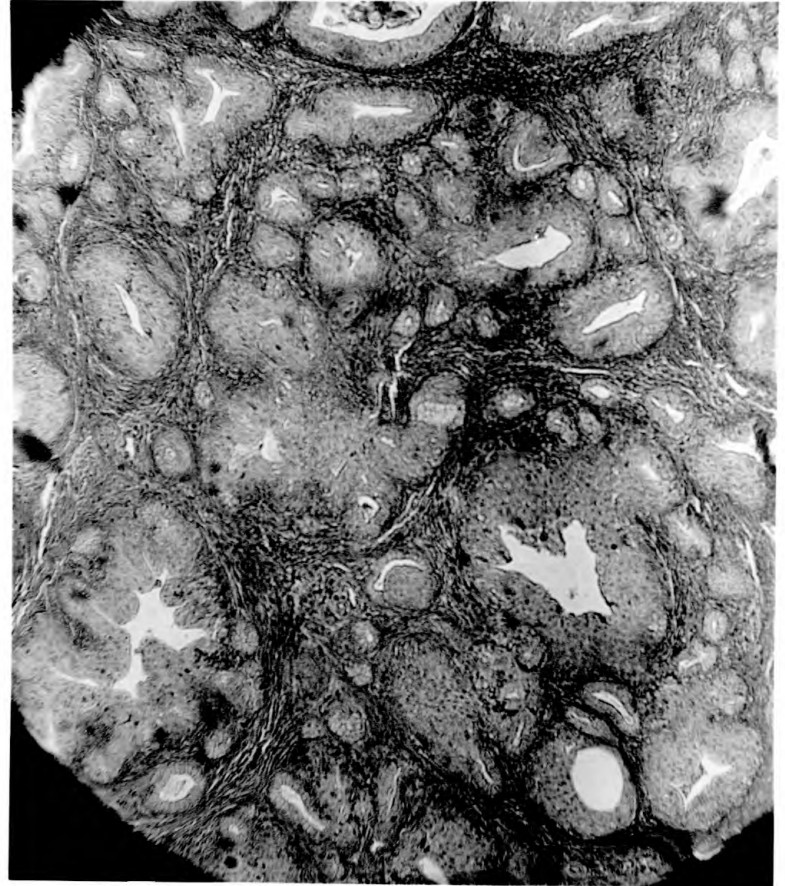


Fig. 2

#### EXPLANATION OF PLATE IV

- Fig. 1. Photomicrograph of seminal vesicle lobule from wether lamb. X 90.
- Fig. 2. Photomicrograph of seminal vesicle lobules from wether lamb which received 2 mg. diethylstilbestrol daily in the ration for four and one-half months. Note bunching of small tubules due to fibrosis of connective tissue. X 90.

PLATE IV

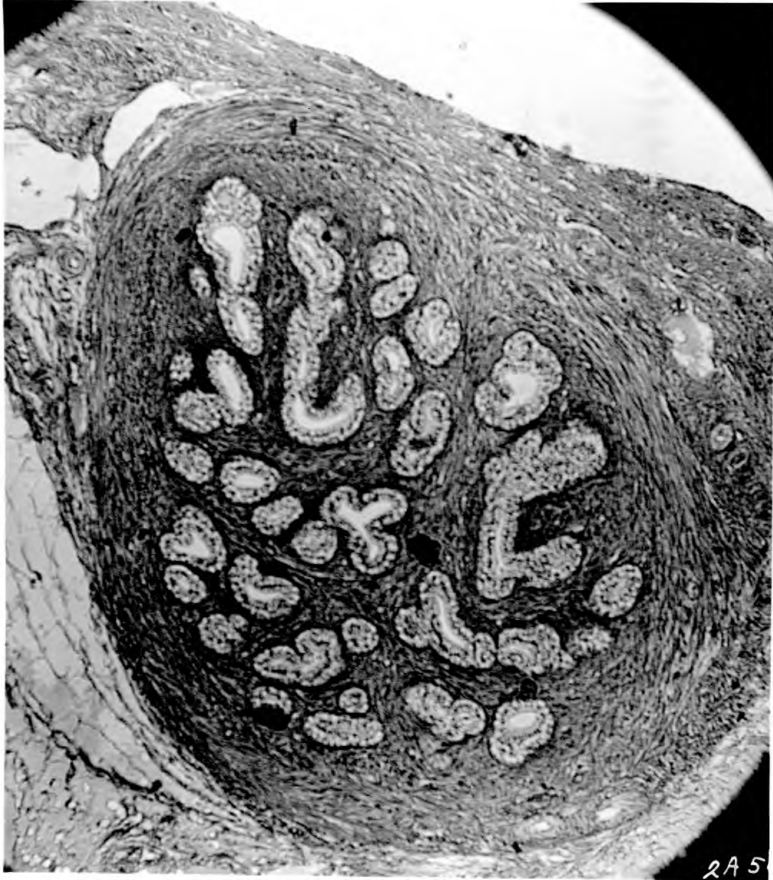

Fig. 1

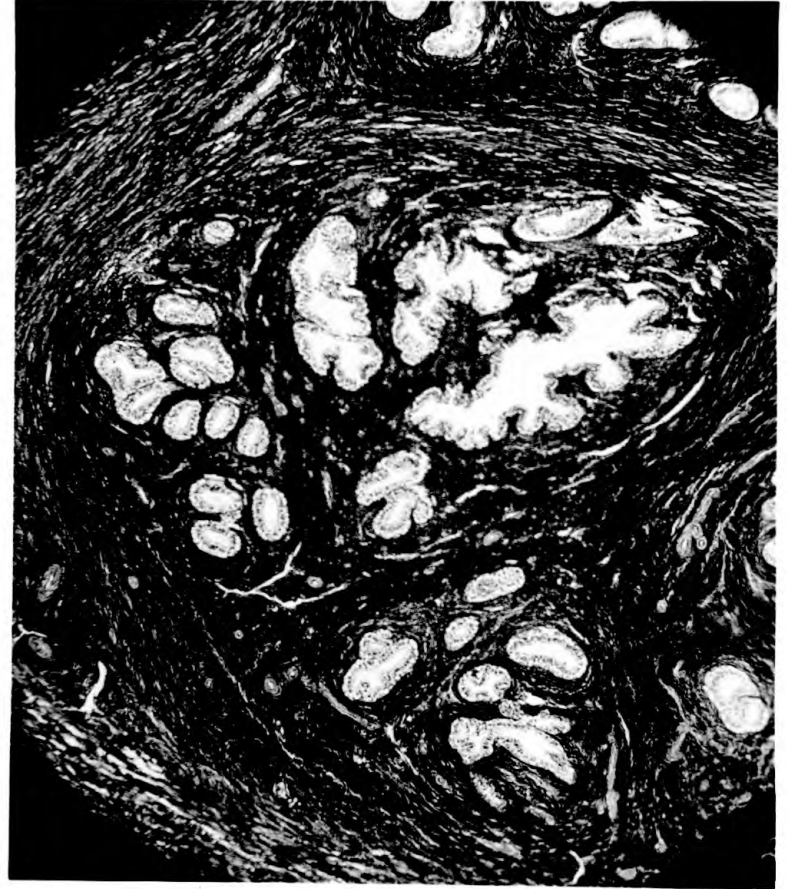


Fig. 2

HISTOLOGICAL CHANGES IN COWPER'S GLANDS AND THE SEMINAL  
VESICLES OF WETHER LAMBS TREATED WITH STILBESTROL  
AND ESTRADIOL-PROGESTERONE

by

ROBERT DAHLMEIER VATNE

B. A., Augustana College,  
Sioux Falls, South Dakota, 1956

---

AN ABSTRACT OF A THESIS

submitted in partial fulfillment of the

requirements for the degree

MASTER OF SCIENCE

Department of Zoology

KANSAS STATE COLLEGE  
OF AGRICULTURE AND APPLIED SCIENCE

1958

This study was undertaken to determine the histological changes involved in the enlargement of Cowper's glands and the seminal vesicles of wether lambs treated with estrogenic hormones. Also, the effects of these various hormones were compared.

This work comprised a portion of a Kansas Agricultural Experiment Station project undertaken jointly by the Zoology and Animal Husbandry Departments of Kansas State College. The sexual structures were collected and over-all size increases evaluated by the Department of Animal Husbandry.

Four groups of experimental animals were randomly allotted. Animals of group I each received a subcutaneous implant of six mg. diethylstilbestrol. Animals of group II received an implant of three and one-half mg. estradiol and 200 mg. of progesterone. Each animal of group III received two mg. of diethylstilbestrol per day in their ration.

After four and one-half months of treatment, the animals were slaughtered. The desired tissues were recovered and slides consisting of serial sections of representative areas of each gland were made.

In addition to general microscopic observations of the sectioned glands, measurement of specific tissues and cells were recorded. An ocular micrometer was employed as the measuring device.

The following results were observed:

1. Cowper's glands and the seminal vesicles of the three treated groups showed hypertrophy. The enlargement was primarily due to increased connective and muscular tissue.

2. Metaplasia of epithelial tissue was observed in Cowper's glands of all treated animals. Animals administered stilbestrol orally, however, showed less extensive changes than the other treated groups. The number of secreting alveoli seemed inversely proportional to the degree of metaplasia.

3. Although the majority of the epithelial tissue in the seminal vesicles of treated animals was unaltered, occasional metaplasia of a portion of major tubule linings was observed in both groups receiving implants.

4. Variation in cell size of secretory epithelium unaffected by metaplasia was not statistically significant. In both glands, however, a slight height increase was found in the animals receiving estradiol-progesterone pellets. This change was possibly caused by the androgenic effect of progesterone.

5. Sloughed epithelial cells in the lumen of conducting tubules from Cowper's glands were found in approximately one-half of the animals treated with either of the implants.