

301

IMMUNOFLUORESCENT DIAGNOSIS OF OVINE EPIDIDYMITIS

by

CHRISTOPHER OLUSEGUN AJAI

D.V.M., University of Ibadan, Nigeria, 1974

---

A THESIS

submitted in partial fulfillment of the

requirements for the degree


MASTER OF SCIENCE

Department of Pathology

KANSAS STATE UNIVERSITY  
Manhattan, Kansas

1980

APPROVED BY:

  
Major Professor

Spec. Coll.  
LD  
2668  
T4  
1980  
A38  
C.2

## ACKNOWLEDGEMENTS

I am grateful to the National Veterinary Research Institute, Vom, Nigeria for financial support during my studies in the United States.

I wish to express my gratitude and appreciation to Dr. James E. Cook, Director, Animal Resource Facilities, for his encouragement, constant guidance throughout my studies of the immunofluorescent technique and advice in writing my thesis. I want to thank Dr. Stanley M. Dennis, Head, Department of Pathology, for kind supervision and advice during my studies at Kansas State University. I also wish to thank Dr. Harry D. Anthony, Head, Diagnostic Laboratory Services and Dr. Harish D. Minocha for serving on my research committee.

I am extremely grateful to Dr. Wayne E. Bailie who provided the cultures used in testing for specificity of the conjugates. Special thanks go to Dr. Sam O. Ogunjumo, Dr. John B. Adeyanju, Dr. Tai A. Cole and Dr. Walid A. Al-Katib for their valued assistance in collection of materials.

The help of the following will be valued for a long time--Anne Kerr, Duane Kerr, Bill Stowe, Dixie Dickens, Terry Moore, Frank Leatherman and John Lyons. I really appreciate them and all others that I worked with during my training.



Finally, I wish to thank my family and Ronke for their understanding and patience during my absence from Nigeria.

## TABLE OF CONTENTS

	Page
Acknowledgements . . . . .	i
List of Tables . . . . .	vii
List of Figures . . . . .	viii
INTRODUCTION . . . . .	1
I. Review of Literature	
A. Immunofluorescent Techniques . . . . .	3
1. Historical . . . . .	3
2. Basic Considerations . . . . .	12
a. Preparation of Antisera . . . . .	12
b. Antibody Titer . . . . .	15
c. Fractionation of Antisera . . . . .	16
d. Determination of Protein Concentration. . .	17
e. Conjugation of Protein with Fluorescein Isothiocyanate . . . . .	17
f. Determination of FITC in Conjugates . . . .	20
g. Immunofluorescent Technique in Diagnostic Bacteriology . . . . .	20
h. Difficulties. . . . .	25
1) Nonspecific Staining . . . . .	25
2) Minimizing NSS . . . . .	28
3) Fluorescent Microscopy . . . . .	31
B. Ovine Epididymitis . . . . .	32
1. Introduction . . . . .	32
2. <u>Brucella</u> Epididymitis . . . . .	34

	Page
a. Differential Features . . . . .	35
1) Growth Requirements and Cultural Characteristics . . . . .	35
2) Morphology . . . . .	36
3) Biochemical Properties . . . . .	37
b. Taxonomic Position of <u>Brucella ovis</u> . . . . .	38
c. Transmission . . . . .	40
d. Pathology . . . . .	43
1) Gross Findings . . . . .	44
2) Histopathology . . . . .	48
e. Diagnosis . . . . .	53
1) Physical Examination . . . . .	53
2) Immunodiagnosis (serodiagnosis). . . . .	54
3) Examination of Semen . . . . .	58
i) Semen Collection . . . . .	58
ii) Visual Examination . . . . .	61
iii) Microscopic Examination . . . . .	62
iv) Bacteriology . . . . .	65
v) Abnormalities of Semen . . . . .	67
3. <u>Actinobacillus</u> Epididymitis . . . . .	69
a. Transmission . . . . .	71
b. Gross Pathology . . . . .	71
c. Histopathology . . . . .	72
d. Examination of Semen . . . . .	73

	Page
e. Diagnosis . . . . .	74
4. <u>Corynebacterium</u> Epididymitis . . . . .	75
II. Materials and Methods	
1. Cultures . . . . .	76
2. Preparation of Antigens . . . . .	76
a) <u>Actinobacillus seminis</u> . . . . .	76
b) <u>Brucella ovis</u> . . . . .	77
c) <u>Corynebacterium pseudotuberculosis</u> . . . . .	78
3. Preparation of Antiserums . . . . .	78
4. Determination of Antibody Titer . . . . .	79
5. Fractionation of Antiserums . . . . .	79
6. Dialysis . . . . .	80
7. Determination of Protein Concentration . . . . .	81
8. Conjugation with Fluorescein Isothiocyanate. . . . .	82
9. Removal of Unreacted Fluorescent Material. . . . .	82
10. Storage of Conjugates . . . . .	83
11. Testing Immunofluorescent Reagents . . . . .	83
a) Homologous and Heterologous Staining . . . . .	83
b) Indirect Immunofluorescent Staining of <u>A. seminis</u> . . . . .	85
c) Immunofluorescent Staining of <u>A. seminis</u> in Ovine Semen . . . . .	86
d) Testis Tissue Powder. . . . .	88
e) Cellulose Acetate Strip Electrophoresis . . . . .	88

	Page
III. Results	
<u>Actinobacillus seminis</u> . . . . .	91
<u>Brucella ovis</u> . . . . .	97
<u>Corynebacterium pseudotuberculosis</u> . . . . .	98
Cellulose Acetate Strip Electrophoresis . . . . .	102
IV. Discussion . . . . .	108
References . . . . .	114
Appendices . . . . .	132
A. Fluorescein Isothiocyanate Conjugation . . . . .	132
B. Unreacted Fluorescent Removal. . . . .	134
Abstract	

## LIST OF TABLES

	Page
Table I.      Organisms Stained with FITC-Conjugated <u>A. seminis</u> Antiserum . . . . .	92
Table II.     Organisms Stained with FITC-Conjugated <u>Br. ovis</u> Antiserum . . . . .	99
Table III.    Organisms Stained with FITC-Conjugated <u>C. pseudotuberculosis</u> Antiserum . . . . .	103

## LIST OF FIGURES

	Page
Fig. 1. Specific Immunofluorescence of <u>A. seminis</u> . .	93
Fig. 2. Specific Immunofluorescence of <u>A. seminis</u> . .	93
Fig. 3. Specific Immunofluorescence of <u>A. seminis</u> . .	93
Fig. 4. Specific Immunofluorescence of <u>A. seminis</u> . .	94
Fig. 5. Specific Immunofluorescence of <u>A. seminis</u> . .	94
Fig. 6. Specific Immunofluorescence of <u>A. seminis</u> . .	94
Fig. 7. Semen Smear Showing Specific Immunofluorescence of <u>A. seminis</u> . . . . .	95
Fig. 8. Semen Smear Showing Specific Immunofluorescence of <u>A. seminis</u> . . . . .	95
Fig. 9. Semen Smear Showing Specific Immunofluorescence of <u>A. seminis</u> . . . . .	95
Fig. 10. Specific Immunofluorescence of <u>A. seminis</u> . .	96
Fig. 11. Specific Immunofluorescence of <u>A. seminis</u> in Semen Smear . . . . .	96
Fig. 12. Specific Immunofluorescence of <u>Br. ovis</u> . . .	100
Fig. 13. Specific Immunofluorescence of <u>Br. ovis</u> . . .	100
Fig. 14. Specific Immunofluorescence of <u>Br. ovis</u> . . .	100
Fig. 15. Specific Immunofluorescence of <u>Br. ovis</u> . . .	101
Fig. 16. Specific Immunofluorescence of <u>C. pseudotuberculosis</u> . . . . .	101
Fig. 17. Specific Immunofluorescence of <u>C. pseudotuberculosis</u> . . . . .	104
Fig. 18. Specific Immunofluorescence of <u>C. pseudotuberculosis</u> . . . . .	104
Fig. 19. Specific Immunofluorescence of <u>C. pseudotuberculosis</u> . . . . .	104

	Page
Fig. 20. Cellulose Acetate Strip Electrophoresis: Protein Profile . . . . .	105
Plate 1. Densitometer Chart Tracings . . . . .	107



## INTRODUCTION

Epididymitis in sheep is an acute or chronic disease of major importance in sheep raising countries and has a number of causes. Diagnosis is based on clinical palpation to detect epididymal induration, spermatic granulomas and enlargements especially of the tail. The main cause is Brucella ovis. It is clinically difficult to differentiate it from epididymitis due to Actinobacillus seminis, Corynebacterium pseudotuberculosis, Corynebacterium pyogenes, Staphylococcus aureus, and other bacteria. The differential diagnosis also includes spermiostasis and spermatic granulomas resulting from aberrant efferent ducts, segmental aplasia of the Wolffian ducts, and varicoceles. Corynebacterium spp. and S. aureus tend to produce abscesses and not spermatoceles and spermatic granulomas in contrast to Br. ovis and A. seminis infections. Epididymitis due to the latter two are clinically and pathologically indistinguishable; diagnosis is based on clinical examination and complement fixation testing. The discovery of A. seminis in the U.S. complicates brucellosis control and eradication programs in sheep.

Ovine epididymitis has been diagnosed on the basis of clinical signs, pathological and serological findings, and evaluation and bacteriological examination of semen. The impracticability and unreliable nature of semen culture and

inadequacy of physical examination resulted in serological methods emerging as the most dependable single aid in detecting infection in individual rams of a flock. As the above epididymal syndromes are almost clinically indistinguishable, there is a need for developing reliable diagnostic procedures, especially serological and improved differential media for bacterial isolation.

The perplexing problems associated with diagnosing ovine epididymitis are compounded by the difficulties in isolating and identifying causative agent(s). Therefore, it was considered worthwhile to investigate immunofluorescence for diagnosing ovine epididymitis. There is little information on the application of IFT for studying ovine genital diseases. From studies of bovine vibriosis, IFT has at least been found to be a comparable diagnostic method when nonspecific fluorescence was minimized.

The purpose of this study was to investigate the immunofluorescence technique for diagnosing ovine epididymitis.

The objectives were to:

1. Develop conjugates for specifically identifying  
A. seminis, Br. ovis, and C. pseudotuberculosis.
2. Develop an IFT for rapidly detecting and identifying  
A. seminis in semen of infected rams.

**THIS BOOK  
CONTAINS  
NUMEROUS PAGES  
THAT WERE  
BOUND WITHOUT  
PAGE NUMBERS.**

**THIS IS AS  
RECEIVED FROM  
CUSTOMER.**

## I. REVIEW OF LITERATURE

## A. IMMUNOFLUORESCENT TECHNIQUES

### 1. Historical

Early investigations with marked antibodies established the principle that it was possible to introduce chemical groups into an antibody molecule without destroying its specific reactivity. Reiner (1930) prepared serologically active atoxyl-azo conjugates of antipneumococcus Type I and II antibodies, using para-aminophenylarsonic acid (atoxyl) for diazotization at pH 5.0 to 7.5. It was suggested that introduction of arsenic into the antibody-carrier protein might be useful for quantitative study of the degree of purification of antibodies as well as quantitative study of the antibody reaction.

Working with therapeutic sera, Bronfenbrenner et al (1931) coupled immune sera with diazotized aromatic amines (para-toluidin, para-anisidine, atoxyl, sulphanilic acid, anthranilic acid, naphthionic acid and amino R salt). It was noted that the preparations lost their species specificity but retained a fair degree of specific immune properties and that their antigenic properties were, in general, less marked than those of native serum.

Heidelberger et al (1933) used a colored label to distinguish between kinds of protein present in an antigen-antibody system. A purplish-red diazo dye

(R-salt-azo-benzidine-azo-egg albumin) was employed in order that colorimetric determination of the antigen in precipitates or supernatants might be as accurate as possible. Marrack (1934) reacted anti-typhoid and anti-cholera sera with diazotized benzidine-azo-R-salt and demonstrated for the first time that homologous organisms were specifically colored pink by the chemically modified antibodies. Fieser and Creech (1939) synthesized and characterized  $\beta$ -anthryl-1,2-benzanthryl-3- and 1,2-benzanthryl-10-isocyanate by conversion to various carbamates and substituted ureas. The isocyanates were coupled with glycine and  $\epsilon$ -aminocaproic acid to give alkali-soluble derivatives. The method of conjugation in aqueous dioxane was found suitable for proteins.

These early findings were not widely accepted because the labels employed were difficult to detect. However, Creech and Jones (1940) found that four conjugates, prepared by interacting isocyanates of polynuclear aromatic hydrocarbons with several proteins, were highly fluorescent.

Other similar conjugated proteins were prepared via coupling in an aqueous dioxane medium and the conjugates were purified by ammonium sulphate and acetone precipitation and the degree of coupling was determined by ultraviolet spectrophotometry. The characteristic fluorescence exhibited by these conjugates in ultraviolet light varied from blue to green (Creech and Jones 1941).

Coons et al (1941) conjugated a  $\beta$ -anthryl-carbamido derivative with antipneumococcus III rabbit serum, that gave a faint blue fluorescence in ultraviolet light in very dilute solution. Unfortunately, since mammalian connective tissue exhibited a blue fluorescence that was enhanced by formalin fixation, this particular antibody conjugate was inadequate for demonstrating antigens in tissues. Immunofluorescent technique (IFT) was initiated with the synthesis of fluorescein-4-isocyanate by the interaction of phosgene and 4-aminofluorescein. The crude fluorescein isocyanate (FIC) was conjugated with pneumococcus III anti-serum to form chemically modified antibodies that fluoresce green (Coons et al 1942). With this significant achievement, numerous reports of the practical application of immunofluorescence appeared. Thus, the cytological distribution of the pneumococcal polysaccharides, types II and III, in mouse tissues was followed histochemically by means of the IF technique (Kaplan et al 1950).

Rickettsia of epidemic typhus fever and Rocky Mountain spotted fever were microscopically localized and identified in smears of exudates and tissue sections from infected cotton rats by means of homologous antibody labelled with fluorescein. Epidemic typhus was also identified in smears from single infected human body lice. Mumps virus antigen was similarly microscopically localized in the parotid acinar cells, lumens, ducts and in the cytoplasm of lining

duct epithelial cells in experimentally infected monkeys (Coons et al 1950).

IFT was also applied to trace the fate of three proteins (crystalline hen's egg albumin, crystalline bovine plasma albumin and human plasma gamma-globulin) after intravenous injection into mice. This was accomplished by preparing frozen sections of quick-frozen tissue, allowing what foreign protein might be present in the section to react with homologous fluorescein-labelled antibody, and examining the section under the fluorescence microscope (Coons et al 1951).

Clayton (1954) extended IFT to the study of changes in distribution of multiple antigens relative to one another during different stages of development in mice. A mixture of several antiserums of different specificities, each coupled to a different dye, was used. FIC gave green fluorescence; 1-dimethyl-amino-5-sulphonyl-chloride-naphthalene yielded a yellow fluorescence while red fluorescence was due to nuclear fast red (benzaldehyde-6-nitro-2-sodium-diazotate).

Weller and Coons (1954) described an indirect IFT for studying etiologic agents of varicella and herpes zoster in vitro. Employing the infected preparations as antigen, fixation of antibody (from human serums derived from cases of varicella, herpes zoster or herpes simplex) was detected by using fluorescent antihuman gamma globulin conjugate.



A method for the specific histochemical demonstration of antibody in cells and parts of cells was carried out in a two stage immunological reaction on frozen tissue sections: 1) allowing reaction between antibody in tissue and dilute antigen applied in vitro, and 2) detecting those areas where this antigen had been specifically absorbed using a fluorescein-labelled antibody. Examination under a fluorescence microscope revealed a yellow-green fluorescence over those areas where a precipitate was formed (Coons et al 1955).

Coons (1956) reviewed the status of IFT. Antibody coupling to a visible label (FIC) provided a microscopic method for studying cells for their content of complex biological substances, and potentially placed a large body of immunological knowledge at the service of histochemists. One major problem remained; purification of the chosen antigenic material derived from the species to be explored, in order to stimulate synthesis of the necessary antibody in some other convenient species. Some other problems associated with IFT included setting up of a fluorescence microscope and obtaining the necessary labelled antibody.

Moody et al (1956) used fluorescein-labelled antiglobulin to identify individual cells of Malleomyces pseudomallei in dried smears prepared from pure cultures. Liu (1956) described a simple, practical and rapid method for diagnosing human influenza infection by means of fluorescein-labelled antibody staining of cells flushed from the nose. Even

though the IFT had a lower sensitivity than the hemagglutination-inhibition test (HIT), a positive diagnosis could be made on the same day as the specimens were collected, while the HIT required a delay of 10-14 days for collection of convalescent serum.

A fluorescent-inhibition technique (based on inhibition of specific staining with fluorescent antibody) was described for detecting Toxoplasma gondii (Goldman 1957). Goldman and Carver (1957) also described a method for stabilizing the isocyanate used in IFT by preparing acetone-dioxane solutions of FIC, dried onto filter paper. The reagent, stored in a desiccator at room temperature, remained active for seven months. It was noted that an antiserum could be stained more intensely by repeating the labelling process two or three times, without danger of loss of protein content as a result of denaturation.

The IF technique of Coons and Kaplan (1950) employed the yellow-green fluorescein label of antibodies to stain and identify organisms specifically. Silverstein et al (1957), however, used a second contrasting fluorescent label on antibody in conjunction with a fluorescein-labelled antibody for the simultaneous differential staining of two organisms in the same smear. This contrasting label was an orange fluorescing amino derivative of rhodamine B.

Pressman et al (1958), comparing the sensitivity of IFT with radioautography, noted that both techniques had

the advantage of demonstrating a small amount of antibody in the presence of a large amount of background protein, if the specific localization had a higher local concentration.

The original choice of fluorescein was based on the brilliance of its fluorescence and the rarity of green-fluorescing materials in tissues. It had the additional advantage that the wavelength of its emitted light (520 mμ, range 510 to 540 mμ) was near the maximum sensitivity of the retina (Coons and Kaplan 1950). However, Chadwick et al (1958) pointed out that fluorescein was not an ideal fluorochrome for tracer work because the method of conjugation was laborious and the apple-green fluorescence often contrasted with the blue-green of autofluorescence. Lissamine Rhodamine B 200 (RB 200) was synthesized to overcome these shortcomings. This dye had a brilliant red fluorescence in aqueous solution. In its sulphonyl chloride form it easily combined with serum proteins without protein denaturation, and yielded stable conjugates with a brilliant orange fluorescence in ultraviolet light. The dye stained organisms specifically as well as giving a reddish-orange background to the tissue.

The difficulties in preparation, the danger of using phosgene and the instability of isocyanates led Riggs et al (1958) to synthesize two new fluorescent isothiocyanate (FITC) dyes by using less toxic thiophosgene. FITC was obtained as an amorphous yellow-orange powder; Rhodamine B

isothiocyanate was a reddish-purple solid. Both compounds were stable for about six months. The dyes were successfully conjugated with antiserums against four different antigens--Bacillus anthracis, Pasteurella tularensis, Rickettsia typhi and Adenovirus RI-67, using the direct (Coons and Kaplan 1950) and indirect (Weller and Coons, 1954) techniques. Marshall et al (1958) compared the relative merits of FIC and FITC by labelling different globulin fractions of antiserums of bacterial, viral and mycotic agents as well as antiglobulin fractions from man and rabbit. Their results indicated that FITC was qualitatively superior to FIC with regards to stability, ease of conjugation and the degree of fluorescence at high dilutions.

Singer (1959) extended the use of IFT to the subcellular level by taking advantage of the resolution attainable with electron microscopy. Electron dense antibody conjugate was prepared by covalently coupling ferritin to antibody. Because of their electron density, individual ferritin molecules were demonstrated with the electron microscope, each exhibiting a characteristic micellar arrangement at the corners of a roughly square lattice.

Smith et al (1960) also used a slightly modified method to study formalin-fixed cultures of Staphylococcus aureus at the subcellular level.

Leduc et al (1969) noted that, in earlier studies using IFT at the subcellular level, penetration of cells

with ferritin-labelled conjugates was difficult because of the large size of the ferritin molecule (650,000 M.W.). Antibody conjugate was labelled with an enzyme marker of smaller molecular size (peroxidase, M.W. 40,000); this resulted in an osmiophilic, electron dense reaction product that could be visualized by electron microscopy. The T antigen of SV40 appeared in a reticular network throughout the nucleus. The problem of penetration diminished but there was a compromise between the degree of preservation of cell ultrastructure and the extent of penetration of labelled immunoglobulins. McLean and Singer (1970) solved the problem of embedding for ultrathin sectioning by using cross-linked albumin--a procedure that did not destroy antigenic activity, as methacrylate and epoxy embedding materials did.

Rinderknecht (1962) reported new methods aimed at obviating time-consuming dialysis while permitting the fluorescent labelling of protein solutions by using a sephadex column. The process of removing hydrolysed or unreacted dye and change of buffer as well as pH, occurred in less than 30 minutes.

Pital and Janowitz (1963) studied the effect of alkalinity (pH 9.0) on staining brightness in the fluorescent-antibody reaction. They concluded that, in all dilutions producing a staining reaction, the fluorescence was distinctly brighter at pH 9.0 than at pH 7.2. In addition,

end-point dilutions exhibiting detectable staining were higher at pH 9.0.

Cook et al (1971) enumerated certain disadvantages associated with using formalin-fixed cryostat sections of tissues in IF studies of Leptospira:

1. The antigen could be detected readily in formalin-fixed tissues but it was difficult to recognize individual leptospire.

2. Both cryostat and a skilled technician must be available.

3. Cryostat-sectioned tissues may become separated from the microscope slides during the prolonged washing and staining required to detect leptospire in formalin-fixed tissues. A new technique, not involving a cryostat, was developed. Scrapings of formalin-fixed tissues were smeared onto glass slides (previously dipped in 1% aqueous gelatine and air-dried) and then stained by direct and indirect techniques to detect fluorescein-labelled antigens. It was found that nonspecific staining was of little significance since specific staining clearly demonstrated leptospire as individual organisms free from debris.

## 2. Basic Considerations

### a. Preparation of Antisera

There are probably more methods for producing antiserum than there are immunologists. Basically one would like to

produce a high titer precipitating antibody that could be diluted sufficiently to reduce or eliminate nonspecific and background fluorescence. Serum from a natural host that had survived infection and possibly subsequent challenge to minimize an anamnestic response would be ideal (Stone 1976).

Methods for producing antiserum are largely empirical. Three factors should be considered: the animal must be stimulated repeatedly; the dose of antigen must be adequate but not overwhelming; and, for nonliving antigens, the use of adjuvants, particularly those of water-in-oil emulsion type, for increasing titer (Coons 1956).

Antibody response is more or less equal to the square root of the change in the antigenic dose administered. This means that the antibody level obtained is not directly proportional to the amount of antigen given. For example, to increase the antibody level three times, it is necessary to increase the antigen dose nine times; conversely, reducing the antigen dose nine-fold only reduced the antibody response about three-fold (Edsal 1957).

Freund (1947) reviewed promoting antibody formation by the addition of unrelated substances such as paraffin oil, kaolin, charcoal, living and killed tubercle bacilli to antigens and reported that antibody response was potentiated and prolonged when the antigen was mixed with killed tubercle bacilli or saprophytic mycobacteria suspended in water-oil

emulsion (adjuvant). It was essential to administer the antigen in water-in-oil emulsion; oil-in-water emulsion was ineffective (Freund 1951).

Dixon and Pittsburgh (1954) reported that the rates of synthesis and degradation of antibody to serum protein antigens were intimately related to the fate of antigen. Prior to appearance of antibody, antigens were catabolized much the same as the host's own serum proteins. With the appearance of antibody, antigen catabolism became extremely rapid. Antibody synthesis was rapid only during the time antigen was readily demonstrable in the host. Antibody to serum protein antigens was catabolized slowly, as was non-antibody globulin, in the absence of antigen and rapidly, as was the antigen itself, in the presence of antigen.

Most antigens of diagnostic significance are complex and incompletely defined. Even a relatively simple antigen might elicit an extremely heterogenous host response that involved both cellular and humoral immunity with the simultaneous production of different classes and subclasses of antibody, the relative concentrations of each changing with time and each representing heterogenous molecular populations with respect to specificity, avidity and physico-chemical characteristics. Patients might have different patterns of response within a "normal" range of biological variability (usually undefined). Diagnostic antiserums were made in mature animals that had antibody populations



peculiar to their individual genetic and environmental influences, and these might cross-react in diagnostic tests. Superimposed on this pattern of antibody heterogeneity was the possibility, during fluorochromal labelling, of producing underlabelled and overlabelled antibody, as well as nonantibody molecules, in the same reagent (Cherry and Reimer 1973).

Animals failing to produce a significant antibody response within about a month would probably fail to do so. Those that did should be kept. The most important ingredient for the production of high titer is time. After six months or more they might be cautiously reinjected. Antibodies produced in the rabbit, horse, monkey, chicken, dog, cow and goat have been successfully used (Coons 1956).

#### b. Antibody Titer

The antibody titer of a serum is usually given in terms of the highest dilution at which it will agglutinate, hemolyze or precipitate the antigen, the volume of toxin it neutralizes, the optimal proportion in which flocculation with antigen occurs, mouse protection--all relative and often inaccurate measures giving no idea whatsoever of the actual mass of antibody involved. The dilution methods particularly, are subject to error of 50 to 100 percent in deciding which was the last positive tube (Heidelberger

et al 1933). In spite of the above, agglutination techniques have become useful tools for detecting small amounts of antibody. Qualitative and semi-quantitative methods of measuring agglutinins included slide and tube agglutination tests, the latter being preferred for titrations of agglutinins by dilution and optimal proportions methods, using particulate antigens. They provide rapid and convenient relative methods for assaying the antibody content of antiserums (Kabat and Mayer 1964).

#### c. Fractionation of Antiserum

Before conjugating antiserum it is usual to carry out a fractionation procedure. The choice of method lies between isolating the globulin fraction by chromatography and simple removal of the bulk of albumin by a crude salting-out procedure (Johnson et al 1967). Conventionally, ammonium sulfate ( $(\text{NH}_4)_2 \text{SO}_4$ ) is widely used as a precipitating agent to isolate globulins. It has the advantage of producing minimal denaturation, high yield of globulin, and simplicity of use. The globulin in each species of animal requires a slightly different percentage of saturated ( $(\text{NH}_4)_2 \text{SO}_4$  to produce optimal results (Hebert et al 1973). Ammonium sulfate is also preferred for the following reasons:

1. Traces of labelled albumin do not produce nonspecific staining when conjugates are properly diluted before use.

2. The fraction obtained by salting-out might be reconstituted to a protein level suitable for conjugating without the need for concentration.

3. If the salting-out procedure is carried out entirely in the cold, the antibody activity in the globulin fraction is comparable to that of the original antiserum (Johnson et al 1967). However, it might occasionally be desirable to prepare conjugates from more refined globulin fractions obtained by chromatography (Goldstein et al 1961).

d. Determination of Protein Concentration

To prepare a conjugate, the protein to be labelled must be accurately measured. The actual weight of FITC is determined by calculations based on several facts, including the total mg of protein. Protein may be measured by determining the N content by the micro-Kjeldahl technique. Before determining the protein concentration of the final globulin, all  $(\text{NH}_4)_2 \text{SO}_4$  must be removed (Stone 1976). The Biuret (Gornall et al 1949) method, however, has proved to be simple and reliable.

e. Conjugation of Protein with Fluorescein Isothiocyanate

Since the introduction of IFT, several procedural variations for labelling serum proteins with FITC have been described. Coons and Kaplan (1950) added FIC in an

acetone-dioxane solution to an immune serum fraction containing acetone, dioxane and carbonate-bicarbonate buffer, the temperature maintained at 0 to 2C. Goldman and Carver (1957) used dry filter paper strips impregnated with FIC and labelled at low temperature without using organic solvents. Riggs et al (1958) introduced the use of FITC in acetone to immune globulin containing acetone and carbonate-bicarbonate buffer, and carried out the reaction at 4C. Marshall et al (1958) added FITC to carbonate-bicarbonate buffered globulin and avoided the use of organic solvents; the reaction was carried out at 4C over a 12 to 18 hour period.

To overcome the variations in staining with different conjugates and antigens, Goldwasser and Shepard (1958) simplified labelling as well as quantitative control of the efficiency of labelling. In general, 0.2 ml of conjugate sufficed for determining the fluorescein-protein (F:P) ratio; this only required a few minutes. Clark and Shepard (1963) labelled immune gamma-globulin by allowing FITC, in a buffered aqueous solution, to diffuse into the gamma-globulin through a dialysis membrane. The dialysis labelling was carried out at 4C for 24 hours.

Tokumaru (1962) investigated the kinetics of the FITC reaction with serum globulin, using sephadex gel filtration for rapid separation of the reactants. The buffer salt concentration, protein concentration, pH and temperature were

all important factors in determining the reaction rate of FITC with globulins. It was recommended that the pH of the conjugation system not exceed 8.8 to avoid decomposition of the FITC. Other studies, however, indicated that at 25 °C, pH 9.5, protein concentration 2.5% and buffer salt concentration of 0.05M, conjugation of FITC with rabbit gamma globulin was essentially completed in 30 minutes (McKinney et al 1964). The isothiocyanate method for covalent coupling of fluorescent molecules to globulins has been successful for the average investigator.

Purified preparations of fluorescein and rhodamine isothiocyanates are readily available from several commercial manufacturers and if necessary, FITC may be purified by chromatographic techniques (Dandliker et al 1967).

In spite of many modifications, FITC coupling depends on the reaction of the epsilon amino group of lysine in the globulin with isothiocyanate. Although globulins have 80 or more lysine residues, most are either not available for coupling or the reaction never proceeded to completion. On a weight basis, 8-15 ug fluorescein (F) will combine with 1 mg of globulin (P). On a molar basis, this is 3-7 and produces a satisfactory fluorescent antibody (Stone 1976). In theory, a high F/P ratio is desired to allow high dilutions of the IF reagent, thereby increasing the specificity by reducing cross-reactive nonspecific background

fluorescence (Griffin et al 1961). However, high P/F ratios could reduce specificity by increasing background (Mothershed 1969).

f. Determination of FITC in Conjugates

McKinney et al (1964) found that fluorescein diacetate served as an excellent color standard for quantitatively determining the fluorescein bound to protein by spectrophotometric measurement. Relationship of the extinction coefficient of fluorescein diacetate to that of other pertinent fluorescein derivatives was also determined (McKinney et al 1964).

Paper chromatographic methods have been useful for determining the number and types of components present in an FITC product and for semiquantitatively measuring the FITC content of the product. The infrared method requires the availability of an infrared spectrophotometer suitable for making analytical measurements and a relatively pure FITC product for use as a reference standard (McKinney et al 1966).

g. Immunofluorescent Technique in Diagnostic Bacteriology

Methods used in diagnostic bacteriology to identify organisms generally involved procedures from which results could not be expected for a few hours at best. If a

complete biochemical and serological work-up was required after isolates have been obtained in pure culture, then results might not be available for several days. In some cases, characteristic staining reactions helped to identify organisms, but because of the nonspecific nature of such reactions, results were generally only presumptive. It was obvious, therefore, that diagnostic bacteriology would benefit greatly from development of methods that would enable one to make rapid specific identification of viable organisms. Such considerations prompted investigations into the possible application of the IFT to identify bacteria in smears. Since the basis of this method is immunochemical, and since reactions often took place in less than one hour, it is believed that the method might offer important advantages in diagnostic bacteriology (Moody et al 1956). However, instances, revealed complimentary nature of both bacteriological and IF procedures, and provided an indication for their combined use when possible (Pugh et al 1977).

Cherry and Moody (1965) pointed out that as with other new techniques, specific tests that succeeded must offer better diagnostic service without increased cost, or diagnostic service that was equal in reliability to that given by other tests but at reduced cost. The use of specific antibody as a histochemical reagent employed the precision of biological specificity for cytochemical purposes. The specificity of the various reactions must, however, be

established by appropriate controls, the character of which would vary with the substance and the circumstances. Labelled antibodies so used identified objects and localized them; they were most effective when used to answer a morphological question (Coons 1956).

The IFT as developed by Coons et al (1941, 1942) was extended by Coons and Kaplan (1950). It has proved to be a powerful tool for immunological research, experimental pathology, cytological investigations and diagnostic microbiology. Numerous bacteria, including acid-fast organisms, gave immunofluorescence; the only requirement was an exposed antigen or hapten at the surface of the bacterial cell. Each new test required its own field evaluation. This situation existed primarily because of the inherent nature of immunofluorescence techniques--extraordinary sensitivity, theoretically and often in practice, permitting detection or identification of a single bacterial cell admixed with large number of contaminants (Cherry and Moody 1965).

Immunofluorescence of bacteria has only two dimensions--morphology and serological specificity. The specificity of an IF test applied to mixed flora, therefore, must be determined experimentally for each bacterial species sought. Lack of specificity could be tolerated only if morphology of the cross-reacting antigen clearly distinguished it from the specific antigen (Cherry and Moody 1965).



Usually, no difficulty was experienced in locating specifically stained bacteria in mixtures containing ratios of contaminants to specific cells as high as  $10^7:1$  (Thomason et al 1956). The order of magnitude of the amount of antigenic material detectable by labelled antibody could also be estimated. A single pneumococcus, for example, was readily detectable microscopically at low magnifications after reaction with specific fluorescent antibody (Coons 1956).

The direct IF method, originally used to stain viruses in tissue sections, involved the direct application of a specific IF preparation to the cell being studied. In the indirect IFT, the virus was first reacted with a specific nonfluorescent antiserum prepared in the rabbit and then reacted with fluorescent antiglobulin prepared against rabbit globulin.

The direct IF method was adapted to the staining of bacteria in smears (Moody et al 1956). Individual cells of Malleomyces pseudomallei were identified on glass slides using fluorescein-labelled antiserum. A number of other investigations have found by means of specific IFT, that individual bacterial cells could be identified accurately in dried smears made directly from pure cultures, mixed cultures and from impression smears of infected animal tissues (Thomason et al 1956; Winter and Moody 1959).

Moody et al (1958) enumerated advantages of the IF method in studies grouping streptococci: rapidity and economy of serums, materials, media and reduced personnel costs.

Working with leptospires, Coffin and Maestrone (1962) claimed that:

- 1) IF results were specific because of the mode of action.

- 2) It was possible to detect minimal amounts of antigen both in fluids and tissues, regardless of the viability of the microorganisms, freshness of the material, pH, temperature, contamination and addition of formalin.

- 3) It was possible to ship dried smears and tissues or fluids preserved with formalin to central laboratories especially equipped with the necessary reagents and conjugates.

- 4) Diagnosis was faster than both bacterial culture and animal inoculation.

- 5) It was economical to establish and operate a central diagnostic laboratory to process suspect specimens sent from the field.

Biegeleisen et al (1962) also reported that smears prepared on glass slides using a phenolized suspension of brucella cells could be kept frozen until needed. These preparations, when tested periodically with labelled antibody for Brucella suis, stained brightly even after being frozen for periods up to seven months.

It should be borne in mind that immunofluorescence emission from suitably labelled bacteria depends on a number of characteristics such as the labelled bacteria; the mounting medium and in particular its pH, ionic strength, viscosity and presence of quenching agents; the light source; and the optics in the path of the light from its source to the labelled bacteria. This immunofluorescence rapidly fades under intense excitation (Taylor and Heimer 1974).

Pital and Janowitz (1963) also reported that high intensity fluorescence was obtained with lower dilutions of a conjugate. In all dilutions producing a staining reaction, the fluorescence was distinctly brighter at pH 9.0 than at pH 7.2. Moreover, end-point dilutions exhibiting detectable staining were higher at pH 9.0.

#### h. Difficulties

##### 1) Nonspecific Staining

Nonspecific staining (NSS) represented one of the most serious problems associated with IFT. It made differentiation between specific and nonspecific fluorescence (NSF) difficult. The precise localization of soluble antigens present in low and variable concentrations, and some other types of viral particles, was rendered unsure by the accompanying NSF (Goldstein et al 1961). NSS was defined as

the uptake, by tissue cells and matrix, of fluorescent components of a conjugate that could be either unreacted fluorescent material (UFM) or the labelled antibody itself. Neither autofluorescence nor heterologous staining of serologically related antigens could properly be designated nonspecific, even though their fluorescence is undesirable (Pittman et al 1967).

The complex phenomenon of NSS results from several known factors that are subject to control and that must be controlled in order to achieve maximum resolution of the specific antigen-antibody reaction. Some of these factors include:

- 1) Protein-protein interactions and unwanted tissue antibodies in the conjugate (Coons 1956).
- 2) FIC-labelled serums, reacting unspecifically with tissue components.
- 3) Adsorption of labelled antisera occurring in frozen sections of fixed or unfixed tissues (Mayersbach 1959).
- 4) NSS increasing with aging of conjugates (Chadwick and Nairn 1960).
- 5) Fluorescein-coupled gamma globulins (Goldstein et al 1961).
- 6) Use of crystalline preparation of FITC instead of the amorphous product at 50 mg/g protein (Goldstein et al 1961).

7) High fluorescein/protein ratios (linear correlation with NSS) resulting in overlabelling (Griffin et al 1961; Hebert et al 1967).

8) Impure dyes giving higher NSS (Hebert et al 1967).

9) Unbound part of fluorescein, not easily removable from serum.

10) Fluorochroming property of conjugates that is their capacity to act as a fluorescent dye (Beutner et al 1968; Beutner 1971).

Coons and Kaplan (1950) recommended conjugating antibody containing globulins at a molar F/P ratio of 1:2. Generally, high F/P ratios gave excessive NSS on tissues. This was confirmed in studies of vaccinia-infected HeLa cells (Fromhagen et al 1962) and in the mixed immunofluorescent staining with antinuclear antibody (ANA) (Beutner et al 1967) as well as in FA studies with group A, beta-hemolytic streptococci and E. coli (Pittman et al 1967; Hebert et al 1967). The degree of NSS also varies with the fluorescein (F) concentration (Hebert et al 1967). In addition, Beutner et al (1963) found that both the F concentrations and F/P ratios governed the degree of NSS as independent variables in their studies of indirect immunofluorescent staining with an ANA-containing serum.

Using convection electrophoresis, Curtin (1958) associated a rapidly moving peak with NSS. Employing column electrophoresis, Goldstein et al (1961) confirmed the:

- 1) Alteration in mobility produced by conjugation with FITC.

- 2) Heterogeneity in the coupled globulin molecules.

- 3) Fact that the factor producing nonspecific fluorescence migrated with the fluorescent antibody.

Fife et al (1959) found that with Trypanosoma cruzi, dried unfixed smears as well as those treated with various concentrations of methanol, ethanol, formalin or with heat regularly gave nonspecific reactions with normal serums. This NSS was associated with desiccation of the trypanosomes.

## 2) Minimizing NSS

To avoid some of these unspecific reactions, purification of serums by repeated adsorptions with organ powders was suggested (Coons 1956). However, some drawbacks are associated with repeated adsorptions:

- 1) The procedure caused considerable loss of conjugate.

- 2) Bacterial contamination was frequent, necessitating absorption of small samples for immediate use.

- 3) Some NSS persisted despite three or more adsorptions.

It had been established that coupling proteins with aromatic isocyanates altered the isoelectric point (IEP) and solubility (Coons et al 1950; Shiller et al 1952). Each treatment lowering the IEP of tissue proteins would decrease or abolish the unspecific uptake of serums by tissue sections

(e.g. storage of sections for several days, heat or chemical influences of fixatives and rinsing solutions of a high pH). Mayersbach (1959) demonstrated by using freeze-dried material for IFT, freezing drying conveniently lowered the IEP of tissues sufficiently to abolish unspecific reactions without impairing the specific antigenicity.

Smith et al (1959) found that counterstaining with Lissamine Rhodamine RB200 gave a contrasting reddish-orange background with fluorescein-labelled antibody systems and reduced nonspecific fluorescence in tissues and tissue cultures. Chadwick and Nairn (1960) found that extraction with powdered activated charcoal removed the UFM almost completely but also markedly reduced the staining intensity of the conjugates. Goldstein et al (1960), however, found little difference when fluorescent globulin preparations were applied to substrates without adsorption and after adsorption (with various kinds of tissue powders) between the amount that could be applied without inducing a disturbing degree of nonspecific fluorescence and the amount still capable of producing specific fluorescence. Goldstein et al (1961) concluded that NSS could be reduced but not eliminated by any one, or any combination, of the following:

- 1) Conjugating only gamma-globulins with FITC.
- 2) Removal of dialyzable fluorescent products on sephadex, followed by concentration through the use of pressure dialysis.

### 3. Use of crystalline preparations of FITC.

Frommhagen and Spendlove (1962) used electrophoretic analysis to demonstrate that six preparations of FITC from one source contained degradation products that exhibited essentially similar fluorescence properties and a similar capacity to couple with serum protein, but that conferred upon the conjugate the propensity for NSS. It was, therefore, recommended that only undegraded FITC that manifested superior specificity and higher fluorescence intensity, be used for conjugating specific immune gamma-globulins, and that pH of the conjugation system not exceed 8.8.

McDevitt et al (1963) evaluated column chromatography and suggested that stepwise elution from diethylaminoethyl (DEAE) cellulose columns could be adapted to large-scale purification of fluorescent conjugates to eliminate NSS. In applying IFT to the diagnosis of bovine vibriosis, Mellick et al (1965) minimized nonspecific fluorescence in stained specimens by using a fraction of the conjugate separated by ion-exchange chromatography. Johnson et al (1967) remarked that NSS attributable to the conjugate was largely overcome by using very potent antiserums for preparing conjugates so that the latter may then be considerably diluted for staining.



### 3) Fluorescent Microscopy

Fluorescence microscopy is more demanding than ordinary "white" light microscopy because mechanical and optical alignment is more critical when the image is relatively dim. Since the brightest fluorescent field is likely to be several times less bright than the ordinary microscope field illuminated with white light, it is important that the microscope be utilized at its highest efficiency. Alignment of the illuminator, types of substage condensers and characteristics of microscope objectives are especially pertinent to fluorescence microscopy (Cherry et al 1960).

Conventional microscopes equipped with glass (as opposed to quartz) optics are suitable for use in IF studies. Although achromatic objectives are suitable, brighter images are obtained with apochromatic or fluorite lenses possessing higher apertures. Very bright light sources are needed to produce visible fluorescence with the minute amounts of fluorescein involved in IF reactions. Lighting sources are usually mercury arc or the newer quartz-iodine-tungsten (halogen) lamps, although xenon lamps also are used for photography, for high intensity excitation at the longer visible wavelengths, and as a stable light source for quantitative IF measurements with incident light. Xenon lamps require DC power supplies that are expensive. The HBO-100 mercury arc lamp is also operated from an expensive DC power supply (Jones et al 1978).

## B. OVINE EPIDIDYMITIS

### 1. Introduction

Infectious ovine epididymitis (IOE, ram epididymitis, ovine brucellosis) is a chronic and insiduously progressive disease caused by Brucella ovis. The disease is characterized by a nonsuppurative inflammation of the interstitium of the tail of the epididymis and by cystic degeneration of the lining epithelium and suppurative inflammation of the epididymal tubules. The inflammatory reaction may result from two separate pathogenetic processes; an inflammatory response to the bacterium itself, and second, an autoimmune reaction manifested against aberrant epididymal ductal contents released during and following infection (Biberstein et al 1964).

It was recognized early that infection leading to genital involvement could be accomplished by a number of nonvenereal routes (Hartley et al 1954). Thus, an extra-genital, presumably bacteremic, phase of the disease had to be considered.

Bacterial epididymitis of rams was described first in Australia (Simmons and Hall, 1953) and New Zealand (Buddle and Boyce, 1953). It has subsequently been found elsewhere; United States (McGowan and Schultz, 1956; Kennedy et al 1956), South Africa (Van Rensburg et al 1958), and Brazil (Ramos et al 1968).

The disease apparently affected all breeds of sheep including Merino (Galloway 1966; Murray 1969; Watt 1970, 1972; Laws et al 1972), Suffolk (Hartley 1955; Keogh et al 1958; McGowan and Devine 1960), Dorset Horns and Border Leicester (Galloway 1966), and Desi rams (Lal Krishna et al 1977). Merino and Suffolk breeds appeared to suffer a high incidence (Jensen 1974).

Individual sheep originating from epididymitis-free areas probably have a higher susceptibility than sheep in general. Rams beyond the age of sexual maturity are believed to be susceptible although incidence increases directly with age. The incidence of clinical epididymitis is higher in flocks containing rams with brucellosis than in brucellosis-free flocks. The incidence in one study were 13.7% and 9.2%, respectively (Murray 1969).

Failure to isolate bacteria from chronic epididymitis in rams led to the suspicion that trauma may be a cause (Gunn 1942). Traumatic spermatocele has been recognized in Dorset Horn rams (Pulsford et al 1967). Graves and Engel (1950) found experimentally in dogs that sterile urine could, under conditions of high intra-abdominal pressure, pass through the vas deferens in a retrograde fashion and, upon reaching the epididymis, cause an inflammatory reaction.

The history, pathology, bacteriology, transmission, sequelae, diagnosis, treatment and control of Brucella infection in sheep have been reviewed (Lawrence 1961).

There is little information available on ram epididymitis caused by microorganisms other than Brucella ovis. There were a few reports where the genera Actinobacillus, Histophilus and Corynebacterium, have been associated with or produced epididymitis. The infections as described were clinically similar to Brucella-induced epididymitis.

Jamieson and Soltys (1947) described a suppurative infectious epididymo-orchitis with diffuse fibrinous orchitis in rams in Scotland caused by Pasteurella pseudotuberculosis. The lesions indicated that the disease originated in the epididymis and then extended to the testis. They noted that the disease incidence was sporadic and occurred during periods of tick activity.

The bacteriological findings in ram epididymitis indicated that a variety of microorganisms, such as Streptococcus species, Staphylococcus species and other Pasteurella species, may be important etiological agents of ovine epididymitis. Other organisms included Bacteriodes sp. Br. abortus and Br. abortus strain 19 (Ekdahl et al 1968).

## 2. Brucella Epididymitis

There were numerous reports of the isolation of Br. ovis from the epididymis (Simmons and Hall 1953). Br. ovis is a major cause of ram epididymitis and commonly inhibits normal semen production in infected rams (Jensen 1974). The

organism may be readily recovered from the semen of naturally and experimentally infected rams even in the absence of palpable genital lesions and from the epididymides, tunicae vaginales, testes, accessory sex glands and regional lymph nodes (Buddle and Boyes 1953).

a. Differential Features

1) Growth Requirements and Cultural Characteristics

For primary isolation, growth is best in a microaerophilic atmosphere of 10% carbon dioxide. Growth does not occur aerobically and is slight anaerobically (Buddle 1956).

Growth on Difco<sup>a</sup> tryptose blood base agar plus 5% bovine blood is visible in 3 to 5 days as small circular, convex, entire, glistening, smooth, translucent, greyish colonies approximately 0.2 to 0.4 mm in diameter. When illuminated by transmitted light, the colonies are yellowish-gray and finely granular. On the surface of the colonies, small granular-appearing central papillae may be seen (Kennedy et al 1956).

Cultures in Difco<sup>a</sup> tryptose broth enriched with 10% bovine serum have moderate turbidity with a slight fine sediment by 5 days. This sediment readily disperses on shaking. There is moderate growth in nutrient gelatine

---

<sup>a</sup>Difco Laboratories, Detroit, MI.

plus 10% bovine serum but no liquefaction after 21 days' incubation. Slight growth develops along the line of inoculation in stabs in serum-enriched semisolid agar, but no surface growth. No hemolysis occurs on bovine, ovine or equine blood. All colonies were rough when examined by the rapid acriflavine test (Braun and Bonestell 1947) and following staining with a 1/2000 solution of crystal violet (White and Wilson 1951). An observation of interest was that all colonies of Br. ovis on solid medium after first culture from naturally infected sheep were of a nonsmooth type (Buddle and Boyes 1953; Buddle 1956). Most strains tended to die if frequent transfers were not made.

## 2) Morphology

On primary isolation, Br. ovis is a nonmotile, nonsporing, noncapsulated small gram-negative, very pleomorphic bacillus or cocco-bacillus with rounded ends, slightly convex sides and straight axes, ranging in size from 0.3u to 0.5u in width and 0.7u to 1.5u in length (McFarlane et al 1952; Simmons and Hall 1953; Kennedy et al 1956; Buddle 1956). There is some tendency toward bipolar staining and gram variability. Many bacilli contain metachromatic granules. The organism may be arranged singly or in pairs, occasionally in triplets and frequently in clumps. In recently isolated cultures bizarre forms such as cuneate cells, singly or in pairs,

with thinner ends facing each other, and teardrop-like and spherical bodies may be present. After repeated transfers, the organism becomes uniformly gram-negative and coccobacillary. It is nonacid-fast when stained by the Ziehl-Neelsen technique but retains the red dye in the modified acid-fast staining technique (Kennedy et al 1956). In cultures from inoculated yolk sacs of seven-day chick embryos, there was reversion to the very pleomorphic form of primary isolations from ram epididymides (Kennedy et al 1956). The pleomorphic character of Br. ovis has been emphasized. As this pleomorphism may be seen in direct smears or in sections of affected organs, it is not a cultural artefact and might represent an important characteristic of brucellae (Kennedy et al 1956).

### 3) Biochemical Properties

No acid was produced from carbohydrates (mono-, di-, tri- and poly-saccharides, alcohols, glucosides or inositol). Growth occurred in the presence of thiamine. The methyl red, Vogel-Proskauer and indol tests were negative. Nitrate was not reduced to nitrite and hydrogen sulphide was not formed. No changes occurred in litmus milk and urea was not decomposed. Catalase test was strongly positive but oxidase test was negative (Simmons and Hall 1953; Buddle and Boyes 1953; Kennedy et al 1956).

b. Taxonomic Position of the Organism

The genus Brucella includes five species of major importance to veterinary medicine: Br. melitensis, with infection reservoirs in goats and sheep; Br. abortus with infection reservoirs in cattle; Br. ovis with infection reservoirs in sheep; Br. suis, with infection reservoirs in swine, and Br. canis, with infection reservoirs in dogs (Carmichael 1976). Another member of the genus, Br. neotomae, has been associated with the desert wood rat (Stoenner and Lackman 1957). Thus, the Brucella genus contains representatives with worldwide distribution and widely divergent host ranges. Besides the existence of these main Brucella groups, there exists within each group a number of sub-groups, containing transitional strains, that frequently are associated with some particular geographical location. The suggestion was that members of the Brucella group were relatively labile and responded readily to environmental changes. Thus there is a need for applying the fullest range of available tests for classifying individual Brucella strains (Wilson 1933).

Bacteria classified in the genus Brucella by biochemical, immunological and pathological behavior also constituted a very homogenous group when examined for the ability of their polynucleotide sequences to interfere with the reassociations of radiolabelled deoxyribonucleic acid (DNA) fragments with



homologous single stranded DNA on nitrocellulose filters or in DNA agar (Hoyer et al 1968b). It was observed that the genus was comprised of a group of organisms with very extensive polynucleotide homologies (Hoyer et al 1968b). The guanine and cytosine contents in the DNA of Br. abortus, Br. melitensis, Br. suis, Br. neotomae and Br. ovis were similar although Br. ovis, like Br. neotomae, differed from the other Brucella species in certain respects, particularly in oxidative metabolic pattern (Hoyer et al 1968b).

There were indications that Br. ovis did not contain all the polynucleotide sequences shared by the DNA of other Brucella species. However, the finding that a large proportion of Br. ovis polynucleotides were similar to those of other Brucella species supported the inclusion of Br. ovis in the genus (Hoyer et al 1968a).

The organism isolated by McFarlane et al (1952) was identified as Br. ovis by Buddle and Boyes (1953). These authors regarded the organism isolated by Simmons and Hall (1953) as a stabilized mutant of Br. melitensis. Buddle (1956) later proposed that the organism of Simmons and Hall be designated Br. ovis, as it and other strains from New Zealand, Queensland, New South Wales, Victoria and South Australia all shared identical agglutinating antigens. Br. ovis also shared antigens with rough strains of Br. abortus and Br. melitensis but did not share the smooth "A" and "M" antigens (Buddle 1956). The organism had

sufficient characters in common with the genus Brucella to warrant its inclusion in the genus, and also sufficient differences from other species to warrant separate species designation (Watt 1972). However, some workers were not convinced that this organism belonged to the genus Brucella (Lawrence 1961). Meyer and Cameron (1956) considered that the organism resembled more closely a Neisseria in its metabolic activity and Kennedy et al (1956) claimed it shared more characteristics in common with Haemophilus. Brucella organisms have also been grouped with several other genera, including Alkaligenes, Francisella and Bordetella (Hoyer et al 1968b).

### c. Transmission

The ram's penis may be subjected to considerable trauma during a mating season with possible abrasion of the epithelial covering of the glans penis. Frequent exposure of the abraded glans to Brucella infection could perhaps facilitate the spread of disease (Miller and Moule 1954).

Hartley et al (1955) reported that clinical lesions developed and Brucella organisms were found in previously noninfected ram semen following mating to ewes served earlier by infected rams. These observations were supported by the findings of Buddle (1955). However infection could not be produced in rams that were mated to ewes with clinical

infection (Buddle 1955). There was no apparent transmission of the organism from contaminated pasture to rams (Hartley et al 1955).

Field observations suggested that the spread of infection in rams occurred readily during the mating season. However, mating was not essential for spread of the disease because epidemiological data indicated that rams that have never been used for service became infected. In fact, spread of infection between rams obviously occurred in absence of ewes. The common practice of rams mounting other rams with subsequent ejaculation of semen could facilitate dissemination of infection from infected rams that may then be transmitted to in-contact rams through the nasal, conjunctival, buccal or rectal mucosae (Buddle 1955).

Ram lambs born from experimentally infected ewes with grossly diseased placentae, failed to develop active infection when observed over a period of nine months following weaning (Buddle 1955). However, in breeding flocks the disease seemed to spread rapidly when infection was introduced into a flock of young clean rams (Snowdon 1958). Although infection of young rams whilst suckling their mothers could not be entirely ruled out, it did not account for the high incidence of the disease in some ram flocks (Snowdon 1958).

Field observations indicated that rams were readily susceptible to infection following close contact with ewes

at copulation and that some rams could excrete the Brucella organisms for at least two years (Hartley 1955). Snowdon (1958), however, disagreed with this view.

Noninfected two-tooth rams secreted Brucella organisms in the semen, following contact over an eight month period with infected rams. It should be noted that there was ample opportunity for infection to occur through the nasal, conjunctival, buccal or rectal mucosa (Buddle 1955).

It has been difficult to produce epididymitis in rams by the experimental transmission of Brucella organisms (Simmons and Hall 1953). Rams have been infected experimentally by the intravenous, subcutaneous and intratesticular routes as well as per os and by the application of infectious materials to mucous membranes of the conjunctiva and prepuce (Buddle and Boyes 1953; Hartley et al 1955; Buddle 1955). The difficulty in experimentally infecting rams was attested to by the finding that relatively small number of animals shed Br. ovis in their semen even though most of the rams received one conjunctival and two subsequent intravenous exposures (Brown et al 1973).

Laws et al (1972) placed 0.25 ml of semen, collected from infected rams by electroejaculation, onto the urethral process, glans and body of the protruded penis of susceptible rams and infection resulted in 17 of 25 challenged rams. In these rams complement fixation (CF) titers developed between two to seven weeks. Br. ovis was first

recovered from semen between weeks 5 to 14 whereas lesions were palpated for the first time between weeks 7 to 12.

Brown et al (1973) also inoculated rams with 0.5 ml of the standardized suspension of Br. ovis strain 3572 via the conjunctival sac of each eye. Rams not shedding Br. ovis in their semen were reexposed intravenously with  $12 \times 10^9$  colony-forming units at 13 and 27 weeks after initial exposure. Serologic responses occurred in all experimentally exposed rams and Br. ovis was isolated from the semen of 28% of the rams. In any case, the semen was the most infective secretion eliminated by rams even though infection may also be excreted in the urine and feces (Buddle 1955).

#### d. Pathology

Br. ovis produced genital disease in rams after intravenous or intrapreputial administration (McFarlane et al 1952). There were neither gross nor microscopic changes in organs other than the genitalia that could be related to the effects of experimental infection. This was in spite of the fact that many nongenital tissues contained the brucellae and some organs "fairly teemed with them." The absence of response to infection in those parenchymatous organs in which reactive reticuloendothelial elements were more easily appreciated, such as liver and kidney, was remarkable (Biberstein et al 1964).

The course of infection, initiated by inoculation of an extragenital mucous surface, was bacteremia that advanced extremely slowly and evoked no observable clinical or pathological response in the host until localization occurred in the reproductive tract during the second month. Localization appeared to be selective in that some tissues were colonized with significantly greater frequency than others. Among these were epididymis, seminal vesicles and ampulae; these were also the only areas where primary lesions were identified.

Why other glandular structures, genital and extragenital, were only transiently and much less frequently infected than the tail of the epididymis and the seminal vesicles was one of the several unanswered questions concerning the natural history of ovine brucellosis. Even more puzzling was the selective tissue pathogenicity shown by the organism (Biberstein et al 1964). It has been suggested that the circulatory arrangement in the tail of the epididymis was responsible (Gamcik and Bogdan 1958).

#### 1) Gross Findings

There were a variety of palpable lesions of the scrotal contents and in complicated epididymitis, there was associated orchitis and testicular atrophy (Miller and Moule 1954). Acute epididymitis was more easily observed in

experimental rams (Simmons and Hall 1953; Kennedy et al 1956; Biberstein et al 1964) and in experimental laboratory animals such as the gerbil (Cuba-Caparo and Myers 1973).

In the acute phase, the entire epididymis on the affected side appeared warm, swollen and doughy. On necropsy there was inflammatory edema in the loose scrotal fascia, fibrin-rich exudate in the cavity of the tunica vaginalis, serosal hyperemia, early granulation tissue formation and edema of the epididymis and testes. Sometimes the acute reaction was less severe, consisting only of a localized edematous swelling of the epididymis and the presence of fluid in the cavity of the tunica vaginalis (Jebson et al 1955).

A chronic phase, that most consistently involved the tail of the epididymis, followed subsidence of the acute reaction. It has been noted that involvement of the head or body of the epididymis was always preceded by this caudal lesion (Biberstein et al 1964).

The palpable lesions usually consisted of an enlarged firm tail of the epididymis with or without coexisting thickening of the tunica vaginalis and secondarily induced changes in the testicle and proximal portions of the epididymis (Jebson et al 1955; Kennedy et al 1956). Enlargement of the epididymal tail varied from barely perceptible to a four- to five-fold increase in size. In some affected rams, the tail of the epididymis may be equal in

size to the associated testicle (Miller and Moule 1954; Shott and Young 1971).

Enlargement of the epididymis may be unilateral or bilateral (Simmons and Hall 1953; Miller and Moule 1954; Jebson 1955; Snowdon 1958; Galloway 1966; Laws 1972) and was usually confined to the tail, although on occasion it involved the body or the head (Jebson 1955). Occasionally the epididymal enlargement involved the entire organ. The enlargement of the proximal portions was not, however, characterized by fibrosis but rather by wide dilatation of the tubules with accumulation of intratubular fluid (Kennedy et al 1956). The enlargement usually remained, following the acute phase but it more commonly occurred without any palpable evidence of the acute reaction (Jebson et al 1955). The affected portion of the gland was firm, even hard. The normal globular contour became irregular. Palpable distinction from the distal pole of the testicle was diminished (Miller and Moule 1954; McGowan and Schultz 1956). In some chronic cases, the whole of the epididymal tail may become sclerosed.

Enlarged cauda epididymides cut with increased resistance due to a more or less uniform increase in dense white connective tissue and thickening of the overlying albuginea. In some cases within this dense white connective tissue, there were solitary or multiple, variable-sized, abscess-like spermatoceles (Gunn 1942; Miller and Moule 1954; Jebson



et al 1955; Kennedy et al 1956; Watt 1970). Spermatoceles, though commonly seen in the tail, may affect any part of the organ, usually unilateral but may be bilateral (Gunn 1942). The condition appeared to commence as a tiny spermatocele by the breaking down and coalescence of a number of epididymal tubules. These spermatoceles were filled with creamy-tan mixture of sperm and other cell debris, and later became inspissated and caseous. The contents may be held under considerable pressure and thus would flow freely when the wall of the affected epididymis was incised. In cases in which a spermatocele ruptured into the cavity of the tunica vaginalis, the cavity became obliterated by adhesions between visceral and parietal layers (Jebson et al 1955; Kennedy et al 1956). In all but the mildest cases, varying degrees of fibrous adhesions existed between the tail of the epididymis and the parietal tunica vaginalis and the distal pole of the testicle, making distinction between them difficult (Miller and Moule 1954; Jebson et al 1955; Kennedy et al 1956).

In cases of epididymitis without a spermatocele, a thickening of the distal end of the parietal layer of the tunica vaginalis first developed. Subsequently, fibrous adhesions became palpable between the two layers of the tunica at the distal end of the sinus epididymis. In a few months, the tail of the affected epididymis resembled an elongated peg (about 5 cm long) but the diameter

remained essentially normal. At necropsy, the parietal layer of the tunica vaginalis at the distal end of the scrotum may vary in thickness up to 7.5 mm. It was white, fibrous and in some cases firmly attached to the visceral layer of the tunica over the epididymis. In other cases, the parietal layer of the tunica was tightly contracted around, but not attached to, the epididymal tail at the point of its attachment to the testicle. This precluded free movement of the testicle and epididymis within the cavity of the tunica vaginalis. In cases where there was not a firm attachment between the two layers of the tunica, discrete fibrous lesions about 1-2 mm in diameter may be observed on both surfaces of the tunica. Some of these extended to the testicle (Miller and Moule 1954). A common finding was fibrosis of the cleft situated between the ventral pole of the testicle and the tail of the epididymis (Jebson et al 1955). Rarely sperm granulomas with fibrosis were found in the head of the epididymis (Kennedy et al 1956).

## 2) Histopathology

Following experimental intratesticular, intraepididymal (Simmons and Hall 1953; Kennedy et al 1956) or intraocular (Biberstein et al 1964) inoculation of rams, the earliest epididymal lesions were confined to the cauda epididymis.

These consisted of perivascular edema and loose accumulations of lymphocytes particularly adjacent to the smaller arterioles, venules and capillaries of the interstitial tissue (Kennedy et al 1956; Shott and Young 1971). They also affected the capillaries coursing between the basal layers of the tubular epithelium and the closely opposed peritubular musculature, and the vessels of the tunica albuginea and muscular coat of the vas deferens.

Focal changes in the epithelium also may occur. These initially consisted of adjacent edematous disorganization of the epithelium and infiltration of lymphocytes and occasional plasma cells. Subsequently, there were focal hyperplasia and metaplasia in which the cytoplasmic outline was indistinct and the accumulated nuclei were smaller, horizontally disposed and diffusely hyperchromatic. At this stage, brucellae were recognizable only with difficulty in Giemsa-stained sections and then especially in the interstitial tissue.

In later stages, stromal edema became more diffuse and cellular infiltration more extensive. Plasma cells and neutrophils were added to the cellular exudate and the capillary endothelium became hyperplastic. The tubal epithelium became more diffusely infiltrated with inflammatory cells that also accumulated in the lumen.

Hydropic degeneration and lysis of epithelial cells in edematous foci was followed by reorganization of the epithelium around them and with formation of excessive

intraepithelial cysts (Shott and Young 1971). Tissue and cellular debris persisted in some cysts. The overlying portions of the epithelium were usually transitional in type but occasionally only a thin cytoplasmic membrane remained.

The unique and characteristic changes produced by this infection--hyperplasia and metaplasia of the epithelium lining the epididymis--were often segmental and usually began in the distal portion of the tail of the epididymis. The hyperplastic epithelium led to folding and finally formation of characteristic intraepithelial cysts (Biberstein et al 1964). The suggestion was made that some of these intraepithelial cysts were of an inclusion type and were secondary to focal epithelial hyperplasia and papillomatous formation (Kennedy et al 1956).

Although the precise mechanism was not obvious, it was apparent that these epithelial changes led to extravasation of sperm and subsequent severe gross lesions. Due to interstitial edema and alterations in the epithelium, a narrowing or obstruction of the actual lumen occurred, resulting in proximal sperm stasis. In advanced lesions, progressive fibrosis and cicatrization developed in the previously edematous interstitial tissue (Simmons and Hall 1953; Kennedy et al 1956; Shott and Young 1971). Intraepithelial accumulations of neutrophils and destruction of epithelium progressed from multiple foci to involve the entire tubular

circumference. This resulted in a wall of neutrophils, separating impacted sperm from the surrounding stroma.

Two types of tubulo-interstitial spermatic granulomas (Kennedy et al 1956; Watt 1970; Shott and Young 1971) apparently occurred. In the second type, granulomatous reaction replaced the intratubular neutrophilic reaction described above, and in the more proximal portions of the tubules sperm stasis and subsequent extravasation resulted in granuloma formation. In tubules in which focal extravasations occurred, the remaining epithelium occasionally underwent squamous metaplasia. Brucellae were not demonstrable with certainty in fully developed granulomas. Surrounding the thin peripheral rim of epithelioid and giant cells, there was active fibrosis. Adhesions resulted in those cases in which the sperm entered the cavity of the tunica vaginalis (Kennedy et al 1956).

Spermatoceles and spermatic granulomas were microscopically similar. The affected part of the epididymis was enlarged and contained a collection of pale green or pale or dark yellow milky or caseated material that was surrounded by a fibrous tissue capsule. Histologically, there was duct dilatation, degeneration of epithelium, spermiostasis and degeneration. Extravasation of spermatozoa into the interstitium resulted in a granulomatous reaction (Jubb and Kennedy 1970). In Merino rams, spermatoceles or spermatic granulomas were a characteristic feature

of chronic epididymitis especially in the tail (Gunn 1942; Miller and Moule 1954). The pathology, pathogenesis, etiology and the role of spermatic granuloma in infertility--aspermia and sterility--have been discussed (Glassy and Mostofi 1956). In the absence of sperm leakage, the changes were mild and frequently inapparent. However, spermatozoa free in the interstitial tissue provoke an acute and chronic inflammatory reaction. A prominent feature of the chronic lesion, therefore, was diffuse fibrosis, tubular obstruction and adhesions between layers of the tunica vaginalis (Biberstein et al 1964).

Atypical testicular lesions, i.e., lesions not in the epididymal tail, have at times been assumed to be due to causes other than the specific epididymitis (Biberstein and McGowan 1958). In any case the only lesion that could be considered at all specific was the epithelial reaction in the tail of the epididymis. The connective tissue reaction in the epididymis, seminal vesicles and ampullae were less distinctive, while the gross changes in epididymis and testicle were the result of sperm leakage (Biberstein et al 1964). It has been emphasized that the macroscopic lesions represented the chronic stage of a productive inflammation induced initially by the brucellae and subsequently by response to sperm extravasation (Kennedy et al 1956).

Findings in rams with natural cases of epididymitis were consistent with those observed in experimental ram and

laboratory animal infections (Cuba-Caparo and Myers 1973). In some rams, in the subsiding acute reaction, Brucella-like organisms were demonstrable in Giemsa-stained sections, both free and within neutrophils in the lumina of the epididymal tubules (Jebson et al 1955).

#### e. Diagnosis

To date, ovine epididymitis has been diagnosed on the basis of clinical features, pathological and serological findings as well as qualitative, quantitative and bacteriological examination of semen.

##### 1) Physical Examination

Palpable abnormality of the scrotal contents was clinically suggestive of ram epididymitis (Miller and Moule 1954; McGowan and Schultz 1956) even though it did not allow detection of all actively infected rams (Hartley et al 1955). Palpation was facilitated if both testicles and epididymides were grasped from the rear of the standing animal and the two glands palpated simultaneously, affording an immediate means of comparison and detection of asymmetry of size, shape and consistency. Affected tissue was firm to hard on palpation, depending upon duration of the lesion and the extent of fibrosis (Gunn 1942; McGowan and Shultz 1956; Galloway 1966; Van Tonder 1977). Each side was then examined

separately by grasping the neck of the scrotum and stretching the skin over the organs while palpating with the other hand; any firm enlargements of the epididymis were then noted (Galloway 1966).

## 2) Immunodiagnosis (Serodiagnosis)

In view of the impracticability and unreliable nature of semen culture and the inadequacy of physical examination above, serological method emerged as the most dependable single aid in detecting infections in individuals of a flock. The reliability of the serological approach has been recorded by a number of workers (Clapp et al 1955; Biberstein and McGowan 1958; Biberstein et al 1964; Laws et al 1972). Serology detected asymptomatic shedders, and only in rare instances did seronegative animals yield brucellae on culture (Clapp et al 1955). Several workers, using the agglutination reaction as a research tool, reported the antigen to be unreliable due to early tendencies toward non-specific and spontaneous agglutination (Meyer and Cameron 1956; Biberstein and McGowan 1958). Biberstein and McGowan (1958) stated that the use of intradermal test was unlikely to gain much favor with breeders and veterinarians, owing to the necessity of handling animals twice and other cumbersome features.



Clapp et al (1955) developed a complement-fixation procedure in which the antigen consisted of a whole-cell suspension of a recently isolated strain. To overcome the strong anticomplementary action of this preparation, the cells were absorbed with complement by suspending them in a 15% guinea pig serum-in-saline solution. Following a 30-minute incubation period at 37C, the mixture was activated and phenolized. The test appeared to achieve good results and correlated well with bacteriological findings in cases where lesions were minimal or absent.

A fact emerging from the Australian data was the large discrepancy between incidence of gross lesions and numbers of seroreactors. In one group of 61 rams with palpable lesions only 45 were serologically positive. This implied that epididymitis in the remaining 16 was due to causes other than Br. ovis infection. Unless special conditions prevailed in these flocks, making the rams particularly liable to trauma or other infections, the question of infected individuals being missed by this test must be considered (Biberstein and McGowan 1958).

Biberstein and McGowan (1958) developed a similar CF procedure, employing as the antigen the supernatant of a sonic-vibrated bacterial suspension. This antigen lacked the anticomplementary properties mentioned above that required use of guinea pig serum or purchased equipment.

A comparison of the sensitivity of whole-cell and soluble antigen indicated that where both tests were positive, higher titers were observed in the majority of samples when the soluble antigen was used. This CF procedure revealed all palpably abnormal rams to be positive or suspicious.

The height of the titer may give no clue to the presence of lesions, their severity or the shedder state of the ram. A ram from which the organism was recovered in prodigious numbers may carry a titer of 1:10, while titers of 1:20 to 1:40 have been observed in rams from which no organisms were isolated. Nonlesion rams frequently carried higher titers than clinically diseased rams. From a diagnostic viewpoint, therefore, no valid reason for titrating positive sera can be advanced (Biberstein and McGowan 1958).

Keogh et al (1958) also reported that rams became clinically, culturally and serologically positive for Br. ovis infection three months after mating but were negative on subsequent examination one year later.

Biberstein et al (1964) reported that the serological response to ram epididymitis infection in terms of CF antibody appeared as early as the second week while uniform positive tests were obtained from the fourth week on. Titers rapidly rose to a maximum beyond the highest dilution tested (1:160) and remained there until the seventh month of infection, when a gradual decline set in. Laws et al (1972) had also used the CF technique for diagnosing

experimental Br. ovis infection in rams. CF tests were done weekly on freshly collected serum to a maximum serum dilution of 1/40. The titers of samples giving reactions above this dilution were determined from samples stored at -20 C.

More recently, Hicks et al (1978) called attention to the possibility of inaccuracy associated with CF testing for ovine brucellosis. In screening rams for export, they found a positive titer in a ram tested prior to export that was negative at a subsequent test.

Myers and Siniuk (1970) described a simple gel-diffusion technique for diagnosing epididymitis caused by Br. ovis. The authors used a simple microslide adaptation of the agar-gel diffusion method and compared it to existing CF procedures; the results were similar. Agar-gel precipitin lines and positive CF reactions were demonstrated with the first post-inoculation (PI) bleeding at 12 days in all experimentally infected rams. All 14 sheep gave positive reactions to both tests on serum samples obtained weekly up to the 124th day PI. Blood samples taken at monthly intervals thereafter until the 335th day PI also demonstrated agreement between the two procedures. If these results could be confirmed by field use, it should extend the possibility of testing large numbers of sheep to areas where laboratory facilities did not exist for carrying out the CF test.

The gel diffusion test with saline extract of Br. ovis was found to be as sensitive as the CF procedure for diagnosing ram epididymitis (Myers et al 1972). Carmichael (1976) noted that in agglutination, complement-fixation and immunodiffusion tests, Br. canis cross-reacted extensively with Br. ovis.

### 3) Examination of Semen

As semen is a highly specialized excretory product containing millions of specialized and sensitive sperm cells, it is essential that all tests to determine its viability should be carried out in the shortest possible period of time and under the most favorable circumstances.

#### (i) Semen Collection

Semen, collected by the artificial vagina (Van Tonder 1977) or by natural ejaculation (Hulet 1977), was generally of better quality when compared to semen obtained by electrical stimulation. The artificial vagina, however, was limited to rams adapted to its use; this rendered it impractical as a routine method. In addition, because of time and difficulty involved in collecting naturally ejaculated specimens, use of the electroejaculator, bipolar rectal probe (Galloway 1966) or transistorized electroejaculator (Cameron and Lauerman 1976) was common.

A simple squeeze crate was effective for restraining rams (Hulet 1977). Rams may also be restrained in a Wild's footrot crush modified so that once the ram walked in, the crush can be swung to a horizontal position, placing the ram in lateral recumbency with the hind legs fixed and at a height of about two feet off the ground (Galloway 1966). Thirdly, ram testing tables could be used but these obviously confined the activities to the consulting room or laboratory and were also more labor intensive and time-consuming when a number of animals had to be tested. Rams could be conveniently laid on any solid floor and kept down flat on the left side by three to four assistants holding the head, hind and front legs, respectively. The front and hind legs were kept together in such a way that the animal was not stretched. A fourth assistant was seated against the back of the ram opposite the loins grasping the upper loin flap and pressing the ram down (Van Tonder 1977).

To prevent cross contamination, operators wore new disposable gloves for each ram and the rectal probe was cleaned with 20 V/V solution of Savlon.<sup>b</sup> Different sets of equipment were used for control and infected animals. The penis was extruded and cleaned with distilled water and sterile cotton wool. A piece of ordinary bandage was folded

---

<sup>b</sup>Savlon Antiseptic Liquid - Imperial Chemical Industries of Australia and New Zealand, Melbourne, Victoria.

in a tape 1 to 2 cm wide and placed as a single loop around the collum glandis of the penis. The person collecting the semen pulled the tape tight around the penis with the two ends held close together between the palm and last three fingers of the left hand. By pressing the two sides of the tape together with the thumb and forefinger of the same hand immediately below the ventral aspect of the penis, opposite the urethra, a firm grip on the tape and penis was obtained. The penis could therefore be directed and semen flow controlled by pressure with the thumb and forefinger. Immediately before ejaculation occurred only the tip of the glans penis and urethral process was introduced into the container and the pressure on the tape and urethral process released. The container was kept at the correct temperature before and after collection and the viability examinations were carried out as soon as possible after collection (Van Tonder 1977). The lubricated rigid electrode was inserted into the rectum for a distance of 12 to 15 cm and pressure on the handle exerted in such a way as to press the inserted end firmly against the ventral wall of the rectum and indirectly on the ampullae. When the collector was ready the handle of the ejaculator was turned, starting slowly and gradually working up to a climax within the extent of four to six turns. The process was then stopped for a few seconds while the electrode was moved around in the rectum. During this pause the collector quickly

positioned and opened the container and inserted the urethral process. When the electrode was fixed at the correct site again, a short sharp turn of the handle was given. This was usually followed by spontaneous ejaculation.

For collecting semen either graduated tubes or wide-mouth McCartney bottles could be used; they are transferred immediately after collection to a portable car ice chest kept approximately at body temperature.

(ii) Visual Examination

This was done immediately after collection and volume, color, density and motility were noted.

Motility can easily be seen by close examination and by tilting the container so as to cause the semen to run down the sides in a thin film. Special attention was given to abnormalities in appearance such as blood and urine contamination and the presence of granules or flakes of pus.

The density of the semen sample is used to estimate the number of sperm in the ejaculate since counting of the cells was a laborious procedure and also interfered with the other observations. Gunn (1942) adopted a scale, ranging from very thick creamy to less than cloudy, to estimate the approximate number of spermatozoa present.

(iii) Microscopic Examination

Motility

Examination for motility is carried out as soon as possible after collection. Care should be taken to prevent sudden exposure of the semen to lower temperatures, especially when placed on a slide. Motility examination consists of two steps: first, determination of wave or mass motility and second, individual movement of sperm cells. A drop of semen, placed directly on a prewarmed slide, is examined at 100X magnification for wave motion and at 400X magnification for motility (Galloway 1966).

Wave motility was observed as dark crested waves moving swiftly in all directions across the field. According to the intensity of movement and crispness of the waves, the motility could be rated on a scale from 0 to 5. Semen of high quality should have a motility rating of five and should have crisp, dark crested waves with rapid movement and change in direction. Such a specimen would at least have a creamy consistency, density and color. Semen with a wave motility of four and upwards was generally considered as satisfactory.

Percentage Live Sperm

For the nigrosin-eosin staining method (Blom 1950), a drop of 5% eosin and two drops of 10% nigrosin are placed side by side on a warmed glass slide. A drop of semen is



placed directly on to the eosin and gently mixed by means of a glass rod and the semen-eosin mixture mixed with the nigrosin. The semen-stain mixture was stirred for a few seconds and a small drop streaked out on a clean glass slide for viewing. Alternatively, the drops of eosin and nigrosin were mixed beforehand and the drop of semen was placed directly onto this mixture and stirred for approximately five seconds before smears were prepared. Actual counts of stained (dead) and unstained (live) sperm cells were made and expressed on a percentage basis. A percentage of less than 20% nonviable spermatozoa was satisfactory.

### Morphology

Morphological examination of individual sperm cells could be accomplished with a vital stain such as opal blue eosin or nigrosin-eosin (Hulet 1977). Special staining techniques could also be employed such as Giemsa or eosin and carbol fuchsin method. Alternatively, semen smears were prepared immediately following collection and stained 48 hours later with carbol fuchsin-eosin and counterstained with Loeffler's methylene blue (Williams' stain) as described by Lagerloff (1936) for morphological examination of bull spermatozoa (Cameron and Lauerman 1976).

The most common type of abnormality observed was secondary involving the tail of the sperm cell and usually occurred after the cell was formed. Amongst these, coiled

and double bent tails, loose heads (i.e. heads without tails) and immature forms with proximal or distal protoplasmic droplets were found (Van Tonder 1977; Galloway 1966).

With regards to semen examination, mean total sperm output, although subject to variation due to the method of collection, was reduced in rams infected with Br. ovis. Infection also resulted in poor motility and a high percentage of loose sperm heads and abnormal tails. Pathological sperm heads were not a common feature of the disease. However, a great deal of variation between as well as within rams was the main feature of the infected group, depending on the stage of the disease and the pathological changes taking place in the epididymis at the time of the semen examination. Rams consistently shedding brucellae in the semen produced semen samples with consistently poor sperm motility (Cameron and Lauerman 1976). Orgebin-Crist (1969) considered the increase of potential for motility to be one of the critical changes to occur in sperm as they passed through the epididymis. The presence of Br. ovis infection in the epididymis would affect this normal epididymal function.

Blom (1950) classified loose normal heads and bent tails as "secondary abnormalities" and considered they were a result of some "unphysiologic condition" affecting the sperm after they have left the spermatogenic epithelium, possibly during their stay in the epididymis. Rao (1971)

in a study of sperm changes in the bovine epididymis found the increase in abnormal sperm tails to be unrelated to the incidence of abnormal heads and suggested that changes in sperm tail morphology were probably brought about by alterations in the epididymal environment. Other workers also considered bent and coiled tails to be formed in the lower part of the tail of the epididymis (Swanson and Boyd 1962).

The pathogenesis of Br. ovis infection in rams has been described as a progression of pathological changes resulting in the formation of spermatic granulomas, majority of cases in the tail of the epididymis (Jubb and Kennedy 1970). In a study by Cameron and Lauerman (1976), it would appear that these changes resulted in an abnormal environment in the epididymis, producing poor sperm motility and an increase in the incidence of loose heads, bent tails and some cases, coiled tails. The incidence of these abnormalities was related to the frequency of shedding of Br. ovis in the semen and subsequently to the degree of pathological changes found in the epididymis. Thus Br. ovis infection in rams was most likely to result in poor semen quality.

#### (iv) Bacteriology

Bacteriological examinations consisted of culturing semen and, when available, testicles, as well as examination

of stained semen smears (Biberstein and McGowan 1958; Keogh et al 1958; Galloway 1966; Myers and Siniuk 1970).

Semen was collected by electroejaculation. Bovine blood agar (BBA) plates were streaked with loopfuls of each semen sample. The plates were placed in a jar and incubated at 37C under 15% CO<sub>2</sub> for 48 hours before the first examination. Plates were inspected daily thereafter for two weeks unless Br. ovis had been isolated earlier or the plates were overgrown with contaminants. Colonies resembling Br. ovis were transferred to BBA slants from which final identification was made on the basis of cultural characteristics, morphology and staining reactions. At least three attempts at isolation were made in the case of each ram, samplings being spaced at weekly intervals or more. When testicles were available the areas cultured included lesions (where present) and the tail of the epididymis whether it was diseased or not.

Smears of fresh semen were stained by the modified acid-fast method or with Giemsa and examined for the presence of intracellular and extracellular modified acid-fast coccobacilli.

Under prevailing field conditions, contamination by more rapidly growing bacteria was common, and failure to recover brucellae from rams with typical lesions and a positive blood test was often due to this circumstance. Some contaminants may be present in collected semen. These may include members

of the genera Corynebacterium and Micrococcus. In view of these findings, negative cultures were not adequate evidence of absence of infection (Biberstein and McGowan 1958).

A question of some interest was whether nonlesion reactor and shedder rams were going through an incubation period and would ultimately develop grossly detectable lesions or whether they may remain silent shedders indefinitely (Biberstein and McGowan 1958).

(v) Abnormalities of Semen

Long before epididymitis could be determined clinically, recognizable seminal changes occurred. Changes included separation of a proportion of sperm heads from their tails and the appearance of numerous multinucleated giant cells. Clinically the condition becomes progressively worse over a period of two or more years, seminal degeneration being present throughout but becoming increasingly worse. Eventually unilateral cases may terminate with the semen returning to normal or almost normal (Gunn 1942). Abscesses with adhesions within the tunica vaginalis cavity often simulated cases of epididymitis in their clinical signs. Miller and Moule (1954) reported that seminal degeneration always heralded development of palpable lesions, and in long standing cases, clear seminal fluid obtained from electrical stimulation contained no sperm.

Jebson et al (1955) noted that in semen samples classified as good, the volume ranged from 0.2 to 3.0 ml and had a creamy turbid appearance. Wet smear preparations had a high proportion of actively motile spermatozoa, abnormal forms were infrequent, and inflammatory cells, if present at all, were scanty. This was in contrast to semen from infected rams in which the appearance of samples varied with the concentration of spermatozoa and content of inflammatory cells. In some, the sperm concentration was so low that the watery ejaculate was barely clouded by their presence. In others, mucoid clots were evident. Variations in sperm quality were often quite independent of their concentration. The main abnormalities were a high proportion of free sperm heads and tails, followed by spermatozoa with returned tails and sometimes with coiled tails. When inflammatory cells were numerous, sperm debris was engulfed or broken down by them. In most rams classified as active carriers of intracellular Brucella organisms were regularly identified. Brucellae were never found in smears or in cultures of semen when inflammatory cells were not present.

Jebson et al (1954) had previously described the excretion of Brucella organisms in experimentally infected rams prior to development of palpable lesions. All rams consistently had poor semen during the period of observation.

McGowan and Devine (1960) made a detailed study of the semen of 29 naturally occurring cases of brucella

epididymitis. The study, based on percentage of live sperm, motility, sperm count and morphology, demonstrated that the semen was definitely inferior in 50% of the rams, and of average quality or better in only 25%. The semen from each ram contained brucellae. In another study using six of the above infected rams, the fertility was found to be markedly lowered.

In conclusion, rams suffering from unilateral or bilateral testicular atrophy, orchitis and/or epididymitis had poor breeding records (Miller and Moule 1954). Epididymitis appears to be the most prevalent cause of wastage and infertility amongst rams (Hulet 1977). It has been suggested that in a ram in which fertility was reduced by hot summer temperatures, concomitant epididymitis could play an additive role in rendering the ram nearly sterile (McGowan and Schultz 1956). Examination of seminal fluids and semen quality should be an integral part of establishing a diagnosis of epididymitis.

### 3) Actinobacillus Epididymitis

Ram epididymitis due to Actinobacillus seminis assumed prominence since institution of eradication programs for Br. ovis infection in sheep.

Baynes and Simmons (1960) in Australia described three natural cases of epididymitis caused by a bacterium that was

placed in the genus Actinobacillus. This organism, isolated from semen, was capable of producing epididymitis when injected into the testicles and epididymis of other rams. It was designated A. seminis.

Other workers have isolated a microorganism, from semen of rams with epididymal infection that was identical morphologically and culturally to A. seminis in the U.S.A., South Africa and Australia (Livingston and Hardy 1964; Simmons et al 1966; Van Tonder and Bolton 1968).

Laws et al (1969) recovered A. lignieresii from purulent epididymo-orchitis in a Border Leicester ram.

Other Actinobacillus-like organisms have been recovered from lesions of the genitalia of rams. Dodd and Hartley (1955) described an unidentified gram-negative bipolar, pleomorphic bacillus associated with suppurative epididymitis in young unshorn rams. The infection was characterized by gross enlargement of the affected side of the scrotum and by a systemic reaction with sudden onset and death within a week. Examination revealed a primary abscess in the epididymis and subjacent tunics in which there was profuse formation of a thick yellow-green pus.

Claxton and Everett (1966) have also reported the recovery of a gram-negative, pleomorphic organism resembling Histophilus ovis from the semen and ampullae of a ram with unilateral periorchitis and peri-epididymitis. Although the bacteriological characteristics of H. ovis has been



reported (Claxton and Everett, 1966; Rahaley and White 1977), its exact taxonomic position is uncertain. It appears to be related to A. seminis (Rahaley 1978).

The extent and significance of actinobacillosis in sheep apart from being a diagnostic and control problem for brucellosis, is unknown (Baynes and Simmons 1960; Livingston and Hardy 1964; Van Tonder 1973; Jensen 1974).

#### a. Transmission

Little is known of the methods of spread of A. seminis within and between flocks under natural conditions (Baynes and Simmons 1960; Livingston and Hardy 1964; Van Tonder 1973). Experimentally acute epididymitis followed by chronicity and shedding of A. seminis in the semen has resulted from intraepididymal and intratesticular inoculation (Baynes and Simmons 1960). Like Brucella infection in rams, transmission of actinobacillary epididymitis had been accomplished using semen (collected from infected rams within 15 minutes) or broth culture of A. seminis (Baynes and Simmons, 1960; Livingston and Hardy, 1964; Watt et al 1970).

#### b. Gross Pathology

Enlargement of the tail of the epididymis (Baynes and Simmons 1960, 1968; Worthington and Bosman, 1968) was the

characteristic feature of the natural as well as experimental infection. Enlargement occurred sooner in rams infected intraepididymally than in those infected intratesticularly (Van Tonder and Bolton 1968). The acute phase subsided about 14 days after inoculation; the scrotum reduced in size with apparent atrophy of the testes and hardening of the epididymis (Baynes and Simmons 1968). Fibrous adhesions between the tunica albuginea and the cauda epididymis also occurred. Such adhesions might extend to the body of the epididymis.

Claxton and Everett (1966) described a case of ram epididymitis caused by Histophilus ovis and noted that the visceral and parietal tunics of the testes and epididymis were adherent and fibrosed, especially in the region of the ventral pole of the testes and the tail of the epididymis.

#### c. Histopathology

The microscopic appearance was similar to that of Brucella-induced epididymitis (Baynes and Simmons 1960). Spermatic granulomas were also encountered (Worthington and Bosman 1968; Claxton et al 1966) as well as marked hyperplasia with cyst formation of the epithelium of the epididymal duct.

#### d. Examination of Semen

Semen smears collected when testicles were grossly swollen had numerous leukocytes but no organisms could be seen even when stained by the modified acid-fast stain. However, semen smears collected when the testicular swelling had regressed often revealed numerous leukocytes and nonacid-fast bacilli. Occasional organisms, retaining the fuchsin might be seen in semen smears especially when the organisms were intracellular. In semen films, the bacilli occurred in chains or in palisade formation. These bacilli were gram-negative, occurring both inside leukocytes and extracellularly (Baynes and Simmons 1960). Semen collected prior to necropsy of infected rams was viscid and creamy and frequently contained sperms with detached heads and tails.

Semen, collected in sterile test tubes by means of an electroejaculator, was streaked on 10% sheep blood agar (SBA) plates for primary isolation. The inoculated plates were incubated at 37C aerobically and in 10% carbon dioxide (CO<sub>2</sub>). Selected colonies were inoculated into brain heart infusion broth containing 10% unheated calf serum (Livingston and Hardy 1964). Small pin-point hemolytic colonies were found on 10% SBA plates after 24 hours incubation under both conditions, but developed more rapidly under CO<sub>2</sub>. The colonies were round, convex, with an entire border, and

grayish-white. After three or four days incubation, the larger colonies were three to four mm in diameter and umbonate (Livingston and Hardy 1964).

The organisms were gram-negative, pleomorphic rods, varying from coccobacilli to long rods (1-6u) and 1u in width (Baynes and Simmons 1960; Livingston and Hardy 1964).

Cultures were nonacid-fast when subjected to the modified Ziehl-Neelson staining method. The organisms were nonmotile in serum broth incubated at 22C or 37C. The organism was nonsporing and required lowered oxygen tension and enriched serum for optimal growth.

Organisms could be recovered from semen samples collected from rams eight days post inoculation. All subsequent weekly examinations were positive. A. seminis might not be isolated from the epididymis even when recovered from the seminal vesicle and the bulbourethral gland. A. seminis was isolated from a spermatic granuloma in the epididymal tail but not from tissue outside the granuloma in another part of the same epididymis. A. seminis has also been isolated from the semen of a young Friesian bull with bilateral epididymitis (Van Tonder and Bolton 1970).

#### e. Diagnosis

Actinobacillus epididymitis is indistinguishable from Br. ovis infection by clinical examination (Jensen 1974).

Serological evidence could be obtained by CF procedure. In experimental infection, serum samples taken two weeks post inoculation gave positive serological results. A serological response was also evident on the third, fourth and fifth weeks but further weekly tests were negative (Baynes and Simmons 1960; Livingston and Hardy 1964).

#### 4) Corynebacterium Epididymitis

Members of the genus Corynebacterium isolated from scrotal lesions in sheep include C. pyogenes and C. pseudotuberculosis (Simmons and Hall 1953; McGowan and Schultz 1956; Ekdahl et al 1968; Watt 1970; Lal Krishna et al 1977). In general, they produced a suppurative epididymitis and the organisms were recovered in lesions elsewhere in the body including mandibular lymph node and lung.

Gram positive coccobacilli, with club forms that stained unevenly and metachromatic granules have been described. In nutrient broth cultures, a coarse, granular deposit with scanty pellicle, was observed after 48 hours at 37C. On blood agar plate, a very narrow zone of hemolysis developed around the cream-colored colonies. It did not liquefy gelatine or coagulate serum. Acid was produced in glucose, maltose, galactose but not in mannitol, sucrose and lactose (Lal Krishna et al 1977).

## II. MATERIALS AND METHODS

## 1) Cultures

The three bacterial cultures were obtained from the American Type Culture Collection: #15768 Actinobacillus seminis, #25840 Brucella ovis, and #19410 Corynebacterium pseudotuberculosis. The cultures were transferred to Brain Heart Infusion broth (BHI)<sup>a</sup> and incubated at 37 C in an atmosphere of 10% CO<sub>2</sub> for 24 to 48 hours. For storage, each culture was grown, in a test tube containing 5 ml BHI broth, 5 ml citrated bovine blood and approximately 100 sterile glass beads, for 48 hours in 10% CO<sub>2</sub>. The cultures were checked by gram stain, most of the fluid was decanted, and the beads were transferred into Pyrex tubes (16 x 125 mm). The tubes were frozen in a horizontal position at -70C and stored until required.

## 2) Preparation of Antigens

a. Actinobacillus seminis: Frozen beads of A. seminis stock cultures were placed in BHI broth with 10% bovine serum, and incubated in an atmosphere of 10% CO<sub>2</sub>, relative humidity 55%, for 48 hours at 37 C. The broth culture was checked for purity by gram stain and by streaking onto a blood agar plate. Five ml of the broth was transferred to each of six Roux flasks containing 5% bovine blood agar (BBA), the flasks

---

<sup>a</sup>Difco Laboratories, Detroit, Michigan.

were gently rotated to ensure even spread of the inoculum over the surface of the agar. The flasks were incubated for 48 hours under the conditions described above. After 48 hours, each flask was checked for purity by gram stain. The growth was harvested by sterile glass beads and formalized phosphate buffered saline (PBS). The bacterial suspension was filtered through sterile gauze to remove any agar particles, centrifuged at 12,061g for 15 minutes, the supernatant discarded, the sediment resuspended in formalized PBS, recentrifuged for 15 minutes, the supernatant discarded and the sedimented cells resuspended in formalized PBS and stored at 2-4C. The concentration of cells determined by barium chloride opacity tubes (Bailey and Scott 1974) was  $6 \times 10^9$  cells per ml. An equal volume of Freund's complete adjuvant<sup>b</sup> was mixed with bacterial suspension; the antigen was stored at 2-4C until used for immunization. Prior to each injection the bacterial adjuvant antigen was mixed by an ultrasonic disintegrator<sup>c</sup> at room temperature for five minutes.

b. Brucella ovis: Br. ovis antigen was prepared as described for A. seminis except that the cultures were incubated for 72 hours and that filtration, centrifugation and resuspension

---

<sup>b</sup>Cappel Laboratories, Downingtown, PA 19335.

<sup>c</sup>Heat Systems Co., Melville, Long Island, New York 11749.



in formalized PBS was repeated three times. The concentration was  $11 \times 10^9$  cells per ml determined by the opacity method. The bacterial adjuvant suspension was stored at 2-4C and ultrasonified prior to each immunizing injection.

c. Corynebacterium pseudotuberculosis: C. pseudotuberculosis was prepared as described for A. seminis except that sterile glass beads were added to the second resuspension of cells in PBS for dispersing the bacterial clumps by shaking. The concentration of cells per ml, determined by the opacity method, was  $20 \times 10^9$ . The bacterial adjuvant suspension was stored at 2-4C and thoroughly mixed by ultrasonification prior to each injection.

### 3) Preparation of Antiserums

Six adult female goats were randomly divided into three pairs. Each pair was injected intramuscularly with 2 ml of bacterial adjuvant suspension once a week for four weeks: #7820 and #7823 for A. seminis, #7821 and #7822 for Br. ovis and #7819 and #7824 for C. pseudotuberculosis. Ten days after the last injection 500 ml blood was collected aseptically from each goat via a jugular vein in a collection kit. The blood was allowed to clot at room temperature and the serum separated by centrifugation at 9,770g for 15 minutes. Approximately 200 ml serum was collected from each goat. The serum was stored at 2-4C.

#### 4) Determination of Antibody Titer

Macroscopic tube agglutination (Kabat et al 1964) was performed on each serum sample.

Several 10 x 75 mm tubes were labeled: 1/1, 1/2, 1/4, 1/8, 1/16, 1/32, 1/64, 1/128, 1/256, 1/512, C<sub>1</sub> and C<sub>2</sub>, respectively, and arranged in a rack; 0.2 ml normal saline was pipetted into each tube except 1/1. 0.2 ml serum was pipetted into tube C<sub>2</sub>, 1/1 and 1/2, respectively. The contents of tube 1/2 were mixed and 0.2 ml was transferred into tube 1/4, mixed and 0.2 ml transferred to the next tube and the process repeated until tube 1/512; the final 0.2 ml was discarded. 0.2 ml A. seminis suspension (formalized PBS) was added to tubes C<sub>1</sub> and 1/1 through 1/512. The contents in all twelve tubes were mixed and the rack placed in a water bath set at 37C for 6 to 8 hours before reading. The same procedure was repeated for Br. ovis and C. pseudotuberculosis.

#### 5) Fractionation of Antiserums

Each antiserum was divided into 20 ml portions in centrifuge tubes and 20 ml of freshly prepared 60% ammonium sulfate solution was added dropwise from a burette to each tube while being gently shaken. This resulted in a protein reaction mixture containing 30% saturated ammonium sulfate;

a milky precipitate of globulins formed. The reaction mixture was set aside in a refrigerator at 4C for 18 hours before centrifuging at 9,770g for 15 minutes to pack the precipitated globulins. The supernatant was discarded. The precipitate was gently resuspended and easily dissolved in sterile doubly distilled water (ddw) to the original volume of serum.

The dissolved globulins were reprecipitated by dropwise addition of 20 ml of freshly prepared 90% ammonium sulfate while being gently shaken. This resulted in a reaction mixture, containing 45% saturated ammonium sulfate; a white precipitate of globulins formed. The mixture was centrifuged immediately at 9,770g for 15 minutes to pack the precipitate. The supernatant was discarded. The precipitate was gently resuspended and readily dissolved in ddw to the original volume of serum.

#### 6) Dialysis

A predetermined length of flat cellophane dialysing tubing was placed in 0.85% NaCl solution, pH 8.0. One end was closed by knotting the tubing, the other end was opened by rubbing gently between two fingers, and 20 ml final ammonium sulfate-salted-out globulins added and the opened end closed by tying off. A string was tied to both ends of the tubing to suspend it in 0.85% NaCl, pH 8.0 contained

in a beaker. The dialysate was stirred continuously by a magnetic stirrer. Care was taken to ensure that both knots of the cellophane tubing were above saline level to prevent possible leakage of globulins. The globulins were dialyzed against frequent changes of saline until sulfate was no longer detected in the dialysate. Presence of sulfate was detected by adding 10 drops of saturated barium chloride solution to an equal volume of saline dialysate. A cloudy precipitate in the test mixture indicated the presence of sulfate. After 6 changes of saline at 6-hour intervals, the test dialysate was usually free of sulfate. The globulin solution was stored frozen at -70C.

#### 7) Determination of Protein Concentration

The protein concentration of the ammonium sulfate-extracted globulins was determined by the Biuret method. Six ml of Hycel Biuret reagent<sup>d</sup> were pipetted into 19 x 100 mm cuvettes labeled a) Monitrol 1; b) Monitrol II; c) Hycel I; d) Hycel II and e) globulins: 0.1 ml globulins, standard and control were added to the appropriate tube and mixed well. The mixtures were incubated in a water bath at 37C for 30 minutes.

---

<sup>d</sup>Hycel Biuret Reagent, Hycel, Inc., Houston, Texas 77036.

The concentration of the reaction mixtures was read in a Spectrophotometer at  $540\text{m}\mu$ .<sup>e</sup> The instrument was set to zero using a reagent blank. Values for Minitrol II (range: 5.1-6.1,  $\bar{X}$  6.9) were obtained from charts. The spectrophotometer was then adjusted to read 6.9. The concentration of Hy II was read as 6.1 and fell in the given range of 5.7 to 6.4. The protein concentration was determined for the three organisms: A. seminis (13 mg/ml), Br. ovis (5.9 mg/ml), and C. pseudotuberculosis (5.9 mg/ml).

#### 8) Conjugation with Fluorescein Isothiocyanate

Conjugation of the three precipitated globulins with FITC was carried out by the method described by Jones et al (1978). The amount of FITC required for a F/P ratio of 25  $\mu\text{g/ml}$  was calculated as 4.329 mg for A. seminis (Appendix A), 19.647 mg for Br. ovis and 22.977 mg for C. pseudotuberculosis.

#### 9) Removal of Unreacted Fluorescent Material

Unreacted fluorescent material (UFM) from A. seminis and C. pseudotuberculosis conjugates was removed by dialysis against phosphate buffered saline (PBS), pH 9 at 4C.

Four to five changes of PBS per day over a 7-day period was required before the dialysate was completely free of

---

<sup>e</sup>Perkin-Elmer Corporation, Mountain View, California 94043.

fluorescence. Removal of UFM was completed when no fluorescence was visible in 5 ml of the dialysate in the dark under UV light.

UFM from the Br. ovis conjugate was removed by gel filtration (Appendix B).

#### 10) Storage of Conjugates

Each conjugate was dispensed into small tubes each containing 3 ml and stored frozen at -70C.

#### 11) Testing the Immunofluorescent Reagents

##### a. Homologous and Heterologous Staining

Forty-eight hour colonies of the three bacteria grown on BBA were suspended in PBS, pH 7.2. One loopful of 1% gelatin<sup>f</sup> solution was mixed with another loopful of bacterial suspension on a glass slide and spread into a thin smear using a wire loop. The smear was air-dried for 5 minutes and then gently heat-fixed over a Bunsen flame. Several other smears were prepared in the same way. Two 1-1.5 cm circles were made around the smear with a glass marking pencil. Two wells were then made on the marks using Marktex ink and Tech-Pen.

---

<sup>f</sup>Bacto-Gelatin, Difco Laboratories, Detroit, Michigan, USA.

Several dilutions of the conjugate being tested - 1:4, 1:8, 1:16, 1:32, 1:64, etc. - were prepared by adding appropriate amounts of PBS, pH 7.2. One drop each of undiluted, 1:4, 1:8, etc., was added to each well. The slides were placed on wooden rods in petri dishes over moistened filter paper and incubated at 37C for 2 hours.

After incubation, excess conjugate was carefully drained off by tilting the slide on its side. The slides were then rinsed in two changes of PBS, pH 7.2 for 2 minutes per rinse.

The slides were blotted dry and counterstained with one drop of rhodamine<sup>g</sup> for 5 minutes. Excess counterstain was drained off before rinsing in PBS, pH 7.2 for a minute. The slides were blotted dry. One drop of mountant<sup>h</sup> was placed on each well and coverslipped, while ensuring that no air bubbles formed.

The slides were examined with a Leitz Ploem incident light FA microscope<sup>i</sup> using a K460 suppression filter and two interference blue KP490 filters as exciting filters. All slides were examined for presence of fluorescence, cell morphology, type of staining, fluorescence intensity and consistency. The background appearance was noted as well as any nonspecific staining.

---

<sup>g</sup>Rhodmine Counterstain, Difco Laboratories, Detroit, Michigan, USA.

<sup>h</sup>FA Mounting Fluid, Difco Laboratories, Detroit, Michigan, USA.

<sup>i</sup>Ernst Leitz GMBH Wetzlar, West Germany.

Specific fluorescence of organisms was recorded as strong (indicating clear outline of cell wall morphology and green fluorescing wall with a dark cellular interior; weak (when fluorescence was less marked but with distinguishable cellular morphology); and negative (when neither fluorescence nor cellular morphology was observed).

The staining titer was determined as the highest dilution giving distinct fluorescence with the homologous strain. A routine test dilution (RTD) was prepared as a dilution that was half as great as the staining titer.

Other strains of the three genera were prepared as before and stained with the RTD of each conjugate. In addition, 31 other bacterial species were stained with each conjugate.

The working conjugate solutions, once thawed from the frozen preserved state, were stored at 4C until used.

#### b. Indirect Immunofluorescent Staining of *A. seminis*

Colonies of *A. seminis* grown on BBA for 48 hours in 10% CO<sub>2</sub> were suspended in PBS, pH 7.2, smeared on a glass slide and air-dried for 5 minutes. The smear was gently heat-fixed by warming over a flame from a Bunsen burner. After cooling, two circles were made around the smear with glass marking pencil and kept close together so that a large coverslip would cover both. Each circle was ringed with Marktex



ink using Tech-Pen. A drop of serum was added to each reaction well.

The slide was placed in a moistened chamber and incubated at 37C for 1 hour. The slide was later rinsed twice in PBS, pH 7.2, for a minute per rinse. One drop of Goat-Globulin-Antiglobulin (Rabbit)<sup>j</sup> was added to each reaction well and incubated at 37C for 1 hour. The slide was washed twice in PBS, pH 7.2 for a minute per wash. One drop of rhodamine counterstain was added to each reaction well. After 10 seconds, the slide was rinsed in PBS, pH 7.2 for 1 minute. The slide was blotted dry and a drop of mounting fluid was added to each well and coverslipped. The slide was then examined with a Leitz Ploem incident light FA microscope using a K460 suppression filter and two interference blue KP490 filters as exciting filters.

c. Immunofluorescent Staining of A. seminis in Ovine Semen

An adult ram #16 was infected with A. seminis by injecting 1 ml A. seminis broth suspension into the tail of the left epididymis.

Semen was collected in sterile test tubes by electroejaculation<sup>k</sup> 5 days post inoculation. A 1:10 dilution of

---

<sup>j</sup>Difco Laboratories, Detroit, Michigan, USA.

<sup>k</sup>SPE Ejaculator, Standard Precision Electronics, Inc., Denver, Colorado 80217.

semen was made by adding PBS, pH 7.2 . Ond drop of diluted semen was mixed with a drop of 1% gelatine on a glass slide, spread into a thin smear and air-dried for 5 minutes. The smear was gently heat-fixed over a Bunsen burner flame. Two 1-1.5 cm circles were made around the smear with glass marking pencil and then ringed with Marktex ink, using Tech Pen. A drop of routine test dilution of A. seminis conjugate was added to the smear. Other smears were stained with conjugate previously adsorbed with testis powder. The slide was placed in a moistened chamber and incubated at 37C for 2 hours. Excess conjugate was carefully drained off and the slide was rinsed in two changes of PBS, pH 7.2 for 2 minutes per rinse. The slide was blotted dry and counterstained with a drop of rhodamine for 5 minutes. Excess counterstain was drained off before rinsing the slide in PBS, pH 7.2 for one minute. The slide was blotted dry. One drop of mountant was added and the smear was coverslipped.

The slide was examined with a Leitz Ploem incident light FA microscope, using a K460 suppression filter and two interference blue KP490 filters as exciting filters. The slide was examined for presence of fluorescence, bacterial and sperm cell morphology, type of staining, and fluorescence intensity and consistency. Background appearance and NSS were noted.

#### d. Testis Tissue Powder

Acetone - precipitated, saline-insoluble ovine testis and epididymis powder was prepared as follows:

- 1) Fresh tissue was placed in a Waring blender with equal volume of 0.15M saline and homogenized.
- 2) The homogenate was slowly poured into acetone at -70C, allowed to stand for 30 minutes, decanted, and added to 4 volumes of acetone at RT.
- 3) The acetone was changed twice daily for two days.
- 4) The precipitate harvested by a suction funnel.
- 5) The powder was dried overnight in vacuo over  $\text{CaCl}_2$  and stored in a screw-capped jar at 2-4C.

#### e. Cellulose Acetate Strip Electrophoresis (CASE)<sup>1</sup>

With a wax pencil CASE strips<sup>m</sup> were labelled at one end of the Mylar side: 1) Human control serum (MTII)<sup>n</sup>; 2) C. pseudotuberculosis conjugate; 3) C. pseudotuberculosis globulin; 4) A. seminis conjugate; 5) A. seminis globulin; 6) Br. ovis conjugate; 7) Br. ovis globulin and 8) Goat normal serum.

---

<sup>1</sup>Henry et al (1974).

<sup>m</sup>Helena Laboratories, 1530 Lindorgh Drive, P.O. Box 752, Beaumont, Texas 77704.

<sup>n</sup>Helena Laboratories, 1530 Lindorgh Drive, P.O. Box 752, Beaumont, Texas 77704.

Strips were soaked in Tris-Barbital-Sodium-Barbital buffer<sup>O</sup> (pH 8.6-9; 0.05 ionic strength) for 45 minutes and blotted dry. Buffer was added to the electrophoresis chamber.<sup>P</sup> Soft tissue papers were kept on the inner ridges of the chamber to form connecting bridges between buffer in the chamber compartments. Ice blocks were placed in the chamber to maintain a temperature of 4C during electrophoresis. Using Super Z Applicator Kit<sup>Q</sup> small quantities each of 1 to 8 were applied to the acetate side of the strips. Strips were placed on ridges of chamber and weighed down with three glass slides to ensure contact with the wet paper. The chamber was connected to a power source<sup>r</sup> and electrophoresis was allowed to proceed for 13 minutes at a constant voltage of 300 volts.

The power source was turned off and the strips removed. One strip was dipped in methanol and later viewed in the dark with a portable UV lamp; other strips were immersed in Ponceau S staining solution<sup>S</sup> for 10 minutes. Strips were

---

<sup>O</sup>Helena Laboratories, 1530 Lindorgh Drive, P.O. Box 752, Beaumont, Texas 77704.

<sup>P</sup>Helena Laboratories, 1530 Lindorgh Drive, P.O. Box 752, Beaumont, Texas 77704.

<sup>Q</sup>Helena Laboratories, 1530 Lindorgh Drive, P.O. Box 752, Beaumont, Texas 77704.

<sup>r</sup>Gelman Instrument Company, 600 South Wagner Road Ann.

<sup>S</sup>Helena Laboratories, 1530 Lindorgh Drive, P.O. Box 752, Beaumont, Texas 77704.

then passed through three washes of 5% acetic acid. At the third acetic acid wash care was taken to ensure that strips had no extra stain except protein. Strips were placed, acetate face down, on blotting pad to remove excess acid. Strips were immersed in methanol for 5 minutes and then in clearing solution (containing 4% Clear Aid<sup>t</sup>, 71% Methanol and 25% Acetic Acid) for 5 minutes.

The soft strips were carefully placed with Mylar side down on glass plate set at 60C. After drying, strips were scanned on a Quick Scan Jr. densitometer<sup>u</sup> using a 525 nm filter.

---

<sup>t</sup>Helena Laboratories, 1530 Lindorh Drive, P.O. Box 752, Beaumont, Texas 77704.

<sup>u</sup>Helena Laboratories, 1530 Lindorh Drive, P.O. Box 752, Beaumont, Texas 77704.

### III. RESULTS

Actinobacillus seminis

The antibody titer determined by the macroscopic tube agglutination was 1/128.

Specific immunofluorescence of A. seminis was observed in smears stained with undiluted conjugate as well as with conjugate dilutions of 1/4, 1/8, 1/16 and 1/32, respectively. The fluorescence was strong with the first four preparations. Nonspecific fluorescence was a problem with undiluted conjugate as well as with the 1/4 and 1/8 dilutions. Nonspecific fluorescence was minimal with 1/16 dilution. Fluorescence observed with 1/32 dilution was weak, and was progressively so with higher dilutions.

Using the RTD, A. seminis was observed to be pleomorphic with coccobacilli predominating. The cell wall was distinct, gave a green fluorescence and was clearly demarcated from a darker interior (Fig. 1-9). The background was amorphous and maroon to dark.

Other organisms stained with the RTD of A. seminis conjugate gave no specific immunofluorescence (Table 1).

With prolonged storage of conjugate solutions at 4C, there was a tendency for a yellow precipitate to deposit in the tube. Such solutions had to be centrifuged to remove particles that would otherwise cause NSS.

TABLE 1. ORGANISMS STAINED WITH FITC-CONJUGATED  
A. SEMINIS ANTISERUM

<u>Organism</u>	<u>Result</u>
<u>A. seminis</u>	Strong
<u>Actinobacillus</u> sp (2)	Negative
<u>A. lignieresii</u>	Negative
<u>Br. ovis</u>	Negative
<u>Br. melitensis</u>	Negative
<u>Br. canis</u>	Negative
<u>Br. abortus</u>	Negative
<u>Br. suis</u>	Negative
<u>C. pseudotuberculosis</u> (2)	Negative
<u>C. equi</u>	Negative
<u>C. renale</u>	Negative
<u>C. pyogenes</u> (2)	Negative
<u>Pasteurella hemolytica</u>	Negative
<u>P. multocida</u>	Negative
<u>Salmonella</u> sp.	Negative
<u>Bordetella bronchiseptica</u>	Negative
<u>Moraxella bovis</u>	Negative
<u>Pseudomonas aeruginosa</u>	Negative
<u>Branhamella catarrhalis</u>	Negative
<u>Citrobacter</u> sp.	Negative
<u>Bacillus cereus</u>	Negative
<u>Proteus mirabilis</u>	Negative
<u>Erysipellos</u> sp.	Negative
<u>Escherichia coli</u> (2)	Negative
<u>Staphylococcus pyogenes</u>	Negative
<u>Staph. aureus</u>	Negative
<u>Staph. epidermidis</u>	Negative
<u>Streptococcus pneumoniae</u>	Negative

Number in parenthesis represents the number of strains tested.



Fig. 1. A. seminis. Note pleomorphic forms,  
consisting of coccobacilli and bacilli with  
rounded ends. Cell walls showed positive  
green fluorescence (X5120).

Fig. 2. A. seminis giving specific immunofluorescence  
(X1600).

Fig. 3. A. seminis showing Chinese-lettered forms.  
Cell walls gave green fluorescence. Note  
the dark interior (X1600).

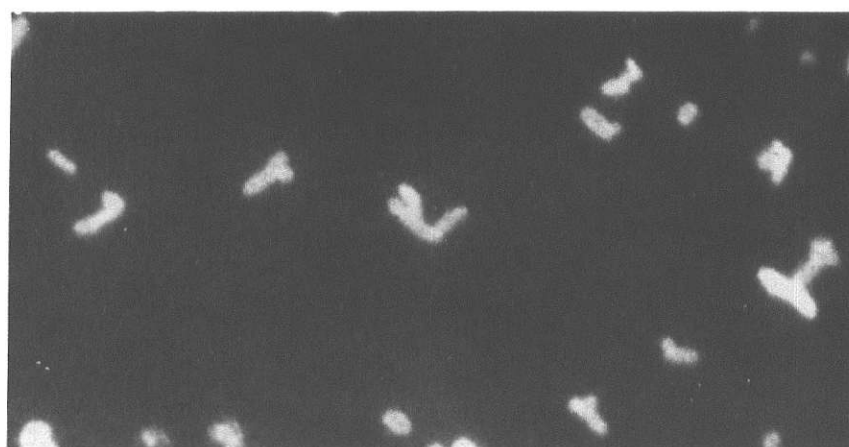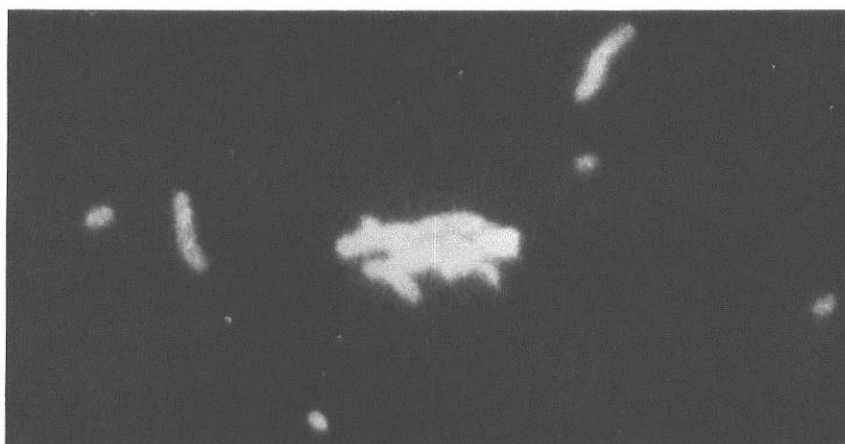

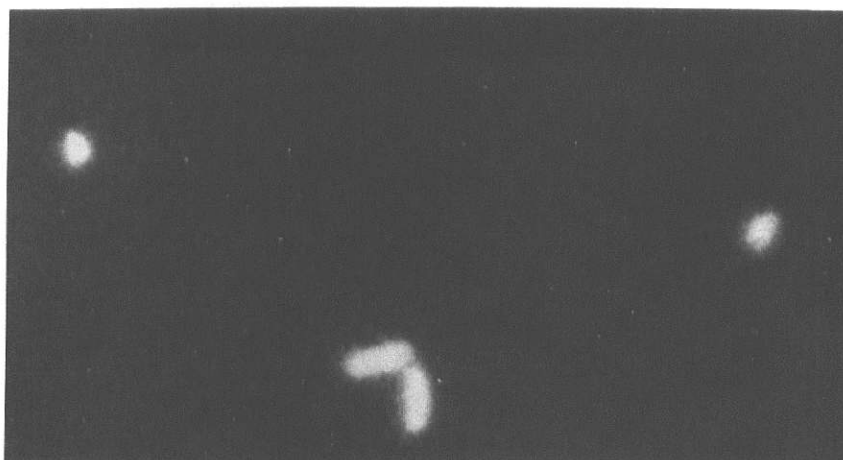
Fig. 4. Pleomorphic forms of A. seminis showing specific immunofluorescence. Note the strong fluorescence (X5120).

Fig. 5. A. seminis giving positive immunofluorescence (X5120).

Fig. 6. A. seminis. Specific immunofluorescence of the paired form (X5120).

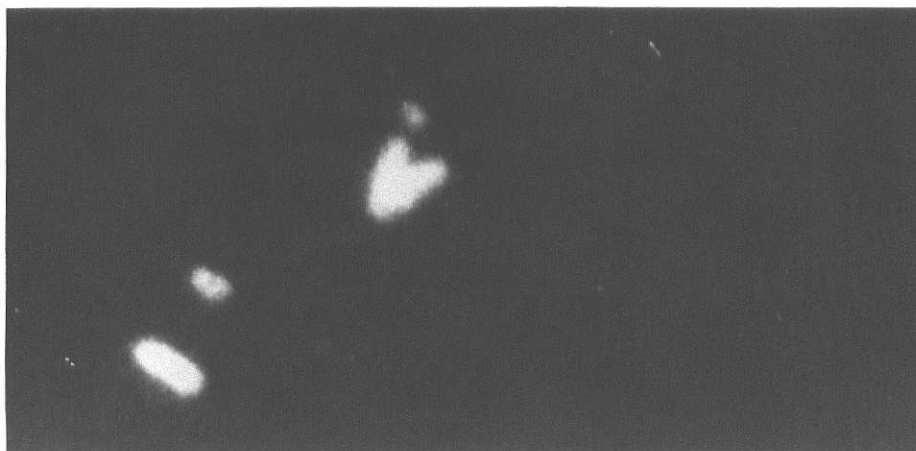
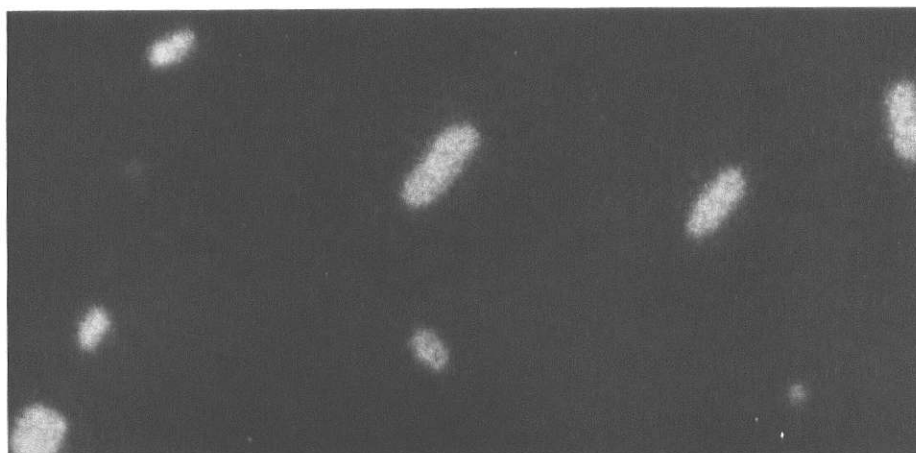
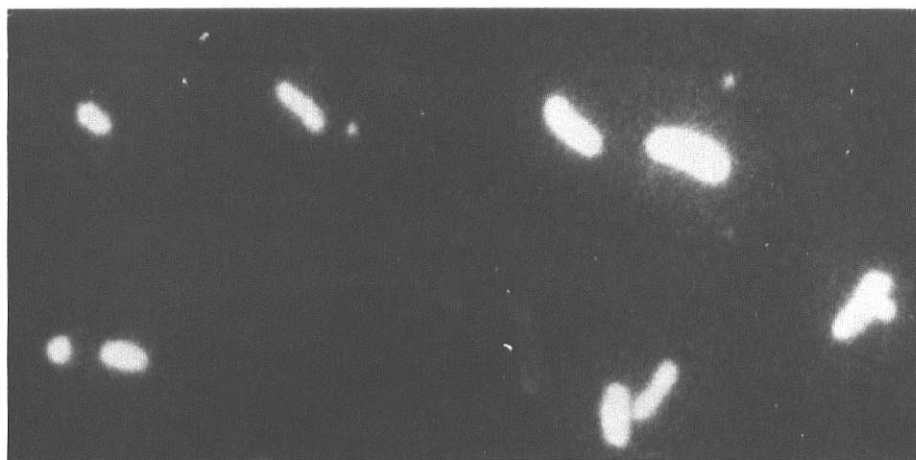Fig. 7. Semen smear. Note specific immunofluorescence of A. seminis in contrast to the glowing head of spermatozoa. Sperm tails did not fluoresce (X1600).

Fig. 8. Semen smear showing specific immunofluorescence of A. seminis. Sperm head with bright glow and sperm tail unstained (X1600).

Fig. 9. Semen smear with A. seminis giving specific immunofluorescence. Note that spermatozoa did not fluoresce (X1600).

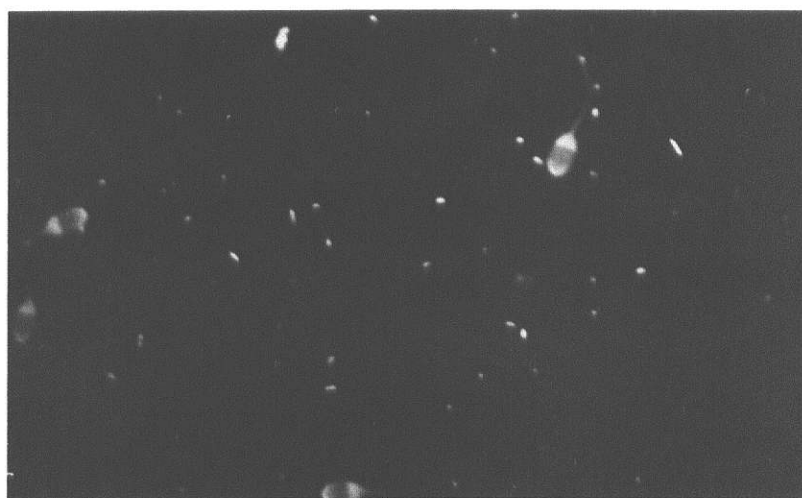
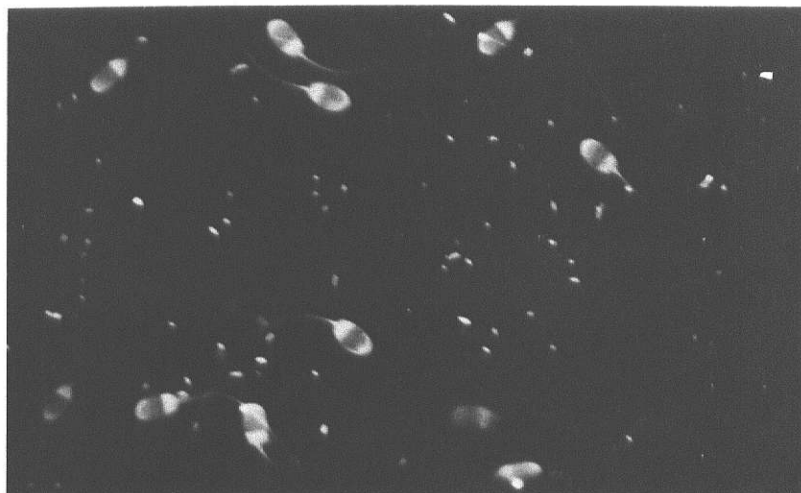
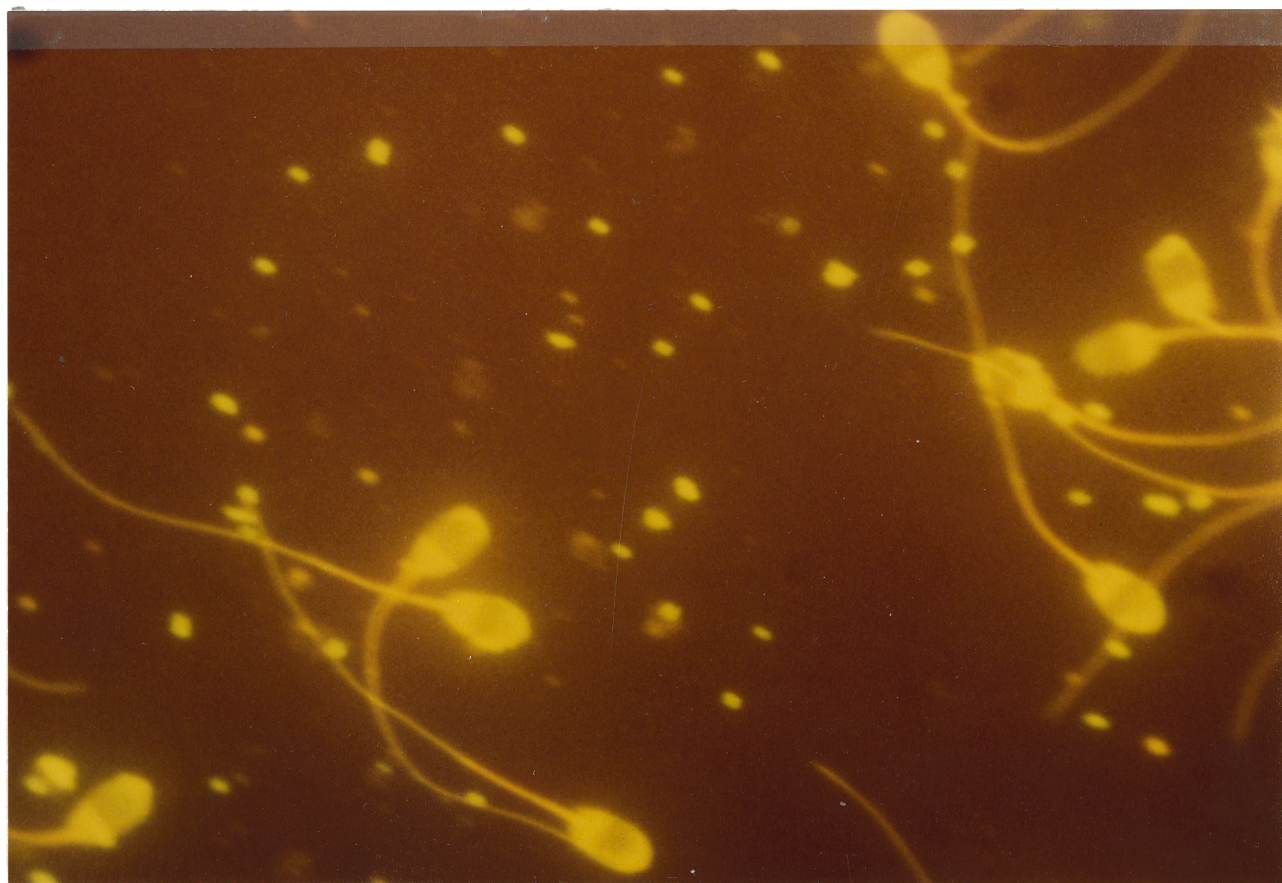
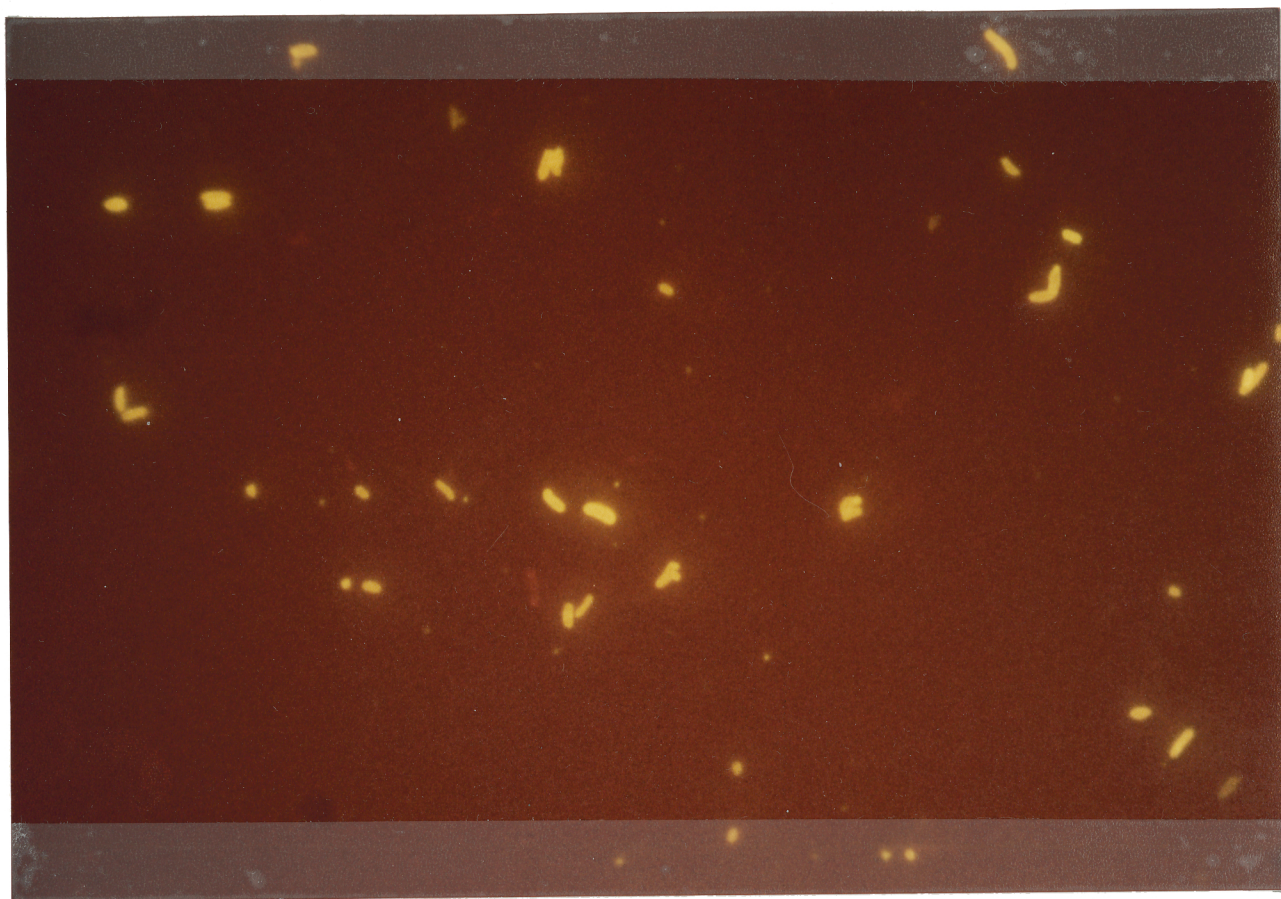


Fig. 10. Specific immunofluorescence of A. seminis.

Fig. 11. Semen smear showing specific immunofluorescence of A. seminis and yellow autofluorescence of sperm head. Note that sperm tails did not fluoresce.







In semen, A. seminis was distinct and gave a positive green fluorescence (Figs. 10-11). Sperm heads but not tails stained intensely with a yellowish autofluorescence. This staining pattern was consistent in other sections of the smears irrespective of a uniform dispersion of sperms and actinobacilli or not. NSS was observed in the background but did not interfere with the identification or evaluation of A. seminis infected semen smears. Autofluorescence of sperm heads was not observed in semen smears stained with conjugate adsorbed with testis powder.

#### Brucella ovis

The antibody titer determined by the macroscopic tube agglutination was 1/64.

Preliminary runs with the conjugate did not give any fluorescence of brucellae. The conjugate was concentrated by adding 0.42 gm. lyphogel<sup>V</sup> to 3 ml of conjugate. This reduced the conjugate volume to 1 ml in about eight hours when set at 4C.

Specific immunofluorescence of Br. ovis was observed in smears stained with undiluted concentrated conjugate as well as with other dilutions of 1/4, 1/8 and 1/16, respectively. The fluorescence was strong with the first

---

<sup>V</sup>Polyacrylamide Gel, Gelman Instrument Company, Ann Arbor, Michigan USA.

three strengths. Nonspecific fluorescence was not a problem since individual organisms fluoresced specifically. The fluorescence emission with 1/16 was weak and was negative at the higher dilutions.

Br. ovis gave specific immunofluorescence and was seen as short coccobacilli (Figs. 12-15). The cell wall was clearly visible, as green fluorescence covering a dark interior (Fig. 15). The background was amorphous and maroon to dark.

Other organisms stained with Br. ovis conjugate gave no specific immunofluorescence (Table II).

With prolonged storage of conjugate solutions at 4C, there was a tendency for deposition of a yellow precipitate in the tube. Such solutions were centrifuged to remove particles that would otherwise cause NSS.

#### Corynebacterium pseudotuberculosis

The antibody titer determined by the macroscopic tube agglutination was 1/64.

Specific immunofluorescence of C. pseudotuberculosis was observed in smears stained with undiluted conjugate as well as with dilutions of 1:4, 1:8, 1:16 and 1:32, respectively. The fluorescence was strong with the first four preparations and weak with a dilution of 1:32. No fluorescence was observed at higher dilutions.

TABLE II. ORGANISMS STAINED WITH FITC-CONJUGATED  
BR. OVIS ANTISERUM

<u>Organism</u>	<u>Result</u>
<u>Br. ovis</u>	Strong
<u>Br. canis</u>	Negative
<u>Br. abortus</u>	Negative
<u>Br. melitensis</u>	Negative
<u>Br. suis</u>	Negative
<u>A. seminis</u>	Negative
<u>Actinobacillus</u> spp. (2)	Negative
<u>A. lignieresii</u>	Negative
<u>C. pseudotuberculosis</u> (2)	Negative
<u>C. equi</u>	Negative
<u>C. renale</u>	Negative
<u>C. pyogenes</u> (2)	Negative
<u>Pasteurella hemolytica</u>	Negative
<u>P. multocida</u>	Negative
<u>Salmonella</u> sp.	Negative
<u>Bordetella bronchiseptica</u>	Negative
<u>Moraxella bovis</u>	Negative
<u>Pseudomonas aeruginosa</u>	Negative
<u>Branhamella catarrhalis</u>	Negative
<u>Citrobacter</u> sp.	Negative
<u>Bacillus cereus</u>	Negative
<u>Proteus mirabilis</u>	Negative
<u>Erysipelas</u> sp.	Negative
<u>Escherichia coli</u> (2)	Negative
<u>Staphylococcus pyogenes</u>	Negative
<u>Staph. aureus</u>	Negative
<u>Staph. epidermidis</u>	Negative
<u>Streptococcus pneumoniae</u>	Negative

Number in parenthesis represents the number of strains tested.

Fig. 12. Specific immunofluorescence of Br. ovis.  
Note the short coccobacilli separate and  
paired (X1600).

Fig. 13. Specific immunofluorescence of Br. ovis  
(X1600).

Fig. 14. Specific immunofluorescence of Br. ovis.  
Note the pleomorphism (X1600).

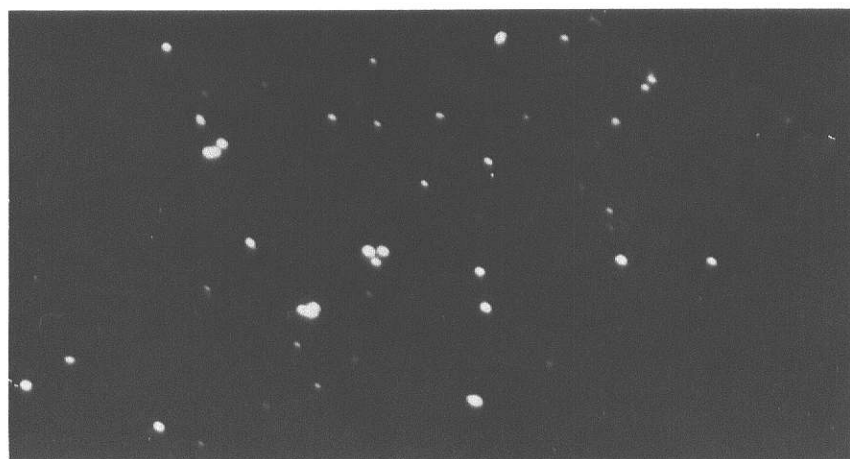
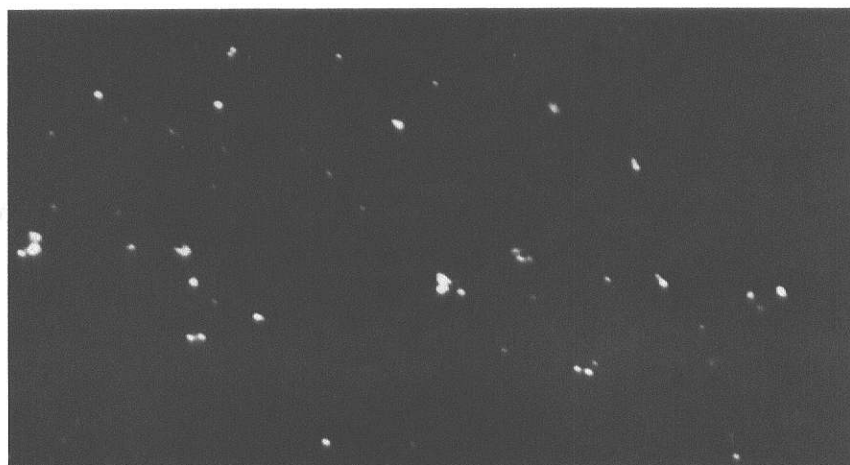
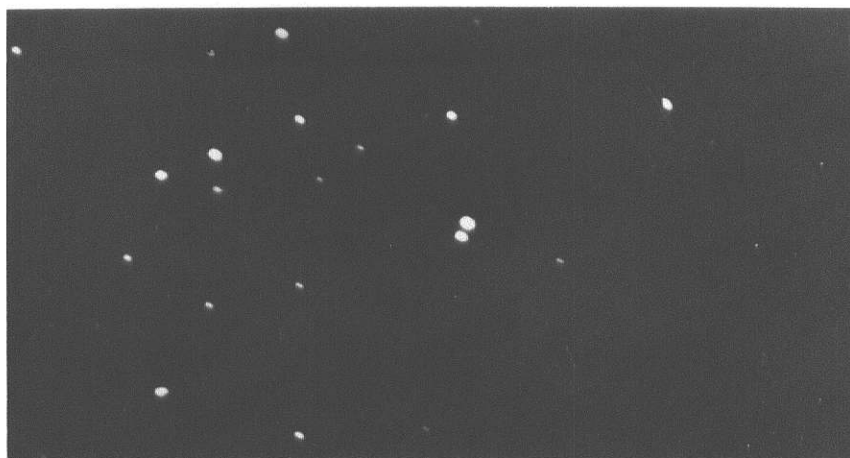
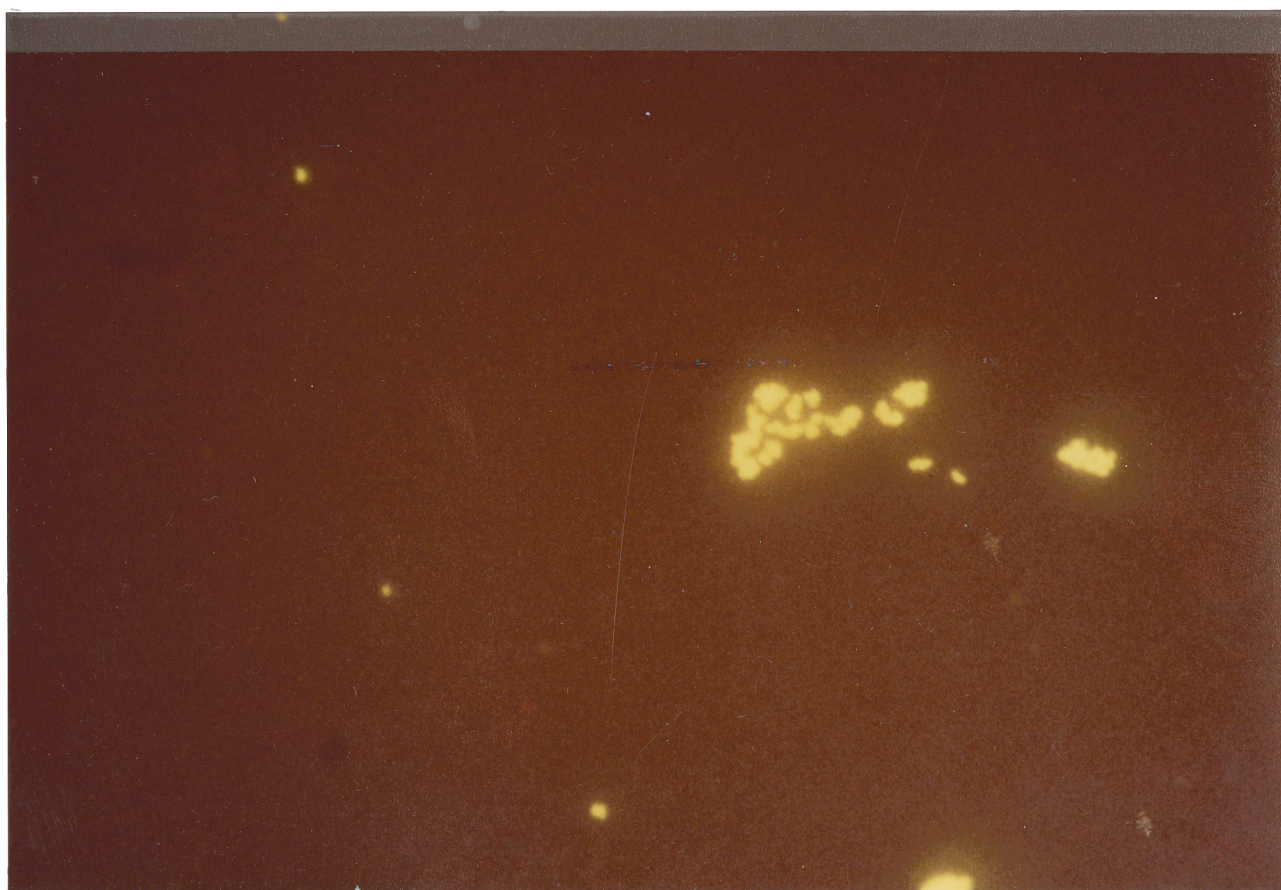



Fig. 15. Specific immunofluorescence of Br. ovis.

Fig. 16. Specific immunofluorescence of C. pseudotuberculosis.





C. pseudotuberculosis was observed as pleomorphic coccobacilli. The cell wall stained clearly with a green fluorescence while the cell interior was dark (Figs. 16-19). The background appearance was amorphous and maroon to dark.

A. seminis gave a specific fluorescence with a dilution of 1:16. Other organisms stained with the conjugate gave no specific fluorescence (Table III).

With prolonged storage of conjugate solution at 4C, there was a tendency for a yellow precipitate to deposit. Such solutions were centrifuged to remove particles that otherwise would cause NSS.

#### Cellulose Acetate Strip Electrophoresis

The separated components in #1 and 8 were used for qualitative interpretations of the protein samples.

CASE strips showed separation of the components in all protein samples analysed (Fig. 20). In the three globulin preparations (#3, 5 and 7), a large proportion of the separated components were gamma globulins with smaller proportions of alpha and beta globulins. In the three FITC-conjugated globulins (#2, 4 and 6), there was little differentiation between the globulins. A high F:P ratio of 25 in the conjugates increased the heterogeneity of the gamma globulins as well as their migration toward the anode and significantly altered the alpha and beta



TABLE III. ORGANISMS STAINED WITH FITC-CONJUGATED  
C. PSEUDOTUBERCULOSIS ANTISERUM

---

<u>Organism</u>	<u>Result</u>
<u>C. pseudotuberculosis</u> (2)	Strong
<u>A. seminis</u>	Strong
<u>Actinobacillus</u> (2)	Negative
<u>A. lignieresii</u>	Negative
<u>C. renale</u>	Negative
<u>C. equi</u>	Negative
<u>C. pyogenes</u> (2)	Negative
<u>Br. ovis</u>	Negative
<u>Br. melitensis</u>	Negative
<u>Br. suis</u>	Negative
<u>Br. abortus</u>	Negative
<u>Br. canis</u>	Negative
<u>Pasteurella hemolytica</u>	Negative
<u>P. multocida</u>	Negative
<u>Salmonella</u> sp.	Negative
<u>Bordetella bronchiseptica</u>	Negative
<u>Moraxella bovis</u>	Negative
<u>Pseudomonas aeruginosa</u>	Negative
<u>Branhamella catarrhalis</u>	Negative
<u>Citrobacter</u> sp.	Negative
<u>Bacillus cereus</u>	Negative
<u>Proteus mirabilis</u>	Negative
<u>Erysipelas</u> sp.	Negative
<u>Escherichia coli</u> (2)	Negative
<u>Staphylococcus pyogenes</u>	Negative
<u>Staph. aureus</u>	Negative
<u>Staph. epidermidis</u>	Negative
<u>Streptococcus pneumoniae</u>	Negative

---

Number in parenthesis represents the number of strains tested.

Fig. 17. Specific IF of C. pseudotuberculosis showing coccobacilli, singly and in clumps (X1600).

Fig. 18. Specific IF of C. pseudotuberculosis (X1600).

Fig. 19. Specific IF of C. pseudotuberculosis. Note the curved round ends of the coccobacillus (X5120).

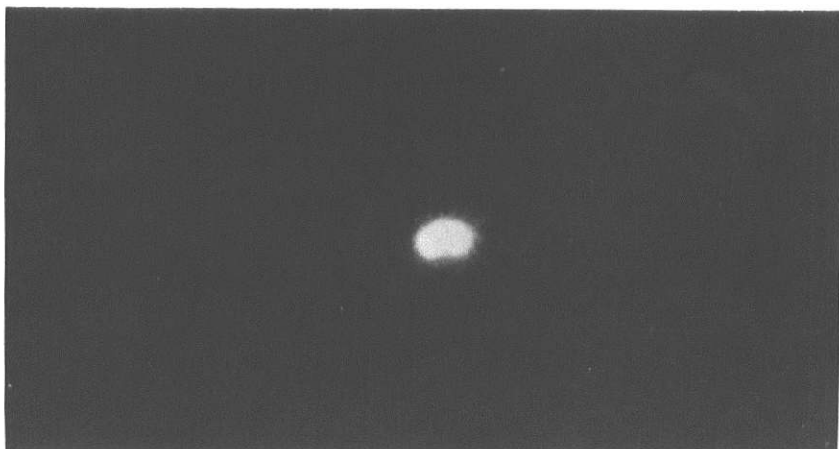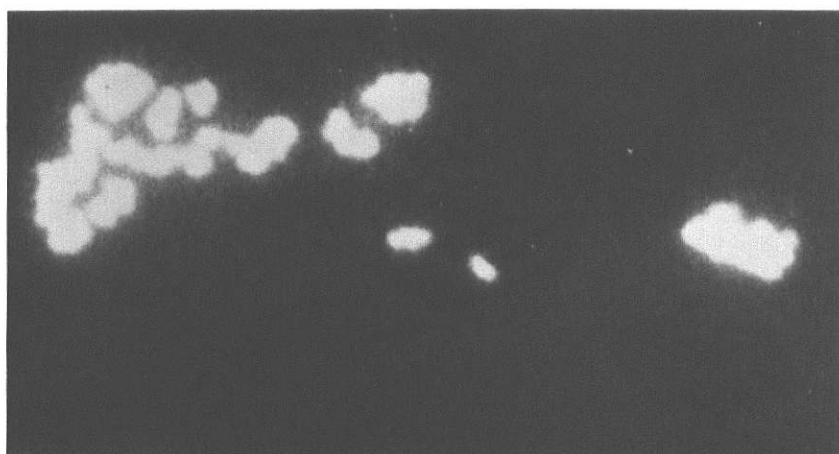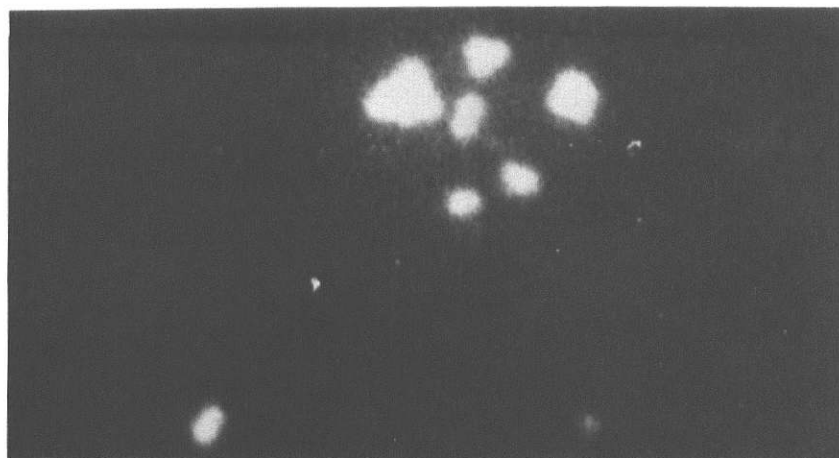
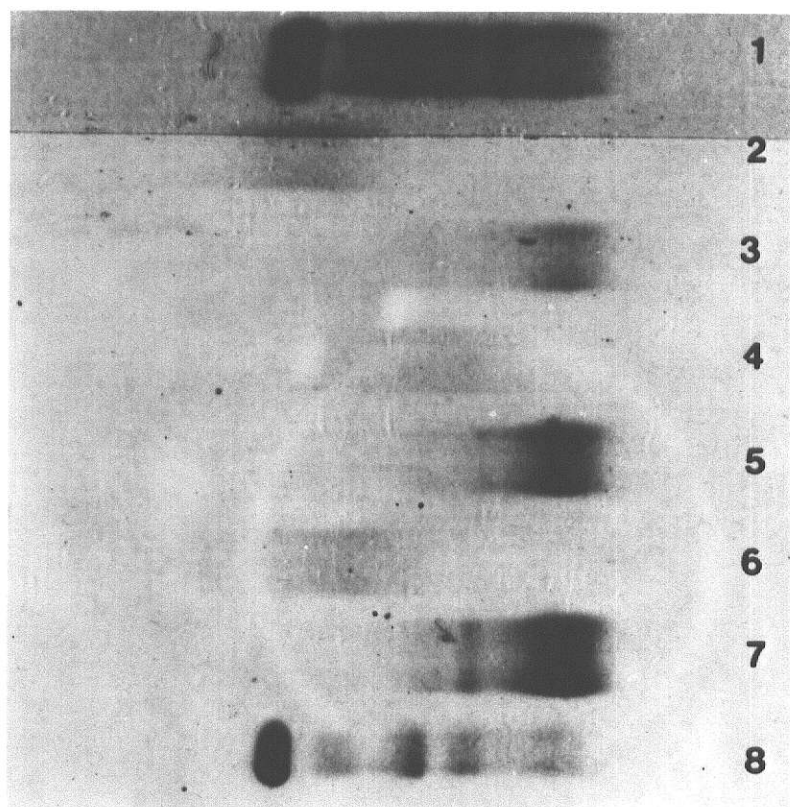


Fig. 20. Cellulose Acetate Strip Electrophoresis: Protein Profile. 1) Human control serum; 2) C. pseudotuberculosis conjugate; 3) C. pseudotuberculosis globulin; 4) A. seminis conjugate; 5) A. seminis globulin; 6) Br. ovis conjugate; 7) Br. ovis globulin and 8) Goat normal serum. Note that separated bands in the globulin preparations (#3, 5 and 7) were mainly gamma globulins. FITC conjugated globulins (#2, 4 and 6) showed greater electrophoretic mobility.



globulins. Both human control and goat normal serums contained albumin as well as globulin fractions.

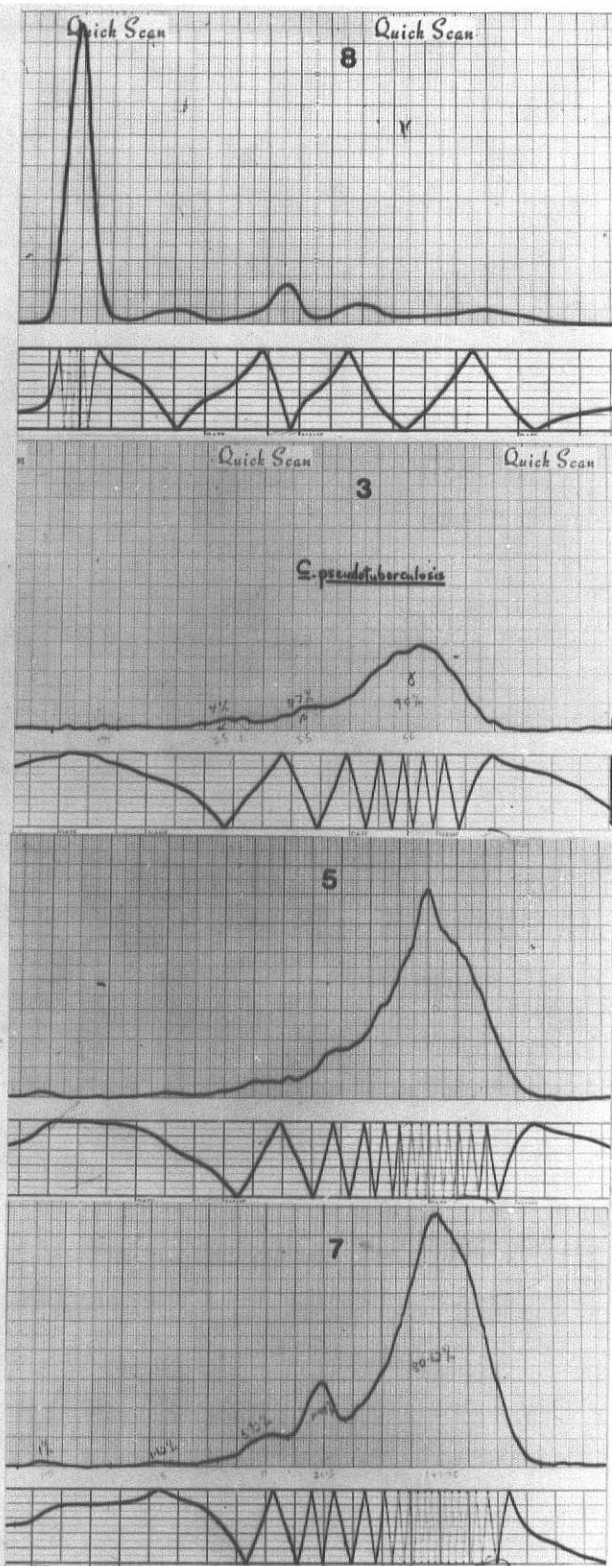
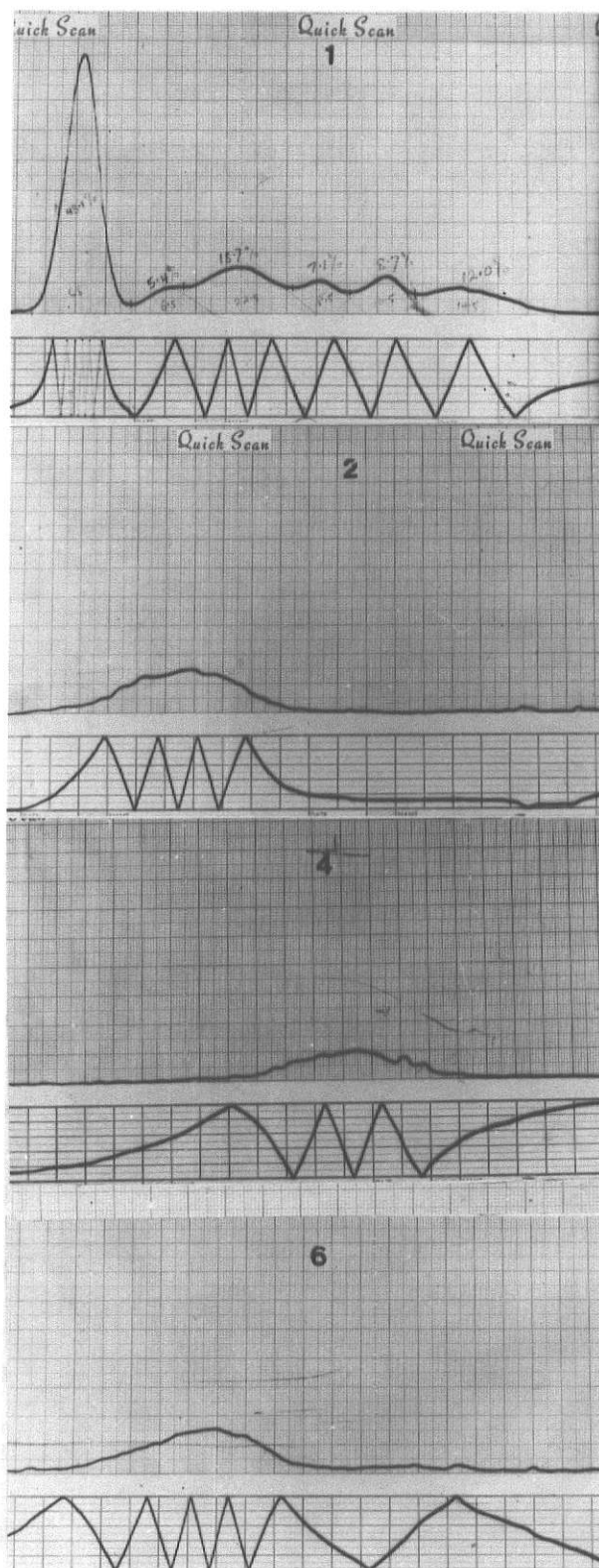
Findings obtained on densitometer charts were consistent with those on CASE strips (Plate 1) and yielded quantitative information about the proportions of the protein fractions. Human control serum was made up of 48.1% albumin, 24.1% alpha, 15.8% beta and 12% gamma globulins. Goat normal serum was composed of 56.15% albumin, 8.2% alpha, 22.08% beta and 13.57% gamma globulins.

C. pseudotuberculosis globulin contained 4% alpha, 5.7% beta and 90% gamma globulins. A. seminis globulin was made up of 2.8% alpha, 8.1% beta and 89.1% gamma globulins while Br. ovis globulin was composed of 2.62% alpha, 16.96% beta and 80.62% gamma globulins.

CASE strips without Panceau S staining, which were examined under UV light, showed fluorescence of the separated components of the conjugates in #2, 4 and 6.

Plate 1. Densitometer Chart Tracings.

1. Human control serum. 48.1% albumin, 24.1% alpha, 15.8% beta and 12% gamma globulins.
2. C. pseudotuberculosis conjugate. There was little differentiation between the globulins.
3. C. pseudotuberculosis globulin. 4% alpha, 5.7% beta and 90% gamma globulins.
4. A. seminis conjugate. Note the little differentiation between the globulins.
5. A. seminis globulin. 2.8% alpha, 8.1% beta and 89.1% gamma globulins.
6. Br. ovis conjugate. Globulin components were not distinct.
7. Br. ovis globulin. 2.62% alpha, 16.96% beta and 80.62% gamma globulins.
8. Goat normal serum. 56.15% albumin, 8.2% alpha, 22.08% beta and 13.57% gamma globulins.





#### IV. DISCUSSION

In biomedical research, it is desirable to visualize in situ the microscopic distribution and localization of antigens in cells and tissues. The IF technique, an advanced form of histochemistry, utilizing antigen-antibody systems with high specificity, appears to be a dream come true. Within two decades following its development by Coons and his associates (1941; 1942; 1950), IFT has developed into a multi-potential diagnostic tool. It has found wide acceptance in microbial cytology and diagnosis and has been utilized for rapid identification of bacteria in smears (Moody et al 1956; Jones et al 1978).

The literature is replete with examples of direct and indirect IF studies with bacteria. IF preparations have been applied to identify Bordetella pertussis (Jones et al 1978), Brucella spp (Carter et al 1958; Biegeleisen et al 1962; Cherry et al 1962), Campylobacter spp (Carter et al 1958; Mellick et al 1965; Lein et al 1968), Corynebacterium spp (Addo 1978; Addo et al 1979) E. coli (Page et al 1962), Leptospira (Coffin et al 1962; Cook et al 1971), Malleomyces pseudomallei (Moody et al 1956), Moraxella bovis (Pugh et al 1977), Mycoplasma spp (Bradbury et al 1976; Kawamura 1977), Pasteurella pestis (Winter et al 1959), Staphylococcus spp (Moody et al 1958), Streptococcus spp (Cherry et al 1965) and Treponema pallidum (Cherry et al 1965).

In studies of ovine epididymitis, one of the major problems has been detection of the etiological agent(s). Specific immunofluorescence in these studies clearly demonstrated that A. seminis, Br. ovis and C. pseudotuberculosis could be identified in smears exposed to appropriate conjugates. The direct implication of this is the possibility of improved diagnosis of ovine epididymitis.

Hitherto, identification of A. seminis (Baynes and Simmons 1960) or Br. ovis (McFarlane 1950) has been based on cultural characteristics, morphology and biochemical reactions. These procedures are suitable when time is not a factor but could be inadequate in working with A. seminis or Br. ovis which are inactive biochemically (Baynes and Simmons 1960; Livingston and Hardy 1964; Simmons and Hall 1953; Buddle and Boyes 1953; Kennedy et al 1960).

Pleomorphism exhibited by both A. seminis (Baynes and Simmons 1960) and Br. ovis (Buddle 1956; Kennedy et al 1956) compounds this diagnostic problem. This is so because in smears stained by routine stains, it is often difficult to ascertain their identity with confidence. Furthermore, this pleomorphism could preclude their identification in smears contaminated by other organisms having similar morphological characteristics.

It cannot be overemphasized that in these studies, all forms of A. seminis and Br. ovis gave specific immunofluorescence and with equal intensity and consistency. An accurate diagnosis could be made. Results were obtained within a few hours, obviating days of waiting in conventional bacteriology.

A. seminis and Br. ovis cause ovine epididymitis which is indistinguishable clinically and both are gram-negative pleomorphs (McFarlane et al 1952; Baynes and Simmons 1960). In a case of mixed infection by the two, it is obvious that their differentiation could pose real challenge to an investigator. The immunofluorescent diagnosis of A. seminis and Br. ovis in smears is, therefore, of significance with regards to rapid differentiation between the two.

One of the attributes of the IF technique is the extraordinary sensitivity, permitting detection of a single bacterial cell admixed with large number of contaminants (Cherry and Moody 1965). This sensitivity (Beutner 1971) was clearly evident in the three IF systems developed and in particular, the A. seminis IF preparation. In this study, an accurate identification of A. seminis in semen smears could be made within a few hours obviating days of waiting needed in conventional diagnostic bacteriology. Detection of A. seminis in semen smears obtained by electroejaculation represents a new dimension in the study of ovine

actinobacillary epididymitis. Hitherto, diagnosis had been based on scrotal palpation, complement fixation, semen culture (Baynes and Simmons 1960; Livingston and Hardy 1964) and gross and microscopic pathology of enlarged epididymis (Baynes et al 1960; Claxton et al 1966; Van Tonder 1968; Worthington et al 1968).

Specificity of the IF preparations in these studies is confirmed by the specific immunofluorescence of A. seminis, Br. ovis and C. pseudotuberculosis. Other bacteria tested were negative. Interestingly, other genera close to the specific antigens did not stain with the corresponding conjugates. Other Actinobacillus spp were negative with the A. seminis conjugate and this seemed to show further the unique character of A. seminis, distinguishing it from other Actinobacillus spp.

No other Brucella spp stained with the Br. ovis conjugate. Carmichael (1976) reported cross-reactions between Br. ovis and Br. canis in agglutination reactions but no such cross-reactions were observed in this IF system. Other Corynebacterium spp were also negative with the C. pseudotuberculosis conjugate and this was in agreement with earlier findings (Addo 1978).

C. pseudotuberculosis conjugate stained A. seminis. However, this lack of specificity can be tolerated (Cherry and Moody 1965) since the morphology of the cross-reacting

antigen (A. seminis) clearly distinguishes it from the specific antigen (C. pseudotuberculosis). In addition, C. pseudotuberculosis causes a suppurative epididymitis from which gram-positive coccobacilli can be readily isolated (McGowan and Schultz 1956; Lal Krishna et al 1977).

One of the major problems associated with the use of IF technique is nonspecific staining (Coons 1956; Pittman et al 1967; Hebert et al 1967; Beutner et al 1968). In these studies, individual organisms could be recognized. Even in semen smears, the yellow autofluorescence on the sperm heads did not interfere with recognition of green fluorescence of A. seminis. This may be due to careful removal of UFM after conjugation by dialysis and gel filtration and the use of diluted conjugate. The autofluorescence of sperm heads, however, may be removed by prior absorption of dilute conjugate with testis powder.

It is of interest to note that the three IF reagents were prepared from antiserums with relatively low antibody titer. This notwithstanding, excellent results were obtained with the three IF systems.

Immunochemical analyses of unlabeled globulins and the three IF reagents demonstrated that the preparations were free of albumin and were composed of the major globulin classes with a predominance of gamma globulins. These findings are similar to those of Hebert et al (1973) in

CASE profiles of goat E. coli serum fractions. The conjugation of FITC with globulins is mediated mainly through the epsilon amino group of lysyl residue, resulting in reduction of the positive charge of the protein molecule (Kawamura 1977) as shown by changes in electrophoretic mobility.

Marking antibody with a fluorescent dye without destroying its specific immunological characteristics is an essential feature of the IF technique (Coons et al 1950). Coupling FITC to globulins in these studies did not alter their specific reactivity since the conjugates recognized their specific antigens. It is concluded from these studies that IF techniques are effective for rapid and accurate diagnosis of bacterial epididymitis in sheep.

## REFERENCES



## A. IMMUNOFLUORESCENT TECHNIQUES

Addo PB: Fluorescent antibody technique in the diagnosis of Corynebacterium pseudotuberculosis. Bull Animal Hlth Prod Afr 26 (2):128-131 (1978).

Addo PB, Cook JE: Specific immunofluorescence of C. renale. Br Vet J 135:50-54 (1979).

Bailey WR, Scott EG: Diagnostic microbiology. 4th ed. pp 400-401. The CV Mosby Company. St Louis (1974).

Beutner EH: Defined immunofluorescent staining: Past progress, present status and future prospects for defined conjugates. Annls NY Acad Sci 177:506-526 (1971).

Beutner EH, Holborow EJ, Johnson GD: Quantitative studies of immunofluorescence: I. Analysis of mixed immunofluorescence staining. Immunology 12:327-337 (1967).

Beutner EH, Sepulveda MR, Barnett EV: Quantitative studies of immunofluorescent staining. Relationships of characteristics of unabsorbed antihuman IgG conjugates to their specific and nonspecific staining properties in an indirect test for antinuclear factors. Bull Wld Hlth Organ 39:587 (1968).

Biegeleisen JZ, Bradshaw BB, Moody MD: Demonstration of Brucella antibodies in human serum: A comparison of the fluorescent antibody and agglutination techniques. J Immunol 88:109-112 (1962).

Bradbury JM, Oriel CA, Jordan FTW: Simple method for immunofluorescent identification of Mycoplasma colonies. J Clin Microbiol 3 (4):449-452 (1976).

Bronfenbrenner J, Hetler DM, Eagle IO: Modification of therapeutic sera with a view to avoiding complications of allergic nature. Science 73:455-457 (1931).

Carter CH, Leise JM: Specific staining of various bacteria with a single fluorescent antiglobulin. J Bact 76:152-154 (1958).

Chadwick, CS, McEntegart MG, Nairn RC: Fluorescent protein tracers: A simple alternative to fluorescein. Lancet 1:412-414 (1958).

Chadwick CS, Nairn RC: Fluorescent protein tracers: The unreacted fluorescent material in fluorescein conjugates and studies of conjugates with other green fluorochromes. Immunology 3:363-370 (1960).

Cherry WB, Goldman M, Carski TR, Moody MD: Fluorescent antibody techniques in the diagnosis of communicable diseases. Centre for Disease Control. Atlanta, Georgia (1960).

Cherry WB, Moody MD: Fluorescent antibody techniques in diagnostic bacteriology. Bact Rev 29:222-250 (1965).

Cherry WB, Reimer CB: Diagnostic immunofluorescence. Bull Wld Hlth Org 48:737-746 (1973).

Clark HF, Shepard CC: A dialysis technique for preparing fluorescent antibody. *Virology* 20:642-644 (1963).

Clayton RM: Localization of embryonic antigens by antisera labelled with fluorescent dyes. *Nature* 193 (4811): 1059-1060 (1954).

Coffin DL, Maestrone C: Detection of leptospire by fluorescent antibody. *Am J Vet Res* 23:159-164 (1962).

Cook JE, Coles EH, Garner FM, Luna LG: Using scrapings from formalin-fixed tissues to diagnose leptospirosis by fluorescent-antibody techniques. *Stain Technology* 46 (6): 271-274 (1971).

Coons AH: Histochemistry with labelled antibody. *Int Rev Cytol* 5:1-23 (1956).

Coons AH, Creech, HJ, Jones RN: Immunological properties of an antibody containing a fluorescent group. *Soc Exp Biol Med* 47:200-202 (1941).

Coons AH, Creech HJ, Jones RN, Berliner E: The demonstration of pneumococcal antigen in tissues by the use of fluorescent antibody. *J Immunol* 45:159-170 (1942).

Coons AH, Kaplan MH: Localization of antigens in tissue cells. II. Improvements in a method for the detection of antigen by means of fluorescent antibody. *J Exp Med* 91:1-13 (1950).

Coons AH, Leduc EH, Connolly JM: Studies on antibody production. I. A method for the histochemical demonstration of specific antibody and its application to a study of the hyperimmune rabbit. *J Exp Med* 102:49-50 (1955).

Coons AH, Leduc EH, Kaplan MH: Localization of antigen in tissue cells. IV. The fate of injected foreign proteins in the mouse. *J Exp Med* 93:173-188 (1951).

Creech HJ, Jones RN: The conjugation of horse serum albumin with 1,2-benzanthryl isocyanates. *J Am Chem Soc* 62:1970-1975 (1940).

Creech HJ, Jones RN: The conjugation of horse serum albumin with isocyanates of certain polynuclear aromatic hydrocarbons. *J Am Chem Soc* 63:1661-1669 (1941).

Curtain CC: Electrophoresis of fluorescent antibody. *Nature* 182:1305-1306 (1958).

Dandliker WB, Alonso R: Purification of fluorescein and fluorescein derivatives by cellulose ion exchange chromatography. *Immunochem* 4:191-196 (1967).

Dixon FJ, Pittsburgh P: The metabolism of antigen and antibody. *J Allergy* 25 (6):487-503 (1954).

Edsall G: The nature of the antigen and the basic characteristics of the immune response. *J Allergy* 28 (1): 1-17 (1957).

Fieser LF, Creech HJ: The conjugation of amino acids with isocyanates of the anthracene and 1,2-benzanthracene series. *J Am Chem Soc* 61:3502-3506 (1939).

Fife EH Jr, Muschel LH: Fluorescent antibody technique for serodiagnosis of Trypanosoma cruzi infection. Proc Soc Exp Biol Med 101:540 (1959).

Freund J: Some aspects of active immunization. Ann Rev Microbiol 1:291-308 (1947).

Freund J: The effect of paraffin oil and mycobacteria on antibody formation and sensitization. Am J Clin Path 21: 645-655 (1951).

Frommhagen LH, Spendlove RS: The staining properties of human serum protein conjugated with purified FITC. J Immunol 89:124-131 (1962).

Goldman M: Staining Toxoplasma gondii with fluorescein-labelled antibody. J Exp Med 105:557-573 (1957).

Goldman M, Carver RK: Preserving fluorescein isocyanate for simplified preparation of fluorescent antibody. Science 126 (3278):839-840 (1957).

Goldstein G, Slizys IS, Chase MW: Nonspecific fluorescence of tissues treated with fluorescent globulins. Bact Proc. p 139 (1960).

Goldstein G, Slizys IS, Chase MW: Studies on fluorescent antibody staining. I. Nonspecific fluorescence with fluorescein-coupled sheep anti-rabbit globulins. J Exp Med 114:89-109 (1961).

Goldwasser RA, Shepard CC: Staining of complement and modifications of fluorescent antibody procedures. J Immunol 80:122-131 (1958).

Gornall AG, Bardawill DI, David MM: Determination of serum proteins by means of biuret reaction. J Biol Chem 177:751-766 (1949).

Hebert GA, Pittman B, Cherry WB: Factors affecting the degree of nonspecific staining given by FITC-labelled globulins. J Immunol 98:1204-1212 (1967).

Hebert GA, Pelham PL, Pittman B: Determination of the optimal ammonium sulfate concentration for the fractionation of rabbit, sheep, horse and goat antisera. Appl Microb 25:26-36 (1973).

Heidelberger M, Kendall FE, Hoo CMS: Quantitative studies on the precipitin reaction antibody production in rabbits injected with an azo protein. J Exp Med 58:137-152 (1933).

Johnson GD, Beutner EH, Holborow EJ: Developments in immunofluorescence. The need for standardized procedures. J Clin Path 20:720-723 (1967).

Jones GL, Hebert GA, Cherry WB: Fluorescent antibody techniques and bacterial applications. Centre for Disease Control Laboratory Manual (1978).

Kabat EA, Mayer MM: Agglutination. Experimental Immunochem. 2nd ed. Chapter 3. pp 97-116. Charles C Thomas publisher. Springfield Illinois USA (1964).

Kaplan MH, Coons AH, Deane HW: Localization of antigen in tissue cells. III. Cellular distribution of pneumococcal polysaccharides Types II and III in the mouse. *J Exp Med* 91:1-15 (1950).

Kawamura A Jr: Fluorescent antibody techniques and their applications. 2nd ed. University of Tokyo Press. Tokyo (1977).

Leduc EH, Wicker R, Avrameas S, Bernhard W: Ultrastructural localization of SV<sub>40</sub><sup>T</sup> antigen with enzyme-labelled antibody. *J Gen Virol* 4:609-614 (1969).

Lein D, Erickson I, Winter AJ, McEntee K: Diagnosis, treatment and control of vibriosis in an artificial insemination centre. *JAVMA* 153 (2):1574-1580 (1968).

Liu C: Rapid diagnosis of human influenza infection from nasal smears by means of fluorescein-labelled antibody. *Proc Soc Exp Biol Med* 92:883-887 (1956).

Marrack J: Nature of antibodies. *Nature* 133:292-293 (1934).

Marshall JD, Eveland WC, Smith CW: Superiority of fluorescein isothiocyanate (Riggs) for fluorescent antibody technique with a modification of its application. *Proc Soc Exp Biol Med* 98:898-900 (1958).

Mayersbach H: Unspecific interactions between serum and tissue sections in the FA technique for tracing antigens in tissues. *J Histochem Cytochem* 7:427 (1959).

McDevitt HO et al: Purification and analysis of fluorescein-labelled antisera by column chromatography. J Immunol 90:634-646 (1963).

McKinney RM, Spillane JT, Pearce GW: Fluorescein diacetate as a reference color standard in fluorescent antibody studies. Anal Biochem 9:474-476 (1964).

McKinney RM, Spillane JT, Pearce GW: A simple method for determining the labelling efficiency of fluorescein isothiocyanate products. Anal Biochem 14:421-423 (1966).

McLean JD, Singer SJ: A general method for the specific staining of intracellular antigens with ferritin-antibody conjugates. Proc Nat Acad Sci US. 65:122-128 (1970).

Mellick PW, Winter AJ, McEntee K: Diagnosis of vibriosis in the bull by use of FA technique. Cornell Vet 55:280-294 (1965).

Moody MD, Goldman M, Thomason BM: Staining bacterial smears with fluorescent antibody. I. General methods for Malleomyces pseudomallei. J Bacteriol 72:357-360 (1956).

Moody MD, Ellis EC, Updyke EL: Staining bacterial smears with fluorescent antibody. IV. Grouping streptococci with fluorescent antibody. J Bact 75:553-560 (1958).

Mothershed SM: Effect of the fluorescein to protein ratio on anti-Treponema pallidum conjugates. Appl Microbiol 18:806-809 (1969).



Page RH, Stulberg CS: Immunofluorescence in epidemiologic control of E. coli diarrhea. Am J Dis Child 104:149-156 (1962).

Pital A, Janowitz SL: Enhancement of staining intensity in the fluorescent antibody reaction. J Bact 86:888-889 (1963).

Pittman B, Hebert GA, Cherry WB, Taylor GC: The Quantitation of nonspecific staining as a guide for improvement of FA conjugates. J Immunol 98:1196-1203 (1967).

Pugh GW, Hughes DE, Kohlmeier RH, Wallace JR, Graham CK: Infectious bovine keratoconjunctivitis: Comparison of a fluorescent antibody technique and cultural isolation for the detection of Moraxella bovis in eye secretions. Am J Vet Res 38 (9):1349-1352 (1977).

Pressman D, Yagi Y, Hiramoto R: A comparison of fluorescein and  $I^{131}$  as labels for determining the in vivo localization of anti-tissue antibodies. Int Arch Allergy 12:125-136 (1958).

Reiner L: On the chemical alteration of purified antibody proteins. Science 72:483-484 (1930).

Riggs JL et al. Isothiocyanate compounds as fluorescent labelling agents for immune serum. Am J Path 34:1081-1097 (1958).

Rinderknecht H: Ultra-rapid fluorescent labelling of proteins. Nature 193 (4811):167-168 (1962).

Schiller AA, Schayer RS, Hess EL: Fluorescein-conjugated bovine albumin. Physical and biological properties. J Gen Physiol 36:489-505 (1952).

Silverstein AM, Eveland WC, Marshall JD Jr: Rapid identification of organisms with fluorescent antibodies of contrasting colors. Bact Proc Soc Am Bact (Abstr). p 147 (1957).

Singer SJ: Preparation of an electron-dense antibody conjugate. Nature 183 (4674):1523-1524 (1959).

Smith CW, Marshall JD Jr, Eveland WC: Use of contrasting fluorescent dye as counterstain in fixed tissue preparations. Proc Soc Exp Biol Med 102:179-181 (1959).

Smith CW, Metzger JF, Zacks SJ, Kase A: Immune electron microscopy. Proc Soc Exp Biol Med 104:336-338 (1960).

Stone SS: Production of antiserums to Mycoplasma and preparation of immunofluorescent antibody for the identification of Mycoplasmas. Proc 19th Ann Meeting Am Ass Vet Lab Diagnosticians. Suppl 127-141 (1976).

Taylor CED, Heimer GV: Measuring immunofluorescence emission in terms of standard international physical units. J Biol Standardization 2:11-20 (1974).

Thomason BM, Moody MD, Goldman M: Staining bacterial smears with fluorescent antibody. II. Rapid detection of varying numbers of Malleomyces pseudomallei in contaminated materials and infected animals. J Bact 72:362-367 (1956).

Tokumaru T: A kinetic study on the labelling of serum globulin with fluorescein isothiocyanate by means of the gel filtration technique. J Immunol 89:195-203 (1962).

Weller TH, Coons AH: Fluorescent antibody studies with agents of varicella and herpes zoster propagated in vitro. Proc Soc Exp Biol Med 86 (4):789-794 (1954).

Winter CC, Moody MD: Rapid identification of Pasteurella pestis with fluorescent antibody. II. Specific identification of P. pestis in dried smears. J Infect Dis 104:281-287 (1959).

#### B. OVINE EPIDIDYMITIS

Baynes JD, Simmons GC: Ovine epididymitis caused by Actinobacillus seminis. Aust Vet J 36:454-459 (1960).

Baynes JD, Simmons GC: Clinical and pathological studies of Border Leicester rams naturally infected with A. seminis. Aust Vet J 44:339-343 (1968).

Biberstein EL, McGowan B: Epididymitis in rams. Studies on laboratory diagnosis. Cornell Vet 48:31-44 (1958).

Biberstein EL, McGowan B, Olander H, Kennedy PC: Epididymitis in rams. Studies on pathogenesis. Cornell Vet 54:27-41 (1964).

Blom EA: Interpretation of spermatic cytology in bulls. Fert Steril 1:223-238 (1950).

Braun W, Bonestell AE: Independent variation of characteristics of Brucella abortus variants and their detection. Am J Vet Res 8:336 (1947).

Brown GM, Pietz, DE, Price, DA: Studies on the transmission of Br. ovis infection in rams. Cornell Vet 63: 29-40 (1973).

Buddle MB: Observations on the transmission of Brucella infection in sheep. NZ Vet J 3:10-19 (1955).

Buddle MB: Studies of Br. ovis (n sp). A cause of genital disease of sheep in New Zealand and Australia. J Hyg (Cambridge) 54:351-364 (1956).

Buddle MB, Boyes, BW: A Brucella mutant causing genital disease of sheep in New Zealand. Aust Vet J 29:145-153 (1953).

Cameron RDA, Lauerman LH: Characteristics of semen changes during Br. ovis infection in rams. Vet Rec 99: 231-233 (1976).

Carmichael LE: Canine brucellosis: Annotated review with selected cautionary comments. Theriogenology 6 (2/3): 105-116 (1976).

Clapp KH: A complement fixation test for the diagnosis of ovine brucellosis with special reference to epididymitis. Aust Vet J 31:27-28 (1955).

Clapp KH, Symons LEA, Doolette JB: The application of a complement fixation test to the diagnosis of ovine brucellosis. Aust Vet J 31:29-30 (1955).

Claxton PD, Everett RE: Recovery of an organism resembling Histophilus ovis from a ram. Aust Vet J 42:457-458 (1966).

Cuba-Caparo A, Myers DM: Pathogenesis of epididymitis caused by Br. ovis in laboratory animals. Am J Vet Res 34: 1077-1085 (1973).

Dodd DC, Hartley WJ: A specific suppurative epididymitis of rams. NZ Vet J 12:105-110 (1955).

Ekdahl MO, Money DFL, Martin CA: Some aspects of epididymitis of rams in New Zealand. NZ Vet J 16:81-82 (1968).

Galloway DB: Some aspects of reproductive wastage in rams. Aust Vet J 42:79-83 (1966).

Gamcik and Bogdan (1958). Cited by Biberstein et al 1964.

Glassy FJ, Mostofi FK: Spermatic granulomas of the epididymis. Am J Clin Path 26:1303-1313 (1956).

Graves RS, Engel WJ: Experimental production of epididymitis with sterile urine; clinical implications. J Urol 64:601-613 (1950).

Gunn RMC: Studies in fertility of sheep. Seminal changes affecting fertility in rams. Aust Vet J 18:94-106 (1942).

Hartley WJ, Jebson JL, McFarlane D: The artificial infection of sheep with a Brucella like organism: Part I: The artificial infection of ewes (Hartley et al). NZ Vet J 2:80-85 (1954).

Hartley WJ, Jebson JL, McFarland. Some observations on natural transmission of ovine brucellosis. NZ Vet J 3:5-10 (1955).

Hicks JD et al. CFT inaccurate for epididymitis. NZ Vet J 26 (1/2):34 (1978).

Hoyer BH, McCullough NB: Polynucleotide homologies of Brucella deoxyribonucleic acids. J Bact 95 (2):444-448 (1968a).

Hoyer BH, McCullough NB: Homologies of deoxyribonucleic acids from Brucella ovis, canine abortion organisms and other Brucella species. J Bact 96 (5):1783-1790 (1968b).

Hulet CV: Prediction of fertility in rams: Factors affecting fertility and collection, testing and evaluation of semen. VM/SAC:1363-1364 (1977).

Jamieson S, Soltys MA: Infectious epididymo-orchitis of rams associated with Pasteurella pseudotuberculosis. Vet Rec 59 (27):351-353 (1947).

Jebson et al: Artificial infection of sheep with a Brucella-like organism: Part II. The artificial infection of rams. NZ Vet J 2:85-89 (1954).

Jebson JL, Hartley WJ, McFarlane RC, McClure TJ: Pathology of brucellosis in rams in New Zealand. NZ Vet J 3:100-104 (1955).

Jensen R: Diseases of sheep. Lea and Febiger. Philadelphia. pp 8-13 (1974).

Jubb KVF, Kennedy PC: Pathology of domestic animals. 2nd ed. 1:463-468. Acad Press Inc NY (1970).

Kennedy PCL, Frazier LM, McGowan B: Epididymitis in rams. Pathology and bacteriology. Cornell Vet 46:303-319 (1956).

Keogh J, Doolette JB, Clapp KH: The epidemiology of ovine brucellosis in South Australia. Aust Vet J 34:412-417 (1958).

Lagerlof N: Sterility in bulls. Vet Rec 48:1159-1173 (1936).

Lal Krishna SB et al: Epididymo-orchitis in ram due to Corynebacterium ovis. Indian Vet J. 517-519 (1977).

Laws L, Elder JK: Ovine epididymo-orchitis caused by Actinobacillus lignieresii. Aust Vet J 45:384 (1969).

Laws L, Simmons GC, Ludford CG: Experimental Br. ovis infection in rams. Aust Vet J 48:313-317 (1972).

Lawrence WE: Ovine brucellosis: A review of the disease in sheep manifested by epididymitis and abortion. Br Vet J 117:435-447 (1961).

Livingston CW, Hardy WT: Isolation of A. seminis from ovine epididymitis. Am J Vet Res 25:660-663 (1964).

McFarlane D et al: Investigations into sheep abortion in New Zealand during 1950 lambing season. Aust Vet J 28:221-226 (1952).

McGowan B, Devine DR: Epididymitis in rams. The effect of the naturally occurring disease upon fertility. Cornell Vet 50:102-106 (1960).

McGowan B, Schultz G: Epididymitis in rams. Clinical manifestations and field aspects. Cornell Vet 46:277-281 (1956).

Meyer M, Cameron HS: Studies on the etiological agent of epididymitis in rams. Am J Vet Res 17:495-497 (1956).

Miller SJ, Moule GR: Clinical observations on the reproductive organs of merino rams in pastoral Queensland. Aust Vet J 30:353-363 (1954).

Murray RM: Scrotal abnormalities in rams in tropical Queensland with particular reference to ovine brucellosis and its control. Aust Vet J 45:63-73 (1969).

Myers DM, Siniuk AA: Preliminary report on the development of a diffusion-in-agar gel method for the diagnosis of ram epididymitis. Appl Microbiol 19:335-337 (1970).

Myers DM, Jones LM, Varela-Diaz VM: Studies of antigens for complement fixation and gel diffusion tests in the diagnosis of infections caused by Brucella ovis and other Brucella. Appl Microbiol 23 (5):894-902 (1972).

Orgebin-Crist ME: Studies on the function of the epididymis. Biol Reprod Suppl 1:155-175 (1969).

Pulsford MF, Eastick BC, Clapp KH, Roberts R: Traumatic epididymitis of Dorset Horn and Poll Dorset rams. Aust Vet J 43:99-101 (1967).



Rahaley RS: Pathology of experimental Histophilus ovis infection in sheep. I: Lambs Vet Path 15 (5):631-637 (1978).

Rahaley RS, White WE: Histophilus ovis infection in sheep in Western Victoria. Aust Vet J 53:124-127 (1977).

Ramos AA et al: Epididymitis in rams. A clinical survey in the State of Rio Grande do Sul, Brazil. Abstr Vet Bull 38 (870):1968.

Rao AR: PhD Thesis. Royal Vet Coll. Stockholm Sweden (1971). Cited by Cameron et al (1976).

Shott L, Young S: Autoimmunity in the pathogenesis of infectious ovine epididymitis. Cornell Vet 61:281-296 (1971).

Simmons GC, Baynes ID, Ludford GG: Epidemiology of A. seminis in a flock of Border Leicester sheep. Aust Vet J 42:183-187 (1966).

Simmons GC, Hall WTK: Epididymitis of rams. Aust Vet J 29:33-40 (1953).

Snowdon WA: Opening of discussion on ovine brucellosis. Aust Vet J 34:417-422 (1958).

Stoenner HG, Lackman DB: A new species of Brucella isolated from the desert wood rat, Neotoma lepida Thomas. Am J Vet Res 18:947-951 (1957).

Swanson EW, Boyd LJ: Factors affecting coiled-tail spermatozoa in the bull. Am J Vet Res 23:300-309 (1962).

Van Rensburg SWJ et al: Infectious infertility in sheep. JS Afr Vet Med Ass 29:223-233 (1958).

Van Tonder EM: Examination of rams for genital soundness. JS Afr Vet Med Ass 48:267-272 (1977).

Van Tonder EM, Bolton TFW: Epididymitis in rams caused by A. seminis. JS Afr Vet Med Ass 39:87-90 (1968).

Van Tonder EM, Bolton TFW: The isolation of A. seminis from bovine semen: A preliminary report. JS Afr Vet Med Ass 41:287-288 (1970).

Watt DA: Investigations of ovine brucellosis in merino rams of western Australia. Aust Vet J 46:506-508 (1970).

Watt DA: Testicular abnormalities and spermatogenesis of the ovine and other species. Vet Bull 42:181-190 (1972).

Watt DA, Bamford V, Nairn ME: A. seminis as a cause of polyarthrititis and posthitis in sheep. Aust Vet J 46:515 (1970).

White PG, Wilson JB: Differentiation of smooth and nonsmooth colonies of brucellae. J Bact 61:239-240 (1951).

Wilson GS: A classification of the Brucella group: A systematic study. J Hyg 33:516-541 (1933).

Worthington RW, Bosman PP: Isolation of A. seminis in South Africa. JS Afr Vet Med Ass 39:81-85 (1968).

## APPENDICES

## APPENDIX A

## Conjugating Globulin with Fluorescein Isothiocyanate

The method of Jones et al (1978) was used. This involved a relatively high fluorescein to protein ratio (F:P) of 25 to 30 ug/mg for antibacterial conjugates of  $(\text{NH}_4)_2 \text{SO}_4$  fractionated antiserum.

Under optimal conditions temperature 25 C; pH 9.5; and 0.05M  $\text{Na}_2 \text{HPO}_4$ , the labelling efficiency of 100% FITC with gamma globulin is approximately 60% when the reaction is allowed to proceed to completion. However,  $(\text{NH}_4)_2 \text{SO}_4$  fractions of antisera are not pure gamma globulins. The average fraction is 70% gamma globulin with 30% beta and alpha globulins, and it has a labelling efficiency of approximately 75% due to the greater affinity of beta and alpha globulins for the dye.

The weight of dye used to label and the resulting F:P ratio were expressed as  $\mu\text{g}$  FITC per mg protein. Therefore, the amount of FITC used for labelling was the desired F:P ratio divided by the labelling efficiency of the protein. In order to label 10 ml of the  $(\text{NH}_4)_2 \text{SO}_4$  extracted globulin, the weight of FITC needed was calculated.

- a. Biuret test: Protein = 13 mg/ml (A. seminis)
- b. 10 ml protein solution contained 13 mg/ml x 10 ml =  
130 mg protein

$$c. \frac{\text{Desired F:P Ratio}}{0.75} = \frac{25}{0.75} = 33.3 \text{ } \mu\text{g FITC/mg protein}$$

$$d. 33.3 \text{ } \mu\text{g FITC/mg protein} \times 130 \text{ mg protein} = 4,329 \text{ } \mu\text{g} = 4.329 \text{ mg FITC}.$$

The FITC was dissolved in 5 ml buffer (0.1M  $\text{Na}_2 \text{HPO}_4$ , pH 9) in a 10 ml beaker. The solution was mixed by a magnetic stirrer until the FITC completely dissolved.

Ten ml protein solution was pipetted into a 25 ml beaker and placed over a magnetic stirrer. While gently stirring, 2.5 ml of 0.2M  $\text{Na}_2 \text{HPO}_4$ , (pH 9) was added slowly and the dissolved FITC was slowly added to the buffered protein. The pH of the mixture was immediately determined and was adjusted to pH 9.5 by adding 0.1M  $\text{Na}_3 \text{PO}_4$  drop by drop. Sterile saline (0.85% NaCl) was added to bring the final volume to 20 ml.

The final solution of each conjugate was gently mixed by a magnetic stirrer at 25C for 2 1/2 hours labelling time. It was then centrifuged at 9,770g for 15 minutes to remove any precipitate formed during conjugation, before removing unreacted fluorescein material (UFM).

## APPENDIX B

## Removal of Unreacted Fluorescein Material

All UFM from the Br. ovis conjugate was removed by gel filtration.

a. Preparation of Gel

60 gm of Sephadex (G25)\* was weighed, dissolved in 500 ml PBS and left overnight at 25C.

b. Packing the Column\*\*

A 25 mm diameter, 90 mm long tubing was connected to a shorter chromatographic column, using internal ring link and external ring screws. The apparatus was connected vertically to a stand in a cold room (5C). The column was filled with PBS and left overnight to detect any leakage.

PBS in the column was released by opening the lower end. This end was closed and the swollen Sephadex was carefully agitated before being introduced a little at a time into the column. When a layer of about 15 mm had settled, the end was opened to start the column draining. The remaining Sephadex was then slowly added and periodically stirred to maintain a uniform suspension until the desired settled height was obtained. When the column was 2.5 cm

---

\* Pharmacia Fine Chemicals AB, Box 175, S-75104 Uppsala 1, Sweden.

\*\*Peters H: Construction and use of a small Sephadex column for the separation of fluorescent antibodies. Stain Tech 38:260-262 (1958).

from the top of the shorter chromatographic column, the tap was closed and the longer piece was detached, while ensuring that about 2.5 cm PBS was above the column.

The PBS was slowly drained to the level of the gel and a piece of filter paper was placed on top of the gel to prevent any disturbance or indentation of the surface while introducing solutions.

PBS (pH 9) was added to the column and allowed to drain out until fine particles of Sephadex were completely eliminated from the column. The fluid level was never allowed to fall below the top of the column. Above the Sephadex column, the tube was filled with PBS and then closed at both ends until used.

### c. Chromatography

Before commencing gel filtration, the fluid level was lowered to the filter paper. Three ml conjugate was then gently introduced, using a syringe with an 8 cm capillary tube connection. The tap was opened. When the entire conjugate had entered the column and the fluid level was just below the filter paper, 2 ml of PBS were first added onto the filter paper. When this had drained through the filter paper, the column was filled with PBS.

The color of the free dye facilitated its separation from the fluorescein-conjugated gamma globulin. Within the

column, the conjugate rapidly separated into two bands-- a lower band of gamma globulin migrating ahead of an upper band of UFM.

The eluate was collected in the dark with the aid of a portable ultraviolet lamp.\*\*\* Collection began when the first fluorescent solution started draining and was stopped when fluorescence faded. The eluate was collected in labelled tubes, each containing 2-3 ml and stored at -70C.

PBS was added continuously to the column until all UFM was completely washed from the column. The rest of the conjugate was similarly treated.

The column was dismantled and the swollen Sephadex was thoroughly washed with water. After removal of excess water, the gel was dehydrated by successive addition of alcohol solutions of increasing percentage. The gel was allowed to equilibrate in between each addition. Final shrinking was done with 95% alcohol. The gel was then washed with diethyl ether to reduce the drying time. The gel was sucked dry on a Buchner funnel and finally dried at room temperature.

---

\*\*\*Compact 4-watt UV Lamp, Ultra-Violet Products, Inc., San Gabriel, Ca. 91778 USA.



IMMUNOFLUORESCENT DIAGNOSIS OF OVINE EPIDIDYMITIS

by

CHRISTOPHER OLUSEGUN AJAI

D.V.M., University of Ibadan, Nigeria, 1974

---

AN ABSTRACT OF A THESIS

submitted in partial fulfillment of the

requirements for the degree

MASTER OF SCIENCE

Department of Pathology

KANSAS STATE UNIVERSITY  
Manhattan, Kansas

1980

Bacterial epididymitis, an acute or chronic disease of major importance in sheep raising countries, has a number of causes, the main one being Brucella ovis. It is clinically difficult to differentiate Brucella epididymitis from that due to Actinobacillus seminis, Corynebacterium pseudotuberculosis, Corynebacterium pyogenes, Staphylococcus aureus, and other bacteria. The discovery of A. seminis in the U.S. complicates brucellosis control and eradication programs in sheep. Diagnosis of ovine epididymitis has been based on clinical signs, scrotal palpation, pathological and serological findings, and evaluation and bacteriological examination of semen. The impracticability and unreliable nature of semen culture and inadequacy of physical examination has resulted in serological methods being the most dependable single aid in detecting infection in flocks and individual rams. This study was undertaken to investigate immunofluorescence in semen for diagnosing ovine bacterial epididymitis, especially A. seminis.

Specific antiserums against A. seminis, Br. ovis, and C. pseudotuberculosis were prepared in adult female goats. The organisms were grown in Brain Heart Infusion broth at 37C in an atmosphere of CO<sub>2</sub> for 48 hours, centrifuged twice and suspended in formalized PBS, and mixed with an equal volume of Freund's complete adjuvant. Two goats were injected intramuscularly with 2 ml adjuvant suspension for each organism weekly for four weeks. Antibody titers,

determined by tube agglutination, were A. seminis (1:128), Br. ovis (1:64), and C. pseudotuberculosis (1:64). The gamma globulins were precipitated with saturated ammonium sulfate at 25C. The protein content was determined by Biuret test. The globulins were conjugated with fluorescein isothiocyanate and unreacted fluorescein was removed by dialysis and by gel filtration.

Immunochemical analysis of unlabeled and labeled globulins by electrophoresis revealed over 80% gamma globulin and small amounts of alpha and beta globulins, and no albumin.

Specific immunofluorescence was observed in cultural smears of A. seminis, Br. ovis, and C. pseudotuberculosis by the direct techniques and A. seminis also by the indirect technique. Specific fluorescence of A. seminis was readily detected in semen. In these studies, individual organisms could be recognized. Even in semen smears, the yellow autofluorescence of the sperm heads did not interfere with recognition of green fluorescence of A. seminis; the former, however, may be removed by prior absorption of dilute conjugate with testis powder.

Good results were obtained with the three IF systems, although they were prepared from antiserums with relatively low antibody titers. It is concluded from these studies that IF techniques are effective for rapid and accurate diagnosis of bacterial epididymitis in sheep.