

HISTOPATHOLOGICAL CHANGES IN THE INTESTINE
OF NEONATAL CALVES AS A RESULT OF
NATURALLY OCCURRING DIARRHEA

by

T. R. Hathaway

B.S., Kansas State University, 1970
D.V.M., Kansas State University, 1972

A MASTER'S THESIS

submitted in partial fulfillment of the

requirements for the degree

MASTER OF SCIENCE

Department of Surgery and Medicine

KANSAS STATE UNIVERSITY
Manhattan, Kansas

1979

Approved by:

Neil V. Anderson DVM
Co-Major Professor

J.M. Knuckenberg DVM
Co-Major Professor

Document
LD
2668
.T4
1979
H39
C. 2

TABLE OF CONTENTS

	Page
LIST OF TABLES	111
LIST OF FIGURES	iv
ACKNOWLEDGEMENTS	vi
INTRODUCTION	1
LITERATURE REVIEW	2
Bacteria	2
Viruses	4
Protozoa	6
Mixed Infections	7
MATERIALS AND METHODS	8
RESULTS	13
DISCUSSION	16
CONCLUSIONS	22
REFERENCES	54
APPENDIX	55
List of Tables	56

LIST OF TABLES

Table		Page
G-1	General appearance, totals	48
G-2	Intraluminal exudate, totals	48
G-3	Differentiated epithelium, totals	49
G-4	Undifferentiated epithelium, totals	50
G-5	Intercellular elements, totals	51
G-6	Lamina propria, totals	52
G-7	Submucosa, totals	53
G-8	Funica muscularis, totals	53

LIST OF FIGURES

Figure	Page
1. Slide Evaluation Index	24
2. Duodenum	26
3. Ileum	26
4. Large Bowel	28
5. Valve of Kerckring	28
6. Abomasum	28
7. Eosinophilic Droplets	30
8. Mitotic Figures	30
9. Eosinophilic Granules	30
10. Dilated Crypts	32
11. Dilated Crypts	32
12. Epithelial Cysts	34
13. Intraluminal Non-Invasive Fungus	36
14. Fibrinous Exudate	36
15. Submucosal Edema	38
16. Submucosa - No Edema	38
17. Edema of Tunica Muscularis	40
18. Tunica Muscularis - No Edema	40
19. Apical Junctional Complex Separation	42
20. Marked Submucosal Edema	42

LIST OF FIGURES (Continued)

Figure		Page
21.	Identification of Causative Agents in Twenty Neonatal Calves with Naturally Occurring Diarrhea	43
22.	Flow Chart of Laboratory Diagnosis	44
23.	Results of Comparison of Histopathology of Calves to the Criteria in the Literature Review	45
24.	Flow Chart Results of Histology of Calves Fit to Literature Review	46
25.	Comparison of Results of Histology of Calves Fit to Literature Review Against Laboratory Diagnosis	47

ACKNOWLEDGEMENTS

The assistance and understanding of Drs. Anderson, Kruckenber, and Vestweber was very much appreciated. I am equally grateful to Val Gaeth for her help in collating the data, to SRS for funding, and to my family, Maren, Marc, and Brock for their understanding.

Above all others, thanks be to God for giving us all so much when we deserve so little.

INTRODUCTION

There are many causative agents associated with the disease complex in calves which is manifested by diarrhea. An infectious agent may be the primary etiologic factor in the development of a lesion in the intestine. This lesion may result in increased secretion and/or decreased absorption, or a motility disturbance. These changes result in a net loss of total body fluids and electrolytes. This loss of fluid and electrolytes is, in most cases, the cause of death since the effects of the infectious agent are usually reversible.

Histopathologic changes in the intestine of calves affected with diarrhea are related to the cause of diarrhea. In addition to the changes caused by the primary etiologic agent, histopathologic changes occur also in response to tissue damage caused by the agent. Secondary or opportunistic agents also elicit these two types of responses.

This thesis will present the hypothesis that the class of etiologic agent can be predicted with reasonable accuracy on the basis of intestinal histopathology alone. This study will compare histopathologic findings with the results of fluorescence microscopy in naturally occurring neonatal calf diarrhea.

LITERATURE REVIEW

The primary, most frequently isolated, agents in the neonatal calf diarrhea complex are bacteria, viruses and protozoal organisms. There are many other factors involved in the pathogenesis of diarrheal disease.

Bacteria are known to be both primary and secondary invading agents in neonatal calf diarrhea. E. coli, Salmonella sp., and Clostridium perfringens type B and C are bacteria which are frequently identified in the neonatal calf diarrhea complex.

Viruses of major importance include rotavirus and coronavirus. Other viruses which have been isolated from calves with diarrhea include parvovirus, bovine virus diarrhea virus, infectious bovine rhinotracheitis virus, bluetongue virus and enteroviruses (9).

Eimeria is the genus of coccidial organisms that is commonly identified in the calf diarrhea complex (9). Cryptosporidia are also commonly identified by light microscopy of tissues. The consistent, intimate association of microvillus damage with cryptosporidia is presumptive evidence that damage is caused by the cryptosporidia and this damage to microvilli can result in diarrhea (7).

Bacteria

Naturally occurring colibacillosis may be either endotoxemic, septicemic, or enteropathogenic. The young calf affected

with either the endotoxemic or septicemic form frequently dies. Meningoencephalitis and arthritis are associated with many cases of septicemic colibacillosis.

The ability of enteropathogenic E. coli to cause diarrhea depends on two important factors - colonization and the production of enterotoxins (10). Microscopically, this form of colibacillosis usually produces minimal tissue alterations. Edema of the lamina propria of the villi may be present. There may also be dilatation of the central lacteal. Leukocytic exudation or infiltration is unpredictable. Capillary congestion in the superficial mucosa often occurs. Epithelial erosion is minimal unless the capillaries become occluded by a platelet plug. This epithelial erosion tends to be associated with a hemorrhagic enteritis (2) of patchy distribution, usually not involving more than 30 to 45 cm of the small intestine in the duodenum. Goblet cells are partially or totally evacuated and large numbers of bacteria adhere to the glycocalyx. Microscopic changes which occur in other organs include congestion and hemorrhage in the meninges and brain (2).

While calves that receive colostrum are more resistant to the septicemic form than colostrum-deprived calves, both are susceptible to bacterial overgrowth in the gut and may die from the effects of endotoxin. The bacteria can localize in either the gut or the regional lymph node (2).

Salmonellosis may cause diarrhea in calves, as part of an acute febrile illness. In the peracute form of salmonellosis,

diarrhea is not a clinical sign because the survival time is very short.

Species of Salmonella, frequently isolated, are: typhimurim, dublin, newport, st. paul, and heidelberg (2).

Moderately severe gastrointestinal inflammation, acute swelling and hemorrhage of the visceral lymph nodes, and scattered petechiation of serous membranes are gross pathologic changes noted in salmonellosis. The exudate is ordinarily catarrhal. It may, however, be hemorrhagic and contain yellowish, easily detachable, deposits of mucin and fibrin. The mucosa overlying the lymphoid tissue may become necrotic and slough. Fibrin casts may be passed with the fecal material (2).

The predominant lesions of Clostridium perfringens type C enteritis are located in the jejunum. They occur less frequently in the ileum or duodenum. The large bowel is not affected. Hyperemia and congestion of the intestine is the first notable sign of inflammation. Secondary changes may include extensive necrosis of the epithelium and, in some cases, emphysema of the intestinal wall. Necrosis may extend through the epithelial layer and may include the muscularis mucosa. The histologic changes seen with Clostridium perfringens type D enteritis are loss of superficial epithelial cells, congestion of the mucosa and numerous bacilli in the lumen of the affected bowel (2).

Viruses

In the calf affected with rotavirus, viral replication is confined to small intestinal absorptive epithelium, i.e. cells

in the "upper" half of the villus. Light microscopy shows shortened, blunted villi with increased numbers of round cells in the lamina propria. Epithelial cells at the tips of villi tend to be cuboidal, rather than columnar, and some cells may show cytoplasmic vacuolation (6).

In the enteric epithelium, cell division occurs only in the crypts of Lieberkühn where the activity of enzymes involved in DNA synthesis, such as thymidine kinase, is high (11). The tip of the villus is associated with an increase digestive enzyme activity (8). β -galactosidase activity is maximal in the mature cells at the tip of the villus and is localized in glycocalyx (microvillus or brush border) in man, hamster, rat and probably in the calf (1).

Villus tip cells in rotavirus-infected animals are rich in thymidine kinase. The digestive enzyme activity profiles of sucrase and β -galactosidase are lower. This change in the enzyme profile more closely resembles that of an immature crypt cell (6).

In the lamina propria of rotavirus-infected calves, reticulum-like cells are present in higher numbers than in the lamina propria of control calves. There is a concomitant increase in the numbers of pyknotic nuclei and also in the number of eosinophils present (5).

Initially, in coronavirus infection, the only histopathologic change in the intestine is the presence of viral antigen in the villus epithelial cells. Antigens are identified by

immunofluorescent microscopy. The presence of viral antigen has not been observed in crypt epithelium. Forty-two to 96 hours after the onset of diarrhea, bridging and shortening of the villi are detectable with the light microscope. Cuboidal epithelial cells are also observed. These cells are immunofluorescence-positive for coronavirus (3). At 48 hours post-onset of diarrhea, villi become noticeably shortened, a small vacuole appears in the cytoplasm of the cells at the tip of villus, and the villus cytoplasm becomes more dense (4). Beyond 96 hours after diarrhea begins, the number of immunofluorescent cells decreases. Histopathologic changes present are atrophy of colonic ridges in the spiral colon and dilated colonic crypts, lined by cuboidal to low columnar epithelium (3).

Protozoa

Two species of the genus *Eimeria* are associated with neonatal calf diarrhea. *E. zurnii* and *E. bovis* are frequently isolated coccidia that are known pathogens of calves.

Schizogony occurs in the small intestinal epithelial cells, primarily in the jejunum and ileum. Each schizont is small and produces only a few merozoites. Very large numbers of gametes are required to cause diarrhea so more than one schizogonous phase is necessary. The merozoites released from the schizonts then penetrate the aboral epithelium.

The usual lesion of coccidiosis is a catarrhal inflammation with various degrees of superficial necrosis if accompanied by bacterial infection. Extensive denudation of the surface of villi and crypts is an indication of heavy infestation. Proliferative overcompensation for lost cells, together with edema, congestion, and leukocytic infiltration, results in a thickened mucous membrane (2).

Cryptosporidia are minute coccidial parasites that occupy the apical border of enterocytes (11). They are encased by host cell membrane (12). Due to this host-parasite association, they undoubtedly derive their nutrients from the host cell rather than from intestinal chyme (11).

Mixed Infections of the Intestine

Additive or synergistic interactions that increase the severity of pathologic changes may occur during mixed infections. Enhanced proliferation of E. coli in the intestine, predisposition to bacteremia, accelerated damage to and delayed regeneration of villus epithelium occur as the result of mixed infections with rotavirus and E. coli in gnotobiotic calves (5). Changes in villus height-crypt depth ratios also occur (1).

The factors involved in the etiology of the calf diarrhea complex include nutritional status and motility disturbances as well as the agents mentioned above. A further complication is suppression of the immune status of the calf by the etiologic agents of calf diarrhea.

MATERIAL AND METHODS

One hundred and sixty-eight neonatal calves, purchased at a community auction market in southwestern Wisconsin, were studied in a drug efficacy trial. One hundred and fifty-two of the original group developed diarrhea of which 46 died naturally or were euthanatized in extremis to prevent post-mortem degeneration. Twenty calves from this latter group were selected at random and assigned, with a blind code, to a histopathologic study.

The calves were four to nine days old when purchased. The stresses were fatigue, fasting, co-mingling and chilling as they were loaded in an enclosed truck and transported 600 miles nonstop to Manhattan, Kansas, in 16 hours. Calves were assigned to individual hutches in the order of their removal from the truck. Seven groups of 24 calves each were studied.

Hutches were arranged on a hillside with a minimum of seven m between hutches in all directions. After each group of 24 calves had been studied for 15 days, calves were evacuated and the hutches were sanitized and relocated one and two-tenths m uphill or laterally to minimize the possibility of contamination between groups.

Fecal specimens were collected when the initial finding of diarrhea was made during daily physical examination. Sterile

disposable polyethylene gloves were worn and defecation was initiated by stimulation at the dorsal aspect of the rectum by insertion of a digit. Ten to 25 gm of feces were collected in each of two paper containers. One aliquot was refrigerated immediately for bacteriologic culture, the other was frozen for fluorescence microscopy for rotavirus and coronavirus.

Initial isolation of fecal organisms was done on blood agar, MacConkey's agar and selenite-brilliant green broth. Broth cultures were transferred to MacConkey's agar.

Complete necropsy examination was done as soon as possible after death. Calves that were unable to arise following vigorous squeezing of the lumbar area were considered to be in extremis and were euthanatized with an intravenous dose of euthanasia solution.* Calves that did not arise following squeezing of the lumbar region were lifted to an upright position only if they seemed reasonably alert. If the calf remained erect, it was observed again later.

Tissues chosen for histopathologic examination were fixed in 10% buffered neutral formalin and processed by standard methods. Six sections of the gastrointestinal tract were taken for histopathologic studies. A tissue sample of abomasum was taken from the greater curvature. Duodenal tissue was obtained from the area midway between the pylorus and the root of the mesentery. Jejunal tissue was taken from the midjejunal area.

*1-61^R, National Laboratories Corp., Somerville, N.J. 08876

Samples of ileum were taken from an area 20 cm orally from the cecum. Samples of cecum and spiral colon were obtained from areas in each organ, respectively, near the center of that organ.

Tissue identification was completed using the following guidelines:

Abomasum (Figure 6, page 28)

1. Absence of villi.
2. Absence of goblet cells.
3. Eosinophilic cytoplasm (epithelial cells).
4. Broad tunica muscularis.

Duodenum (Figure 2, page 26)

1. Presence of villi.
2. Length of villi (longest villi in small bowel).
3. Branching of villi (high degree of foliation of villi).
4. Brunner's glands (seen in duodenum and much less frequently in the jejunum).

Jejunum

1. Presence of villi.
2. Length of villi (proportionally shorter than duodenal villi).
3. Branching of villi (proportionally less foliation than duodenum).
4. Brunner's glands (occur only rarely in jejunum).

5. Peyer's patches (occur rarely in jejunum).

Ileum (Figure 3, page 26)

1. Presence of villi.
2. Length of villi (shortest villi in the small bowel).
3. Foliation of villi (smallest degree of foliation).
4. Peyer's patches (seen in the ileum but much less frequently in the jejunum).

Large Bowel (Figure 4, page 28)

1. Absence of villi.
2. Presence of goblet cells (marked).
3. Spiral colon and cecum (indistinguishable histologically).
4. Epithelial cells (basophilic cytoplasm).

Another criterion used for identifying tissues was:

Valves of Kerckring (Figure 5, page 28)

(present in small bowel and not present in large bowel).

After tissue identification to the highest degree of certainty possible the slides were examined microscopically and histopathologic changes in the criteria listed in Figure 1 (page 24) were rated. The basis for an explanation of the grading system is included in the Appendix.

The histologic data were also compared, subjectively, to the literature review composite. If one category predominated in pattern of changes, the calf was assigned to that category. If the two categories were equally dominant, the etiology was described as mixed and the calf was assigned to both categories. If the three categories appeared equally likely the calf was assigned to each of the three categories.

RESULTS

Each of the 20 calves (100%) chosen at random for the histopathologic study, were positive for E. coli as determined by the techniques described in Material and Methods. Cryptosporidia were identified in gut tissues of eight of the 20 calves (40%). In three of eight calves, cryptosporidia were identified in three of six slides. Three calves were positive for cryptosporidia on two of six slides, but only on one of six slides in two of the calves (50%) that were immunofluorescence positive to viral antigen. The viral antigen positive calves were categorized as follows: only coronavirus antigen (2 - 50%), only rotavirus antigen (1 - 25%), or both coronavirus and rotavirus antigen (1 - 25%). None of the four cryptosporidia-positive calves (0%) were immunofluorescence-positive to bovine virus diarrhea antigen. (See Figure 22).

Twelve of 20 calves (60%) were classified as cryptosporidia-negative. Two of the 12 calves (16.67%) were classified non-viral, again on the basis of negative immunofluorescence. The remaining ten calves (83.33%) were immunofluorescence-positive to only coronavirus antigen (4 - 40%), only rotavirus antigen (2 - 20%), or both coronavirus and rotavirus antigen (2 - 20%). Two of 10 calves (20%) were positive to bovine virus diarrhea antigen.

The data were tabulated and are presented in table form.

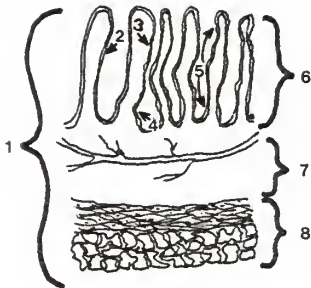
The tables are identified in the following manner:

1. A letter (A-F) is indicative of an etiologic classification, which is as follows:

- A - Coronavirus negative, rotavirus negative
- B - Coronavirus negative, rotavirus positive
- C - Coronavirus positive, rotavirus positive
- D - Coronavirus positive, rotavirus negative
- E - Bovine virus diarrhea positive, others unspecified
- F - Cryptosporidia positive, others unspecified

These tables are in the appendix beginning on page 63.

2. A number (1-8) is indicative of that portion of the microscopic anatomy of the intestinal wall which was examined. The numbers and the area they are associated with are illustrated in the following diagram:



Tables G-1 to G-8 present the data collated according to categories thought to be indicative of cause. The data are presented as two numbers, the first number being the total number of slides that were classified as having moderate or marked change in the characteristic noted. The second number is the total number of slides observed under that category. The letters, A-F, are representative of the etiologic classification described previously (page 14, paragraph 1).

DISCUSSION

The data are summarized in tables G(1-8), pages 48-53. The results of a comparison to the laboratory diagnosis and of a comparison to the review of literature are discussed below.

Comparison of Histopathologic Data to Laboratory Diagnosis

Lymphocytes in the gut tissue, when observed in a scanning mode by light microscopy are a good characteristic (Table G-1) for differentiating the etiologic categories (listed on page 14 paragraph 1), B, C and E from the other categories. A is a category in which lymphocytes are lower than in B, C, E. Category A is designated as the "bacterial infection" category on the basis of exclusion of coronavirus, rotavirus, and bovine virus diarrhea virus. Other viral agents or chlamydia have not been excluded.

Neutrophils appear to be substantially greater in category C than in others. Erythrocyte infiltration is lower in category A (bacterial). Eosinophilia is lower in category D. Monocytes and macrophages are not good indicators because of uniformity in all categories. Edema, parasites and bacteria in this area are not helpful in differentiation of etiology.

Intraluminal exudates (Table G-2) are of little value in differentiating etiologies. There is little difference between etiologies within types of exudate.

In table G-3, increased pyknosis of differentiated epithelial cells occurred in category B, as opposed to lack of that change in other categories. Vacuolation and cell lysis of tips of villi, which are uniform in all categories, are not good etiologic indicators.

A study of the undifferentiated epithelium (Table G-4) indicates that there is more lysis of undifferentiated crypt epithelial cells in category D. The lysis of undifferentiated cells is expected to predominate in the crypts because undifferentiated cells reside in the crypts. Cuboidal cells are a lower percentage of total epithelial cells observed in category C than in other categories. Proportions of cytoplasmic granules and mitotic figures are not different between categories.

Separation of tight junctions (apical junctional complexes) is lower in category A, "bacterial infection." Dilated crypts are more often observed in category E, bovine virus diarrhea positive. There is no indication that the intercellular elements - lymphocyte, neutrophil, macrophage, globule leukocyte and eosinophil - are good indicators of cause.

Lymphangiectasia was most pronounced in cryptosporidia infected and "bacterial infected" calves. Villus blunting was frequent in coronavirus positive - rotavirus positive calves, suggesting that the dual infection had caused greater loss of villus epithelial cells. Infiltrates of the lamina propria which could aid in distinguishing between causes

include: lymphocyte (higher in B and E than in the other categories), neutrophil (higher in category C - coronavirus positive, rotavirus positive), plasma cell (lowest in A, "bacterial infected"), and eosinophil (higher in categories E - bovine virus diarrhea - and F - cryptosporidia - and lower in category A).

On Table G-7, submucosal edema was seen on a lower proportion of slides in category B - rotavirus positive calves. Neutrophils are higher in categories D and C. The erythrocyte numbers are lowest in categories B and E. Monocytes, macrophages, and plasma cells show only slight differences between categories. Eosinophils do not show differences between categories.

In the tunica muscularis (Table G-8), neutrophils are most frequently associated with the coronavirus positive, rotavirus negative category. Higher numbers of plasma cells are most frequently associated with slides from calves that are bovine virus diarrhea positive. An increase in erythrocytes is noted in the group that is rotavirus positive and coronavirus negative. The changes in eosinophils and edema, from category to category, are unremarkable.

Trends that appear in reviewing the data are as follows:

- A. "Bacterial diarrhea" - category A, coronavirus negative, rotavirus negative.

In the general appearance category fewer slides showed evidence of lymphocyte infiltration. Lymphangiectasia was pronounced in more slides. The number of slides on which separation of apical tight junctions was noted was increased. Fewer

slides show erythrocyte infiltration in both the general appearance table and the table of changes in the submucosa.

- B. "Dual infection" - category C, coronavirus positive, rotavirus positive.

Neutrophilia in general and specifically in the submucosa is seen on relatively more slides in this category. A similar increase is seen in the degree of villus blunting. An increase in the number of slides upon which cuboidal epithelial cells is noted is not apparent.

- C. Category E - bovine virus diarrhea positive.

Based upon the number of slides that were graded as moderate and marked, increased in numbers of plasma cells and lymphocytes are seen in the lamina propria. In the same manner, erythrocytes are increased in the submucosa.

- D. Category F - cryptosporidia positive.

The most important criteria which places an individual in this category is location of the organism. An increase in the number of slides upon which lymphangiectasia is evident, is also noted in this category.

These differences are not clear-cut but are helpful in raising the possibility that one or another category of etiologic agents is implicated.

Comparison of Data to Composite of Literature Review

The results of the histological examination of the 20 calves were, again, blind coded and then compared to a list of criteria gathered from the literature review. The criteria used as a basis for a diagnosis of bacterial diarrhea are:

1. edema of the lamina propria
2. dilated lacteals
3. variable leukocytic infiltration
4. capillary congestion of the mucosa
5. bacteria adhering to the glycocalyx

The criteria used as a basis for a diagnosis of viral diarrhea are:

1. shortened villi with bridging
2. increased round (mononuclear) cells
3. cuboidal epithelial cells
4. cytoplasmic vacuolation
5. increased pyknotic nuclei in epithelial cells
6. increased eosinophils
7. dilated crypts

The criteria used as a basis for a diagnosis of protozoal diarrhea are:

1. catarrhal inflammation
2. superficial necrosis
3. edema
4. congestion
4. leukocyte infiltration

Seventeen of the calves (17/20) had attributes of the viral category. Three of the viral-classified calves (3/17) also fit well in the bacterial category. The bacterial group was resolved further to protozoal (1/3) and non-protozoal diarrhea (2/3). The non-bacterial classification (14/17) was further resolved to protozoal (3/14) and non-protozoal (11/14) diarrhea.

Three of the calves (3/20) appeared to fit the classification of non-viral diarrhea. Two of these calves (2/3) fit the bacterial classification and one of them (1/3) fit the protozoal classification.

CONCLUSIONS

1. The histopathologic study indicated that certain changes were highly indicative of the etiologic classification.

A. "Bacterial diarrhea."

Lymphocyte infiltration, lymphangiectasia, and erythrocyte infiltration were all seen on a greater proportion of slides.

B. "Dual infection."

Neutrophilia and an increase in villus blunting were noted frequently in this category.

C. Bovine virus diarrhea positive.

Increased numbers of plasma cells, lymphocytes, and erythrocytes were identified on greater numbers of slides.

D. Cryptosporidia positive.

Presence of the organism and lymphangiectasia were common characteristics of this category.

2. The composite of the literature review underestimated the number of calves that did have "bacterial diarrhea" (five of 20 - 25%). The contemporary literature focuses on viral etiologies. We might hypothesize that the attributes of "bacterial diarrhea" are ascribed to "viral diarrhea" when, actually, a mixed infection exists.

3. The composite of the literature review estimated "viral diarrhea" very well (15 of 17 - 88.24%) as compared with the laboratory data.

4. The composite of the literature review estimated "protozoal diarrhea" relatively poorly (two of eight - 25%), although eight calves is a small sample of the population of calves that do have "protozoal diarrhea".

Figure 1

I. Architecture - General Appearance
entities that can or do occur
transmurally

A. Infiltrates	N	S	M	M
1. Lymphocyte				
2. Neutrophil				
3. Monocyte				
4. Macrophage				
5. Plasma Cell				
6. Fibrocyte				
7. RBC				
8. Eosinophil				

II. Specific Areas

A. Intraluminal Exudates (+-)		
1. Fibrinous		
2. Catarrhal		
3. Necrotic		
4. Hemorrhagic		
5. Lytic		
6. Purulent		

B. Epi. cell population				
1. Erosion				
2. -Plasia				
3. -Trophy				
4. Pigment				
5. Inclusions				

C. Individual diff. epi. cells				
1. Pyknosis				
2. Karyorrhexis				
3. Karyolysis				
4. Vacuolization				
5. Cell shape				
6. Lysis				
7. Cytoplasmic granules				

D. Individual undiff. epi. cells				
1. Pyknosis				
2. Karyorrhexis				
3. Karyolysis				
4. Vacuolization				
5. Cell shape				
6. Lysis				
7. Cytoplasmic granules				
8. Mitotic figures				

E. Intercellular Elements

1. Lymphocyte				
2. Neutrophil				
3. Macrophage				
4. Globule leukocyte				
5. Eosinophil				

F. Apical Junctional complex

1. Separation				
---------------	--	--	--	--

G. Lamina propria

1. Lymphangiectasia				
2. Crypt abscesses				
3. Villus blunting				
4. Villus bridging				
<u>Infiltrates</u>				
5. Lymphocyte				
6. Neutrophil				
7. Monocyte				
8. Macrophage				
9. Plasma Cell				
10. Fibrocyte				
11. RBC				
12. Amyloid				
13. Eosinophil				

H. Tunica Muscularis

1. -Trophy				
2. Lymphocyte				
3. Neutrophil				
4. Monocyte				
5. Macrophage				
6. Plasma Cell				
7. Fibrocyte				
8. RBC				
9. Amyloid				
10. Eosinophil				
11. Edema				

I. Submucosa

1. <u>Edema</u>				
<u>Infiltrates</u>				
2. Lymphocyte				
3. Neutrophil				
4. Monocyte				
5. Macrophage				
6. Plasma Cell				
7. Fibrocyte				
8. RBC				
9. Amyloid				
10. Eosinophil				

J. Dilated Crypts

--	--	--	--	--

Slide Evaluation Index

Figure 2

Section of duodenum (x400)
illustrating Brunner's glands
in the submucosa and Crypto-
sporidia in crypts of Lieberkühn

Figure 3

Section of ileum (x100)
illustrating Peyer's
patches in submucosa

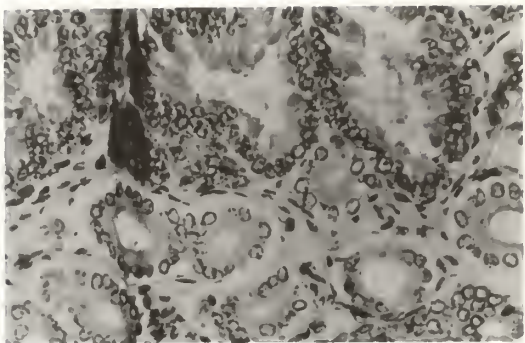


Figure 2

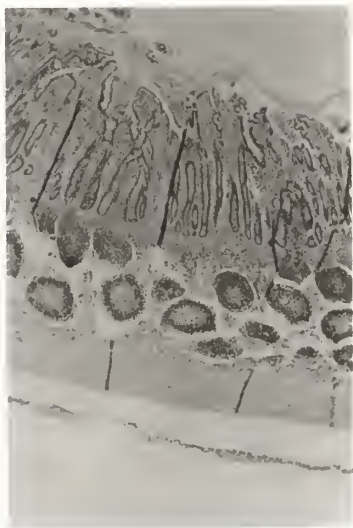


Figure 3

Figure 5

Valve of Kerckring
(x100) illustrated
as found in bovine
small intestine

Figure 4

Section of large bowel
(x400) illustrating gob-
let cells interspersed
in the epithelial cell
layer

Figure 6

Section of abomasum (x400)
illustrating lack of goblet
cells, lack of branched villi
and eosinophilic epithelial
cell cytoplasm. Cryptosporidia
also visualized attached to
epithelial cell surface

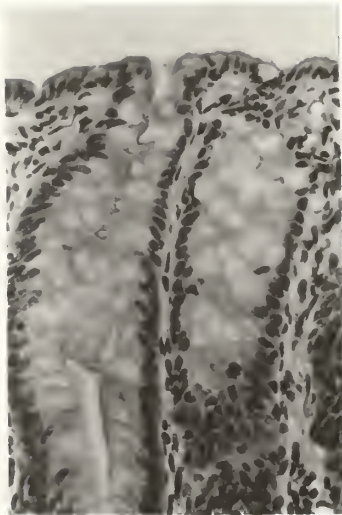


Figure 4

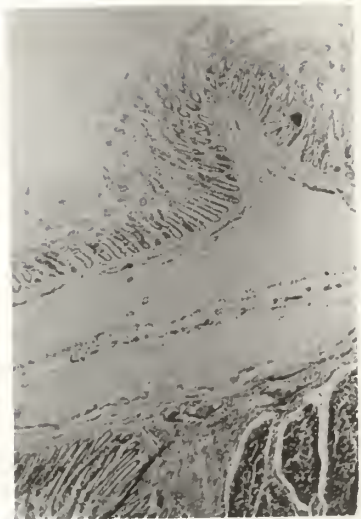


Figure 5

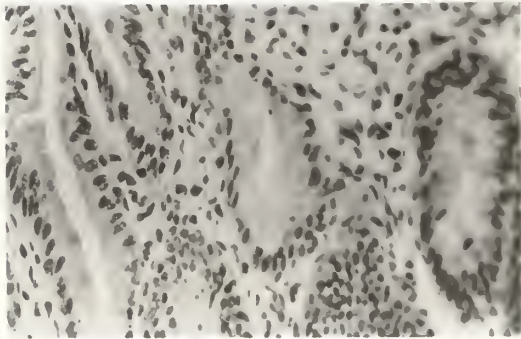


Figure 6

Figure 8

Mitotic figures
in crypt epithel-
ium of small bowel
(x400)

Figure 7

Eosinophilic drop-
lets in apical cy-
toplasm of epithel-
ial cells (x400)

Figure 9

Eosinophilic granules in
supranuclear cytoplasm of
small bowel epithelium (x400)

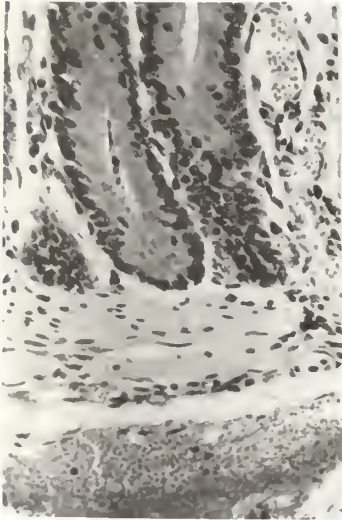


Figure 7

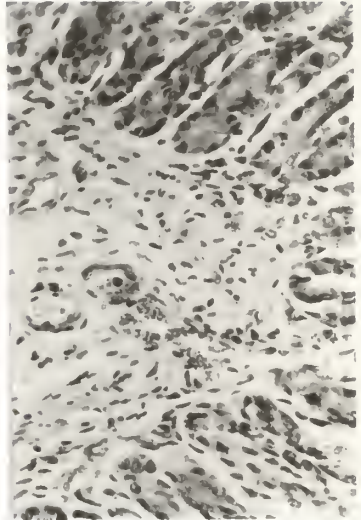


Figure 8

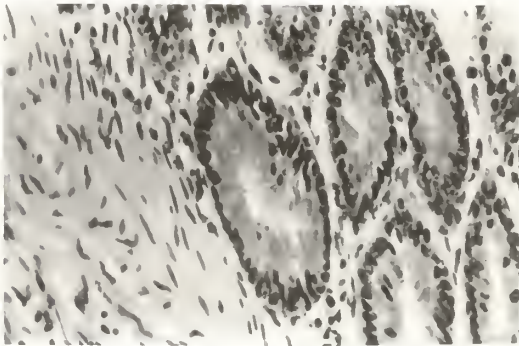


Figure 9

Figure 10

Dilated crypts in large bowel
(x400) - graded moderate

Figure 11

Dilated crypts in large bowel
(x100) - graded moderate

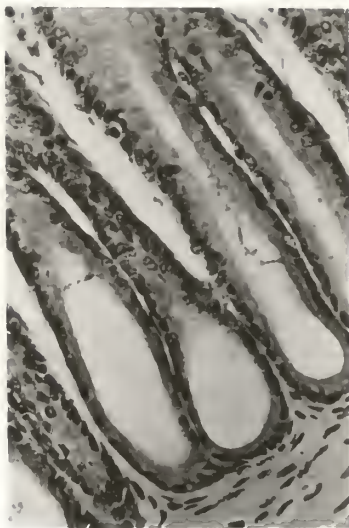


Figure 10

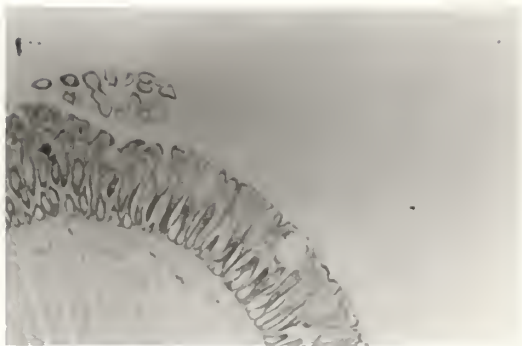


Figure 11

Figure 12

Epithelial cysts in large bowel (x400)
resulting from chronic irritation of
epithelium

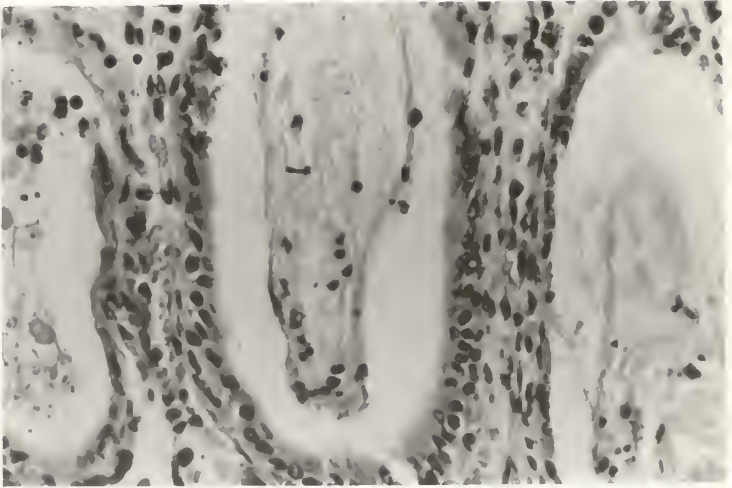


Figure 12

Figure 13

Intraluminal non-invasive fungus
located on the epithelial surface
of the rumen

Figure 14

Fibrinous exudate of small bowel,
muscularis mucosa separated during
slide preparation

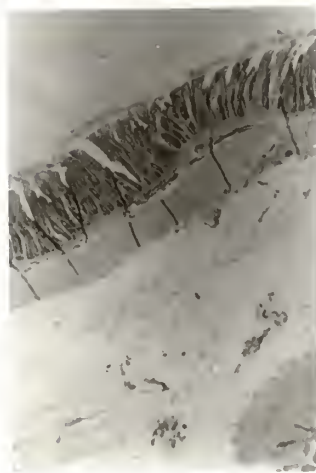

Figure 14

Figure 15

Slight submucosal edema
in the small bowel

Figure 16

Submucosa of the small
bowel showing no edema

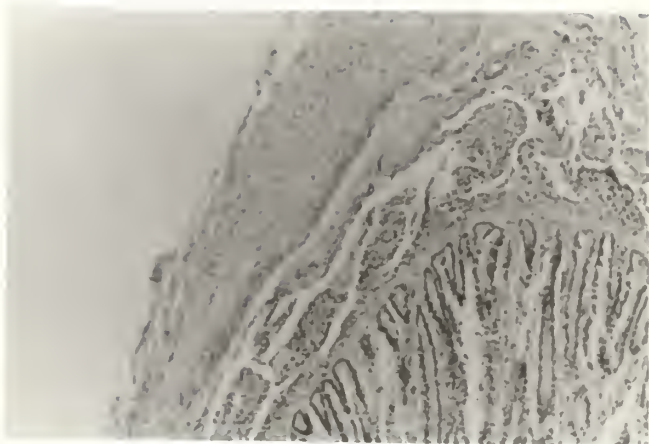


Figure 15

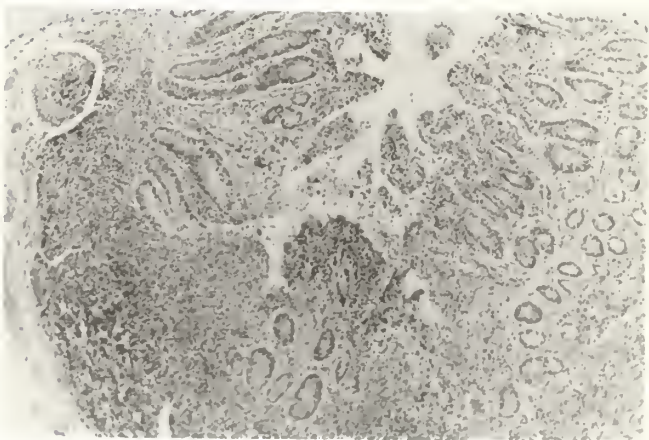


Figure 16

Figure 18

Tunica muscularis
showing no edema

Figure 17

Edema of tunica muscularis
of the small bowel


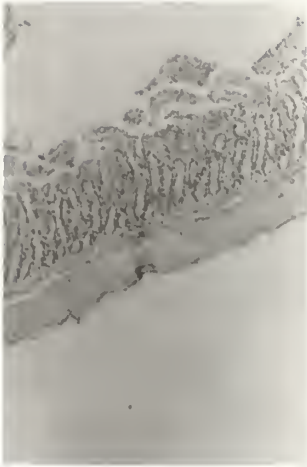


Figure 17

Figure 19

Loss of villus architecture
and marked separation of
apical junctional complexes

Figure 20

Marked submucosal edema
of the small bowel

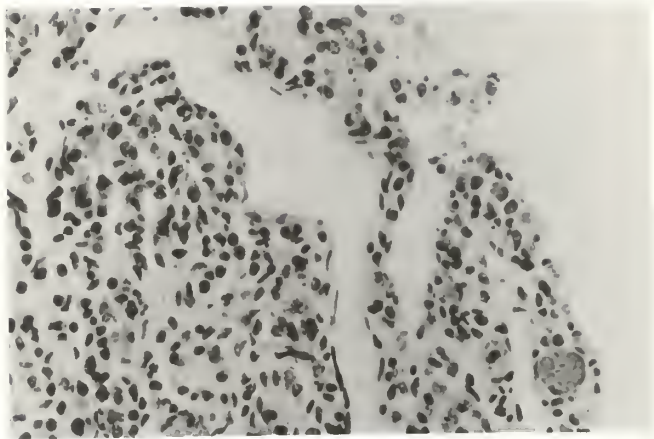


Figure 19

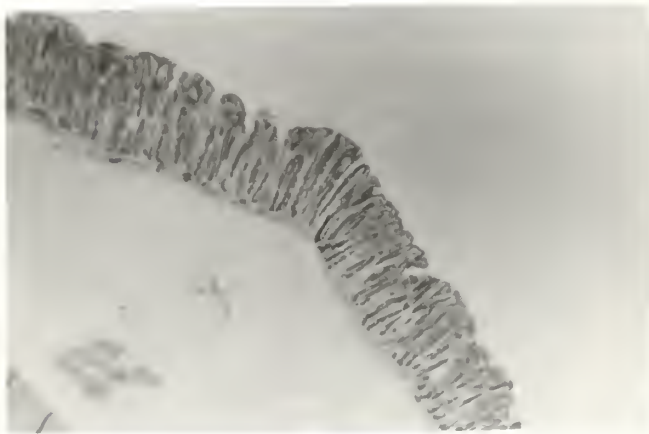


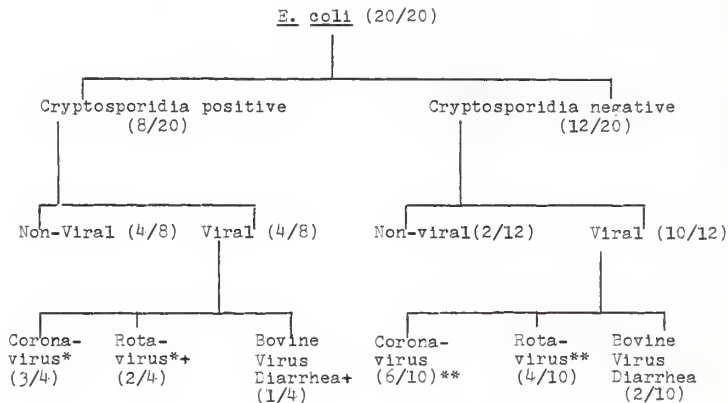
Figure 20

Figure 21

Identification of Causative Agents in 20
Neonatal Calves with Naturally Occurring Diarrhea

Calf No.	Crypto-sporidia	only Coronavirus	only Rotavirus	Rotavirus & Coronavirus	Bovine virus diarrhea	E. coli
6		+				+
13	+					+
14	+					+
26	+	+				+
28						+
43						+
68		+				+
99					+	+
102			+			+
121	+		+		+	+
122			+			+
130	+					+
133					+	+
143	+					+
145	+			+		+
155		+				+
156	+	+				+
159				+		+
160		+				+
168				+		+
total	8	6	3	3	3	20

Figure 22
Flow Chart of Laboratory Diagnosis



* one calf was positive for both coronavirus and rotavirus

** two calves were positive for both coronavirus and rotavirus

+ one calf was positive for both rotavirus and bovine virus
diarrhea virus

Figure 23

Results of Comparison of Histopathology of Calves
to the Criteria in the Literature Review

Calf number	Bacterial	Viral	Protozoal
6		+	
13		+	
14		+	
26		+	
28		+	+
43		+	
68		+	
99		+	
102		+	
121		+	+
122		+	
130	+		
133		+	
143	+		
145		+	
155	+	+	
156	+	+	+
159			+
160		+	+
168	+	+	
Total	5+	17++	5+++

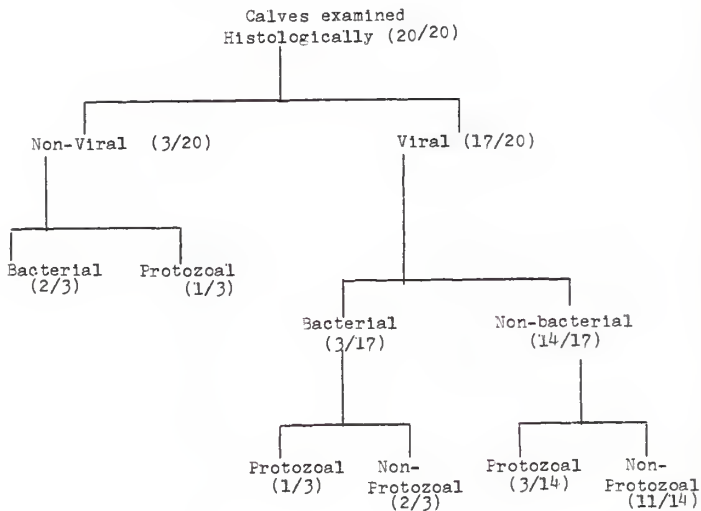
+ 2 - bacterial only, 2 bacterial and viral, 1 - bacterial, viral and protozoal

++ 11 - viral only, 2 viral and bacterial, 3 - viral and protozoal, 1 - viral, bacterial, and protozoal

+++ 1 - protozoal alone, 3 - protozoal and viral
1 - protozoal, viral, and bacterial

Figure 24

Flow Chart Results of Histology
of Calves Fit to Literature Review



Comparison of Results of Histology of Calves Fit
to Literature Review Against Laboratory Diagnosis

Calf number	Bacterial	Viral	Protozoal
6	0	+ 0	
13	0	+ 0	0
14	0	+ 0	0
26	0	+ 0	0
28	0	+	+
43	0	+	
68	0	+ 0	
99	0	+ 0	
102	0	+ 0	
121	0	+ 0	+ 0
122	0	+ 0	
130	+ 0	0	0
133	0	+ 0	
143	+ 0	0	0
145	0	+ 0	0
155	+ 0	+ 0	
156	+ 0	+ 0	+ 0
159	0	0	+
160	0	+ 0	+
168	+ 0	+ 0	

+ - result of literature review

0 - result of laboratory diagnosis

Figure 25

TABLE G-1
Total Slides Graded in
General Appearance Category*

	Lympho- cyte	Neutro- phil	Mono- cyte	Macro- phage	Erythro- cyte	Edema	Parasite	Bact.	Eos.
A	18-36	14-35	10-35	2-35	15-35	1-34	6-34	6-34	21-34
B	12-17	8-17	5-22	2-17	15-17	2-17	1-16	3-16	10-17
C	9-15	11-15	3-15	4-15	12-15	3-15	2-15	2-15	8-15
D	12-32	16-32	8-32	8-32	24-32	3-32	4-32	5-32	8-28
E	11-15	7-15	4-14	1-15	13-15	1-13	1-14	4-15	11-14
F	25-44	14-44	17-44	5-44	26-44	4-43	5-44	7-42	25-42

TABLE G-2
Intraluminal Exudates* Seen on Slides

	Fibrinous (pos-tot)	Catarrhal (pos-tot)	Necrotic (pos-tot)	Hemorrhagic (pos-tot)	Lytic (pos-tot)	Furulent (pos-tot)
A	2-35	3-35	6-35	6-35	3-35	1-35
B	2-17	3-17	0-17	8-17	6-17	0-17
C	1-15	2-15	3-15	7-14	0-15	0-15
D	5-32	1-32	6-32	8-32	4-32	1-32
E	2-15	2-15	1-14	5-15	3-15	0-15
F	3-44	1-44	7-44	7-44	7-44	2-44

*Data are given as two numbers. The first number is the number of slides that were graded moderate and marked. The second number is the total number of slides observed.

TABLE G-3

Differentiated Epithelium
(Numbers of slides)

	Pyknosis*	Vacuolation*	Lysis (Tips-General-Crypts)	Cell Shape (Cuboidal-Columnar)
A	7-35	19-33	8-3-2	7-26
B	10-17	9-17	6-2-4	2-14
C	4-15	6-15	10-1-1	2-11
D	7-32	17-32	15-2-8	6-26
E	6-14	9-14	5-1-2	2-11
F	10-44	24-42	16-4-2	10-31

*Data are given as two numbers. The first number is the number of slides that were graded moderate and marked. The second number is the total number of slides observed.

TABLE G-4

Undifferentiated Epithelium
(Number of Slides)

	Fykknosis*	Vacuolation*	Lysis (Fips-General-Crypts)	Cell Shape (Cuboidal-Columnar)
A	4-34	3-33	7-0-1	5-28
B	4-17	1-17	4-1-3	3-14
C	2-15	0-15	5-2-0	2-13
D	4-32	3-32	4-4-6	7-24
E	3-14	1-12	3-1-1	4-10
F	7-44	2-42	9-1-1	9-33
	Cytoplasmic Granules (positive-total)		Mitotic Figures (positive-total)	
A	23-31		26-31	
B	11-17		15-17	
C	13-15		15-15	
D	25-29		28-29	
E	12-14		12-14	
F	32-39		35-40	

*Data are given as two numbers. The first number is the number of slides that were graded moderate and marked. The second number is the total number of slides observed.

TABLE G-5

Intercellular elements, tight junction and crypt shape
(Number of slides)*

	Lympho- cyte	Neutro- phil	Macro- phage	Globule Leukocyte	Separation Tight Junction	Dilated Crypts	Eosino- phil
A	2-32	1-35	0-32	1-35	8-31	6-22	4-35
B	3-17	4-18	1-17	1-17	12-17	3-15	1-17
C	1-15	1-15	1-15	0-15	8-15	1-14	2-15
D	4-32	4-32	0-32	1-32	17-31	4-30	1-29
E	3-14	2-13	1-13	0-13	8-14	1-13	4-13
F	2-44	3-44	5-44	1-44	19-40	3-41	5-44

*Data are given as two numbers. The first number is the number of slides that were graded moderate and marked. The second number is the total number of slides observed.

TABLE G-6
Changes in Lamina Propria
(Number of slides)*

	Lymphangiectasia	CryptAbscesses	Villus Blunting	Villus Bridging
A	15-34	2-34	12-35	3-35
B	5-17	2-16	12-17	3-16
C	2-15	1-15	13-15	3-15
D	7-32	4-32	18-32	2-32
E	5-13	1-13	7-13	1-13
F	21-43	3-43	21-44	3-44

Infiltrates (Number of slides)*							
	Lympho- cyte	Neutro- phil	Mono- cyte	Macro- phage	Plasma Cell	Erythro- cyte	Eosino- phil
A	15-34	10-33	8-34	3-34	2-34	16-36	21-33
B	12-17	9-17	5-17	1-17	4-17	15-17	9-17
C	7-15	11-15	4-15	3-15	5-15	9-15	8-15
D	10-22	8-25	3-28	5-37	7-32	14-22	7-30
E	12-15	8-15	5-15	1-15	4-14	12-15	13-15
F	13-45	13-45	16-44	3-44	7-44	24-45	41-43

*Data are given as two numbers. The first number is the number of slides that were graded moderate and marked. The second number is the total number of slides observed.

TABLE G-7

Submucosa
(Number slides graded moderate and marked and
total number slides observed)

	Edema	Lympho- cyte	Neutro- phil	Mono- cyte	Macro- phage	Plasma Cell	Erythro- cyte	Eosino- phil
A	13-34	12-34	3-34	3-34	1-34	8-34	11-34	3-33
B	1-15	7-16	3-16	0-16	1-16	1-15	13-15	0-16
C	5-15	4-15	7-15	1-15	3-15	2-15	7-15	1-15
D	6-29	7-25	10-30	2-32	4-32	10-32	18-32	0-31
E	4-13	7-15	2-14	0-14	1-14	2-13	11-14	0-14
F	13-40	18-43	7-42	2-43	3-43	9-42	19-43	2-42

TABLE G-8

Tunica Muscularis
(Number slides graded moderate and marked and
total number slides observed)

	Lympho- cyte	Neutro- phil	Mono- cyte	Macro- phage	Plasma Cell	Erythro- cyte	Eosino- phil	Edema
A	8-32	2-33	3-32	2-32	9-32	4-32	2-31	1-12
B	5-16	2-16	1-16	1-16	1-16	7-15	1-15	3-7
C	5-14	1-14	1-14	2-14	1-14	2-14	0-14	0-2
D	5-29	10-32	2-32	2-32	6-29	4-31	1-32	2-7
E	5-13	1-13	1-13	2-13	5-13	4-14	1-12	0-4
F	13-40	3-42	4-42	3-42	8-40	5-42	2-42	0-17

REFERENCES

1. Halpin CJ, Caple IW: Changes in Intestinal Structure and Function of Neonatal Calves Infected with Reovirus-like Agent and Escherichia coli. Aust Vet Journal 52:438-441, 1976.
2. Jubb KVF, Kennedy PC: Pathology of Domestic Animals. New York, Academic Press, 1970, pp 65-190.
3. Mebus CA: Pathogenesis of Coronaviral Infection in Calves. J A V M A 173:631-632, 1978.
4. Mebus CA, Stair EL, Rhodes MD, Twiehaus MJ: Pathology of Neonatal Calf Diarrhea by a Corona Virus-like Organism. Vet Pathol 10:45-64, 1973.
5. Mebus CA, Stair EL, Underdahl NR, et al: Pathology of Neonatal Calf Diarrhea Induced by a Reo-like Virus. Vet Pathol 8: 490-505, 1971.
6. Middleton FJ: Pathogenesis of Rotaviral Infection. J A V M A 173:544-546, 1978.
7. Moon HW, McClurkin AW, Isaacson RE, Pohleuz J, Skartvedt SM, Gillete KG, Baetz AL: Pathogenic Relationships of Rotavirus, Escherichia coli, and Other Agents in Mixed Infections in Calves. J A V M A 173:577-583, 1978.
8. Nordshom C, Dahlquist A: Quantitative Distribution of Some Enzymes along the Villi and Crypts of Human Small Intestine. Scand J Gastro 8:407-416, 1973.
9. Pearson GR, McNulty MS, Logan EF: Pathological Changes in the Small Intestine of Neonatal Calves Naturally Infected with Reovirus (Rotavirus). Veterinary Record 102:454-458, 1978.
10. Smith HW, Halls E: Observations by the ligated intestinal segment and oral inoculation methods on Escherichia coli infections in pigs, calves, lambs and rabbits. J Pathol Bact 98:499-529, 1967.
11. Snyder SP, England JJ, McChesney AE: Cryptosporidiosis in Immunodeficient Arabian Foals. Vet Pathol 15:12-17, 1978.
12. Vetterling JM, Takenchi A, Madden FA: Ultrastructure of Cryptosporidium wrairi from the Guinea pig. J Protozool 18:248-260, 1971.
13. Williamson RCN, Chir MB: Intestinal Adaptation. NEJM 298:1393-1402, 1978.

APPENDIX

LIST OF TABLES

Table		Page
A(1-8)	Coronavirus negative, rotavirus negative ..	63
B(1-8)	Coronavirus negative, rotavirus positive ..	71
C(1-8)	Coronavirus positive, rotavirus positive ..	79
D(1-8)	Coronavirus positive, rotavirus negative ..	87
E(1-8)	Bovine virus diarrhea	95
F(1-8)	Cryptosporidia positive	103

Criteria for slide evaluation

I. Architecture - general appearance

A. Cellular infiltrates

Graded None - Slight - Moderate - Marked

None - no more inflammatory cells present than normally expected for species and age

Slight - approximately 2 cells seen in 3 hpfs

Moderate - 3-5 cells seen in 3 hpfs

Marked - more than 5 cells seen in 3 hpfs

B. Edema

Graded - None - Slight - Moderate - Marked

None - no edema noted at any level

Slight - occasional small areas where tissue was slightly separated

Moderate - tissue separation noted in nearly all fields but separation not severe

Marked - severe separation of tissue

C. Parasites

D. Bacteria

C & D graded None - Slight - Moderate - Marked

None - no parasites or bacteria noted

Slight - occasional parasite or bacterium

Moderate - seen in over one fourth but in less than three fourths of the high power fields

Marked - seen in nearly all fields

II. Specific Areas

A. Intraluminal exudates

Positive - exudate was identified in one or more areas

Negative - exudate was not identified on this slide

B. Epithelial cell population

1. Erosion - Graded Hemorrhagic Infarct - Erosion - New Ulcer - Old Ulcer - Normal

Hemorrhagic Infarct - wedge shaped area lacking nuclei, erythrocytes present in necrotic tissue

Erosion - loss of villus architecture

New Ulcer - erosion penetrating to tunica muscularis

Old Ulcer - erosion penetrating through tunica muscularis

2. -plasia

Graded a-, hypo-, eu-, hyper-

aplasia - failure of cells to develop--absence of epithelial cells

hypoplasia - decreased numbers of epithelial cells present

euplasia - normal numbers of epithelial cells

hyperplasia - greater than normal numbers of epithelial cells

3. -trophy

Graded a-, hypo-, eu-, hyper-

atrophy - cells shrunken

hypotrophy - cells smaller in size than normal columnar epithelium

eutrophy - morphologically normal epithelial cells

hypertrophy - large epithelial cells present

4. Pigment

5. Inclusions

Graded None - Slight - Moderate - Marked

None - no pigment or inclusions seen

Slight - pigment scattered, inclusions seen
in less than 2 cells observed in 5 hpfs

Moderate - pigment or inclusions noted in cells
in approximately 1/2 of hpfs observed

Marked - pigment or inclusions noticed in nearly
every hpf

C. Individual Differentiated Epithelial Cells

1. Pyknosis

2. Karyorrhexis

3. Karyolysis

4. Vacuolation

Graded None - Tips of Villi - Generalized - Crypts

None - no epithelial cell lysis

Tips of Villi - lysis of cells predominantly near
villus tips

Generalized - lysis of epithelial cells on villi
and in crypts

Crypts - lysis of epithelial cells predominantly
in crypts

6. Cytoplasmic granules (figures 7 and 8, page 30)

Graded positive - negative

7. Cell Shape

Graded Cuboidal - Columnar - Other

D. Individual Undifferentiated Epithelial Cells

1. Pyknosis

2. Karyorrhexis

3. Karyolysis

4. Vacuolation
 - Graded - None - Slight - Moderate - Marked
5. Lysis
 - Graded None - Tips of Villi - Generalized - Crypts
 - None - no epithelial cell lysis
 - Tips of villi - lysis of cells predominantly
near villus tips
 - Generalized - lysis of epithelial cells on villi
and in crypts
 - Crypts - lysis of epithelial cells predominantly
in crypts
6. Cytoplasmic granules (figures 7 and 8, page 30)
7. Cell Shape
 - Graded Cuboidal - Columnar - Other
8. Mitotic figures (figure 8, page 30)
 - Graded None - Slight - Moderate - Marked
- E. Intercellular elements
 - Graded None - Slight - Moderate - Marked
 - None - no intercellular elements in 3 hpfs
 - Slight - one to two cells per 3 hpfs
 - Moderate - three cells per 3 hpfs
 - Marked - more than 3 cells per 3 hpfs
- F. Separation of Apical Junctional Complexes
 - Graded None - Slight - Moderate - Marked
 - None - tight junctions between epithelial cells -
all intact
 - Slight - tight junction separation seen only in a
few scattered areas
 - Moderate - approximately one-half of the tight
junctions exhibit separation
 - Marked - nearly all tight junctions are loosened
or separated

G. Lamina Propria

All categories graded None - Slight - Moderate - Marked

Lymphangiectasia

None - dilated lacteals not seen

Slight - dilation of lacteals did not exceed the width of one epithelial cell and was diffusely scattered

Moderate - dilation of lacteals was approximately one epithelial in width and was seen in more than one-half of the villi

Marked - dilation of lacteals seen in nearly all villi

Crypt abscesses, villus blunting, and villus bridging

Graded None - Slight - Moderate - Marked

Infiltrates

Graded same as under general appearance category (page 57)

I. Submucosa

Infiltrates

Graded the same as in A and B of the general appearance category (page 57)

H. Tunica Muscularis

-trophy

Graded hypo-, eu-, and hyper-

Hypotrophy - tunica muscularis narrower than normal

Eutrophy - normal tunica muscularis

Hypertrophy - tunica muscularis thicker than normal

Infiltrates

Graded the same as in A and B of general appearance category (page 57)

Crypt Appearance

J. Dilated Crypts

Graded None - Slight - Moderate - Marked

None - crypt dilation not seen

Slight - crypt dilation scattered diffusely
over slide

Moderate - crypts dilated in every field (figures
10 & 11)

Marked - epithelial cysts present (figures 12 & 13)

TABLE A - 1

Histopathologic observations (number of slides) from six of 20 neonatal calves with diarrhea. These six calves were negative to rotavirus and to coronavirus by fluorescence microscopy.

Architecture - General Appearance

	Grade	None*	Slight	Moderate	Marked
Cellular Infiltrates					
1. Lymphocyte		8	10	11	7
2. Neutrophil		15	6	11	3
3. Monocyte		16	9	9	1
4. Macrophage		19	14	2	0
5. Plasma Cell		18	13	3	1
6. Fibrocyte		35	0	0	0
7. Erythrocyte		17	3	9	6
8. Eosinophils+		6	7	14	7
Edema		33	0	1	0
Parasites		26	2	5	1
Mycotic Agents		29	0	2	0
Amyloid		35	0	0	0

*No relative increase above the expected number in neonatal bovine tissue

+total in all grades is 28 - four slides not graded

TABLE A - 2

Histopathologic observations (number of slides) from six of 20 neonatal calves with diarrhea. These six calves were negative to rotavirus and to coronavirus by fluorescence microscopy.

Specific Changes

Intraluminal Exudates	Positive	Negative			
1. Fibrinous	2	33			
2. Catarrhal	3	32			
3. Necrotic	6	29			
4. Hemorrhagic	6	29			
5. Lytic	3	32			
6. Purulent	1	34			
Epithelial Cell Population	Hemorrhagic Infarct	Erosion	New Ulcer	Old Ulcer	Normal
1. Erosion	1	0	1	0	33
	A-	Hypo-	Eu-	Hyper-	
2. -plasia	0	0	34	1	
3. -trophy	0	0	35	0	
	None	Slight	Moderate	Marked	
4. Pigment	35	0	0	0	
5. Inclusions	35	0	0	0	

TABLE A - 3

Histopathologic observations (number of slides) from six of 20 neonatal calves with diarrhea. These six calves were negative to rotavirus and to coronavirus by fluorescence microscopy.

Individual Differentiated Epithelial Cells

	None	Slight	Moderate	Marked
1. Fyknosis	15	13	7	0
2. Karyorrhexis	25	12	0	0
3. Karyolysis	31	4	0	0
4. Cytoplasmic vacuolation	4	9	15	4
	None	Tips	General	Crypts
5. Lysis of epithelial cells	21	8	3	2
	Positive	Negative		
6. Cytoplasmic Granules	29	4		
	Cuboidal	Columnar	Other	
7. Cell Shape	7	26	1	

TABLE A - 4

Histopathologic observations (number of slides) from six of 20 neonatal calves with diarrhea. These six calves were negative to rotavirus and to coronavirus by fluorescence microscopy.

Individual Undifferentiated Epithelial Cells

	None	Slight	Moderate	Marked
1. Pyknosis	12	18	4	0
2. Karyorrhexis	27	7	0	0
3. Karyolysis	34	0	0	0
4. Cytoplasmic vacuolation	25	5	0	3
	None	Tips	General	Crypts
5. Lysis of epithelial cells	25	7	0	1
	Cuboidal		Columnar	Other
Cell Shape	5		28	0
	Positive		Negative	
7. Cytoplasmic Granules	23		8	
8. Mitotic Figures	26		5	

TABLE A - 5

Histopathologic observations (number of slides) from six of 20 neonatal calves with diarrhea. These six calves were negative to rotavirus and to coronavirus by fluorescence microscopy.

Intercellular Elements

	None	Slight	Moderate	Marked
1. Lymphocyte	25	5	2	0
2. Neutrophil	29	5	1	0
3. Macrophage	26	6	0	0
4. Globule Leukocyte	30	4	1	0
5. Eosinophil	24	7	4	0
	Apical Junctional Complex			
	None	Slight	Moderate	Marked
Separation	13	10	6	2
	Crypt Appearance			
	None	Slight	Moderate	Marked
Dilation	21	5	5	1

TABLE A - 6

Histopathologic observations (number of slides) from six of 20 neonatal calves with diarrhea. These six calves were negative to rotavirus and to coronavirus by fluorescence microscopy.

Lamina Propria

	None	Slight	Moderate	Marked
1. Lymphangiectasia	17	2	10	5
2. Crypt Abscesses	28	4	2	0
3. Villus Blunting	13	5	8	4
4. Villus Bridging	30	2	2	1
5. Lymphocyte	8	11	13	2
6. Neutrophil	14	9	6	4
7. Monocyte	17	9	7	1
8. Macrophage	21	10	3	0
9. Plasma Cell	16	16	2	0
10. Fibrocyte	34	0	0	0
11. Erythrocyte	16	4	9	7
12. Amyloid	34	0	0	0
13. Eosinophil	6	6	11	10

TABLE A - 7

Histopathologic observations (number of slides) from six of 20 neonatal calves with diarrhea. These six calves were negative to rotavirus and to coronavirus by fluorescence microscopy.

Submucosa

	None	Slight	Moderate	Marked
1. Edema	10	11	9	4
2. Lymphocyte	12	10	11	1
3. Neutrophil	20	11	3	0
4. Monocyte	22	9	3	0
5. Macrophage	21	12	1	0
6. Plasma Cell	13	13	7	1
7. Fibrocyte	32	2	0	0
8. Erythrocyte	14	9	5	6
9. Amyloid	34	0	0	0
10. Eosinophil	26	4	3	0

TABLE A - 8

Histopathologic observations (number of slides) from six of 20 neonatal calves with diarrhea. These six calves were negative to rotavirus and to coronavirus by fluorescence microscopy.

Tunica Muscularis

	Hypo-	Eu-	Hyper-	
1. -trophy	0	29	1	
	None	Slight	Moderate	Marked
2. Lymphocyte	7	17	7	1
3. Neutrophil	24	7	1	1
4. Monocyte	25	4	3	0
5. Macrophage	21	9	2	0
6. Plasma Cell	13	10	8	1
7. Fibrocyte	32	1	0	0
8. Erythrocyte	27	1	3	1
9. Amyloid	31	0	0	0
10. Eosinophil	25	4	2	0
11. Edema	11	1	0	0

TABLE B - 1

Histopathologic observations (number of slides) from three of 20 neonatal calves with diarrhea. These three calves were rotavirus positive and negative to coronavirus by fluorescence microscopy.

Architecture - General Appearance

Grade	None*	Slight	Moderate	Marked
Cellular Infiltrates				
1. Lymphocyte	0	5	6	6
2. Neutrophil	1	8	5	3
3. Monocyte	6	11	3	2
4. Macrophage	7	8	2	0
5. Plasma Cell	3	9	5	0
6. Fibrocyte	16	0	5	0
7. Erythrocyte	2	0	5	10
8. Eosinophils+	5	2	5	5
Edema	14	1	1	1
Parasites	15	0	1	0
Bacteria	11	2	3	0
Mycotic Agents	16	0	0	0
Amyloid	15	1	0	0

*No relative increase above the expected number in neonatal bovine tissue

+total in all grades is 28 - four slides not graded

TABLE B - 2

Histopathologic observations (number of slides) from three of 20 neonatal calves with diarrhea. These three calves were rotavirus positive and negative to coronavirus by fluorescence microscopy.

Specific Changes

Intraluminal Exudates	Positive	Negative			
1. Fibrinous	2	15			
2. Catarrhal	3	14			
3. Necrotic	0	17			
4. Hemorrhagic	8	9			
5. Lytic	6	11			
6. Purulent	0	17			
Epithelial Cell Population	Hemorrhagic Infarct	Erosion	New Ulcer	Old Ulcer	Normal
1. Erosion	0	0	2	0	15
	A-	Hypo-	Eu-	Hyper-	
2. -plasia	1	1	15	0	
3. -trophy	1	1	15	0	
	None	Slight	Moderate	Marked	
4. Pigment	17	0	0	0	
5. Inclusions	17	0	0	0	

TABLE B - 3

Histopathologic observations (number of slides) from three of 20 neonatal calves with diarrhea. These three calves were rotavirus positive and negative to coronavirus by fluorescence microscopy.

Individual Differentiated Epithelial Cells

	None	Slight	Moderate	Marked
1. Fyknosis	2	5	9	1
2. Karyorrhexis	4	10	2	1
3. Karyolysis	9	7	0	1
4. Cytoplasmic vacuolation	3	5	7	2
	None	Tips	General	Crypts
5. Lysis of epithelial cells	5	6	2	4
	Positive	Negative		
6. Cytoplasmic Granules	13	3		
	Cuboidal	Columnar	Other	
7. Cell Shape	2	14	2	

TABLE B - 4

Histopathologic observations (number of slides) from three of 20 neonatal calves with diarrhea. These three calves were rotavirus positive and negative to coronavirus by fluorescence microscopy.

Individual Undifferentiated Epithelial Cells

	None	Slight	Moderate	Marked
1. Fyknosis	2	11	4	0
2. Karyorrhexis	7	9	1	0
3. Karolysis	13	4	0	0
4. Cytoplasmic vacuolation	15	1	0	1
	None	Tips	General	Crypts
5. Lysis of epithelial cells	9	4	1	3
	Cuboidal		Columnar	Other
6. Cell Shape	3		14	0
	Positive		Negative	
7. Cytoplasmic Granules	11		6	
8. Mitotic Figures	15		2	

TABLE B - 5

Histopathologic observations (number of slides) from three of 20 neonatal calves with diarrhea. These three calves were rotavirus positive and negative to coronavirus by fluorescence microscopy.

Intercellular Elements

	None	Slight	Moderate	Marked
1. Lymphocyte	8	6	2	1
2. Neutrophil	12	2	4	0
3. Macrophage	14	2	1	0
4. Globule Leukocyte	11	5	1	0
5. Eosinophil	13	3	1	0
	Apical Junctional Complex			
	None	Slight	Moderate	Marked
Separation	1	4	6	6
	Crypt Appearance			
	None	Slight	Moderate	Marked
Dilation	8	4	1	2

TABLE B - 6

Histopathologic observations (number of slides) from three of 20 neonatal calves with diarrhea. These three calves were rotavirus positive and negative to coronavirus by fluorescence microscopy.

Lamina Propria

	None	Slight	Moderate	Marked
1. Lymphangiectasia	9	3	3	2
2. Crypt Abscesses	9	5	1	1
3. Villus Blunting	3	2	5	7
4. Villus Bridging	8	5	2	1
5. Lymphocyte	1	4	8	4
6. Neutrophil	1	7	5	4
7. Monocyte	8	4	3	2
8. Macrophage	9	7	1	0
9. Plasma Cell	3	10	4	0
10. Fibrocyte	17	0	0	0
11. Erythrocyte	2	0	7	8
12. Amyloid	17	0	0	0
13. Eosinophil	5	3	7	2

TABLE B - 7

Histopathologic observations (number of slides) from three of 20 neonatal calves with diarrhea. These three calves were rotavirus positive and negative to coronavirus by fluorescence microscopy.

Submucosa

	None	Slight	Moderate	Marked
1. Edema	8	6	0	1
2. Lymphocyte	1	8	6	1
3. Neutrophil	8	5	3	0
4. Monocyte	11	5	0	0
5. Macrophage	12	3	1	0
6. Plasma Cell	8	6	1	0
7. Fibrocyte	15	0	0	0
8. Erythrocyte	2	1	5	8
9. Amyloid	16	0	0	0
10. Eosinophil	11	5	0	0

Table B - 8

Histopathologic observations (number of slides) from three of 20 neonatal calves with diarrhea. These three calves were rotavirus positive and negative to coronavirus by fluorescence microscopy.

Tunica Muscularis

	Hypo-	Eu-	Hyper-	
1. -trophy	1	14	4	
	None	Slight	Moderate	Marked
2. Lymphocyte	4	7	5	0
3. Neutrophil	9	5	2	0
4. Monocyte	14	1	1	0
5. Macrophage	7	8	1	0
6. Plasma Cell	10	5	1	0
7. Fibrocyte	15	1	0	0
8. Erythrocyte	6	2	6	1
9. Amyloid	14	1	0	0
10. Eosinophil	11	3	1	0
11. Edema	3	1	1	2

TABLE C - 1

Histopathologic observations (number of slides) from three of 20 neonatal calves with diarrhea. These three calves were positive to rotavirus and to coronavirus by fluorescence microscopy.

Architecture - General Appearance

Grade	None*	Slight	Moderate	Marked
Cellular Infiltrates				
1. Lymphocyte	2	4	4	5
2. Neutrophil	2	2	4	7
3. Monocyte	5	7	3	0
4. Macrophage	6	5	4	0
5. Plasma Cell	3	6	6	0
6. Fibrocyte	14	0	0	0
7. Erythrocyte	1	2	7	5
8. Eosinophils+	7	0	3	5
Edema	12	0	3	0
Parasites	12	1	2	0
Bacteria	8	5	1	1
Mycotic Agents	15	0	0	0
Amyloid	14	0	0	0

*No relative increase above the expected number in neonatal bovine tissue

+total in all grades is 28 - four slides not graded

TABLE C - 2

Histopathologic observations (number of slides) from three of 20 neonatal calves with diarrhea. These three calves were positive to rotavirus and to coronavirus by fluorescence microscopy.

Specific Changes

Intraluminal Exudates	Positive	Negative			
1. Fibrinous	1	14			
2. Catarrhal	2	13			
3. Necrotic	3	12			
4. Hemorrhagic	7	7			
5. Lytic	0	15			
6. Purulent	0	15			
Epithelial Cell Population	Hemorrhagic Infarct	Erosion	New Ulcer	Old Ulcer	Normal
1. Erosion	0	0	1	0	14
	A-	Hypo-	Eu-	Hyper-	
2. -plasia	0	0	15	0	
3. -trophy	0	0	15	0	
	None	Slight	Moderate	Marked	
4. Pigment	14	1	0	0	
5. Inclusions	15	0	0	0	

TABLE C - 3

Histopathologic observations (number of slides) from three of 20 neonatal calves with diarrhea. These three calves were positive to rotavirus and to coronavirus by fluorescence microscopy.

Individual Differentiated Epithelial Cells

	None	Slight	Moderate	Marked
1. Pyknosis	3	8	4	0
2. Karyorrhexis	8	6	1	0
3. Karyolysis	12	3	0	0
4. Cytoplasmic vacuolation	2	7	5	1
	None	Tips	General	Crypts
5. Lysis of epithelial cells	3	10	1	1
	Positive	Negative		
6. Cytoplasmic Granules	14	0		
	Cuboidal	Columnar	Other	
7. Cell Shape	2	11	1	

TABLE C - 4

Histopathologic observations (number of slides) from three of 20 neonatal calves with diarrhea. These three calves were positive to rotavirus and to coronavirus by fluorescence microscopy.

Individual Undifferentiated Epithelial Cells

	None	Slight	Moderate	Marked
1. Pyknosis	7	6	2	0
2. Karyorrhexis	12	3	0	0
3. Karyolysis	15	0	0	0
4. Cytoplasmic vacuolation	15	0	0	0
	None	Tips	General	Crypts
5. Lysis of epithelial cells	8	5	2	0
	Cuboidal		Columnar	Other
6. Cell Shape	2		13	0
	Positive		Negative	
7. Cytoplasmic Granules	13		2	
8. Mitotic Figures	15		0	

TABLE C - 5

Histopathologic observations (number of slides) from three of 20 neonatal calves with diarrhea. These three calves were positive to rotavirus and to coronavirus by fluorescence microscopy.

Intercellular Elements

	None	Slight	Moderate	Marked
1. Lymphocyte	12	2	1	0
2. Neutrophil	9	5	1	0
3. Macrophage	10	4	1	0
4. Globule Leukocyte	12	3	0	0
5. Eosinophil	11	2	2	0
	Apical Junctional Complex			
	None	Slight	Moderate	Marked
Separation	3	4	4	4
	Crypt Appearance			
	None	Slight	Moderate	Marked
Dilation	9	4	1	0

TABLE C - 6

Histopathologic observations (number of slides) from three of 20 neonatal calves with diarrhea. These three calves were positive to rotavirus and to coronavirus by fluorescence microscopy.

Lamina Propria

	None	Slight	Moderate	Marked
1. Lymphangiectasia	12	1	1	1
2. Crypt Abscesses	10	4	1	0
3. Villus Blunting	1	1	6	7
4. Villus Bridging	12	0	1	2
5. Lymphocyte	4	4	6	1
6. Neutrophil	2	2	7	4
7. Monocyte	4	7	4	0
8. Macrophage	3	9	3	0
9. Plasma Cell	3	7	5	0
10. Fibrocyte	15	0	0	0
11. Erythrocyte	4	2	6	3
12. Amyloid	15	0	0	0
13. Eosinophil	7	0	3	5

TABLE C - 7

Histopathologic observations (number of slides) from three of 20 neonatal calves with diarrhea. These three calves were positive to rotavirus and to coronavirus by fluorescence microscopy.

Submucosa

	None	Slight	Moderate	Marked
1. Edema	7	3	3	2
2. Lymphocyte	2	9	4	0
3. Neutrophil	4	4	7	0
4. Monocyte	9	5	0	0
5. Macrophage	7	5	3	0
6. Plasma Cell	6	7	2	0
7. Fibrocyte	14	0	0	0
8. Erythrocyte	4	4	4	3
9. Amyloid	15	0	0	0
10. Eosinophil	14	0	1	0

TABLE C - 8

Histopathologic observations (number of slides) from three of 20 neonatal calves with diarrhea. These three calves were positive to rotavirus and to coronavirus by fluorescence microscopy.

Tunica Muscularis

	Hypo-	Eu-	Hyper-	
1. -trophy	0	13	0	
	None	Slight	Moderate	Marked
2. Lymphocyte	4	5	5	0
3. Neutrophil	7	6	1	0
4. Monocyte	10	3	1	0
5. Macrophage	6	6	2	0
6. Plasma Cell	10	3	1	0
7. Fibrocyte	14	0	0	0
8. Erythrocyte	10	2	1	1
9. Amyloid	14	0	0	0
10. Eosinophil	14	0	0	0
11. Edema	2	0	0	0

TABLE D - 1

Histopathologic observations (number of slides) from six of 20 neonatal calves with diarrhea. These six calves were positive to coronavirus and negative to rotavirus by fluorescence microscopy.

Architecture - General Appearance

Grade	None*	Slight	Moderate	Marked
Cellular Infiltrates				
1. Lymphocyte	6	14	7	5
2. Neutrophil	6	10	9	7
3. Monocyte	16	8	2	6
4. Macrophage	14	10	7	1
5. Plasma Cell	13	10	4	5
6. Fibrocyte	31	1	0	0
7. Erythrocyte	4	4	6	18
8. Eosinophils+	11	9	7	1
Edema	26	3	2	1
Parasites	28	0	3	1
Bacteria	20	7	5	0
Mycotic Agents	32	0	0	0
Amyloid	32	0	0	0

*No relative increase above the expected number in neonatal bovine tissue

+total in all grades is 28 - four slides not graded

TABLE D - 2

Histopathologic observations (number of slides) from six of 20 neonatal calves with diarrhea. These six calves were positive to coronavirus and negative to rotavirus by fluorescence microscopy.

Specific Changes

Intraluminal Exudates	Positive	Negative			
1. Fibrinous	5	27			
2. Catarrhal	1	31			
3. Necrotic	6	26			
4. Hemorrhagic	8	24			
5. Lytic	4	28			
6. Purulent	1	31			
Epithelial Cell Population	Hemorrhagic Infarct	Erosion	New Ulcer	Old Ulcer	Normal
1. Erosion	0	0	0	0	32
	A-	Hypo-	Eu-	Hyper-	
2. -plasia	0	1	29	2	
3. -trophy	0	1	30	1	
	None	Slight	Moderate	Marked	
4. Pigment	32	0	0	0	
5. Inclusions	32	0	0	0	

TABLE D - 3

Histopathologic observations (number of slides) from six of 20 neonatal calves with diarrhea. These six calves were positive to coronavirus and negative to rotavirus by fluorescence microscopy.

Individual Differentiated Epithelial Cells

	None	Slight	Moderate	Marked
1. Pyknosis	8	17	6	1
2. Karyorrhexis	21	9	2	0
3. Karyolysis	24	8	0	0
4. Cytoplasmic vacuolation	4	11	14	3
	None	Tips	General	Crypts
5. Lysis of epithelial cells	7	15	2	8
	Positive	Negative		
6. Cytoplasmic Granules	28	4		
	Cuboidal	Columnar	Other	
7. Cell Shape	6	26	0	

Table D - 4

Histopathologic observations (number of slides) from six of 20 neonatal calves with diarrhea. These six calves were positive to coronavirus and negative to rotavirus by fluorescence microscopy.

Individual Undifferentiated Epithelial Cells

	None	Slight	Moderate	Marked
1. Pyknosis	13	15	4	0
2. Karyorrhexis	21	11	0	0
3. Karyolysis	31	1	0	0
4. Cytoplasmic vacuolation	28	1	1	2
	None	Tips	General	Crypts
5. Lysis of epithelial cells	17	4	4	6
	Cuboidal		Columnar	Other
6. Cell Shape	7		24	0
	Positive		Negative	
7. Cytoplasmic Granules	25		4	
8. Mitotic Figures	28		1	

TABLE D - 5

Histopathologic observations (number of slides) from six of 20 neonatal calves with diarrhea. These six calves were positive to coronavirus and negative to rotavirus by fluorescence microscopy.

Intercellular Elements

	None	Slight	Moderate	Marked
1. Lymphocyte	21	7	4	0
2. Neutrophil	21	7	4	0
3. Macrophage	26	6	0	0
4. Globule Leukocyte	29	2	1	0
5. Eosinophil	21	7	1	0
	Apical Junctional Complex			
	None	Slight	Moderate	Marked
Separation	6	8	7	10
	Crypt Appearance			
	None	Slight	Moderate	Marked
Dilation	26	0	2	2

TABLE D - 6

Histopathologic observations (number of slides) from six of 20 neonatal calves with diarrhea. These six calves were positive to coronavirus and negative to rotavirus by fluorescence microscopy.

Lamina Propria

	None	Slight	Moderate	Marked
1. Lymphangiectasia	19	6	3	4
2. Crypt Abscesses	22	6	4	0
3. Villus Blunting	7	7	8	10
4. Villus Bridging	26	4	1	1
5. Lymphocyte	6	6	7	3
6. Neutrophil	6	11	8	0
7. Monocyte	17	8	3	0
8. Macrophage	17	15	5	0
9. Plasma Cell	10	15	7	0
10. Fibrocyte	31	1	0	0
11. Erythrocyte	4	4	14	0
12. Amyloid	31	1	0	0
13. Eosinophil	13	10	7	0

TABLE D - 7

Histopathologic observations (number of slides) from six of 20 neonatal calves with diarrhea. These six calves were positive to coronavirus and negative to rotavirus by fluorescence microscopy.

Submucosa

	None	Slight	Moderate	Marked
1. Edema	11	12	6	0
2. Lymphocyte	6	12	7	0
3. Neutrophil	12	8	10	0
4. Monocyte	15	15	2	0
5. Macrophage	15	13	4	0
6. Plasma Cell	8	14	9	1
7. Fibrocyte	32	0	0	0
8. Erythrocyte	6	8	8	10
9. Amyloid	32	0	0	0
10. Eosinophil	28	3	0	0

TABLE D - 8

Histopathologic observations (number of slides) from six of 20 neonatal calves with diarrhea. These six calves were positive to coronavirus and negative to rotavirus by fluorescence microscopy.

Tunica Muscularis

	Hypo-	Eu-	Hyper-	
1. -trophy	0	25	3	
	None	Slight	Moderate	Marked
2. Lymphocyte	7	17	5	0
3. Neutrophil	13	9	10	0
4. Monocyte	25	5	2	0
5. Macrophage	16	14	2	0
6. Plasma Cell	13	10	6	0
7. Fibrocyte	31	1	0	0
8. Erythrocyte	19	8	4	0
9. Amyloid	32	0	0	0
10. Eosinophil	29	2	1	0
11. Edema	2	3	1	1

TABLE E - 1

Histopathologic observations (number of slides) from three of 20 neonatal calves with diarrhea. These three calves were positive to bovine virus diarrhea by fluorescence microscopy.

Architecture - General Appearance

Grade	None*	Slight	Moderate	Marked
Cellular Infiltrates				
1. Lymphocyte	0	4	4	7
2. Neutrophil	2	6	3	4
3. Monocyte	5	5	1	3
4. Macrophage	5	9	1	0
5. Plasma Cell	4	8	2	1
6. Fibrocyte	14	0	0	0
7. Erythrocyte	1	1	5	8
8. Eosinophils+	2	1	7	4
Edema	11	1	1	0
Parasites	13	0	1	0
Bacteria	7	3	3	1
Mycotic Agents	14	0	0	0
Amyloid	2	1	7	4

*No relative increase above the expected number in neonatal bovine tissue

+total in all grades is 28 - four slides not graded

TABLE E - 2

Histopathologic observations (number of slides) from three of 20 neonatal calves with diarrhea. These three calves were positive to bovine virus diarrhea by fluorescence microscopy.

Specific Changes

Intraluminal Exudates	Positive	Negative			
1. Fibrinous	2	13			
2. Catarrhal	2	13			
3. Necrotic	1	14			
4. Hemorrhagic	5	10			
5. Lytic	3	12			
6. Purulent	0	15			
Epithelial Cell Population	Hemorrhagic Infarct	Erosion	New Ulcer	Old Ulcer	Normal
1. Erosion	0	0	0	0	14
	A-	Hypo-	Eu-	Hyper-	
2. -plasia	1	1	12	0	
3. -trophy	1	1	12	0	
	None	Slight	Moderate	Marked	
4. Pigment	14	0	0	0	
5. Inclusions	14	0	0	0	

TABLE E - 3

Histopathologic observations (number of slides) from three of 20 neonatal calves with diarrhea. These three calves were positive to bovine virus diarrhea by fluorescence microscopy.

Individual Differentiated Epithelial Cells

	None	Slight	Moderate	Marked
1. Fyknosis	1	7	5	1
2. Karyorrhexis	5	8	0	1
3. Karyolysis	9	4	0	1
4. Cytoplasmic vacuolation	1	4	7	2
	None	Tips	General	Crypts
5. Lysis of epithelial cells	7	5	1	2
	Positive		Negative	
6. Cytoplasmic Granules	12		1	
	Cuboidal		Columnnar	Other
7. Cell Shape	2		11	2

TABLE E - 4

Histopathologic observations (number of slides) from three of 20 neonatal calves with diarrhea. These three calves were positive to bovine virus diarrhea by fluorescence microscopy.

Individual Undifferentiated Epithelial Cells

	None	Slight	Moderate	Marked
1. Pyknosis	6	5	3	0
2. Karyorrhexis	9	5	0	0
3. Karyolysis	12	2	0	0
4. Cytoplasmic vacuolation	11	1	0	1
	None	Fips	General	Crypts
5. Lysis of epithelial cells	10	3	1	1
	Cuboidal		Columnar	Other
6. Cell Shape	4		10	0
	Positive		Negative	
7. Cytoplasmic Granules	12		2	
8. Mitotic Figures	12		2	

TABLE E - 5

Histopathologic observations (number of slides) from three of 20 neonatal calves with diarrhea. These three calves were positive to bovine virus diarrhea by fluorescence microscopy.

Intercellular Elements

	None	Slight	Moderate	Marked
1. Lymphocyte	8	3	2	1
2. Neutrophil	10	1	2	0
3. Macrophage	9	3	1	0
4. Globule Leukocyte	9	4	0	0
5. Eosinophil	7	2	4	0
	Apical Junctional Complex			
	None	Slight	Moderate	Marked
Separation	4	2	1	7
	Crypt Appearance			
	None	Slight	Moderate	Marked
Dilation	9	3	0	1

TABLE E - 6

Histopathologic observations (number of slides) from three of 20 neonatal calves with diarrhea. These three calves were positive to bovine virus diarrhea by fluorescence microscopy.

Lamina Propria

	None	Slight	Moderate	Marked
1. Lymphangiectasia	6	2	1	4
2. Crypt Abscesses	9	3	1	0
3. Villus Blunting	5	1	1	6
4. Villus Bridging	9	3	0	1
5. Lymphocyte	1	2	7	5
6. Neutrophil	1	6	4	4
7. Monocyte	9	1	4	1
8. Macrophage	4	10	1	0
9. Plasma Cell	4	6	2	2
10. Fibrocyte	15	0	0	0
11. Erythrocyte	2	1	4	8
12. Amyloid	15	0	0	0
13. Eosinophil	1	1	9	4

TABLE E - 7

Histopathologic observations (number of slides) from three of 20 neonatal calves with diarrhea. These three calves were positive to bovine virus diarrhea by fluorescence microscopy.

Submucosa

	None	Slight	Moderate	Marked
1. Edema	4	5	1	3
2. Lymphocyte	1	6	6	1
3. Neutrophil	10	2	2	0
4. Monocyte	6	8	0	0
5. Macrophage	8	5	1	0
6. Plasma Cell	5	6	1	1
7. Fibrocyte	14	0	0	0
8. Erythrocyte	1	2	3	8
9. Amyloid	14	0	0	0
10. Eosinophil	10	4	0	0

TABLE E - 8

Histopathologic observations (number of slides) from three of 20 neonatal calves with diarrhea. These three calves were positive to bovine virus diarrhea by fluorescence microscopy.

Tunica Muscularis

	Hypo-	Eu-	Hyper-	
1. -trophy	1	12	0	
	None	Slight	Moderate	Marked
2. Lymphocyte	2	6	3	2
3. Neutrophil	6	6	1	0
4. Monocyte	8	4	1	0
5. Macrophage	7	4	2	0
6. Plasma Cell	4	4	4	1
7. Fibrocyte	13	0	0	0
8. Erythrocyte	6	4	3	1
9. Amyloid	12	1	0	0
10. Eosinophil	9	2	0	1
11. Edema	1	3	0	0

TABLE F - 1

Histopathologic observations (number of slides) from eight of 20 neonatal calves with diarrhea. These eight calves were positive to cryptosporidia by light microscopy.

Architecture - General Appearance

Grade	None*	Slight	Moderate	Marked
Cellular Infiltrates				
1. Lymphocyte	5	14	14	11
2. Neutrophil	15	15	7	7
3. Monocyte	16	11	10	7
4. Macrophage	21	18	5	0
5. Plasma Cell	22	13	7	2
6. Fibrocyte	43	0	0	0
7. Erythrocyte	14	4	10	16
8. Eosinophils+	8	9	14	11
Edema	38	1	4	0
Parasites	36	3	3	2
Bacteria	22	13	7	0
Mycotic Agents	36	0	2	0
Amyloid	43	0	0	0

*No relative increase above the expected number in neonatal bovine tissue

+total in all grades is 28 - four slides not graded

TABLE F - 2

Histopathologic observations (number of slides) from eight of 20 neonatal calves with diarrhea. These eight calves were positive to cryptosporidia by light microscopy.

Specific Changes

Intraluminal Exudates	Positive	Negative			
1. Fibrinous	3	41			
2. Catarrhal	1	43			
3. Necrotic	7	37			
4. Hemorrhagic	7	37			
5. Lytic	7	37			
Furulent	2	42			
Epithelial Cell Population	Hemorrhagic Infarct	Erosion	New Ulcer	Old Ulcer	Normal
1. Erosion	0	0	0	5	38
	A-	Hypo-	Eu-	Hyper-	
2. -plasia	1	1	40	2	
3. -trophy	1	1	42	0	
	None	Slight	Moderate	Marked	
4. Pigment	43	1	0	0	
5. Inclusions	44	0	0	0	

TABLE F - 3

Histopathologic observations (number of slides) from eight of 20 neonatal calves with diarrhea. These eight calves were positive to cryptosporidia by light microscopy.

Individual Differentiated Epithelial Cells

	None	Slight	Moderate	Marked
1. Euknosis	13	21	9	1
2. Karyorrhexis	24	19	0	1
3. Karyolysis	33	10	0	1
4. Cytoplasmic vacuolation	4	15	20	4
	None	Tips	General	Crypts
5. Lysis of epithelial cells	21	16	4	2
	Positive	Negative		
6. Cytoplasmic Granules	38	3		
	Cuboidal	Columnar	Other	
7. Cell Shape	10	31	3	

TABLE F - 4

Histopathologic observations (number of slides) from eight of 20 neonatal calves with diarrhea. These eight calves were positive to cryptosporidia by light microscopy.

Individual Undifferentiated Epithelial Cells

	None	Slight	Moderate	Marked
1. Pyknosis	12	25	7	0
2. Karyorrhexis	26	17	0	0
3. Karyolysis	40	3	0	0
4. Cytoplasmic vacuolation	34	6	0	2
	None	Tips	General	Crypts
5. Lysis of epithelial cells	31	9	1	1
	Cuboidal	Columnar	Other	
6. Cell Shape	9	33	0	
	Positive	Negative		
7. Cytoplasmic Granules	32	7		
8. Mitotic Figures	35	5		

TABLE F - 5

Histopathologic observations (number of slides) from eight of 20 neonatal calves with diarrhea. These eight calves were positive to cryptosporidia by light microscopy.

Intercellular Elements

	None	Slight	Moderate	Marked
1. Lymphocyte	34	8	1	1
2. Neutrophil	36	5	3	0
3. Macrophage	30	9	5	0
4. Globule Leukocyte	35	8	1	0
5. Eosinophil	27	12	5	0
	Apical Junctional Complex			
	None	Slight	Moderate	Marked
Separation	11	10	8	11
	Crypt Appearance			
	None	Slight	Moderate	Marked
Dilation	34	4	2	1

TABLE F - 6

Histopathologic observations (number of slides) from eight of 20 neonatal calves with diarrhea. These eight calves were positive to cryptosporidia by light microscopy.

Lamina Propria

	None	Slight	Moderate	Marked
1. Lymphangiectasia	18	4	12	9
2. Crypt Abscesses	36	4	3	0
3. Villus Blunting	14	9	11	10
4. Villus Bridging	36	5	1	2
5. Lymphocyte	16	16	8	5
6. Neutrophil	15	18	7	6
7. Monocyte	17	11	10	6
8. Macrophage	21	20	3	0
9. Plasma Cell	19	18	7	0
10. Fibrocyte	44	0	0	0
11. Erythrocyte	16	5	9	15
12. Amyloid	44	0	0	0
13. Eosinophil	9	7	14	13

TABLE F - 7

Histopathologic observations (number of slides) from eight of 20 neonatal calves with diarrhea. These eight calves were positive to cryptosporidia by light microscopy.

Submucosa

	None	Slight	Moderate	Marked
1. Edema	13	14	7	6
2. Lymphocyte	12	12	14	4
3. Neutrophil	24	12	6	0
4. Monocyte	24	17	2	0
5. Macrophage	25	15	3	0
6. Plasma Cell	17	16	9	0
7. Fibrocyte	43	0	0	0
8. Erythrocyte	11	13	9	10
9. Amyloid	43	0	0	0
10. Eosinophil	37	3	2	0

TABLE F - 8

Histopathologic observations (number of slides) from eight of 20 neonatal calves with diarrhea. These eight calves were positive to cryptosporidia by light microscopy.

Tunica Muscularis

	Hypo-	Eu-	Hyper-	
1. -troph	1	38	2	
	None	Slight	Moderate	Marked
2. Lymphocyte	8	19	13	0
3. Neutrophil	31	8	3	0
4. Monocyte	30	8	4	0
5. Macrophage	23	16	3	0
6. Plasma Cell	22	10	8	0
7. Fibrocyte	42	0	0	0
8. Erythrocyte	30	7	4	1
9. Amyloid	41	1	0	0
10. Eosinophil	36	4	1	1
11. Edema	13	4	0	0

HISTOPATHOLOGICAL CHANGES IN THE INTESTINE
OF NEONATAL CALVES AS A RESULT OF
NATURALLY OCCURRING DIARRHEA

by

T. R. Hathaway

B.S., Kansas State University, 1970
D.V.M., Kansas State University, 1972

AN ABSTRACT OF A MASTER'S THESIS

submitted in partial fulfillment of the

requirements for the degree

MASTER OF SCIENCE

Department of Surgery and Medicine

KANSAS STATE UNIVERSITY
Manhattan, Kansas

1979

ABSTRACT

Many causative agents are associated with diarrhea disease of neonatal calves and these agents may each result in a unique set of histopathologic changes. These changes were studied in 20 calves, randomly selected, from a group of 46 that died of naturally occurring diarrhea. The 46 deaths occurred in a group of 152 calves that developed naturally occurring diarrhea.

Tissues from the digestive tracts of each of the 20 calves were analyzed microscopically and were graded in 76 categories according to an index developed for this purpose. The results of this grading procedure were compared with the laboratory diagnosis (culture, immunofluorescence, and parasitology). The data were also compared, subjectively, to a synopsis of histopathologic changes for bacterial, viral and protozoal agents as reported in the literature.