

THE ANATOMY AND SURGICAL DEPRIVATION OF THE ORAL
AND NASAL SENSES IN THE SHEEP

by

HAROLD WAKENSHAW CHAPMAN

B. V. Sc., University of Sydney, 1960

A MASTER'S THESIS

submitted in partial fulfillment of the

requirements for the degree

MASTER OF SCIENCE

Department of Anatomy

KANSAS STATE UNIVERSITY
Manhattan, Kansas

1965

Approved by:



Major Professor

LD
2668
T4
1965
C46
C-2

TABLE OF CONTENTS

Document

GENERAL INTRODUCTION 1

PART I: THE SENSORY NEUROANATOMY OF THE NASAL, ORAL
AND LABIAL REGIONS IN SHEEP 2

 Introduction 2

 Materials and Methods 2

 Results and Discussion 3

 (a) The Olfactory Nerve (I) 3

 (b) The Lingual Nerve (V) 6

 (c) The Glossopharyngeal Nerve (IX) 12

 (d) The Infraorbital Nerve (V) 13

 (e) The Mental Nerve (V) 15

 Summary 16

PART II: SURGICAL TECHNIQUES OF OLFACTORY DEPRIVATION AND
LINGUAL, GLOSSOPHARYNGEAL, INFRAORBITAL AND MENTAL NEURECTOMY 18

 Introduction 18

 Materials and Methods 18

 (a) General 18

 (b) Olfactory Deprivation 21

 (c) Lingual and Glossopharyngeal Neurectomy 23

 (d) Infraorbital and Mental Neurectomy 26

 Results 27

 Discussion 31

 Summary 33

GENERAL SUMMARY 35

ACKNOWLEDGMENTS 36

LITERATURE CITED 37

GENERAL INTRODUCTION

This thesis consists of a description of the anatomy of the oral and nasal senses in sheep and of the surgical techniques used to deprive sheep of these senses in order to prepare them for behavioral studies. The thesis is divided into two parts, each self-contained except for the list of literature cited. Part I deals with the anatomy, and part II with the surgery, of the olfactory, lingual (V), glossopharyngeal, infraorbital and mental nerves.

PART I

THE SENSORY NEUROANATOMY OF THE NASAL, ORAL
AND LABIAL REGIONS IN SHEEPINTRODUCTION

For the study of the role of the nasal, oral and labial senses in the ingestive behavior of sheep it was desired to produce animals which had been partially or completely deprived of these senses. As insufficient details of the relevant anatomy of the sheep were included in the available literature an anatomical study was considered necessary.

MATERIALS AND METHODS

The heads of three sheep were dissected in detail and additional observations were made on two other animals. These were crossbred sheep of Hampshire and Rambouillet origin from the research flock of the College of Veterinary Medicine.* In addition the heads of four Hampshire x Rambouillet lambs from the meat production experiments of the Department of Animal Husbandry* were examined. Supplementary observations were made on three Border Leicester x Merino sheep from the C.S.I.R.O.** flock. Incidental observations were made during necropsies of sheep of both types.

All of the dissections were carried out on fresh specimens. A stereoscopic dissecting microscope (10.5 diameter magnification) was used and successive stages of the dissections were recorded by means of a Polaroid camera mounted on a Polaroid "Copymaker." The terminology used

* Kansas State University, Manhattan, Kansas.

** Commonwealth Scientific and Industrial Research Organization, Division of Plant Industry, Canberra, A.C.T., Australia.

is that of Sisson and Grossman (1953) except where otherwise indicated. The English form is used instead of the Latin and rostral and caudal are substituted for anterior and posterior. In order to provide a reference to works on human anatomy the terminology of Romanes (1964) is included where it differs from that of Sisson and Grossman (1953).

RESULTS AND DISCUSSION

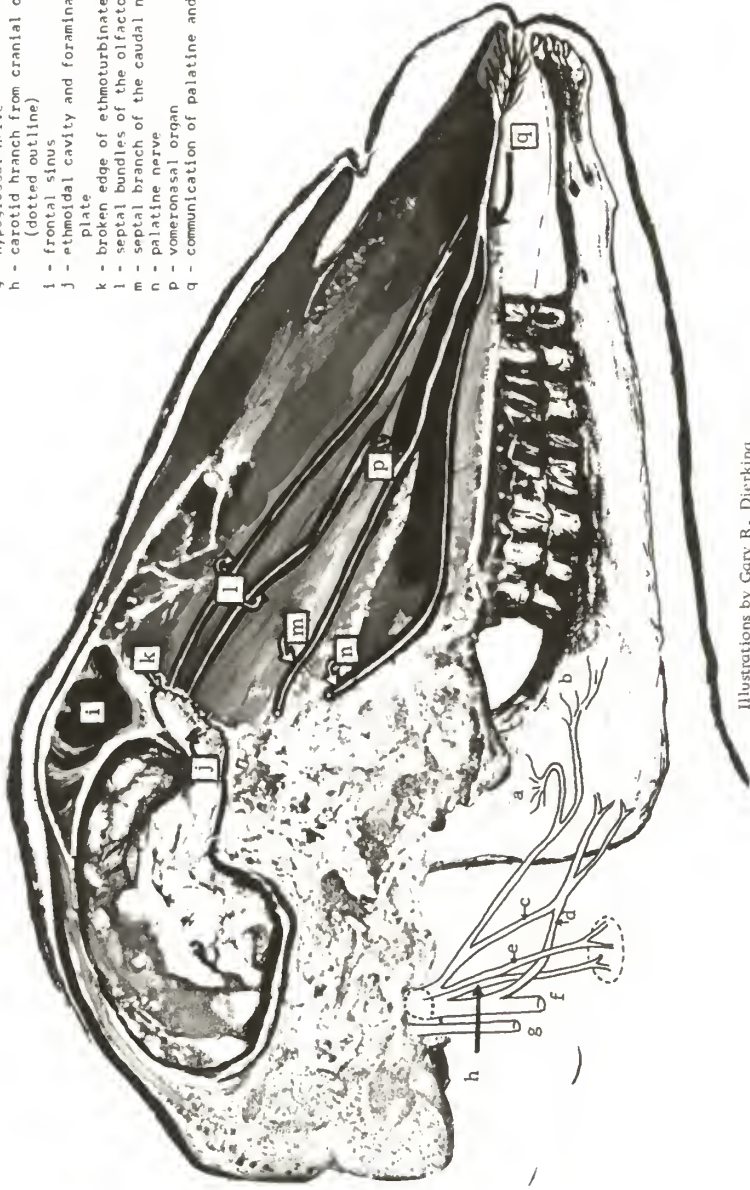(a) The Olfactory Nerve (I)

The olfactory bulb was located at the rostral end of the olfactory lobe of the brain and in the ethmoidal fossa. The olfactory nerves which were the axons of the olfactory cells located in the specialized olfactory mucosa ran in bundles through the cribriform plate of the ethmoid bone and terminated on the bulb. The cribriform plate formed the rostral boundary and part of the walls, roof and floor of the ethmoidal fossa and was at approximately right angles to the long axis of the head. The cribriform plate lay ventral to the internal plate of the frontal bone and rostral to the angle of the plate (see fig. 1) and was ellipsoid in shape, the greater and lesser diameters being about 2 cm. and 1 cm. respectively.

The caudal border (or rim) of the ethmoidal fossa was found to be formed by a slight ridge of the ethmoid bone and by an infolding of the dura mater which formed a diaphragm with an opening about three-quarters the size of the cribriform plate and located in the ventral half of the fossa. This diaphragm contained the ethmoidal nerve (see below) and separated the cerebral hemisphere from the olfactory bulb which extended further beyond the hemisphere than was shown by Taylor (1955) or Ranson and Clark (1959). The dura was closely applied to the cribriform plate and extensions of it accompanied the olfactory nerves through the foramina

Fig. 1. The Glossopharyngeal Nerve (Diagrammatic) and the Olfactory Apparatus (Semi-diagrammatic, Parasagittal Section).

- a - lingual branch of glossopharyngeal (branch to pharynx)
- b - lingual branch of glossopharyngeal (branch to tongue)
- c - pharyngeal branch of glossopharyngeal
- d - branch to the pharyngeal plexus of vagus
- e - carotid sinus branch of the glossopharyngeal nerve
- f - accessory nerve and vagus in common sheath
- g - hypoglossal nerve
- h - carotid branch from cranial cervical ganglion (dotted outline)
- i - frontal sinus
- j - ethmoidal cavity and foramina of cribriform plate
- k - broken edge of ethmoturbinate
- l - septal bundles of the olfactory nerve
- m - septal branch of the caudal nasal nerve
- n - palatine nerve
- p - vomeronasal organ
- q - communication of palatine and nasal nerves



Illustrations by Gary R. Dierking

of the plate.

From the bulb the olfactory nerves passed through the foramina to ramify in the olfactory mucosa. One or two grossly visible bundles ran forward on the nasal septum reaching the vomero-nasal organ and one or two similarly branched on the lateral wall of the ventral meatus. The main area of olfactory mucosa could be recognized grossly (by its yellow color) on the posterior two-thirds of the ethmoturbinates and the adjacent surfaces of the septum and the lateral wall.

The vomero-nasal organ was located on the nasal septum near the ventral border of the septum and parallel to it. The mucosa of the vomero-nasal organ of the sheep has been described as being olfactory in structure (von Braun, 1892). In all of the sheep dissected in the present investigation the organ was found to be a closed cylinder. Since branches of the olfactory nerve reached parts of the septum and the lateral wall these areas presumably contained olfactory cells although they are not usually regarded as part of the specialized olfactory mucosa.

In view of Tucker's (1963) demonstration of the response of the nasal trigeminal branches to odorants it is appropriate to mention here the chief branches of the trigeminal in the nasal cavity. The caudal nasal nerve (a branch of the maxillary nerve) had two branches, one of which was distributed on the lateral wall of the nasal cavity. The other branch passed rostrally and ventrally in the septal mucosa to a position ventral to the vomero-nasal organ and ran parallel to it to the palatine fissure through which it communicated with the palatine nerve and, in some animals, with the termination of the lateral branch. It gave twigs to the septal mucosa and was probably homologous with the nasopalatine nerve of man

(Romanes, 1964).

The ethmoidal nerve was the terminal branch of the naso-ciliary nerve which was a branch of the ophthalmic division of the trigeminal nerve. It entered the cranial cavity through the homonymous foramen and ran embedded in the dura mater to its exit in the middle of the dorsal rim of the cribriform plate. Its branches supplied the mucosa of the dorsal turbinate bone.

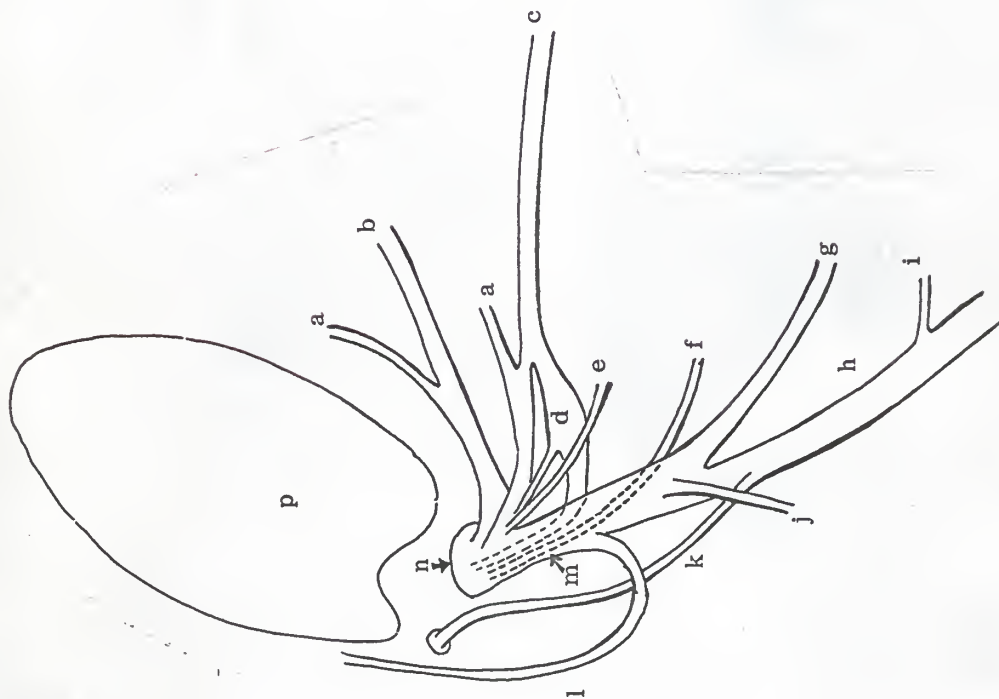
(b) The Lingual Nerve (V)

The lingual nerve was a terminal branch of the mandibular nerve which was one of the divisions of the trigeminal, or fifth cranial, nerve. In the sheep the mandibular nerve divided at or within the foramen ovale, from which it emerged (fig. 2). The branches were (1) the large caudal trunk, (2) the masseteric nerve, (3) one or two deep temporal nerves (one or both of the temporal nerves in some animals were derived from the buccinator or masseteric nerves), (4) the buccinator nerve (buccal--Romanes, 1964) and (5) the lateral and medial pterygoid nerves. Medial to the branches of the mandibular nerve was a large ganglion from which a branch joined the buccinator nerve. One of the branches of the buccinator nerve went to the parotid duct and, according to Denton (1957) supplied the parasympathetic innervation of the parotid gland.

The caudal trunk passed rostrally and ventrally between the medial and lateral pterygoid muscles. The superficial temporal nerve (most of which joined the ventral buccal branch of the facial nerve) branched from the trunk at the caudal border of the lateral pterygoid muscle. The trunk divided into the lingual and the mandibular alveolar nerves near the middle of the insertion of the lateral pterygoid muscle on the mandible. Near

Fig. 2. The Mandibular Nerve (Diagrammatic).

- a - deep temporal nerves--one or both may arise separately from the mandibular nerve
- b - masseteric nerve
- c - buccinator nerve
- d - ganglion
- e - lateral pterygoid nerve
- f - medial pterygoid nerve
- g - mandibular alveolar nerve
- h - lingual nerve
- i - branch to the isthmus faucium
- j - mylohyoid nerve (retracted caudally)
- k - chorda tympani
- l - superficial temporal nerve
- m - caudal trunk of the mandibular nerve
- n - foramen ovale
- p - temporal condyle



this division the small mylohyoid nerve arose from the trunk or from the mandibular alveolar nerve.

The chorda tympani branch of the facial nerve emerged from the petrous temporal bone through the petrotympanic fissure which was located just caudal to the tip of the postglenoid process. It then passed medially to the external carotid artery and joined the lingual nerve just distal to its origin. In some cases the chorda tympani joined the lingual portion of the trunk before the gross division but after the fibers of the lingual and mandibular nerves had formed separate bundles.

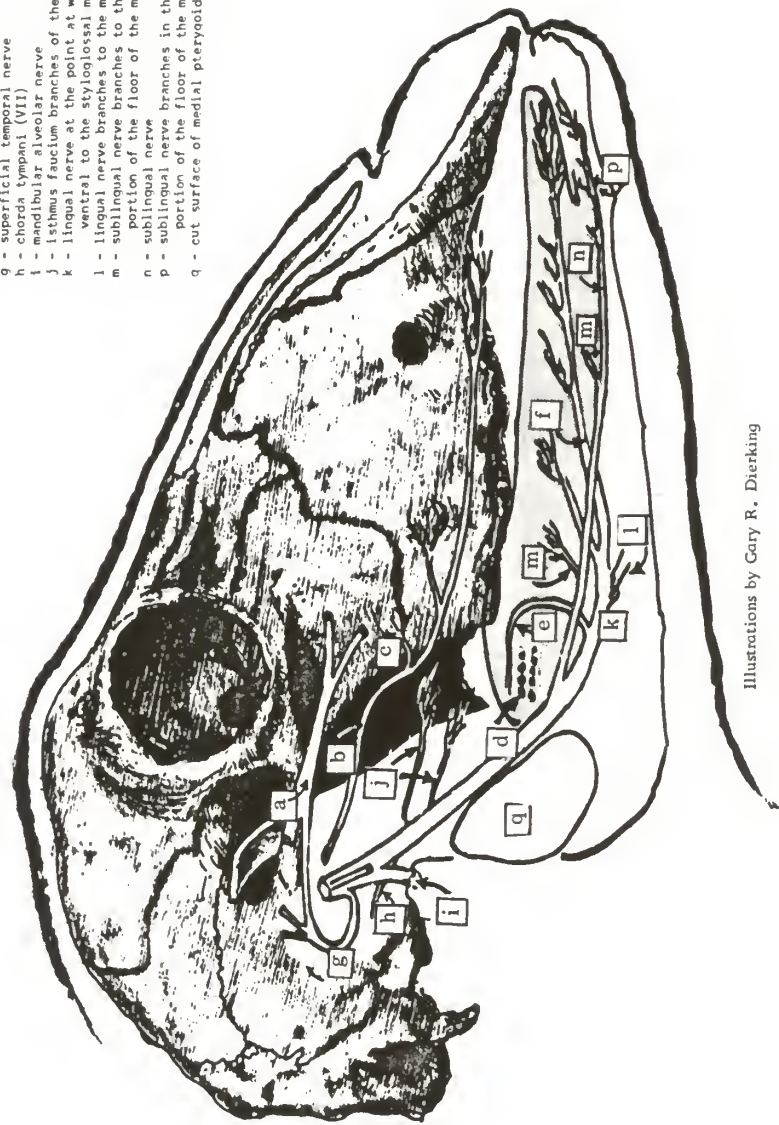
The lingual nerve (fig. 3) passed rostrally and ventrally between the medial and lateral pterygoid muscles and over the lateral surfaces of the hyoglossal and styloglossal muscles. At the ventral border of the styloglossal muscle the lingual nerve passed lateral to the mandibular duct to which it contributed several small branches. The nerve then ran in a dorsorostral direction between the lateral surface of the genioglossal and the medial surface of the styloglossal muscles and divided into a number of branches.

Caudal to the rostral border of the medial pterygoid muscle (at the level of the alveolar tuberosity of the maxilla) the lingual nerve gave rise to one or two small branches which passed rostrally to innervate the mucosa of the isthmus faucium and of the adjacent cheek and over the alveolar tuberosity. The sublingual^{*} nerve arose between the rostral border of the medial pterygoid muscle and the last mandibular cheek tooth.

* This is the term used by Miller (1964) and by Kitchell (1963). Sisson and Grossman (1953) termed this nerve the superficial branch and the continuation of the lingual nerve the deep branch while Romanes (1964) did not name the branches of the lingual nerve.

Fig. 3. The Lingual (V) and Buccinator Nerves (Diagrammatic).

- a - facial nerve before its division into dorsal and ventral buccal branches
- b - buccinator nerve
- c - parotid duct branch of the buccinator
- d - vallate papillae
- e - caudal branch of the lingual nerve
- f - rostral branch of the lingual nerve
- g - superficial temporal nerve
- h - chorda tympani (VII)
- i - mandibular alveolar nerve
- j - isthmus faucium branches of the lingual nerve
- k - lingual nerve at the point at which it passes ventral to the styloglossal muscle
- l - lingual nerve branches to the mandibular duct
- m - sublingual nerve branches to the lateral portion of the floor of the mouth
- n - sublingual nerve
- p - sublingual nerve branches in the rostral portion of the floor of the mouth
- q - cut surface of medial pterygoid muscle



Illustrations by Gary R. Dierking

It passed forward between the medial surface of the ramus of the mandible and the scanty rostral portion of the sublingual gland, parallel to the ventral border of the ramus and about halfway between it and the dorsal border.

In its course the sublingual nerve gave off branches to the long narrow portion of the floor of the mouth lateral to the attached portion of the tongue. The terminal branches of the sublingual supplied the floor of the mouth rostral to the fixed portion of the tongue (this was a comparatively small area in the sheep) and the lingual aspect of the gums of the incisors. No branches communicating with the lingual nerve were detected. For much of its course the sublingual nerve lay ventrolateral, and closely applied, to the mandibular duct.

Some of the terminal branches of the lingual nerve joined with those of the hypoglossal nerve while others passed through loops formed by the hypoglossal branches. The most caudal branch of the lingual passed dorsally from its point of origin which was approximately at the level of the middle of the dorsal prominence of the tongue. After passing medial to the styloglossal and hypoglossal muscles to reach the lamina propria it turned caudally and ran in a course parallel with the lateral edge of the tongue and gradually approaching the epithelium. It ended by branching at a point about 0.5 cm. rostral to the most medial and caudal vallate papilla (fig. 4).

The largest branch of the lingual nerve ran to near the tip of the tongue where it divided into a number of branches that radiated out like a fan. In the sheep most of the fungiform papillae were found in a crescent shaped area around the ventral aspect of the tip of the tongue. The

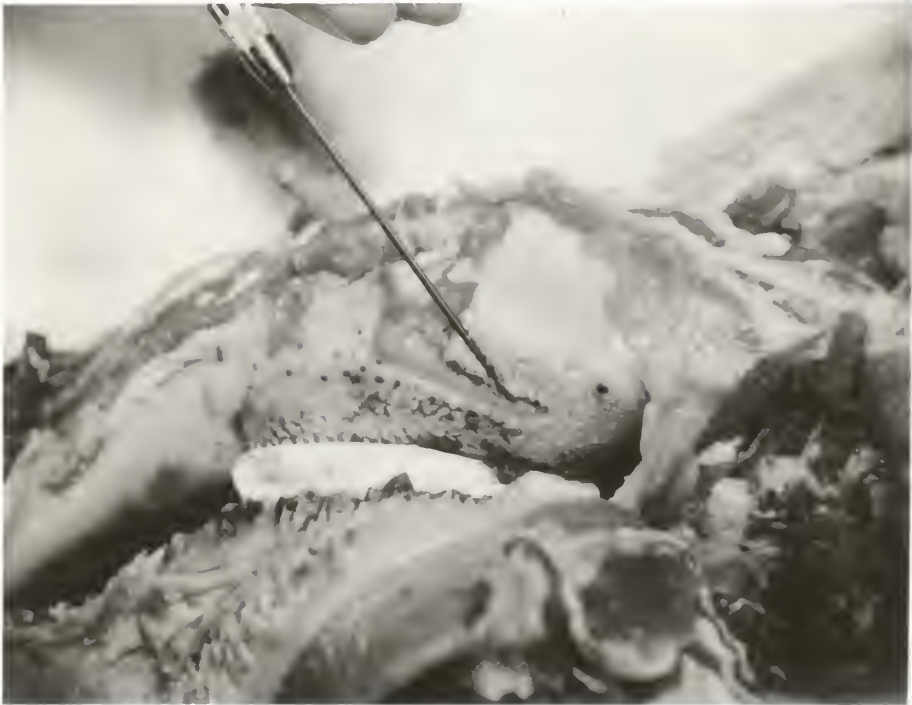

Fig. 4. The Caudal Branch of the Lingual Nerve (V).

The right mandible has been removed and the cheek retracted so that the tongue and the maxillary cheek teeth are visible. The caudal branch of the lingual nerve has been dissected to the point indicated by the tip of the needle where it divided into microscopic twigs. The vallate papillae can be seen lateral to the point of the needle.

rostral part of the dorsum also bore a number of fungiform papillae, the density of which decreased from the tip caudally. Rostral to the dorsal prominence there was a large triangular area free of fungiform papillae. The rest of the fungiform papillae were located in a narrow strip on the lateral edge of the tongue and fibers of the middle branches of the lingual nerve were traced to this strip.

The path described for the most caudal branch is of particular interest in view of the usual statement (based on the exhaustive study of human subjects by Lewis and Dandy, 1930) that the chorda tympani innervates the rostral two-thirds of the tongue and the glossopharyngeal nerve the caudal third (see, for example, Patton, 1960, and Pfaffman, 1959). Few anatomical or physiological studies of taste in ruminants have been reported. However in the most detailed study to date Bernard (1962) reported that in the calf the chorda tympani responded to stimulation of the caudal as well as the rostral parts of the tongue (the glossopharyngeal only responded when the caudal part was stimulated). The caudal branch of the lingual nerve (V) described in the present study would provide an anatomical basis for a similar finding in the sheep.

(c) The Glossopharyngeal Nerve (IX)

The glossopharyngeal (or ninth cranial) nerve left the cranial cavity by means of the jugular foramen. At this point it was closely related to the accessory and vagus nerves (which had a common sheath) and to the cranial cervical ganglion (fig. 1). The carotid sinus nerve was given off near the jugular foramen and the glossopharyngeal nerve divided near the muscular angle of the stylohyoid bone, into the pharyngeal and lingual branches. The pharyngeal branch of the glossopharyngeal joined that of the vagus to form

a plexus on the lateral aspect of the pharynx. For most of its course the lingual branch lay medial and approximately parallel to the ventral border of the stylohyoid bone (the great cornu of the hyoid bone). Halfway between the muscular angle and the rostral end of the bone the nerve dipped down ventrally so that it could be seen from the lateral aspect without removing the stylohyoid bone.

At the rostral border of the thyrohyoid bone (the thyroid cornu of the hyoid bone) the lingual branch of the glossopharyngeal divided into two branches. One of these passed around the rostral border of the thyrohyoid then coursed in a caudal direction medial to the bone to reach the wall of the pharynx where it ramified. The other went to the area of the vallate papillae of the tongue and ramified in the lamina propria.

(d) The Infraorbital Nerve (V)

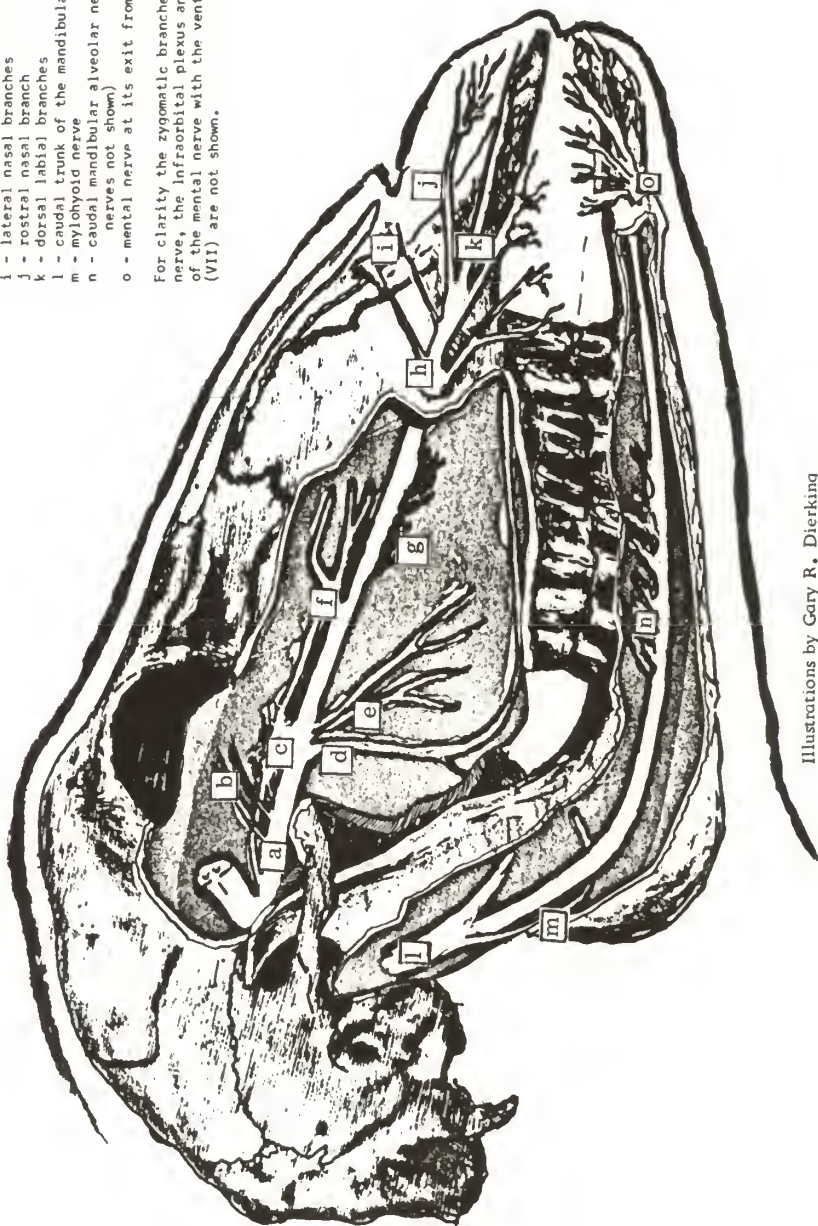
The trigeminal nerve (the fifth cranial nerve) divided into three trunks, the ophthalmic, mandibular and maxillary nerves. The maxillary nerve (fig. 5) in the sheep gave off the zygomatic nerve before it emerged from the foramen orbito-rotundum ventral to the abducens, trochlear, oculomotor, ophthalmic and zygomatic nerves. It passed rostrally across the pterygopalatine fossa to enter the maxillary foramen. In the middle of the fossa it gave off two branches to the periorbita and communicated with the pterygopalatine ganglion. More rostrally the palatine nerve branched off the main trunk. Closer to the maxilla several small caudal maxillary alveolar nerves were formed. The caudal nasal nerve branched off the medial surface of the nerve and divided into two branches one of which ran to the septum and the other to the lateral wall of the nasal cavity.

The continuation of the maxillary nerve was the infraorbital nerve

Fig. 5. The Mental and Infraorbital Nerves
(Diagrammatic).

- a - maxillary nerve
- b - periorbital branches
- c - pterygopalatine ganglion
- d - palatine nerve
- e - caudal maxillary alveolar nerves
- f - caudal nasal nerve
- g - middle maxillary alveolar nerves
- h - infraorbital nerve at its exit from the foramen
- i - lateral nasal branches
- j - rostral nasal branch
- k - dorsal labial branches
- l - caudal trunk of the mandibular nerve
- m - mylohyoid nerve
- n - caudal mandibular alveolar nerves (rostral nerves not shown)
- o - mental nerve at its exit from the foramen

For clarity the zygomatic branches of the facial nerve, the infraorbital plexus and the communications of the mental nerve with the ventral buccal nerve (VII) are not shown.



Illustrations by Gary R. Dierking

which passed rostrally in the infraorbital canal accompanied by the homonymous artery and vein. In the canal it gave off the middle maxillary alveolar nerves which innervated the maxillary sinus and most of the cheek teeth. As the nerve left the infraorbital foramen it divided into a number of branches which were grouped as (1) the lateral nasal branches (small branches that innervated the skin and nasal mucosa in the area of the parietal nasal cartilage), (2) the rostral nasal branch (a large branch that ramified in the floor of the vestibule of the nose and sent twigs to the skin and the mucosa of the most rostral part of the lips) and (3) the dorsal labial branches (large branches that supplied the skin and mucosa of the cheek from the labial commissure forward). The dorsal labial branches communicated with the dorsal buccal nerve (zygomatic branches of the facial nerve--Romanes, 1964) to form the infraorbital plexus. No macroscopic gingival branches of the infraorbital were seen. With the aid of the dissecting microscope twigs of the rostral nasal branch could be seen entering the rostral part of the dental pad. More caudally the buccogingival line of reflection of the mucosa was found to be innervated by twigs from the palatine nerve.

(e) The Mental Nerve (V)

The mental^{*} nerve (fig. 5) arose from the mandibular alveolar nerve within the mandibular canal. In the canal the mandibular alveolar nerve (the origin of which was described previously) gave branches to the mandibular cheek teeth and incisors. The mental nerve divided into a number

* This term was used by Romanes (1964). Sisson and Grossman (1953) termed the branches of the mental nerve the inferior labial and mental branches of the mandibular alveolar nerve.

of branches before it emerged from the mental foramen accompanied by the mental artery and vein. There was only one mental foramen and it was located at the level of the rostral half of the mandibular interalveolar space.

The mental nerves were distributed to the skin of the chin and the submucosa of the lower lip rostral to the mental foramen. A few small branches communicated with the ventral buccal nerve (marginal mandibular branch--Romanes, 1964) and formed what could be called, by analogy with the infraorbital nerve, the mental plexus. In the interalveolar space there was no line of demarcation between gingival and labial mucosae so that it was impossible to differentiate between the innervation of the two. Around the incisors there was a clearly marked line of reflection of the labial mucosa. There were no macroscopic branches of the mental nerve crossing this line but small twigs could be seen entering the gingival mucosa with the aid of the dissecting microscope.

The author's preliminary data derived from experiments with neurectomised sheep suggested that the mental or the infraorbital nerves or both might function in chemoreception. It was important therefore to delineate the areas innervated by the nerves in order to enable physiological recording studies to be carried out and to direct the search for aberrant taste buds such as those located by Pfaffman (1952) around the orifice of the naso-incisor duct of the rat.

SUMMARY

The anatomy of the olfactory, lingual (V), glossopharyngeal, infraorbital and mental nerves of the sheep is described. The most caudal branch of the lingual nerve was found to reach the caudal part of the

tongue in contrast to other animals in which the lingual nerve has been reported to innervate only the rostral two-thirds of the tongue. The significance of the findings is briefly discussed.

PART II

SURGICAL TECHNIQUES OF OLFACTORY DEPRIVATION AND LINGUAL,
GLOSSOPHARYNGEAL, INFRAORBITAL AND MENTAL NEURECTOMYINTRODUCTION

Arnold (1963) has reviewed the literature on the importance of the senses to the grazing animal and has reported preliminary experiments using sense-impaired sheep. Lindsay (1965) has similarly investigated the importance of the sense of smell in reproduction in sheep, using the olfactory lobectomy* technique described below, and Beilharz and Kay (1963) used neurectomies in a study of the sodium appetite of sheep. Tribe (1949) performed olfactory lobectomy on ten-day-old lambs and reported the results of experiments using them.

In order to prepare the sensory deprived sheep used in Arnold's (1963) study and in later similar studies it was necessary to devise rapid simple techniques for the impairment of the tactile sense in the lips and of olfaction and taste. On the basis of some preliminary studies (Arnold, 1963) it was decided to impair the sense of smell by olfactory lobectomy, that of taste by lingual and glossopharyngeal neurectomy and that of labial touch by mental and infraorbital neurectomy.

MATERIALS AND METHODS(a) General

The sheep were divided into groups according to their origin and the

*The term "lobectomy" is used for simplicity to denote the surgical technique even though only the olfactory bulb portion of the olfactory lobe was removed.

methods used in operating on them. The sheep in groups I, II and III were hornless Australian Crossbreds (Merino x Border Leicester) from the C.S.I.R.O. flock. Those in group IV were crossbreds of Hampshire-Rambouillet origin from the flock of the College of Veterinary Medicine, Kansas State University. All animals were considered clinically normal at the time of surgery although no special examinations were carried out.

Group I consisted of yearling wethers weighing 50-70 kg. Surgery was performed by Dr. J. A. Munro^{*} and by the author, during Dr. Munro's demonstration of the technique of olfactory lobectomy to the author. The standard hospital aseptic technique was used during these operations. Anesthesia was induced by intravenous thiopentone sodium (10 mg./kilo) and was maintained by means of a low concentration of fluothane mixed with oxygen in a closed circuit apparatus. The sheep were kept in pens for several weeks before and after surgery, and feed and water were withheld for 24 hours before operating.

The animals in group II were ewes and wethers aged 6-24 months and weighing 25-70 kilos. Olfactory lobectomy and all four types of neurectomy were performed on the sheep. The simplified aseptic technique used included scrubbing of the surgeon's hands and forearms which were then disinfected with benzalkonium chloride (Zephiran--Bayer). Gloves, gowns and masks were not used. The sheep's skin was clipped finely, disinfected with iodine and draped with sterile towels. Up to eight animals were operated on in a day with one assistant who prepared each sheep and anaesthetised it while giving the maintenance doses of anesthetic to the

* From the Dept. of Physiology, Melbourne University. Present address: Royal Melbourne Hospital, Parkville, Vic., Australia.

previous sheep.

Anesthesia was induced and maintained by means of 5% thiopentone sodium injected through a polyethylene cannula introduced into the external jugular vein through a 14 gauge needle. The initial dose was 6-8 ml. and injection was continued slowly until the jaw was slack. Maintenance doses of 2 ml. were given as required. All except the first ten animals were intubated with an endotracheal tube (Magill size 8) and, in case of respiratory arrest were given 150 mg. of bemegride (Megimide--Abbotts) and, if necessary, mouth-to-tube artificial respiration. The suture material was of a non-capillary synthetic type (Vetafil Medium--Bengers). A single dose of all-purpose penicillin (1.2 m. units of "Bicillin"--Wyeth) was injected after surgery. The sheep were held in pens without feed or water for 12-24 hours before surgery and were returned to pasture as soon as they had recovered consciousness.

Group III consisted of eight yearling wethers weighing about 50 kg. They were operated on under very unfavorable conditions, in a dusty, fly-infested barn and using tranquilizers and local anesthesia. Benzalkonium chloride was used to disinfect the instruments, the sheep's skin and the surgeon's hands. The infraorbital and mental nerves of four of these sheep were cut while the other four (selected randomly) served as controls and were subjected to the identical procedure except for the actual severing of the nerves.

There were three yearling wethers in group IV. Tracheotomies were performed on them using the same general technique described for group II except that in the absence of an assistant the maintenance doses of anesthetic were given by the surgeon.

(b) Olfactory Deprivation

Olfactory Lobectomy. A 7-10 cm. incision was made in the midline from the highest point of the poll forward. The skin and periosteum were reflected laterally as far as possible and a 2.5 cm. trephine was used to make an opening into the frontal sinus at the level of the supra-orbital foramen. The hole was enlarged as necessary with bone forceps (rongeurs) and the mucosa of the frontal sinus was stripped out. Bleeding was stopped by electro-cautery (group I) or by plugging the periphery of the sinus with swabs and cotton.

The thickness of the internal plate of the frontal bone was very variable so that great care was necessary in entering the cranial cavity. A 0.95 cm. trephine was used to make an opening on each side of the medial septum just caudal to the angle of the internal plate. If the opening was made more rostral it was likely to enter the nasal cavity making intracranial infection highly probable while if it was made more caudal there was more damage to the cerebral hemispheres during the probing of the ethmoidal foramen. The hole was temporarily plugged with bone wax to stop the bleeding.

The dura was cut and a blunt probe was passed through the incision and used to disrupt the olfactory lobe within the ethmoidal fossa. Probing was thorough in an attempt to ensure that all the neural tissue had been disrupted. On the other hand the surgeon had to take care to be as gentle as possible in order to avoid breaking the larger vessels. Hemorrhage from these was the cause of death in several animals. The blood and tissue were removed by suction in group I but not in most of the animals in group II. The ethmoidal fossa was packed with small cotton balls which were left in

place for at least five minutes and were replaced for a further period if excessive bleeding was still occurring at the end of the first. The fossa was packed with absorbable gelatin sponge, the frontal sinus was dusted with penicillin and sulfanilamide powder and the skin incision was closed, using continuous mattress sutures.

Other Methods. Other methods of olfactory impairment included the use of a tracheotomy to bypass the olfactory apparatus. The tracheotomy was carried out through a midline incision made in the middle of the ventral cervical region. Half-moon pieces of adjacent tracheal rings and the associated ligaments and tissue were excised and a polyethylene tube that fitted the lumen of the trachea snugly was inserted and anchored by a suture passed through the tube and tied to the skin suture. The external nares were blocked with adhesive tape. The adhesion of the tape was improved by using a rubber-based glue and it was held in place by pieces passing behind the ears and around the jaws (taking care not to curtail the normal jaw movements of eating). The tape was tolerated well by the sheep in contrast to swabs placed within the nostrils which caused violent head shaking and reflex sneezing (even though there was no expulsion of air these movements were sufficient to dislodge the swabs).

One sheep from group II was used in an attempt to assess the method of chemical destruction of the olfactory mucosa described by Smith (1938) in rats. The sheep was anaesthetised and intubated, its head was inverted and 50 ml. of a solution of zinc sulphate (1%) and sodium chloride (0.5%) was injected into one nostril. The solution ran out of the other nostril. The solution was at once drained out of the nasal cavity by lowering the head. Four days later the sheep was slaughtered.

(c) Lingual and Glossopharyngeal Neurectomy

The glossopharyngeal neurectomy was regarded as more difficult and more likely to be complicated by hemorrhage and was therefore routinely done before the lingual neurectomy. The sheep was fastened in dorsal recumbency and the head and neck were fixed in an outstretched, inverted position by means of bolsters. The skin incision was made in the midline of the intermandibular space from the laryngeal prominence to about two inches caudal to the mandibular symphysis. Mayo scissors and the scissor opening technique were used to dissect the skin and the cutaneous muscle away from the subcutaneous tissue. The fingers were used to separate the connective tissue and retract the omohyoid muscle medially and the submandibular gland and the stylohyoid bone laterally in order to create a space between the stylohyoid bone and the larynx (fig. 6).

The lingual branch of the glossopharyngeal nerve in some sheep was found along the medial side of the stylohyoid bone and in other sheep was detached from this position during the retraction so that it crossed the floor of the space from the caudal, medial corner to the rostral, lateral one. The nerve had a characteristic fasciculated appearance, which was used to differentiate it from the branches of the pharyngeal plexus in this area, and it was much smaller than the hypoglossal nerve (which was found on the lateral side of the stylohyoid bone unless unusual distortion of the tissues had occurred).

The next step was done as rapidly as possible as there were a number of small, fragile vessels in the area (though none immediately associated with the nerve) and as the field was so small that even a slight hemorrhage obscured the nerve. The lingual branch of the glossopharyngeal nerve was

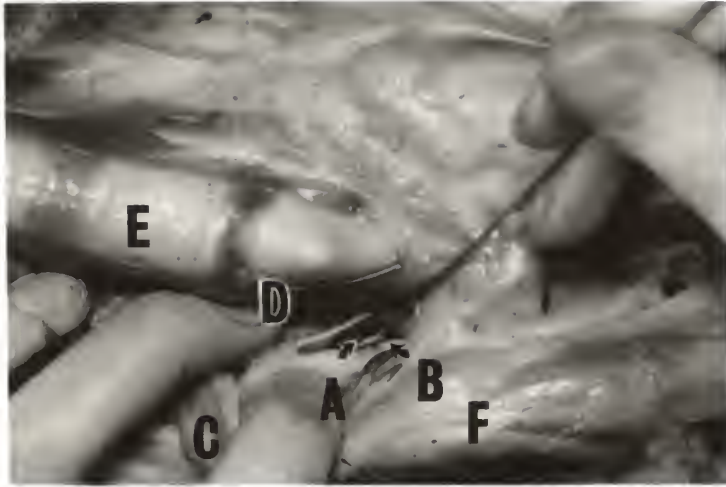


Fig. 6. The Surgical Approach to the Glossopharyngeal Nerve.

a, Lingual branch of glossopharyngeal nerve; b, Stylohyoid bone;
c, Mandibular gland; d, Omohyoid muscle; e, Trachea; f, Angle of
mandible.




Fig. 7. The Surgical Approach to the Lingual Nerve.

g, Lingual nerve; h, Hypoglossal nerve; i, Mylohyoid muscle (cut and
retracted); j, Angle of mandible.

grasped with dissecting forceps, placed over a hook and drawn up out of the cavity. The use of the hook, which was made by bending a blunt probe around the jaw of an old hemostat, made isolating the nerve much easier. At this stage the identification of the nerve was confirmed by the typical enlargement at the point at which it divided into two branches, one of which went to the caudal part of the pharynx and the other to the tongue. The nerve was severed by sliding partly open scissors along the proximal part and cutting as deeply as possible. Then the distal part was pulled until it broke thus removing a portion of the nerve. The other glossopharyngeal nerve was then cut in a similar fashion, using the same skin incision.

The skin and cutaneous muscle were then dissected free from the subcutaneous tissue, and retracted, at a point approximately two inches rostral to the angle of the mandible. An opening was made in the connective tissue lateral to the external maxillary vein and caudal to the origin of the lingual vein (this landmark was usually obvious as soon as the skin was retracted). A finger was used to bluntly divide the mylohyoid muscle.

The lingual nerve could be seen coursing deep to the opening made in the mylohyoid muscle, on the fascia overlying the more medially located styloglossal muscle (fig. 7). The hypoglossal nerve at this point was more superficial and parallel to the ventral border of the mandible. The chief dangers in using this approach were those of making too rostral an incision so that the nerve could not be located and of hemorrhage which rapidly obscured the field. The advantage of this approach was that all the branches of the lingual nerve were severed.

The nerve was then grasped as proximally as possible with dissecting forceps and the hook, and cut using the technique described for the glossopharyngeal nerve. After the nerve on the opposite side had been

divided the skin incision was closed using continuous mattress sutures. Occasionally there was some swelling after the operation but this always cleared up in a few days.

(d) Infraorbital and Mental Neurectomy

For the infraorbital neurectomy the sheep was placed in lateral recumbency and the head fastened down. A two-inch incision was made starting at (and at right angles to) the lower border of the maxilla and just in front of the infraorbital foramen. In those animals in which it was impossible to palpate the foramen the incision was located at the rostro-caudal level of the first cheek tooth. The skin was retracted and blunt dissection was used to expose and free the dilatator naris muscle which lies over the foramen and which is the most dorsal muscle in this area of the head (there are no levator naris muscles in the sheep).

The foramen was exposed by retracting the muscle ventrally and separating it from the facial vessels which ran along its dorsal border. The approach was more difficult in those cases in which the initial incision was inadvertently made caudal to the foramen. Separating the infraorbital blood vessels from the nerves was often found to be very difficult and rather than risk leaving the nerves intact the blood vessels were usually severed. The nerves were cut as close to the foramen as possible and the distal ends were grasped with hemostats and pulled out so they broke as far distally as possible. The incision was closed with a continuous mattress suture and the procedure was repeated on the other side.

For the mental neurectomy the sheep's head was fastened in the position described for the glossopharyngeal neurectomy. A 5-7 cm. incision was made

in the midline from just behind the mental pad and the skin was retracted laterally. Blunt dissection was used to separate the buccinator muscle from the mandible and expose the mental foramen which was palpated through the subcutaneous tissue. If possible the mental blood vessels were separated from the nerve which was grasped with hemostats and cut in the same way as the infraorbital nerve. Occasionally the artery was broken off inside the mental foramen, where it was inaccessible for clamping and tying, but no harm seemed to be done in those cases which were sutured while still bleeding. After the nerves on both sides had been cut the skin incision was closed with continuous mattress sutures.

In the sheep in group II that were subjected to infraorbital and mental neurectomy, the sublingual nerve was also cut. It was reached through the same incision as the mental nerve. A hole was made in the mylohyoid muscle by the scissor opening technique and the nerve was located medial to the ramus of the mandible. It was dissected free from the surrounding tissue (including the mandibular duct) and cut in the same way as the infraorbital nerves.

RESULTS

All the sheep in group I were used in the development of the olfactory lobectomy technique. The results obtained with these animals are summarised in table 1. All the animals that died within 48 hours of surgery were found on necropsy to have had the olfactory lobe and bulb completely removed. Among those of the survivors that were later necropsied the surgical efficacy varied from approximately 50% to 100% removal of the bulb. Only two of these seven survivors had had the bulb completely removed.

Of the sheep in group II, 32 were subjected to olfactory lobectomy.

Table 1

Tag no.	Efficacy*	Comments
2772	100	P-O**--infection, nasal cavity entered
2817	100	P-O**--infection, no other complication
2882	100	P-O**--infection, <u>Oestrus ovis</u> present
3469	Lost eartag, lived at least 15 months
3828	100	Killed 2 years after surgery
3951	Lost ear tag, lived at least 4 months
3960	100	Killed 2 years after surgery
3983	+50	Killed 2 years after surgery
4020	99	Killed 2 years after surgery
4026	Died 6 months after surgery, no autopsy
A168	100	P-O**--hemorrhage#
C652	65	Killed 2 years after surgery
X386	+75	Killed 6 months after surgery
X387	100	P-O**--cerebral hemispheres damaged
X404	65	Killed 6 months after surgery

*Estimate at necropsy of percentage of cribriform plate free of nervous tissue.

**Died within 48 hours of surgery

#The cribriform plates of this animal were scraped much more severely than usual during a demonstration of the technique.

Of these, one was killed during surgery after a cotton ball was lost in the cranial cavity, one died of respiratory arrest during surgery and three died within a week of surgery probably as a result of intracranial hemorrhage. The heads of two of these three were examined. The efficacy of removal was 100% in the one and 75% in the other. All of the others were still alive 18 months after surgery.

The attempt to destroy the olfactory mucosa chemically was considered to be unsuccessful as no evidence of inflammation of the olfactory area of the treated animal was found at necropsy. It was thought that the solution had not penetrated between the ethmoturbinates which were tightly coiled and complex.

Lingual and glossopharyngeal neurectomies were performed on 36 sheep in group II. One died during surgery, two died during or after subsequent olfactory lobectomy and one died a month after surgery and was found to have an abscessed lung. One sheep was euthanatized at the time of surgery because it was believed that some nerve other than the glossopharyngeal had been severed. At necropsy that suspicion was confirmed. The lingual and glossopharyngeal nerves of all the other animals necropsied had been cut, as had those of two animals used in the development of the technique and killed immediately after surgery. During an experiment not otherwise included in this report the glossopharyngeal nerve of a sheep similar to those in group IV was isolated and a thread was tied around it. At necropsy it was confirmed that the correct nerve had been isolated.

The infraorbital and mental nerves of nine sheep in group II and of four sheep in group III were cut. There was a high incidence of abscess formation in all eight sheep in group III. There was no significant

difference between the experimental and the control sheep of group III in live weight change or in feed intake.

Two sheep were subjected to lingual, glossopharyngeal, mental and infraorbital neurectomies and 13 to olfactory lobectomy combined with lingual and glossopharyngeal neurectomies. These animals were included in the totals for the individual operations listed above. None of the animals subjected to multiple neurectomies (or milder procedures) chewed their tongues. They all ate hay normally but tended to dribble pelleted feed out of their mouths while chewing it. In a number of animals ulcers 1-2 cm. in diameter were observed on the dorsum of the tongue. The cause of the ulcers could not be determined.

There were two deaths attributed to anesthesia in group II. One of these sheep had inadvertently not been fasted before surgery and was one of the animals that were not intubated. Regurgitation occurred while the animal was on its back and it inspired ingesta and died before it could be righted. After this incident intubation was made routine. The other sheep died during a lobectomy in which it was recorded that excessive damage had been done to the cerebral hemispheres. Injection of bemegride and artificial respiration failed to revive it.

The three animals in group IV had been subjected to a series of procedures before the tracheotomy and were moderately sodium deficient at the time. They all failed to eat for about 24 hours after surgery although their jaw movements did not seem to be restricted by the tape. Later they partially regained their appetite. Within about a week labored, noisy respiration occurred and it was found that the tracheotomy tube had become partially obstructed with dried mucus, pus and blood. As the

necessary observations had been completed the tube and tape were removed and the tracheotomy wound was allowed to close.

DISCUSSION

Complete removal of a sense is not essential (though it may be desirable) in studying the role of that sense in a particular behavioral pattern. Provided that some behavioral alteration was produced one could validly claim that the sense was necessary for the normal behavioral pattern. One could not claim that it was the only sense involved nor could one argue from a lack of response as a response might have occurred had the sense been completely removed.

Incomplete sensory removal may at times be an advantage. Beilharz and Kay (1963) reported that cutting the buccinator (buccal--Romanes, 1964) as well as the glossopharyngeal and lingual nerves resulted in chewing of the tongue whereas the denervation reported in the present study did not have this effect. Pfaffman (1952) found that cutting the chorda tympani and glossopharyngeal nerves only attenuated the sodium chloride preference of rats. Commenting on Richter's (1939) finding that cutting the lingual, chorda tympani and glossopharyngeal nerves abolished the preference he said: "... removal of the lingual nerve eliminates not only taste but all sensibility from the anterior tongue. Animals so operated may damage their own tongues by biting and chewing. Drinking is difficult. Under these conditions discrimination might fail because of a generalized incapacity rather than a specific loss of taste sensitivity."

The variability in the surgical completeness of the olfactory lobectomy presents a special problem. The answer may be in a variation in the surgical technique although Tribe (1949) using a more radical approach

(on 10-day-old lambs) reported that of the two animals necropsied one had only two thirds of the lobe removed. One might assume that one or more of his three experimental animals may have had only part of the bulb removed; however he detected no behavioral differences among them.

Similarly the present author was unable to distinguish between the reactions of different lobectomised animals to the presentation of a cotton wad soaked in carbon disulphide (or, for that matter, between their reactions and those of normal sheep). Arnold* on the basis of unpublished data prepared a score for the estimated olfactory acuity of the lobectomised sheep, but this was found to have no relationship to the necropsy findings. Since it was impossible to detect differences among the lobectomised sheep it was of course also impossible to detect prior to necropsy those animals which had had the lobe completely removed. The technique of tracheotomy and taping the nose would overcome this difficulty. It has not been tested under field conditions but Cresswell's (1962) report indicates that it should be possible to maintain the animals for suitably long periods.

The neurectomies had the advantage of being surgically repeatable. Variation between animals after surgery was thus solely due to the normal biological variation which is very great in this area of physiological psychology. This source of variation may be reduced by the use of monozygotic twins (Bell, 1959, has used twin calves) but the incidence of these in sheep is low and detection is difficult. The author (preliminary experiments) has used the sodium preference of sodium deficient sheep as a model system for studying the role of the senses in intake regulation.

* Arnold, G. W. (1963) C.S.I.R.O., Canberra, A.C.T., Australia.

Selected groups showed little variation from day to day or among sheep.

Pending more detailed anatomical and physiological studies it is not possible in the lower animals to refer to the complete removal of the olfactory or gustatory senses since there are probably unknown pathways for the perception of stimuli usually associated with these senses. As examples we may take the trigeminal responses to odorants reported by Tucker (1963); the taste buds found near the naso-incisor duct of the rat by Pfaffman (1952) and the author's unpublished data showing that a greater change was produced in the sodium appetite of sodium deficient sheep by mental, infraorbital, lingual and glossopharyngeal neurectomy than by the section of the latter pair of nerves alone. Whether such results are attributed to extensions of the gustatory or olfactory senses, to the common chemical sense or to some new sense seems to be of little import.

Despite these difficulties the techniques described have been of great value in behavioral studies in sheep. Arnold* reported marked differences in acceptance of herbage species between normal sheep and the sense impaired sheep described in the present paper. Both Arnold* and the author in unpublished studies have found alterations in the sodium appetite of sodium deficient sheep after section of all four of the nerves discussed in contrast with Beilharz and Kay (1963) who found that section of the lingual, glossopharyngeal and buccinator had little effect.

SUMMARY

Surgical techniques for olfactory impairment and lingual,

* G. W. Arnold (1964)--unpublished annual report of the Grasslands Agronomy Section, C.S.I.R.O., Canberra, A.C.T., Australia.

glossopharyngeal, infraorbital and mental neurectomy are described. One hundred sheep were included in the study. The variation in the efficacy of the olfactory lobectomy and the interpretation of results obtained from experiments with sense deprived sheep are discussed.

GENERAL SUMMARY

The anatomy of the olfactory, lingual (V), glossopharyngeal, infra-orbital and mental nerves of the sheep and surgical techniques for the impairment of the olfactory sense and for lingual, glossopharyngeal, infraorbital and mental neurectomy are described. The caudal terminal branch of the lingual nerve (V) was found to reach the caudal portion of the tongue and the significance of this difference between sheep and other animals in which the lingual nerve has been reported to innervate only the rostral two-thirds of the tongue is discussed. One hundred sheep were included in the impairment study. The variation in the efficacy of the olfactory lobectomy technique described and the interpretation of the results obtained from experiments with sense deprived sheep are discussed.

ACKNOWLEDGMENTS

The work described in this thesis was performed while the author was an officer of the Division of Plant Industry, Commonwealth Scientific and Industrial Research Organization (C.S.I.R.O.) and while a Research Associate in the Department of Anatomy, College of Veterinary Medicine, Kansas State University, on leave from C.S.I.R.O.

The author is indebted to Dr. J. A. Munro (Royal Melbourne Hospital) for invaluable instruction and assistance in the development of the olfactory lobectomy technique and to Dr. D. A. Denton (Howard Florey Institute, Melbourne) for making this possible. Without the cheerful and efficient assistance of Mr. T. J. Shepherd (C.S.I.R.O.) it would have been impossible to have performed the number of operations performed--and without the friendly insistence of Dr. G. W. Arnold (C.S.I.R.O.) the motivation might have been lacking. The author's thanks also go to Dr. F. H. W. Morley (C.S.I.R.O.), Prof. D. M. Trotter (K.S.U.) and Dr. R. L. Kitchell (K.S.U.) for enabling the author to spend a very pleasant, constructive year at Kansas State University during which part of this work was done.

LITERATURE CITED

- Arnold, G. W. (1963). Ph. D. Thesis, University of London.
- Beilharz, S. and R. N. B. Kay (1963). J. Physiol., 165: 468.
- Bell, F. R. (1959). Nature, 183: 345.
- Bernard, R. A. (1962). Ph. D. Thesis, Cornell University.
- Cresswell, E. (1962). Empire J. exp. Agric., 30: 82.
- Denton, D. A. (1957). Quart. J. exp. Physiol., 42: 72.
- Kitchell, R. L. (1963) in Zotterman, Y. (ed.). "Olfaction and Taste."
Macmillan: 1st ed., London.
- Lewis, D. and W. E. Dandy (1930). Archives of Surgery, 21: 249.
- Lindsay, D. R. (1965). Animal Behaviour (in press).
- Miller, M. E. (1964). "Anatomy of the Dog." Saunders: 1st ed., Philadelphia.
- Patton, H. D. (1960) in Ruch, T. C. and J. F. Fulton. "Medical Physiology and Biophysics. 18th ed. of Howell's Textbook of Physiology."
Saunders: Philadelphia.
- Pfaffman, C. (1952). J. comp. physiol. Psychol., 45: 393.
- Pfaffman, C. (1959). in Field, J. (ed.). "Handbook of Physiology," vol. 1, sec. 1. American Physiol. Society: 1st ed., Washington.
- Ranson, S. W. and S. L. Clark (1959). "The Anatomy of the Nervous System."
Saunders: 10th ed., Philadelphia.
- Richter, C. P. (1939). Trans. Amer. neurol. Assoc., 65: 49.
- Romanes, G. J. (1964). "Cunningham's Textbook of Anatomy." Oxford:
10th ed., London.
- Sisson, S. and J. D. Grossman (1953). "The Anatomy of Domestic Animals."
Saunders: 4th ed., Philadelphia.
- Smith, C. G. (1938). Canad. med. Assoc. J., 39: 138.
- Taylor, J. A. (1955). "Regional and Applied Anatomy of the Domestic Animals, Part One, Head and Neck." Oliver and Boyd: 1st ed., Edinburgh.
- Tribe, D. E. (1949). J. agric. Sci., 39: 309.

Tucker, D. (1963). J. gen. Physiol., 46: 453.

von Braun, A. (1892). Archiv für mikroskopische Anatomie, 39: 651.

THE ANATOMY AND SURGICAL DEPRIVATION OF THE ORAL
AND NASAL SENSES IN THE SHEEP

by

HAROLD WAKENSHAW CHAPMAN

B. V. Sc., University of Sydney, 1960

AN ABSTRACT OF A MASTER'S THESIS

submitted in partial fulfillment of the

requirements for the degree

MASTER OF SCIENCE

Department of Anatomy

KANSAS STATE UNIVERSITY
Manhattan, Kansas

1965

Sheep with deficits of taste, olfaction and labial tactile senses were required for experiments on the role of these senses in the ingestive and reproductive behavior of sheep. Insufficient details of the anatomy of the principal nerves involved in these senses were available in the literature so that an anatomical study was necessary in conjunction with the development of the surgical techniques.

The nasal cavity was found to be innervated by several branches of the trigeminal nerve (V) and of the olfactory nerve (I). Branches of the olfactory nerve were found on the medial and lateral walls of the nasal cavity as well as in the main olfactory area on the mucosa of the ethmoturbinates. The vomeronasal organ, which was innervated by the olfactory nerve, was a closed cylinder in the sheep dissected.

The major branches of the maxillary (V) and mandibular (V) nerves were identified. The lingual, infraorbital and inferior alveolar (which later becomes the mental) nerves were traced from their origins and their branches located. The chorda tympani (VII) nerve joins the lingual nerve near its origin bearing the fibers which innervate the taste buds. The most caudal terminal branch of the lingual (V) was found to reach the caudal part of the tongue in sheep in contrast to other animals in which the lingual nerve is regarded as innervating only the rostral two-thirds of the tongue. The origin and branching of the glossopharyngeal (IX) nerve and the course of its lingual and pharyngeal branches were traced. The lingual branch terminates by branching in the caudal portion of the tongue near the vallate papillae.

One hundred sheep were used in the surgical study. The olfactory bulb and tract on each side were disrupted by means of probing through a

small opening in the internal plate of the frontal bone made as close as possible to the cribriform plate of the ethmoid bone. The efficacy of this operation was 100% in those animals that died just after surgery but varied from 50-100% in the survivors. Other methods of olfactory deprivation included the use of a tracheotomy to bypass the olfactory apparatus and an unsuccessful attempt to destroy the olfactory mucosa chemically.

The lingual branch of glossopharyngeal nerve was cut medial to the stylohyoid bone before the formation of its lingual and pharyngeal terminal branches and using a rapid, simple ventral approach. The ventral approach was also used to transect the lingual nerve (V) near its emergence from between the pterygoid muscles. The infraorbital and mental nerves were cut at their foramina.

Incomplete removal of a sense did not prevent the use of the sheep for behavioral studies. It may have been an advantage in that the more limited behavioral changes were probably more specifically related to the senses under study.