

A GROSS AND MICROSCOPIC STUDY OF THE BONE MARROW  
OF CLINICALLY ACCESSIBLE BONES OF THE  
IMMATURE, THE MATURE, AND THE AGED CAT

by

MARTIN RAYMOND FREY

B. S., Kansas State University, 1956  
D. V. M., Kansas State University, 1956

---

A MASTER'S THESIS

submitted in partial fulfillment of the

requirements for the degree

MASTER OF SCIENCE

Department of Anatomy

KANSAS STATE UNIVERSITY  
Manhattan, Kansas

1961

## TABLE OF CONTENTS

INTRODUCTION .....	1
MATERIALS AND METHODS .....	2
REVIEW OF LITERATURE .....	8
OBSERVATIONS .....	14
DISCUSSION .....	23
SUMMARY .....	31
ACKNOWLEDGMENTS .....	33
LITERATURE CITED .....	34
APPENDIX .....	39

## INTRODUCTION

Bone marrow studies of all animals have logically been concentrated on individual cellular detail and differentiation. Cellular distribution and concentration of various body marrow was often of interest to the clinician or pathologist only to the extent that he had to know which areas within accessible bones would yield cellular marrow. Most of these areas within animals were chosen either on the basis of assumptions that the cellularity pattern resembled that of man, or because of the worker's previous observations at the necropsy table.

This study of the bone marrow cellularity of a random population of mongrel cats was undertaken in an effort to add to the available knowledge concerning variation in cell concentration of marrow from various areas of the body. In this study, the areas chosen were those from which marrow was taken for most studies in laboratory animals. These areas were the proximal ends of the femur, humerus, and tibia, and the iliac crest region of the ilium. Information from these areas was hoped to serve as a foundation for later more inclusive marrow observations. Cats were used because of their availability and because their susceptibility to infectious and neoplastic diseases of the blood-forming organs made marrow examination a rather common clinical procedure.

In an effort to achieve objective measurements, the cellularity of that marrow which was available in large pieces (from the femur and the humerus) was appraised photometrically.

Preliminary work also was done with stain color separation by photographic negatives in anticipation of more refined photometrical measurement of marrow cellularity in later studies.

Because chronological ages of the available cats were not known in most cases, an effort was made to divide the subjects into biological age groups on the basis of epiphyseal cartilage and dental studies.

## MATERIALS AND METHODS

### Selection of Experimental Animals

Approximately 40 mongrel cats were collected for the study. In many instances, no history was available concerning age, previous illness, or recent diet of the animals. It was decided to select only on the basis of absence of apparent clinical symptoms of disease, current normal appetite, and determination of a hematocrit and blood leucocyte count which could be considered close to or within the normal range. Hematocrits were determined by the use of capillary tubes and a high speed microhematocrit centrifuge using a running time of three minutes. White blood cell counts were determined by ordinary laboratory techniques employing National Bureau of Standards tested pipettes and the AO bright-line hemacytometer. No animals were used for this study if the microhematocrit readings were below 24 or the total leucocyte count was below 5,000/cu mm of blood. An exception was made for the three-week-old kitten with a hematocrit of 20. Leucocytosis was not determined in blood samples taken from any

of the cats which had been eating normally and which were therefore considered for use in this project. With the exception of the animals identified as Nos. 1 through 6, all 31 of the cats finally selected for use in the study were observed for a period of at least one week during which time they were fed a standard commercial pet ration.

#### Tissue Collection, Preparation, and Evaluation

Collection procedures on each individual cat followed a standard pattern. The cat was first weighed and then administered an anesthetic dose of sodium pentobarbital intraperitoneally. After surgical anesthesia was reached (usually about 20 minutes), cardiocentesis was performed to collect five cc of the peripheral blood, using ethylene diamine tetra acetate as the anticoagulant. The animal was then euthanatized by an injection of magnesium sulfate into the brain stem through the foramen magnum. As rapidly as possible, the humerus, ilium, femur, and tibia of the left limbs were removed and partially defleshed.

Marrow samples of the femur and humerus were removed from the medullary cavity at the junction of the proximal and middle thirds of each bone. This site was determined by measurement, and half of the cortical bone was chipped away six millimeters proximally and distally from this point to gain access to the marrow. Thus each sample, if entire, was approximately 10 to 12 millimeters in length. An attempt was made to collect all the marrow in this length of the cavity as one piece. When the consistency

of the sample was such that it was not possible to collect it as a single unit, the marrow was scooped out and allowed to adhere to a small piece of porous paper.

A jeweler's saw with a number four blade was used to remove tissue from the ilium and the tibia. The first cut on the ilium was made by starting at the cranial dorsal iliac spine of the tuber sacrale and proceeding in a direction perpendicular to the long axis of the wing of the ilium. A second cut was made parallel and two to three millimeters caudal to the first so that the tissue taken represented a good cross section through the ilium at this level. It was believed that this tissue, when sectioned, would show just what type of marrow could be reached by inserting a biopsy needle into the thick dorsal part of the iliac crest. The first cut in the proximal end of the tibia was started from the articular surface with the cutting blade directed on an imaginary line from the tibial tuberosity to the very postero-medial projection of the medial condyle. Because of the convexity of the medial border of the medial condyle, the cut, started on this line and continued distally from the articular surface, separated the dense cortical bone from the medial surface of the epiphysis and shaft of the tibia. This cut was continued distally for two to three centimeters, depending on the size of the bone. A second cut was started on a line two to three millimeters lateral and parallel to the first cut and continued distally for the same distance.

Marrow tissue thus obtained, usually within 30 minutes after death of the animal, was fixed for a period of 24 to 36 hours. One of the mixtures known as "Kaformacet" was employed as the tissue fixative. The mixture used contained 425 cc of five percent potassium dichromate, 50 cc of 40 percent formalin, 25 cc of 95 percent glacial acetic acid, and 500 cc of distilled water per liter as used by Kristensen (1949).

After fixation and 24 hours of washing in tap water, the tissues were added to a solution made up of equal parts of 85 percent aqueous formic acid and 20 percent aqueous solution sodium citrate for decalcification as used by Custer (1932). The time required for effective decalcification of the densest bone in the tissues varied from 24 to 48 hours. Though bone spicules were rarely present in the humeral or femoral marrow, these specimens were always subjected to the same treatment as the tissues from the ilium and the tibia. Following decalcification, the tissues were again washed for 24 hours and put into metal capsules. Dehydration was accomplished in a series of increasing strengths of isopropyl alcohol. After dehydration through 95 percent isopropanol, the dense cortical bone was trimmed away from iliac and tibial specimens and all tissues were left in 98 percent ethanol for a 12-hour period. From this point, the tissues were prepared for celloidin embedding. This required three-hour pre-treatments in each of two changes of 100 percent ethanol and each of two solutions of absolute ethanol and ether (equal parts). The tissues were then embedded by immersion in a two

percent alcohol-ether solution of Parlodion (Mallinckrodt) for four days. During this period, the tissues in the embedding fluid were sealed in a desiccator jar to prevent moisture condensation and excess solvent evaporation. Hardening of the tissues was effected by immersion in two changes of chloroform for 12 hours each. Double-embedding was completed in a paraffin bath at 56 to 57 degrees Fahrenheit under partial vacuum. Paraffin blocks were cast in paper boats, hardened in ice water and refrigerated. The paraffin used in embedding and block-casting had a melting point rating of 54.9° F.

Sections were cut at five microns, mounted on glass slides, and held in an oven at 57° F. for a minimum of 12 hours. The mounted sections were then passed through acetone, xylene, decreasing strengths of isopropanol, and finally water. Tissues were stained for six hours in a water solution of Gallocyanin which was used as a bone marrow nuclear stain by Kristensen (1949). After staining, the sections were dehydrated and coverslipped in the usual manner. Canada balsam was used as the mounting medium.

Slides of the four areas in each cat were evaluated visually with a 16 millimeter microscope objective lens, using a 10X eyepiece. Identifying numbers of each slide were masked for the period of this examination. Each slide was judged to fall within one of five categories of cellularity, from five for the most cells, down to one for the type of marrow having the fewest cells. These categories are described and illustrated in Plates I through V (Appendix).



The humerus and femur marrow sections were additionally judged for relative cellularity on the basis of light absorption by the stained nuclei. With the sensing head of a photometer (model 200 M, Photovolt Corporation, New York, New York) attached to the photography tube of an AO, Spencer binocular microscope, the photometer scale was adjusted to a reading of 100 by changing the intensity of the light passing through the optical system as well as the glass slide, cover slip, and mounting medium near the edge of the marrow object. The measurement of light passage was then determined for five representative fields of the marrow section, using the 16 millimeter objective lens and 10X eyepiece. In a few cases, the section was not large enough to permit five readings, or was not arranged so that tissue completely filled the field for the purpose of even one reading.

Light intensity was readjusted to achieve a reading of 100 on the scale when using the four millimeter objective lens and 10X eyepiece. Using this objective, 10 fields were randomly chosen by selection of marks on the stage micrometer and then viewing to be certain that tissue completely filled the field. Two of the slides were not satisfactory for light absorption determination.

#### Gross Marrow Evaluation Procedures

After the marrow samples were removed, observed, and placed in the fixative solution, the remainder of the marrow in each of the four bones under study was examined and gross observations

were recorded. These observations were limited to color. The marrow cavities were exposed by splitting the cortical bone with bone cutters. This avoided the smearing of red marrow experienced when a saw is used.

#### Age Studies

Following the gross examination of marrow, the right humerus and the skull of each animal was removed and defleshed. When tissue collection for the entire study was complete, the humeri were arranged according to size, and radiographed in both the posterior-anterior and the medial-lateral positions. From these radiographs, the presence or absence of an epiphyseal line of cartilage at the proximal and distal ends was demonstrated. The skulls were used to compare dentition, whether deciduous or permanent, and the degree of deterioration and amount of deposits and discoloration found in permanent teeth.

#### REVIEW OF LITERATURE

Since the introduction of bone marrow biopsy and marrow puncture methods into human medicine, much has been published about different marrow techniques and determinations. A lot of work has been done with laboratory animals and is of comparative value for both human and veterinary medical considerations. It is surprising that so few studies have been made with the cat which serves well as a laboratory experimental species. In this review, some of the work from the vast literature of bone marrow

which is of particular interest in view of the procedures and objectives of the present study, was pointed out.

#### Obtaining Bone Marrow from Small Animals

Erf (1937) used a Steinman pin tapered to a long point for inserting through skin, muscle, and cortical bone of the tibia, humerus, and femur of rabbits in any place where the bone is close to the surface. After establishing patency into the marrow, a lumbar puncture needle was inserted for the aspiration of marrow. Meyer and Bloom (1943) cited the iliac crest approach of Ho et al. (1940) and stated that they felt the crest of the ilium was the preferable site for aspiration of marrow in dogs. Sawitsky and Meyer (1947) obtained marrow for study from 15 cats by rotating and pushing a spinal tap needle into the anterior superior border of the iliac crest; they later (1948) used this same site for obtaining marrow from guinea pigs. Vigran (1947) used a dental bur to drill an opening into the lateral surface of the distal part of the femur shaft in rats. McFadyean (1948) described the use of the dental drill to make an oblique opening in the cortex of the proximal third of the rat femur. He stated this was an easier approach than that of Vigran, but said the ilium was an even better site in most laboratory animals. Sundberg and Hodgson (1949) described the aspiration of marrow from laboratory animals from the proximal end of the tibia at the triangular area inferior to the medial condyle and medial to the tibial tuberosity. Another approach to the femoral marrow in

small animals is by way of the trochanteric fossa. Schryver (1960) used this approach to obtain the marrow for his differential studies of normal cat marrow.

#### Gross Marrow Appearance

While a lot has been written about the gross appearance of bone marrow, it is generally realized that cellularity is easily misjudged by simple gross appraisal. Custer and Ahlfeldt (1932) presented the classical picture of the disappearance of red marrow with advancing age from the long bones in man, yet Custer (1932) warned that gross examinations were often fallacious in that congestion or hemorrhage might be grossly indistinguishable from hyperplasia. Lawrence et al. (1940), in their work with cat bone marrow, have agreed with Custer that the gross appearance might well be of small value. Huggins and Blocksom (1936) suggested that the spreading of stained bone dust by sawing, and the hemolysis of erythrocytes and subsequent gravitation of blood pigment were major obstacles when judging intact marrow specimens.

#### Determination of Cellularity

Probably the simplest and most used method of microscopically evaluating marrow is the preparation and examination of direct smears and imprints. Many workers, including Peabody (1926), Custer (1932), Dameshek et al. (1934), Reich and Kolb (1942), Pettet et al. (1955), and Griffing (1960) warned against reaching inaccurate conclusions about total cellularity or cell-type

distribution because of injudicious appraisal of bone marrow smears and imprints. Because of the simplicity of their preparation and because excellent cell detail can be maintained, smears and imprints are still widely used. Stansey and Higgins (1937) maintained that imprints were satisfactory if the interpreter kept in mind that only the free cells of marrow were represented. Limarzi (1939) praised the clearness of cellular detail possible with imprints and he believed as good a morphology outline was possible as with a section.

Much of the work done on the investigation of smears and imprints has not included evaluation of total or relative cellularity other than a possible reference to the concentration of cells. Propp (1951) described six grades, from aplastic to markedly hyperplastic, in his evaluation of bone marrow smears. Grunsell (1955) graded spreads of sheep marrow, depending on the density of cells within the walls of the reticulum, around the syncytium, and along the edges of the spread. An even more elaborate total cell estimation procedure for smears was described by Sandkühler and Gross (1956). They used a special eyepiece complete with a net and square field limitation adjusted so that the cells in one one-thousandth of a square centimeter could be counted.

Total nucleated cell estimation has become almost routine since Gordon (1939) reported early results on total erythrocyte and total nucleated cell counts in human marrow. Samples are ordinarily taken by the puncture and aspiration method, though

for post mortem work more elaborate techniques might be used. In their work with adult dogs, Rekers and Coulter (1948) squeezed drops of marrow from bones and homogenized it on a drop plate before diluting it in a white blood cell pipette. Fruhman and Gordon (1955) described a necropsy technique of diluting a weighed mass of rat marrow and calculating total counts from this known dilution. Burke and Harris (1959) described a similar technique which could be adapted to live laboratory animals. With the dental drill, they made openings in the cortical bone of rat femurs through which marrow was removed by pressing a polyethylene tube into the medullary cavity. Gerarde (1956) described a method of forcing all the marrow from the femur of rats, mice, or hamsters so that cell suspension and biochemical studies could be accomplished.

Schleicher and Sharp (1937) did some of the early work on marrow centrifugation, and Limarzi (1939) and Schleicher (1944) followed up with descriptions of centrifugation with the Wintrobe hematocrit tube as an instrument used in determining components of the marrow. This technique was evaluated by Berman and Axelrod (1947) who found it suitable for very crude estimates of fat content, but not so accurate as the evaluation of sections. Berman and Axelrod (1947) likewise described centrifugation as being of some value in estimating the mean cellularity of a group of cases, but having too great a range of error to permit the data from an individual sample to be interpreted as an index of cellularity.

Tissue sections are widely valued for cellularity estimations because the architecture of the tissue is not disturbed, yet even with these, observer differences permit error. Kindred (1942) measured percentages of the total marrow, fat, and vessels in marrow sections by projecting them onto graph paper with camera lucida and determining the relative area occupied by each. From this he determined the percentage of active marrow. Another approach to systematic evaluation of sectioned marrow cellularity was that used by Berman and Axelrod (1950). They estimated the relative area occupied by fat, in sections, with the aid of a Whipple eyepiece micrometer, and from this judged the percentage of active marrow.

Sabin et al. (1936) found that if sections of rabbit marrow were prepared with great care, they were best for cell differential as well as total cellularity estimations. The inadequate distribution and trauma always found in smears led Epstein and Tompkins (1943) to a similar preference for sectioning of guinea pig marrow. Bloom (1945) found cell differentiation difficult with sections of trephined sternal marrow of dogs. In a summation of the requirements of a complete post mortem marrow study, Osgood and Seaman (1944) listed the advantages and limitations of bone marrow imprints, sections, and cell suspension smears. They did not find it possible to differentiate properly the cells seen in the sectioned marrow.

Donohue et al. (1958) approached total body marrow cellularity determinations in a new manner. The total uptake of

radioactive iron in normal rats, rabbits, and monkeys was determined directly by isolating the skeleton and measuring its radioactivity. This reading could then be compared with the uptake in a small aliquot of a known number of bone marrow cells to determine the approximate total cellularity.

#### Determination of Biological Age

According to Sisson and Grossman (1953), the distal epiphysis of the humerus is one of the first extremities to unite with the shaft in the horse, ox, pig, and dog. In these same animals the proximal humeral epiphysis is one of the latest long bone extremities to unite with its diaphysis. Dawson (1925) found that the first epiphyseal union to occur in the rat is at the distal end of the humerus and the last union is that between the proximal humeral extremity and its shaft. Dawson cited the work of Stevenson (1924) as showing the same order of union in man and most other mammals. Hudson (1960), doing bone marrow studies with cats of unknown ages, found that 3 of his 12 cats in the study had many un-united epiphyses, but in each case the distal epiphysis of the humerus was united with its shaft.

#### OBSERVATIONS

##### Condition of Experimental Animals

Most of the cats used in this study were either farm cats or city pound stray cats, and they varied considerably in age and condition. Many of the females were in some stage of pregnancy



or had been nursing kittens. These variables are summarized in Table 1 (Appendix).

#### Determining Ages of Experimental Animals

Teeth and epiphyseal line studies disclosed that most of the subjects were young adults. In two of the cats (Nos. 25 and 26), littermates whose ages were known to be three months, the distal humeral epiphyses were still separated from the diaphysis by cartilage. Number 33 was a three-week-old kitten, and his humerus was not included in the radiological studies. All the other humeri no longer showed an epiphyseal line of cartilage at the distal end. The proximal epiphyseal part of the humerus was clearly separated from the diaphyseal part in the above three animals (Nos. 25, 26, and 33) as well as 16 others (Nos. 1, 3, 4, 6, 7, 11, 12, 16, 17, 21, 22, 23, 27, 28, 31, and 35). In four of the cats (Nos. 2, 5, 15, and 30), the proximal epiphyseal line was still faintly evident on the radiograph. Histological sections would be required before any significance could be placed on this finding. The teeth did not appear to be from a younger group than four of those (Nos. 9, 24, 32, and 34) whose proximal epiphyseal lines were not at all visible with the radiological studies.

The other four cats (Nos. 8, 10, 14, and 29) whose proximal epiphyseal lines of cartilage were shown to be missing by radiograph, were placed into an aged group on the basis of the appearance and condition of their teeth. This included several to

many missing teeth, increased tartar deposits and dental caries, and a darker color, which conditions Gandal (1954) suggested to be of sufficient significance to differ older specimens from young adults. Since No. 21 still had about half of her deciduous teeth, she was placed into the youngest group with Nos. 25, 26, and 33 to complete the grouping as summarized in Table 1.

#### Gross Marrow Observations

Because of the great variations in the gross appearance of the marrow tissue, no attempts were made to tabulate the detailed findings. General groupings of the gross marrow observations are shown in Table 2 (Appendix). The marrow color of same-sexed and similarly conditioned cats within each age group was detailed in the following paragraphs. Differences in shades of red color observed were often attributable to the degree of anoxia which existed at the time circulation ceased. The texture was not mentioned. In general, the lighter colored or "fatty marrow" was firmer and often somewhat crumbly as compared to the generally more viscous red marrow. Since the marrow of the ilium appeared red in every cat in the study, this observation is not mentioned for each animal.

In the immature group, cats No. 25 and 26 (littermates, three months of age) had marrow of identical appearance. That marrow from the femur and humerus was reddish-gray. Marrow in the proximal end of the tibia appeared the same, but was progressively lighter in color toward the distal end. Cat No. 21 was

two months older and somewhat fatter, but the marrow appeared much like that from Nos. 25 and 26. The color of the distal half of the tibial marrow was more distinctly yellow in appearance. Cat No. 33 (three weeks old) had uniformly dull red marrow in all bones examined. Cats of this youngest group were the only ones for which ages were precisely known.

Numbers 1, 7, 11, 12, and 17 in the young mature age group were thin, non-pregnant females. Numbers 1 and 7 had dark red marrow in the femur, humerus, and proximal end of the tibia. The marrow in the distal half of the tibia was pale gray except for some slight reddishness around the edge in No. 1. Animals No. 11 and 12 had medium bright red marrow throughout the medullary cavities of the femur and humerus, and in the proximal end of the tibia. The marrow in the distal two-thirds of the tibia from cat No. 11 was light pink and in cat No. 12 the marrow of this same area was marbled reddish-gray and white. Cat No. 17 had dark red marrow throughout the four bones and many trabeculae in most of the marrow cavities.

Continuing with animals of the young mature group, the thin pregnant females No. 3 and 6 had red marrow in the humeri. Cat No. 3 had red marrow in the femur except for some small scattered areas of gray to white marrow. The proximally located marrow tissue in the tibia was red but appeared lighter colored distally and was yellow at the distal end. Marrow from cat No. 6 was light red in the proximal halves of the femur and tibia, and nearly white in the distal halves of the same bones. Cat No. 27

(pregnant and in fair condition) had dark reddish-gray marrow in all four bones except for yellow marrow in the distal third of the tibia and pale red marrow in the middle third of the same bone. Cats No. 16 and 35 were both females in good condition. Cat No. 16 had red marrow in the humerus and proximal parts of the tibia and femur. The marrow in its tibia appeared yellow in the distal third and pale red in the center third. Marrow in the femur also was red in the distal tip of the medullary cavity, but was pale gray in the center portion. Number 35 had red, gray, and white marbled appearing marrow in its humerus and femur and in the proximal portion of the tibia. Marrow in the rest of the tibia was pale reddish-gray to white.

The only thin male cat in the young mature group was No. 4. This cat had dark red marrow in all four bones. Male cats No. 23 and 28 (fair condition) had mottled reddish-gray marrow in their humeri and femora, and in the proximal two-thirds of their tibiae. Yellow marrow filled the distal one-third of the tibia. Cats No. 22 and 31 were males in good condition. Number 22 had mottled appearing reddish-gray marrow in all four bones except for the yellow marrow found in the distal half of the tibia. The humerus of cat No. 31 contained red with patchy areas of lighter colored marrow. In the femur, the marrow was red on each end and somewhat yellow or fatty-appearing in the center. The tibia was the same as in cat No. 22.

In the mature group of cats, No. 2 (thin pregnant female), and Nos. 5 and 34 (thin nursing females) each had red marrow in

their respective humeri and femora except for a small amount of pale gray marrow in the distal end of the femora of cats Nos. 2 and 5. Number 5 had red marrow throughout its tibia while Nos. 2 and 34 showed an area of white marrow in the distal ends of their tibiae. Cat No. 9 (female in fair condition) had red marrow in the humerus and femur, and in the proximal portion of the tibia. The marrow in the distal part of the tibia was yellow. The four male cats in this group (Nos. 15, 24, 30, and 32) were in fair to good condition. The marrow of the humeri and femora and the proximal parts of the tibiae of Nos. 15, 24, and 30 was dark red except for some patchy areas of pale colored marrow in the center of the femur of No. 15. The distal end of the tibia of No. 15 was yellow marrow with peripherally arranged red marrow. The distal end of the tibiae of Nos. 24, 30, and 32 contained yellow marrow. The marrow of the humerus, femur, and proximal end of the tibia in cat No. 32 was marbled red and yellow.

Two male cats of the aged group were in good condition and the marrow in their humeri, femora, and proximal two-thirds of their tibiae was red. In each case, the transition to yellow marrow in the distal one-third of the tibia was abrupt. Cat No. 10 was very large, but somewhat thinner than either No. 8 or No. 14. His marrow was dark red throughout the four bones that were examined. The final cat of this group, No. 29, was a thin nursing female. The marrow of this cat was red in all bones except for a small tip of yellow marrow in the distal end of the tibia.

### Processing of Tissues

In the cases where the selected humeral and femoral marrow could be removed as one piece, the tissue ordinarily remained intact through all of the processing. The most care was required when the tissue was being washed after fixation and decalcification since it was still quite soft at this stage. When it was necessary to apply the marrow to paper at the time of removal from the bones, two or three minutes were allowed for moisture from the marrow to penetrate the paper before it was placed in the fixative. If this precaution was taken, the marrow adhered nicely to the paper through the rest of the processing. When the paraffin blocks were cast, the tissue was put into the paraffin with the paper still attached. This caused no difficulty when the tissues were cut in the microtome because the paper could easily be sliced away before a usable part of the marrow tissue was reached by the cutting blade.

No attempt was made to remove cortical bone from the tissue specimens of tibia and ilium prior to decalcification. Though decalcification time would have been reduced, the possible damage caused by pressure close to the soft trabecular bone and marrow was avoided. After the tissues had been dehydrated through 95 percent alcohol, much of the cortical bone was trimmed away to increase the ease of sectioning. At this time the trabecular bone was firm and not easily damaged.

### Appearance and Evaluation of the Marrow Sections

Preliminary work showed that simple paraffin embedding was not satisfactory since the sections were compressed to a variable degree by the cutting technique. Prior embedding with the Parlodion caused the formation of a matrix which held fat spaces "open" and the sections were quite satisfactory. The presence of the Parlodion likewise decreased shrinkage ordinarily caused by the oven paraffin embedding.

In rating the marrow, both visually and with the photometer, some conditions were discovered which probably increased the error. Some of the marrow had quite a "marbled" effect. That is, strips of highly cellular marrow were sometimes present in part of an otherwise moderately cellular section. Many sections which showed moderate to high cellularity for the most part had some small areas of great fattiness. This was especially common when the sectioned tissue had some large vessels present in it. It was also common to find highly cellular areas along the edges of sections which were otherwise mostly fat.

In a few cases, a small amount of the Parlodion was not removed from the section by the acetone and xylene treatments, and the fuzzy outline of this became stained. It was usually easy to avoid such areas of the section when the photometer readings were taken. Some of the ilium and tibia sections showed areas where bone dust, formed as a result of the sawing process, had forced marrow from its intertrabecular spaces. It was not difficult to avoid such areas when the marrow was being evaluated for

cellularity. Only those spaces with the marrow and fat intact were considered.

Some "free marrow" was usually present at the end of the tibial sections furthest from the proximal epiphysis. It was observed that this marrow sometimes differed in cellularity from that found in the intertrabecular spaces, but not in a consistent manner. That is, occasionally it was more cellular, but in other cases, less cellular than the intertrabecular marrow. In both the tibial and iliac sections, variations within single sections seemed even greater than in the free marrow tissue sections of the humerus and femur. Some intertrabecular spaces were filled with highly cellular marrow, and others in the same section had one-half to two-thirds of their area filled with fat cells. In these cases, the dominant pattern of cellularity was recorded.

Table 3 (Appendix) shows the averages of five low power and 10 high power photometer readings (except where numbers in parentheses indicated exceptions) of the humeral and femoral marrow. Visual cellularity ratings in five categories from a low rating of one to the high rating of five also were indicated for all four examined areas of each cat. Microphotographs of a typical area within each classification of cellularity, and a short explanation of the criteria for classification, are included as Plates I through V (Appendix).

No significance could be placed on the color of the marrow in judging its cellularity. All marrow selected for microscopic examination appeared some shade of red or reddish-gray. Yet



microscopically, all degrees of cellular concentration were observed in the marrow from the 31 cats. In Table 2 (Appendix), the rough average of the visual cellularity ratings was added in parentheses after each cat. From a study of this table, it was concluded that not even a fatty appearance to some or several parts of the marrow was helpful in predicting the microscopically determined cellular concentration.

#### DISCUSSION

The need existed for marrow cellularity studies and determinations throughout the bones of normal cats. Limited time, funds, and facilities forced the use of animals which had been collected from the streets and about which nothing was known. With this in mind, the findings from such animals might be of as much interest as data secured from "normal" animals closeted in the laboratory environment. Since a complete bone marrow survey was beyond the scope of this work, the logical places to make limited observations were those areas most commonly used to obtain bone marrow for cellular differentiation. In man and larger animals, the sternum, spinous processes, ribs, and ilium are most often invaded to obtain marrow. In the smaller animals, size limitations precluded use of the sternum, ribs, and spinous processes as ordinary sources of bone marrow. Nearly without exception, marrow was taken from either the ilium or the proximal end of the femur, humerus, or tibia in the smaller animals.

These areas were selected for this study as the beginning step for greater understanding of the bone marrow cell distribution in the cat.

#### Fatty Changes in Marrow with Ageing

The concept of the occurrence of fatty morphogenesis in a consistent pattern in the marrow of long bones of the normal adult human, as was described by Custer and Ahlfeldt (1932), probably is not so pronounced in the cat. Hudson (1960) found fatty appearing marrow only in the pes, manus, and usually in the lower part of the tibia, radius, and ulna of well nourished adult cats. Goodman (1952) found no yellow appearing marrow in the femur of 13 normal cats ranging in age from one to 45 months. Perhaps the same was true with the rabbit. Nye (1931) reported that gross examination of the long bones of rabbits revealed relatively much more red marrow than in the same bones of man. Huggins and Blocksom (1936) found that in adult rabbits, the marrow of the pelvis, femur, and proximal two-thirds of the tibia was always red.

The dog seemed to develop a change from red to fatty marrow in its long bones more like the change observed in man, according to the work of Oehlbeck et al. (1932) and Huggins and Blocksom (1936). Oehlbeck et al. (1932) and Fairman and Whipple (1933) found that in normal adult dogs, the extent of red marrow was often quite variable.

Goodman (1952) chemically determined the percentage of lipids in proximal and distal femoral marrow in cats up to four years of age. He did not find a relative increase of fat in the distal femoral marrow as compared to the proximal marrow in the older cats. The overall increase of percent lipids in the dry marrow increased only very slightly in the oldest cats (42 and 45 months) as compared to the youngest. In view of the poor condition of many of the animals used in the author's study, it was interesting to note that Goodman observed a significantly lower percentage of fat in the femoral marrow of one heavily parasitized cat and two cats which were caged outdoors as compared to the ten cats kept indoors. Goodman attributed this difference to the stresses placed on the three cats.

#### Comparison of Cellularity

Discovering a pattern to the cellularity of the bone marrow by age group was impossible in this selection of cats. An attempt was first made to compare the youngest group (Nos. 21, 25, 26, and 33) with the aged group (Nos. 8, 10, 14, and 29). Surprisingly the average cellularity, as determined both photometrically and visually, was almost identical. If, as reported for man by Cheli and Giordano (1947), the marrow of the aged more frequently becomes hyperfunctional than fatty, this comparison is not so startling. Comparing the young group to the mature also did not reveal any trend. Two of the immature cats (Nos. 21 and 33) appeared to have higher cellularity than all of the mature cats except No. 30. The other two immature cats had

marrow which was nearly the same as the remainder of the mature cats.

An attempt was made to compare cats of similar conditions within a single age group. The similarity was not more consistent than between animals of different conditions in different age groups. For example, the five thin females in the young mature group included two of the fattiest marrows (Nos. 1 and 11) and one of the most cellular marrows (No. 17) in the entire study. The other two (Nos. 7 and 12) had marrow which was more average in cellularity.

An attempt to demonstrate the lack of consistent trends in the marrow from the cats of this study included an effort to explain it. Perhaps such variation could be expected among cats which were not housed, fed, and cared for in an identical manner. In addition to the lack of similar care, the stresses on each might have been quite different. Some of the cats were parasitized. Other specimens probably were in or just past the recovery stages of an acute infection. A few might have had an insidious chronic infection. Some had shelter and others did not. A small number were in late pregnancy, early pregnancy, or not pregnant. In short, no two were alike and so inconsistent trends in marrow cellularity were not unexpected. Cats No. 25 and 26 were littermates which presumably were raised in similar conditions. Even so, No. 26 was judged to have higher cellularity in each of the four bones. The observation Fairman and Whipple (1933) made in dogs, that the ratio of red to fat marrow

is a variable which is under constant adjustment depending on the need for red blood cells and many other factors, could as well be made for the cat. The findings of Goodman (1953) in the cat indicated that of these factors, age is the least important in determining bone marrow cellularity. Except for his three cats which had obvious stresses, the cats from age one month to age 45 months showed little variation in fat percentages.

Within each individual cat of this study, a definite similarity was observed in the bone marrow from the four areas. In most cases the photometric readings of the humeral marrow sections agreed closely with those of the femoral marrow, and the visual ratings of all four bones were always surprisingly close together. It might be concluded that any of these four areas was equally good for obtaining marrow. Preferences expressed by workers who have taken marrow from large numbers probably were partially based on greater familiarity with just one of the areas (methods). The author believes that though the marrow in the intertrabecular spaces of the tibia and ilium was representative of that found in any of the four areas, it might be more difficult to obtain representative samples since the reticulum and its enmeshed cells has more anchoring endosteal surface. On the other hand, in marrow of low cellularity where cells are confined to the endosteal surface, and the center marrow is largely fat, perhaps the most cellular marrow samples would be obtained where there is a higher ratio of endosteum to marrow space.

A comparison of the visual and the photometric methods of cellularity determination showed reasonable agreement on the humeral and femoral marrow. Not enough readings were made in the one and five categories to warrant comparison. The range from the lowest to the highest photometer readings given any tissue which fell within the visually rated categories of two, three, and four (Plates II, III, and IV) and the averages of all readings in the same categories are shown in Table IV (Appendix).

Where work is undertaken by one observer, and is not reported, the visual determination might be sufficient. The readings taken on the photometer would be the same for anyone who used identical methods, and this was their contribution. In addition, the visual method described in this paper evaluated, for the most part, only the size and spacing of the fat cells and gave little significance to the spacing of the stained nuclei to each other.

Abercrombie (1946) criticized the extrapolation from the mean number of nuclei within a certain volume of a microscopic section to the probable mean number in a given mass of the tissue, such as a cubic millimeter. He pointed out that some of the nuclei are only parts and some are whole. With photometry, used to compare relative cellularity, this error should not be a factor, since the stained chromatin of partial nuclei would not have as great a light wave absorbing capacity as would the whole nuclei. The size of the nuclei, and the ratio of blast to mature nuclei probably did have an effect on the readings though this

was offset to some extent by the lower density of stained chromatin in the larger blast form cells. In complete bone marrow studies, the cellularity of sections perhaps should not be compared unless the ratio of blast form to mature form cells, as determined by a count from each section, was reasonably similar.

#### Methods

In preliminary work, both Zenker's solution and the Kaformacet formula used by Kristensen (1949) were used as fixative agents. Since cellular detail achieved with hematoxylin and eosin staining was excellent in tissues fixed with either agent, Kaformacet was chosen for this work because the tissues were easier to process after fixation. It was necessary to use absolutely fresh fixative to avoid slight staining of erythrocytes by the nuclear stain.

The stain employed had to be one which would impart a sharp color to the nucleus without staining the cytoplasm or osteoid. Hematoxylin, gallocyanin, magenta, and Feulgen technique stains were evaluated, and gallocyanin was the most satisfactory. If fresh fixative was used, the erythrocytes, osteoid, and the cytoplasm of all other cells was minimally stained. This permitted the preparation of slides for light absorption determination based essentially on the number of nuclei present for a given field. These photometer readings were interpreted only as an index of the relative cellularity and were considered significant only as a comparative value.

Some of the authors who had pointed up the necessity of approximating cellularity by the use of sections were mentioned in the literature review. Because of their reports, the involved task of preparing doubly-embedded tissue sections of the areas of bone marrow under consideration was accomplished. The addition of a photometric technique increased the ease and objectivity of evaluating those sections, providing the sections of marrow were large enough to fill a microscope field.

Photographic negatives were made of up to three millimeter by four millimeter portions of bone marrow sections from all four bone marrow sources. Any area of the negative which did not represent marrow tissue was masked by black paper. Light transmission detected passing through the negative picture of the marrow by a photometer then served as a measure of relative cellularity. These preliminary studies of further photometric techniques of cellularity determination were promising, but control films indicated that variables still exist in the development process. The greatest advantage of determining light transmission through the photographic negatives was that the relative cellularity of a large section of tissue could be determined by one reading.

#### Age Determination

Virtually nothing has been published about determination of the age of the cat. Gandal (1954) stated that if enough work were done examining eruption dates, wearing features, and



coloration of the teeth of a species of mammals, no doubt reasonably accurate criteria for age determination could be discerned. For the present work, the epiphyseal closures and appearance of teeth suffice for grouping the animals by ages. It was assumed that the cat's epiphyseal closure sequence approximates that of the ox, horse, pig, dog, and rat, and the humerus was studied to determine if the distal and proximal epiphyseal lines of cartilage were present or absent. Though it was expected that the majority of animals would be young adults, the fact that easily the largest group was that with the distal epiphyseal line no longer visible and the proximal line still determinable on the radiographs indicates that the time between the two epiphyseal closures in this bone of the cat is considerable.

#### SUMMARY

A study was undertaken to determine information about cell concentration of bone marrow within clinically accessible bones of various ages of cats. Marrow from the four areas which served as sources of aspirated bone marrow from small and laboratory animals was described grossly and was microscopically evaluated for cell concentration or cellularity.

Specimens of bone marrow were procured from the wing of the ilium and the proximal ends of the tibia, femur, and humerus of 31 mongrel cats of various ages and conditions. The specimens were double-embedded, sectioned, and stained with gallocyanin. These sections were then visually rated, for cellularity, in one

of five groups which categorized all degrees of visible fat deposition from no visible fat, to all fat except for small lines and scattered groups of cells. The extremes, either no fat, or nearly all fat, were uncommon, but the other three categories were found in cats irregardless of age or condition. The marrow taken from any one cat was very similar in each of the four areas.

In addition to visual evaluation, the tissue sections of marrow taken from the humerus and femur of each cat were rated, according to the relative amount of light absorbed by the stained nuclei, as determined by a photometer attached to a microscope. With this arrangement, greater light absorption indicated greater cellularity. The comparative cellularity of the sections as determined by relative amount of light absorption was similar to that observed visually. Advantages of the photometric method of cellularity determination included its objectivity and the greater ease of comparing data obtained with that obtained at other times and places.

After marrow tissue specimens were saved from the four bones, the color of the remaining marrow was noted and recorded. No correlation was found between the color of the gross marrow and the cellularity as determined microscopically.

The cats were divided into four rough age groups on the basis of the epiphyseal lines of the humerus and the condition of the teeth.

## ACKNOWLEDGMENTS

The author acknowledges with gratitude the helpful assistance, guidance, and encouragement extended freely to him by Dr. D. M. Trotter, major professor, and Head of the Department of Anatomy, Kansas State University, and Dr. J. H. Venable of the Oklahoma State University Department of Veterinary Anatomy.

Appreciation is also expressed to Dr. Newton B. Tennille, Oklahoma State University, for his aid in preparing the excellent radiographs used in this study.

Additional appreciation for assistance or advice is due Dr. E. H. Coles, Dr. W. E. Brock, Dr. D. R. Peterson, and Dr. C. B. Vanzant.

The assistance of Mrs. Betty Clapp in cutting and mounting the tissue sections is gratefully acknowledged.

Thanks are expressed to Mr. J. R. Yorke for the preparation of photographs.

## LITERATURE CITED

- Abercrombie, M.  
Estimation of nuclear population from microtome sections.  
Anat. Rec. 94:239-247, 1946.
- Berman, L., and A. R. Axelrod.  
Evaluation of volumetric data obtained by centrifugation of aspirated sternal marrow of adults. Am. J. Clin. Path. 17: 551-560, 1947.
- 
- Fat, total cells, and megakaryocyte content of sections of aspirated marrow of normal persons. Am. J. Clin. Path. 20: 686-687, 1950.
- Bloom, Frank.  
Bone marrow biopsies in normal and diseased dogs - differential cell counts. J.A.V.M.A. 107:220-225, 1945.
- Burke, William T., and Charles Harris.  
Total cell counts of the bone marrow of normal albino rats from 1 to 50 weeks of age. Blood 14:409-414, 1959.
- Cheli, E., and A. Giordano.  
Contributo allo studio del midollo osseo e del sangue periferico nella senilita. Archivio 'E. Maragliano' di Patologia e Clinica 2:18-35, 1947. Abstracted in Excerpta Medica 2:662-663, 1949.
- Custer, R. P.  
Studies on the structure and function of bone marrow I.  
J. Lab. Clin. Med. 17:951-960, 1932.
- Custer, R. P., and Florence Ahlfeldt.  
Studies on the structure and function of bone marrow II.  
J. Lab. Clin. Med. 17:960-962, 1932.
- Dameshek, William, Henry H. Henstell, and Eleanor H. Valentine.  
The comparative value and the limitations of the trephine and puncture methods for biopsy of the sternal bone marrow.  
Annals of Int. Med. 11:801-818, 1937.
- Dawson, Alden B.  
The age order of epiphyseal union in the long bones of the albino rat. Anat. Rec. 31:1-17, 1925.
- Donohue, D. M., B. W. Gabrio, and C. A. Finch.  
Quantitative measurement of hemopoietic cells of the marrow.  
J. Clin. Invest. 37:1564-1570, 1958.

- Erf, L. A.  
A simple, practical, and sterile technique for obtaining bone marrow from animals by puncture. *J. Lab. and Clin. Med.* 22:1080-1082, 1937.
- Epstein, Robert D., and Edna H. Tompkins.  
A comparison of techniques for the differential counting of bone marrow cells (guinea pig). *Am. J. Med. Sci.* 206:249-260, 1943.
- Fairman, E., and G. H. Whipple.  
Bone marrow volume in adult dogs. *Am. J. of Physiology* 104: 352-357, 1933.
- Fruhman, George J., and Albert S. Gordon.  
A quantitative study of adrenal influence upon the cellular element of the bone marrow. *Endocrinology* 57:711-718, 1955.
- Gandal, C. P.  
Age determination in mammals. *N. Y. Acad. Sci. Trans.* 16: 312-314, 1954.
- Gerarde, H. W.  
A method for the quantitative collection of femoral marrow in small laboratory animals. *A.M.A. Archives of Industrial Health* 13:331-335, 1956.
- Goodman, D. C.  
Quantitative studies on the distribution of lipids in the bone marrow of the rat, pig and cat. *Kans. Acad. Sci. Trans.* 55:214-222, 1952.
- Gordon, Abraham S.  
Studies in bone marrow. *J. Lab. and Clin. Med.* 24:352-359, 1939.
- Griffing, William.  
The significance of bone marrow examination in certain diseases of the bovine and canine. Unpublished M. S. thesis, Kansas State University, Manhattan, Kansas, 1960.
- Grunsell, C. S.  
The marrow cells of normal sheep. *J. of Comp. Path. and Therapeutics* 65:8-17, 1955.
- Ho, E. A., H. J. Chu, and I. C. Yuan.  
A simple method for obtaining bone marrow from the dog. *Chinese Medical Journal* 58:679-681, 1940. Cited by L. Meyer and F. Bloom (1943).

- Hudson, G.  
Bone marrow volume in cats. *Jour. of Anatomy* 94:274-278, 1960.
- Huggins, C., and B. H. Blocksom, Jr.  
Changes in outlying bone marrow accompanying a local increase of temperature within physiological limits. *Jour. Exp. Med.* 64:253-274, 1936.
- Kindred, James E.  
A quantitative study of the hemopoietic organs of young adult albino rats. *Am. Jour. of Anatomy* 71:207-243, 1942.
- Kristensen, H. K.  
Staining of human bone marrow after decalcification. *Acta Path et Microbio.* 26:715-718, 1949.
- Lawrence, J. S., and others.  
Infectious feline agranulocytosis, leucopenia, and pronounced neutropenia. *Am. J. Path.* 16:333-354, 1940.
- Limarzi, L. R.  
The diagnostic value of sternal marrow aspirations. *Ill. Med. Journal* 75:38-46, 1939.
- McFadyean, A. J. S.  
Marrow biopsy in laboratory animals. *Journal of Path. and Bact.* 60:332-333, 1948.
- Meyer, L., and F. Bloom.  
The bone marrow of normal dogs. *Am. J. Med. Sci.* 206:637-641, 1943.
- Nye, R. N.  
Bone marrow volume in rabbits. *Soc. Exp. Biol. and Med. Proc.* 29:34-37, 1931.
- Oehlbeck, L. W. F., F. S. Robscheit-Robbins, and G. H. Whipple.  
Marrow hyperplasia and hemoglobin reserve in experimental anemia due to bleeding. *Jour. of Exp. Med.* 56:425-448, 1932.
- Osgood, Edwin E., and Arthur J. Seaman.  
The cellular composition of normal bone marrow as obtained by sternal puncture. *Physiological Reviews* 24:46-69, 1944.
- Peabody, F. W.  
The pathology of the bone marrow in pernicious anemia. *Am. J. Path.* 3:179-202, 1927.
- Pettet, J. D., G. L. Pease, and Talbert Cooper.  
Evaluation of paraffin sections of aspirated bone marrow in malignant lymphomas. *Blood* 10:820-830, 1955.

- Propp, S.  
An improved technique of bone marrow aspiration. *Blood* 6:  
585-599, 1951.
- Reich, C., and E. M. Kolb.  
A quantitative study of the variations in multiple sternal  
marrow samples taken simultaneously. *Am. J. Med. Sci.* 204:  
496-504, 1942.
- Rekers, P. E., and M. Coulter.  
A hematological and histological study of the bone marrow  
and peripheral blood of the adult dog. *Am. J. Med. Sci.*  
216:643-655, 1948.
- Sabin, F. R., and others.  
Changes in the bone marrow and blood cells of developing  
rabbits. *Jour. of Exp. Med.* 64:97-120, 1936.
- Sandkuhler, S., and E. Gross.  
Normal bone marrow total cell and differential values by  
quantitative analysis of particle smears. *Blood* 11:856-862,  
1956.
- Sawitsky, Arthur, and Leo M. Meyer.  
The bone marrow of normal cats. *J. of Lab. and Clin. Med.*  
32:70-75, 1947.
- 
- Bone marrow of normal guinea pigs. *Blood* 3:1050-1054, 1948.
- Schleicher, E. M.  
Staining aspirated human bone marrow with domestic wright  
stain. *Stain Tech.* 17:161-164, 1944.
- Schleicher, E. M., and E. A. Sharp.  
Rapid methods of preparing and staining bone marrow. *J. of  
Lab. and Clin. Med.* 22:949-951.
- Schryver, Herbert F.  
The bone marrow of the normal cat. Unpublished M. S. thesis,  
University of Pennsylvania, Philadelphia, 1960.
- Sisson, S., and J. D. Grossman.  
The anatomy of the domestic animals. Saunders: Philadelphia,  
1953.
- Stansey, J., and G. M. Higgins.  
A quantitative cytologic study of the bone marrow of the adult  
dog. *Am. Jour. Med. Sci.* 193:462-470, 1937.

Stevenson, P. H.

Age order of epiphyseal union in man. Am. Jour. Physical Anthropology 7:53, 1924. Cited by Dawson (1925).

Sundberg, R. D., and R. E. Hodgson.

Aspiration of bone marrow in laboratory animals. Blood 4: 557-561, 1949.

Vigran, I. M.

A method of bone marrow biopsy from the rat. Jour. Lab. and Clin. Med. 32:102-103, 1947.



**APPENDIX**

Table 1. Age grouping and vital statistics.

Immature <sup>1</sup>		Young mature <sup>2</sup>		Mature <sup>3</sup>		Aged <sup>4</sup>													
No.:	Sex:Con.:	Ht.:	WBC <sup>5</sup> :	No.:	Sex:Con.:	Ht.:	WBC :	No.:	Sex:Con.:	Ht.:	WBC								
21	F	G	35	10.1	1	F	T	39	8.3	2	F	PGT	33	9.6	8	M	G	35	8.8
25	M	G	28	6.9	3	F	PGT	28	5.4	5	F	TNu	32	13.0	10	M	S	29	15.8
26	M	G	29	8.8	4	M	T	28	11.8	9	F	S	29	8.4	14	M	G	34	20.0
33	M	S	20	5.3	6	F	TPG	32	5.4	15	M	G	33	9.0	29	F	TNu	31	21.2
					7	F	T	34	9.2	24	M	S	30	23.7					
					11	F	T	27	6.2	30	M	S	32	12.2					
					12	F	T	30	6.2	32	M	S	27	6.2					
					16	F	G	29	10.7	34	F	TNu	25	6.4					
					17	F	T	24	6.8										
					22	M	G	36	18.6										
					23	M	S	29	17.5										
					27	F	SPG	29	14.5										
					28	M	S	31	16.2										
					31	M	G	34	10.9										
					35	F	G	24	8.5										

1 Classified immature based on persistent epiphyseal line in the distal part of the humerus and (in case of No. 21) on presence of deciduous dentition.

2 Young mature classification based on permanent dentition; distal epiphyseal line not visible on radiograph; proximal epiphyseal line visible on radiograph.

3 Classified mature because of permanent dentition and the proximal and distal epiphyseal lines of cartilage are no longer visible on the radiographs.

4 Aged classification - same as the mature except condition of the teeth suggests a more advanced age.

5 Number assigned the cat for the study.

6 Condition of the cat: T is thin, S is fair, G is good. PG means pregnant, and Nu indicates the cat had been nursing kittens.

7 Microhematocrit determination.

8 Leucocyte count expressed as thousands per cubic millimeter.

Table 2. Gross appearance of the marrow in summary.

I <sup>1</sup>	:	II <sup>2</sup>	:	III <sup>3</sup>	:	IV <sup>4</sup>	:	V <sup>5</sup>
33(4-5) <sup>6</sup>		25( 2 )		2( 3 )		3( 2 )		35(3)
17(3-4)		1( 1 )		8(2-3)		6( 1 )		32(2)
4( 4 )		7(2-3)		9( 2 )		31(2-3)		
5(2-3)		11( 2 )		12( 2 )				
10( 4 )				14( 3 )				
				15(2-3)				
				16( 3 )				
				21( 3 )				
				22( 4 )				
				23( 3 )				
				24( 2 )				
				27( 3 )				
				28( 2 )				
				29(1-2)				
				30( 4 )				
				34( 2 )				

- <sup>1</sup> Group I includes those cats which had red marrow throughout all four bones.
- <sup>2</sup> Group II includes those cats which had red marrow in the ilium, femur, and humerus, and red plus light red to gray marrow in the tibia.
- <sup>3</sup> Group III includes those cats which had red marrow in the ilium, femur, and humerus, and red plus white or yellow in the tibia.
- <sup>4</sup> Group IV includes those cats which had all red marrow in the ilium and humerus, and red plus yellow or white marrow in the femur and tibia.
- <sup>5</sup> Group V includes those cats with red marrow in the ilium, and red plus yellow or white marrow in the femur, humerus, and tibia.
- <sup>6</sup> The numbers in parentheses indicate the average visual rating of the marrow sections made from all bones, as indicated in Table 3.

Table 3. A complete listing of the average photometer readings with both low and high power for the humerus and femur slides as well as the visual cellularity ratings for marrow from each of the four areas of each cat.

		: Photometer readings:		Photometer readings:		Visual cellularity	
Cat :		of humerus slides :		of femur slides :		ratings <sup>3</sup>	
No. :	L. power <sup>1</sup> :	H. power <sup>2</sup> :	L. power <sup>1</sup> :	H. power <sup>2</sup> :	Hum <sup>5</sup> :	Fem :	Ili :Tib
1	95	95	95	96	1	1	1
2	72	68	74	73	3	2	4
3	78	81	81	80	2	2	3
4	67	68	69	70	4	4	4
5	82	81	83	82	2	3	3
6	-- <sup>4</sup>	--	95	92	1	1	1
7	79	75	69	68	2	3	3
8	79	78	66(3)	71	2	3	3
9	75(2)	72	84(2)	81	2	2	2
10	63(3)	62	72	72	4	4	4
11	89(3)	89	92	90	2	2	2
12	--	89	--	74	2	2	2
14	68	69	64	67	3	3	3
15	89	85	80(4)	78	2	3	3
16	74	73	77	72	3	3	2
17	55	52	53	55	4	4	3
21	63	60	65	61	3	3	4
22	68	67	68	67	4	4	4
23	76(4)	75	74	73	3	3	3
24	85	84	80	80	2	2	2
25	82	81	80	80	2	2	2
26	78	78	71	71	3	3	3
27	63	62	69	68	3	3	3
28	82	82	77	75	2	3	2
29	84	83	75	74	2	2	1
30	65	67	69	67	4	4	4
31	83	83	77	75	2	3	3
32	83	83	81	80	2	2	2
33	--	61	--	59	5	5	4
34	--	--	82	77	2	3	2
35	--	78	77(3)	76	3	4	3

<sup>1</sup> Average of five readings except where it is parenthetically indicated that fewer readings were taken.

<sup>2</sup> Average of ten readings.

<sup>3</sup> Cellularity as rated by eye through the microscope at 100 X and as explained in Plates I through V.

<sup>4</sup> Blanks indicate no readings were possible because of artifact spaces or fragmentation of the tissue section.

<sup>5</sup> Hum designates humerus; Fem designates femur; Ili designates ilium; Tib designates tibia.

Table 4. Comparison of visually rated cellularity categories two, three, and four with the range and average of photometer readings of the same humeral and femoral marrow. Figures were taken from Table 3.

Bone marrow source	Visual category	Number of tissue sections (cats)	Low power readings : Extremes : Averages	High power readings : Extremes : Averages
Humerus	2	14 <sup>1</sup>	75 to 85	72 to 89
Femur	2	9 <sup>2</sup>	74 to 92	73 to 90
Humerus	3	8 <sup>3</sup>	63 to 78	60 to 78
Femur	3	13	64 to 83	61 to 82
Humerus	4	5	55 to 68	52 to 68
Femur	4	6 <sup>4</sup>	53 to 77	55 to 76

<sup>1</sup> Only 13 readings were taken on low power.

<sup>2</sup> Only 8 readings were made on low power.

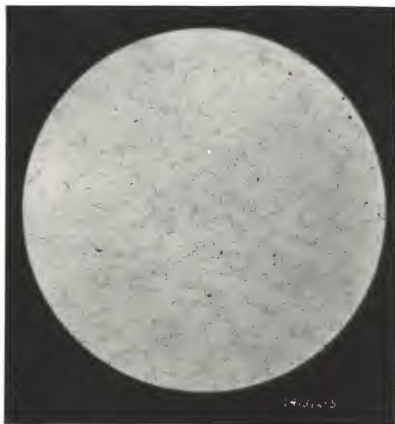<sup>3</sup> Only 7 readings were made on low power.

<sup>4</sup> Only 5 readings were made on low power.

EXPLANATION OF PLATE I

An area of low cellularity is illustrated. Marrow with this degree of cellularity was given a one rating. Tissue on the slide was mostly fat, with only lines and wedges of cells between the fat spaces.

## PLATE I

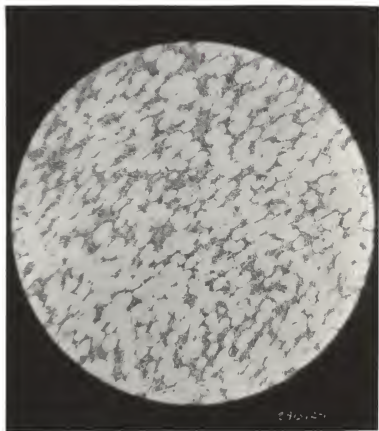


#### EXPLANATION OF PLATE II

An area of medium low cellularity is illustrated. Marrow with this degree of cell concentration was given a two rating. This tissue is more than half fat, but there are definite areas of fair cell concentration.



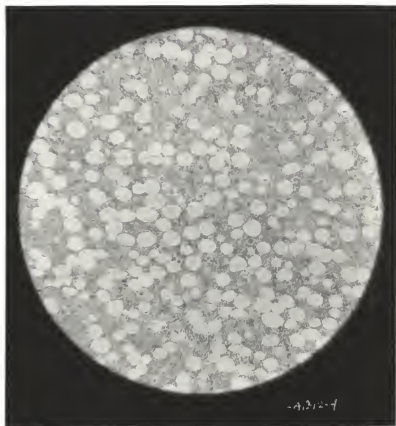
## PLATE II



#### EXPLANATION OF PLATE III

An area of medium high cellularity is illustrated. The fat spaces are only moderate in size and the fat no longer constitutes the major tissue of this section. Marrow with this degree of cellularity is rated as three.

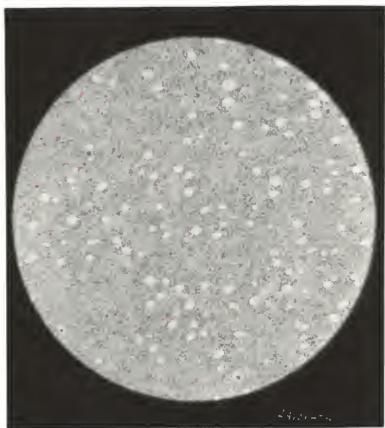
## PLATE III



#### EXPLANATION OF PLATE IV

An area of high cellularity is illustrated. This tissue would receive a four rating on the arbitrary cellularity scale used in this paper. This tissue differs from that receiving the highest cellularity rating only because of the presence of some fat spaces.

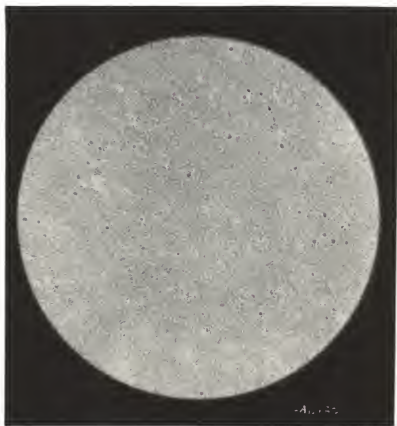
## PLATE IV



EXPLANATION OF PLATE V

An area of high cellularity is illustrated.  
This tissue would receive a five rating.  
No fat spaces are visible.

## PLATE V



A GROSS AND MICROSCOPIC STUDY OF THE BONE MARROW  
OF CLINICALLY ACCESSIBLE BONES OF THE  
IMMATURE, THE MATURE, AND THE AGED CAT

by

MARTIN RAYMOND FREY

B. S., Kansas State University, 1956  
D. V. M., Kansas State University, 1956

---

AN ABSTRACT OF A MASTER'S THESIS

submitted in partial fulfillment of the

requirements for the degree

MASTER OF SCIENCE

Department of Anatomy

KANSAS STATE UNIVERSITY  
Manhattan, Kansas

1961



Marrow studies of all animals have been most concerned with individual cellular detail and differentiation. This study was carried out on 31 mongrel cats of various ages in an attempt to add to the available basic knowledge of cellular distribution and concentration within four areas from which marrow is commonly aspirated.

No cats were used which had little or no appetite, which did not appear clinically healthy, which had an abnormal temperature, or which had a white blood cell count below 5,000 per cubic millimeter or a microhematocrit determination of less than 24. All other cats which became available for the study were used without regard to additional criteria of selection.

Double-embedded marrow specimens from the four areas were sectioned at five microns and the nuclei stained for a standard period with gallocyanin.

Cellularity of these sections was judged visually and photometrically. Five visual categories were described from the tissue at one extreme which appeared to contain only cells and no fat, to the tissue at the other extreme which appeared as mostly fat. These categories were based only on the amount of fat and did not include any considerations concerning cell spacing or ratio of blast to differentiated nuclei in each section. Photometric cellularity determinations were made of the humerus and femur sections, based on the cumulative amount of light absorbed by the stained nuclei in low and high power microscope fields. This light absorption was measured by a photometer attached to the

microscope and adjusted to register 100 on the scale with no nuclei in the field. The readings obtained were interpreted as an index of the relative cellularity, the lower readings indicating the highest degrees of cell concentration per unit area.

Approximate age groupings of the cats in this study were made on the basis of the presence or absence of the proximal and distal epiphyseal lines of the humerus as determined by radiographs. The condition and appearance of the teeth were also considered in this endeavor.

Findings of this study included the presence of similarly concentrated bone marrow in all four areas within each individual cat. No significant correlation of marrow cellularity to age or condition was apparent. The appearance of or absence of fat in marrow or the gross color of the marrow in any part of the long bones was not of any significance in predicting cellularity of the areas studied.

Cellularity, as determined photometrically, agreed fairly closely with the visual estimations of cell concentration. The photometric evaluations had the advantage of avoiding human differences of interpretation and of taking into consideration greater or lesser concentrations of nuclei in the cellular areas.

Preference of one of the four examined sites over any of the others as a source of marrow did not seem justifiable. Ease of site preparation, entry into the medullary cavity, or aspiration of the contents present therein differed, but these factors were not included in the observations of this study.