

THE DEVELOPMENT AND ATRESIA OF THE GRAAFIAN FOLLICLE
AND THE DIVISION OF INTRA-OVARIAN OVA IN THE GUINEA PIG

by

HOMER DALE KIRGIS

B. S. Kansas State College
Of Agriculture and Applied Science, 1936

A THESIS

submitted in partial fulfillment of the

requirements for the degree of

MASTER OF SCIENCE

KANSAS STATE COLLEGE
OF AGRICULTURE AND APPLIED SCIENCE

1937

KANSAS STATE COLLEGE LIBRARIES

(Box)
ment
LD
2668
T4
1937
K51
C.2

TABLE OF CONTENTS

	Page
ACKNOWLEDGMENTS.....	1
INTRODUCTION.....	2
REVIEW OF LITERATURE.....	2
MATERIAL AND METHODS.....	7
OBSERVATIONS.....	9
Normal Follicles.....	9
Slightly Atretic Follicles.....	10
Completely Atretic Follicles.....	18
Differentiation of Ova and Development of Follicles.....	19
Corpora Lutea.....	21
DISCUSSION.....	21
SUMMARY.....	26
LITERATURE CITED.....	27
APPENDIX.....	30

ACKNOWLEDGMENTS

The writer wishes to express his sincere appreciation to his major instructor, Dr. Mary T. Harman, Professor of Zoology, for her helpful advice and assistance during the progress of this research. The writer also wishes to thank Dr. H. L. Ibsen, Professor of Genetics, for furnishing the guinea pigs for this investigation.

INTRODUCTION

Except for the work of Engle (1927), little has been done on the relationship of follicular growth and atresia in pregnant animals. He made a quantitative study of follicular atresia during the oestrus cycle and the first four and one-half days of pregnancy. The reports concerning the rate of follicular growth and degeneration during the oestrus cycle have varied as well as the observations on the division of intra-ovarian ova.

The purpose of this investigation is to determine the extent of follicular growth, follicular atresia and the development of the ova within these follicles in the ovary of the guinea pig. Particular attention has been given to these conditions to determine their relation to the oestrus cycle and pregnancy.

REVIEW OF LITERATURE

Reports concerning follicular growth and degeneration deal mainly with their occurrence during the oestrus cycle. In the mouse the percentage of atretic follicles with antra varies with the oestrus cycle (Engle, 1927). The highest percentage of these follicles in an atretic condition is reached during the cornified cell stage when 86 per cent of

the follicles are undergoing degeneration. However, he finds the largest number of degenerating follicles occur at the beginning of the dioestrus period. During the first four and one-half days, the perimplantation period of pregnancy, there were fewer atretic follicles and there was no periodic divergence as in the ovaries of non-pregnant animals.

Following an investigation of a series of mammalian ovaries, Harman (1935) reported the universal occurrence of either ova in some stage of maturation or ova undergoing nuclear and cytoplasmic divisions or both in all ovaries examined. This investigation included observations on ovaries of the cat, rabbit, mouse, rat, and guinea pig.

Cyclic variations do not occur in the rabbit doe (Asami, 1920). He found that small, medium and large follicles undergo atresia at all stages of the oestrus cycle. They do not occur in greater numbers at one stage than at another. He states that degeneration of the granulosa is the primary factor in medium and large follicles, whereas in small follicles much greater degenerative changes occur in the egg than in the granulosa. He supports the theory advanced by Loeb (1917) and by Walsh (1917) that proliferation of the granulosa and indirectly of the ovary probably depends on an internal secretion of the ovum which acts as a growth stimulus.

It has been shown that only a small percentage of follicles reach maturity (Allen, Kountz and Francis, 1925). They found that in the ovary of the sow 10 to 14 days preceding ovulation there is an average of 45 visible follicles less than three mm. in diameter. Only 15 per cent of these follicles reach maturity and are ovulated. They suggest that only a limited amount of nutriment (material that can be utilized by the egg) is available so that there must be an elimination of some of the ova. The smaller number of follicles of preovulation size are considered the metabolic equivalent of the larger number of smaller follicles.

In his work on the guinea pig, Loeb (1917) made the observation that under certain conditions mitoses in the granulosa cells of the follicle are especially frequent around the ovum. He and later Walsh (1917) suggested that the stimulus for the growth of the granulosa cells which ultimately determines the growth of the whole follicle, depends upon a substance given off by the ovum. Loeb (1917) also reported that in underfed guinea pigs, those which had lost at least 25 per cent of their initial weight, maturation of follicles ceased and in the majority of cases the follicles became atretic before they had reached even medium size.

The Graafian follicles of guinea pigs which receive a vitamin C deficient diet undergo early degeneration (Kramer,

Harman and Brill, 1933). They observed that in extreme cases of the degeneration of the Graafian follicle there was neither a discus proligerus nor a stratum granulosum.

As a result of a study of the prepubertal follicle and of the process of follicular atresia from the first to the 37th day in the life of the albino mouse, Engle (1931) reported that until the appearance of the antrum folliculi on the 12th, 13th and 14th days there is a very slow growth of the follicle. However, on the 15th day the follicles increase greatly in size and reach almost the size of those found at the time of the first oestrus. He reports that follicular atresia does not appear to be cyclic as in the adult mouse and that pseudomaturational spindles and the degenerative fragmentation of such ova do not appear until after the ovum has attained mature size.

Conditions inducing atresia also seem to be a stimulation to maturation according to Pincus and Enzmann (1935). They injected crystalline thyroxin and thyroprotein into rabbit does on heat and observed that the increase in follicular atresia was accompanied by an increase in the number of ova undergoing maturation.

Following a study of the ovaries of 60 normal rats between the ages of 15 and 66 days, Lane (1935) reported that the average percentage of the total follicles which are vesti-

ular (those in which the granulosa was loosened or contained an antrum) ranges from 11 per cent at 15 days; to 39 per cent at 37 days; to 29 per cent at 50 days; and then rose to 50 per cent at ovulation at 66 days.

An average of from 400 to 500 young ova may differentiate in each ovary of the mouse at each normal oestrus period (Allen, 1923) while an average of four and one-half ova of an earlier generation mature. The percentage of survival thus approximates only about one per cent. Pregnancy does not interrupt the production and destruction of follicles in the rat (Swezy and Evans, 1930). They found that at the end of each five day period of pregnancy ripe follicles are present with many smaller follicles showing all stages of degeneration.

The extended parthenogenetic development of ova within the ovaries of the guinea pig was reported by Loeb (1932). This work is not in accord with that of Kampmeir (1929) for the dog, Newman (1913) for the armadillo, Smith (1925) for the opossum nor Kingery (1914) for the mouse. Their observations showed that the "developing egg" was completely destroyed by degeneration before many cytoplasmic and nuclear divisions had taken place.

MATERIAL AND METHODS

A group of 62 guinea pigs was used in this experiment. Forty-six of these animals had been pregnant for various lengths of time up to 35 days. The remaining 16 were not pregnant and were killed at different stages of the oestrus cycle. The guinea pigs used were all normal healthy animals. They were fed a well-balanced diet. For the group of pregnant animals the time of the last copulation was used in determining the duration of pregnancy. When the animals were killed, the number of embryos in each horn of the uterus was recorded. The ovaries were fixed in Bouin's fixing fluid and stained with Delafield's hematoxylin. Some were counterstained with eosin. The sections were 10 microns in thickness.

The non-pregnant animals were killed at different periods during the oestrus cycle. The day of the oestrus cycle was determined from the date of the last period of heat. A group of animals was killed during heat and the period immediately following. Two animals were killed while in heat, two on the first day and two on the third day of the oestrus cycle. The group representative of the mid-stage of the cycle consisted of one animal killed on the sixth day, two on the seventh day and one on the

ninth day. Those representing the late stages of the cycle included three groups of two animals each. One group killed on the 13th, one on the 14th and one on the 15th day of the cycle. There are two animals for each period of pregnancy listed in Table I except for the two, four, eight, 23 and 30 day periods.

The entire ovaries of some of the animals were examined for the number of the different types of follicles present. However, it was found that the relative number of these follicles in sections from the central portion of the ovary corresponded closely to the number found in the entire ovary. Therefore, the final examination consisted of observations made on serial sections from the central portion of each ovary. Extreme care was taken to obtain an exact count of all the follicles present. The section of the follicle in which the nucleolus was observed was, in most instances, the one recorded. If the nucleolus was not seen, the section was recorded in which the nucleus showed the most nuclear material. No count was made of the young ova directly beneath the germinal epithelium. However, notes were kept on the relative numbers existing in all animals.

A calibrated mechanical stage was used to record the positions of all the follicles observed.

OBSERVATIONS

On the basis of the degree of atresia the follicles were placed in three classes; normal follicles, slightly atretic follicles and completely atretic follicles. The follicles of both the pregnant and non-pregnant animals are classified in the same way.

Normal Follicles

The follicles classified as normal contained no degenerating cells. This group was further divided on the basis of the degree of development as small, medium or large. Two follicles listed as small are shown in Figures 1 and 6. These follicles are composed of from one to several layers of follicular cells. Many of them contain no antra but some show that one has begun to form as is seen in the small follicle in Figure 1. In the small follicle of Figure 6, the layers of follicular cells still closely surround the ovum. The ova and surrounding follicular cells of all the normal follicles are essentially alike in appearance. Cells undergoing mitoses are found in the young follicles especially.

A typical large follicle is also shown in Figure 1. The follicular cells have a compact arrangement, and none

are scattered in the follicular cavity. There are two small antra in the discus proligerus, but they are surrounded by definite layers of cells. The amount of chromatin in the granulosa cells of this follicle is considerably less than that in the degenerating granulosa cells of the slightly atretic follicles shown in Figures 4 and 5. The medium-sized group consists of follicles possessing antra approximately mid-way in development between that of the small follicle shown in Figure 1 and the antrum of the large follicle shown beside it. The ovum of the normal large follicle shown in Figure 2 is characteristic of the ova of all the normal follicles. The cytoplasm is finely granular. It is free of vacuoles and has a healthy compact appearance. Fine chromatin granules are scattered throughout the nucleus and the nucleolus is very distinct. No ova in any stage of maturation were found in follicles of this group. None gave evidence of degeneration by the presence of vacuoles or fragmenting nuclei.

Slightly Atretic Follicles

All the follicles listed in Tables I and II as containing eggs undergoing maturation were in a slightly atretic

Table 1. Follicles and Corpora Lutea in the Ovaries and the Number of Embryos of the Pregnant Animals.

Animal	Days	No. of small follicles	No. of medium-sized follicles	No. of large follicles	No. of corpora lutea	No. of follicles with egg maturing	No. of embryos in horn	No. of corpora lutea
<u>D-16</u>								
R-3	2	20	x	x	7	x	2	2
L-2	"	29	x	x	13	x	1	1
<u>I-12</u>								
R-5	4	27	x	x	11	x	1	1
L-5	"	33	x	x	8	x	2	2
<u>M-1</u>								
R-4	7	14	1	x	2	x	1	1
L-4	"	8	x	x	1	x	1	1
<u>M-9</u>								
R-4	"	6	x	x	2	2	2	2
L-4	"	20	x	x	4	x	1	1
<u>I-7</u>								
R-6	8	5	x	x	2	x	x	x
L-7	"	19	1	x	5	1	2	2
<u>M-2</u>								
R-5	9	5	x	x	1	x	3	3
L-5	"	12	x	x	1	x	x	x
<u>M-6</u>								
R-5	"	11	1	2	2	2	1	1
L-5	"	14	x	x	2	3	1	1
<u>R-8</u>								
R-5	11	16	1	x	3	3	2	2
L-4	"	32	x	x	x	3	2	2
<u>H-7</u>								
R-4	"	41	1	2	1	4	1	1
L-3	"	27	x	x	2	5	1	1
<u>I-4</u>								
R-4	12	48	1	1	5	3	1	1
L-4	"	34	2	2	5	3	1	1
<u>I-18</u>								
R-4	"	55	x	3	8	3	2	2
L-4	"	52	x	2	5	2	x	x
<u>H-1</u>								
R-4	13	23	1	x	5	2	1	1
L-3	"	19	x	1	3	1	1	1
<u>B-13</u>								
R-5	"	20	x	x	9	3	2	2
L-3	"	24	x	x	8	1	x	x

*Identification number and letter of animal is underscored. R and L indicate right and left ovaries respectively and the accompanying number indicates the slide of the series examined.

Table 1. (continued)

Animal:	Days:	No. of small follicles:	No. of medium-sized normal follicles:	No. of large normal follicles:	No. of corpora lutea like cysts:	No. of follicles with egg maturing:	No. of embryos in horns:	No. of corpora lutea:
G-10								
R-5	14	11	x	4	7	x	1	1
L-7	"	36	x	1	4	1	1	1
H-5								
R-2	"	32	1	1	6	x	1	1
L-4	"	31	x	3	13	2	1	1
G-13								
R-3	15	21	x	x	4	2	1	1
L-3	"	25	x	x	7	3	1	1
G-6								
R-4	"	18	1	1	6	1	1	1
L-6	"	26	x	x	5	1	1	1
G-4								
R-3	16	27	x	1	5	5	1	1
L-3	"	29	x	1	6	1	1	1
D-6								
R-5	"	21	x	2	4	1	x	x
L-3	"	24	x	x	1	x	1	1
G-17								
R-5	17	34	1	1	7	1	2	2
L-4	"	22	3	x	4	2	2	2
A-25								
R-3	"	33	1	2	4	1	1	1
L-3	"	45	x	x	6	1	1	1
D-1								
R-4	18	18	x	1	11	4	1	1
L-4	"	30	x	x	2	7	1	1
G-20								
R-5	"	21	x	2	4	2	1	1
L-4	"	25	x	1	x	1	1	1
G-2								
R-5	19	19	x	1	7	x	1	1
L-3	"	26	x	1	3	2	1	1
E-2								
R-2	"	24	x	x	6	4	x	x
L-4	"	25	1	2	4	3	2	2
G-18								
R-4	20	29	x	x	2	1	x	x
L-4	"	38	x	x	11	1	2	2
E-12								
R-4	"	22	x	x	2	x	5	5
L-3	"	23	x	x	4	2	x	x

Table 1. (continued)

: Animal and ovary :	: Days preg-nant :	: No. of small normal follicles :	: No. of medium-sized normal follicles :	: No. of large normal follicles :	: No. of corpora lutea-like :	: No. of follicles with egg maturing :	: No. of embryos in horns :	: No. of corpora lutea :
: R-4 :	:	:	:	:	:	:	:	:
: R-6 :	: 21 :	: 37 :	: x :	: 4 :	: 3 :	: 2 :	: x :	: x :
: L-5 :	: " :	: 28 :	: x :	: x :	: 1 :	: 1 :	: 1 :	: 1 :
: L-2 :	:	:	:	:	:	:	:	:
: R-4 :	: " :	: 17 :	: 1 :	: 1 :	: 4 :	: x :	: 1 :	: 1 :
: L-5 :	: " :	: 24 :	: x :	: x :	: 1 :	: 1 :	: 2 :	: 2 :
: A-30 :	:	:	:	:	:	:	:	:
: R-4 :	: 23 :	: 16 :	: x :	: 1 :	: 1 :	: x :	: 2 :	: 2 :
: L-4 :	: " :	: 20 :	: 1 :	: 1 :	: 3 :	: 1 :	: 1 :	: 1 :
: C-2 :	:	:	:	:	:	:	:	:
: R-4 :	: 24 :	: 26 :	: x :	: 3 :	: 4 :	: 2 :	: x :	: x :
: L-5 :	: " :	: 39 :	: x :	: x :	: 7 :	: 2 :	: 1 :	: 1 :
: M-16 :	:	:	:	:	:	:	:	:
: R-5 :	: " :	: 34 :	: x :	: x :	: 7 :	: 2 :	: 1 :	: 1 :
: L-4 :	: " :	: 29 :	: x :	: x :	: 7 :	: x :	: 1 :	: 1 :
: L-8 :	:	:	:	:	:	:	:	:
: R-6 :	: 25 :	: 37 :	: x :	: 1 :	: 1 :	: x :	: 1 :	: 1 :
: L-4 :	: " :	: 45 :	: x :	: 1 :	: 1 :	: x :	: 1 :	: 1 :
: M-5 :	:	:	:	:	:	:	:	:
: R-5 :	: " :	: 24 :	: x :	: 3 :	: 1 :	: x :	: 2 :	: 2 :
: L-5 :	: " :	: 34 :	: x :	: 1 :	: 4 :	: x :	: x :	: x :
: L-5 :	:	:	:	:	:	:	:	:
: R-8 :	: 27 :	: 25 :	: x :	: x :	: x :	: 1 :	: 2 :	: 2 :
: L-6 :	: " :	: 21 :	: x :	: x :	: 4 :	: 1 :	: 1 :	: 1 :
: M-17 :	:	:	:	:	:	:	:	:
: R-4 :	: " :	: 25 :	: x :	: 1 :	: 7 :	: x :	: 2 :	: 2 :
: L-5 :	: " :	: 33 :	: x :	: 2 :	: 1 :	: 1 :	: x :	: x :
: K-3 :	:	:	:	:	:	:	:	:
: R-5 :	: 29 :	: 24 :	: x :	: 2 :	: 3 :	: x :	: 1 :	: 1 :
: L-4 :	: " :	: 28 :	: x :	: 3 :	: 4 :	: x :	: x :	: x :
: L-4 :	:	:	:	:	:	:	:	:
: R-6 :	: " :	: 24 :	: x :	: 1 :	: 2 :	: 2 :	: 1 :	: 1 :
: L-5 :	: " :	: 31 :	: x :	: 3 :	: 6 :	: 5 :	: x :	: x :
: I-26 :	:	:	:	:	:	:	:	:
: R-4 :	: 30 :	: 28 :	: x :	: 1 :	: 2 :	: 1 :	: 1 :	: 1 :
: L-3 :	: " :	: 41 :	: x :	: 1 :	: 1 :	: x :	: x :	: x :
: A-10 :	:	:	:	:	:	:	:	:
: R-4 :	: 31 :	: 29 :	: x :	: x :	: 5 :	: 2 :	: 1 :	: 1 :
: L-5 :	: " :	: 18 :	: x :	: x :	: 10 :	: 2 :	: 2 :	: 2 :
: A-19 :	:	:	:	:	:	:	:	:
: R-4 :	: " :	: 22 :	: x :	: x :	: 1 :	: x :	: 1 :	: 1 :
: L-4 :	: " :	: 14 :	: x :	: x :	: 1 :	: x :	: 1 :	: 1 :

Table 1. (continued)

Animal	Days	No. of small normal follicles	No. of medium- sized normal follicles	No. of large normal follicles	No. of corpora luteal- like cysts	No. of follicles with egg maturing	No. of embryos in horn	No. of corpora lutea
R-12								
R-5	32	38	x	1	12	1	1	1
L-4	"	45	x	x	4	5	1	1
M-3								
R-3	"	32	x	x	x	1	1	1
L-5	"	23	x	2	x	1	x	x
L-1								
R-3	34	26	1	x	1	5	1	1
L-4	"	16	1	x	x	1	2	2
M-28								
R-4	"	27	1	x	6	1	2	2
L-7	"	24	x	1	4	x	x	x
Q-5								
R-3	35	40	x	3	1	1	x	x
L-6	"	23	1	x	5	x	1	1

Table II. Follicles and Corpora Lutea in the Ovaries of the Non-pregnant Animals.

Animal and ovary*	Time of cycle when killed	No. of small normal follicles	No. of medium-sized normal follicles	No. of large normal follicles	No. of corpora lutea like maturing	No. of follicles with egg	No. of corpora lutea
<u>K-4</u>	During						
R-4	heat	4	x	x	5	x	1
L-3	"	6	x	x	8	1	1
<u>H-9</u>							
R-3	"	20	x	x	9	x	2
L-2	"	22	x	x	6	x	2
<u>A-18</u>							
R-5	1st day	20	x	x	4	x	x
L-3	" "	14	x	x	4	x	1
<u>A-28</u>							
R-4	" "	30	x	x	7	x	1
L-6	" "	10	x	x	3	x	2
<u>A-29</u>							
R-5	3rd "	23	3	x	x	x	1
L-5	" "	6	1	1	x	x	2
<u>B-5</u>							
R-4	" "	33	x	x	9	x	1
L-3	" "	17	x	x	3	x	2
<u>I-13</u>							
R-3	6th "	19	x	x	x	2	3
L-4	" "	16	4	1	x	x	1
<u>A-11</u>							
R-4	7th "	21	2	x	3	1	1
L-3	" "	21	x	x	x	2	1
<u>A-34</u>							
R-2	" "	13	1	x	1	1	2
L-2	" "	10	x	2	1	2	1
<u>L-3</u>							
R-5	9th "	25	x	x	5	2	x
L-3	" "	42	x	x	8	4	1
<u>G-7</u>							
R-6	13th "	16	x	x	2	1	1
L-5	" "	41	x	2	2	0	x
<u>B-6</u>							
R-5	" "	18	1	1	11	3	2
L-4	" "	25	x	x	9	2	x
<u>B-11</u>							
R-6	14th "	16	x	1	6	x	x
L-3	" "	17	1	x	8	1	2

*Identification number and letter of animal is underscored. R and L indicate right and left ovaries respectively and the accompanying number indicates the slide of the series examined.

Table II. (continued)

	Time of:	No. of	No. of	No. of	No. of	No. of	No. of	No. of
Animal:	oestrus:	small	medium-	large	corpora:	follicles:	follicles:	follicles:
and	cycle	normal	sized	normal	luteal-:	with egg	corpora:	corpora:
ovary	when	follicles:	normal	follicles:	like	maturing	lutea	lutea
:	killed	:	follicles:	:	ovula	:	:	:
<u>B-10</u>	:	:	:	:	:	:	:	:
B-4	14th da:	9	x	x	5	1	2	:
L-4	" "	9	2	1	1	1	2	:
<u>B-10</u>	:	:	:	:	:	:	:	:
B-2	15th "	16	x	x	5	x	1	:
L-5	" "	4	x	2	1	1	x	:
<u>B-14</u>	:	:	:	:	:	:	:	:
B-4	" "	18	x	x	5	x	1	:
L-3	" "	45	x	x	15	2	x	:

condition. A typical follicle of this type is shown in Figure 3. The granulosa and discus proliferous cells here, in contrast to those of the corpora luteal-like cysts, seem to be degenerating. The amount of chromatin material in these cells has been increased as compared to those of the normal follicle in Figure 1. These enlarged masses of chromatin often appear like large nucleoli. The quantity of cytoplasm also increases until the cell wall finally bursts leaving the masses of chromatin to float free in the follicular fluid. The scattering of the degenerating follicular cells seen in Figure 3 is characteristic of these follicles.

The extruded polar body shown lying beside the ovum and the small polar spindle located near the periphery is also a characteristic condition. A higher magnification of the ovum is given in Figure 4. Neither the ovum nor the extruded polar body appears to be degenerating. The second polar spindle lies in the outer portion of the ovum. The second maturation division has advanced to the metaphase stage as shown by the position of the chromosomes at the center of the spindle. This condition was the most char-

acteristic for the ova of the slightly atretic follicles.

Figure 5 shows another follicle listed in this group. The first segmentation spindle is located near the center of the ovum. The two extruded polar bodies still remain in close contact with the wall of the ovum.

All of the follicles in this group are medium-sized or large. Several cases were observed in which most of the follicular cells had disintegrated and the cavity was filling by an ingrowth of theca-like cells. A few follicles in this group contain ova still in the resting condition. However, in each of these cases degeneration is evident in only a few of the granulosa cells indicating that atresia is still in an early stage. Even if there are as few as fifteen or twenty of the follicular cells disintegrating the ovum is in some stage of maturation.

Completely Atretic Follicles

The follicles listed as corpora luteal-like cysts are those in which the atretic condition is complete. The entire follicle gives the appearance of an area of connective tissue. Figure 6 shows the characteristic small size and general appearance of these follicles. The cells composing the cyst resemble enlarged follicular cells. They appear much like normal follicular cells in which the cytoplasm had been

increased about twice in amount. Theca-like cells surround these connective-tissue cells. The cysts seem to be formed from small follicles in which an ingrowth and enlargement of the cells of the stratum granulosum and an enlargement of the cells of the discus proligerus has occurred.

The ova of these follicles are closely encircled by this cyst-like tissue and are always in some stage of degeneration. All of the ova observed which showed signs of having undergone cleavage were in these follicles. Sometimes the divisions of the cytoplasm and nucleus are almost equal as shown in Figure 7. However, the degenerating condition shown by the irregular cell membranes and vacuoles is common for all the ova in this group of follicles. The nuclear and cytoplasmic divisions are generally very irregular. There often occurs several divisions of the nucleus with no or at least fewer divisions of the cytoplasm.

Differentiation of Ova and Development of Follicles

We found that after the 11th day of pregnancy and during the prooestral period the number of young differentiating ova directly beneath the germinal epithelium increases greatly. Before these times the young ova undergoing differentiation are sparsely scattered in the peripheral portion of the ovary. The ovaries of all animals which had

been pregnant for longer periods and those of the animals which were killed during prooestrus containing large masses of young ova. It was obvious that their rate of differentiation had been increased many times. However, that this increase in the number of young ova did not affect the number of Graafian follicles developing is shown in Tables I and II. The number of normal small follicles is fairly constant for both the pregnant and non-pregnant animals at all times.

The normal follicles ranged in size from the large one shown in Figure 1 to small ones in which the ovum was surrounded by a single row of follicular cells. A comparison of Figures 1, 3 and 5 shows the relative sizes of the normal large follicles and the typical slightly atretic and completely atretic follicles. These photographs were made with the same magnification. Both the normal and slightly atretic follicles are rather large. Figure 5 indicates the usual small size of the completely atretic follicles or corpora luteal-like cysts.

Immediately following the heat period and during the first 12 days of pregnancy there is a relatively small number of medium-sized and large follicles. After this there is, in most cases, from one to four or five in each ovary. During the first three days of the oestrus cycle and the

first nine days of pregnancy the relative number of the slightly atretic follicles, those which contain maturing eggs, is smaller than later. The number of corpora luteal-like cysts showed no significant variation in any of the animals examined.

Corpora Lutea

Tables I and II show the number of corpora lutea present in each ovary and, if the animal was pregnant, the number of embryos present in that horn of the uterus. Well-formed corpora lutea were found in the ovaries of all the pregnant animals and in each case their number checked with the number of embryos in the corresponding horn of the uterus. All of the sections of each ovary were examined for corpora lutea.

DISCUSSION

Our observations have shown a definite correlation between the condition of the ovum and the condition of the follicle. If the follicle were normal, the ovum which it contained was normal. If the follicle were slightly atretic as shown by a degeneration and scattering of the granulosa cells, the ovum was in some stage of maturation. There were a few exceptions to this condition. In these instances,

the follicles showed the very first indications of atresia. A small number, perhaps seven or eight, follicular cells were found undergoing degeneration and floating freely in the follicular fluid detached from the still normal granulosa cells. The eggs in these follicles were normal, and since the atretic condition evidently precedes the maturation of the egg it would seem to indicate that the atresia of the follicle stimulates the egg to begin its maturation divisions. This is in agreement with the report of Pincus and Enzmann (1935) in which the number of ova undergoing maturation was increased following the inducement of follicular atresia in rabbit does.

If the follicle were completely atretic and corpora luteal-like in appearance, the ovum either was degenerating or had divided into several portions. The ova contained in these follicles probably had not undergone the maturation divisions as no polar bodies were found attached to them. As mentioned before, the completely atretic follicles were quite small, the slightly atretic follicles were medium or large, and the normal follicles ranged from small to large. The variation which we have found in the atresia of these follicles is similar to that reported by Asami (1920) in rabbit does. He says that in the rabbit the atresia of medium and large follicles is primarily of the granulosa

while that of small follicles is primarily of the ovum and less pronounced in the granulosa. We have found this to be true also in the guinea pig. However, Asami does not mention any relation between the condition of the follicle and the condition of the egg as we have reported.

Concerning the numbers of the different types of follicles existing at different times during the oestrus cycle and pregnancy, we have found that in the guinea pig the number of small normal follicles is practically constant at all times. This number varies but little in spite of the fact that there are periods of increased production of ova by the germinal epithelium. Periods of more active proliferation of ova by the germinal epithelium have also been reported by Swezy and Evans (1930) for the rat; Allen (1923) for the mouse; and others. Therefore, there is a great mortality of young ova before any semblance of a follicle is formed; but regardless of the time, the ovary is producing approximately the same number of young follicles. Our data show that the number of corpora luteal-like cysts also remains fairly constant. This is not in accord with the report of Loeb (1917) in which he states that, although there is some variation, the proportion of ovarian follicles which are in the late stages of connective tissue atresia to well-preserved follicles and follicles in the stage of

granulosa degeneration show two maxima, one about six to seven days after ovulation and another at the time preceding the next ovulation.

Our observations show that medium or large follicles are present at all times, however, there is a relatively small number in the ovary during the period immediately following oestrus, and the first 12 days of pregnancy. Engle (1927) reported that in the mouse, the destruction of follicles is lowest on the second day of the oestrus cycle and that during early pregnancy the destruction of follicles as well as other ovarian activities is lowered. He does not distinguish between types of atresia. We have found that the destruction of the medium and large follicles is low during the first three days of the oestrus cycle and the first nine days of pregnancy. However, the destruction of small follicles continues at a regular rate during the entire oestrus cycle and up to the 35th day of pregnancy. Granulosa degeneration takes place in these follicles followed by the maturation of the egg. Since the follicular cells are destroyed by this atresia, the cavities of the degenerating follicles are filled probably by an ingrowth of theca cells.

A larger number of follicles are destroyed during early stages of development. The follicular cells of these

degenerating follicles become greatly enlarged until a small corpora luteal-like cyst is formed. The contained egg degenerates rapidly. However, the degeneration is sometimes preceded by several nuclear and cytoplasmic divisions. As reported by Harman (1935), we have found in this investigation that it is a common procedure for intra-ovarian ova to undergo both maturation divisions and in some cases to continue development by the formation of the first segmentation spindle. The cytoplasmic and nuclear divisions of intra-ovarian ova are also a common occurrence.

Our observations have not disclosed any indication of a far-going parthenogenetic development of intra-ovarian ova in the guinea pig such as Loeb (1932) reported in the guinea pigs in his laboratory. In fact, if we consider true parthenogenesis to be the regular development of a mature unfertilized ovum into a normal individual, or at least into the fundamentals of such an organism, none of the cases which we have observed can be considered true parthenogenesis. Our results are more in agreement with those of Kampmeir (1929) for the dog; Newman (1913) for the armadillo; Smith (1925) for the opossum; and Kingery (1914) for the mouse. Each of them has reported that the process is an abnormal division of the ovum which never continues until the fundamentals of an embryo are formed.

SUMMARY

Observations have been made on the ovary of the guinea pig at various stages of the oestrus cycle and at different times during pregnancy up to the 35th day. A quantitative study of Graafian follicles, maturing ova, ova undergoing cytoplasmic and nuclear divisions and corpora lutea was made.

1. In spite of the fact there are periods of increased differentiation of young ova from the germinal epithelium, the number of normal developing young follicles remains almost constant at all times.

2. The degeneration of these young follicles is a regular process continuing at approximately the same rate during all the stages studied. Their degeneration consists of an enlargement of the surrounding follicular cells until a corpora luteal-like cyst is formed. This is accompanied by a pronounced degeneration of the egg which sometimes results in several nuclear and cytoplasmic divisions.

3. The number of medium and large follicles increases following the third day of the oestrus cycle and the 12th day of pregnancy.

4. The percentage of degenerating medium and large follicles to normal follicles is highest at those times at which they are most numerous. Their destruction increases

on the ninth day of pregnancy. Their atresia consists of a degeneration and scattering of the granulosa cells followed by a maturing of the enclosed ovum.

5. Intra-ovarian ova which have passed through either one or both maturation divisions are common in the guinea pig. Also, it is not unusual to find ova which have proceeded in development to the formation of the first segmentation spindle. They are always found in medium or large follicles in which the granulosa cells have begun to degenerate.

6. Intra-ovarian ova which have passed through several cytoplasmic and nuclear divisions are found frequently in the ovary of the guinea pig. They are always in small corpora luteal-like cysts. No far-going parthenogenetic development of these ova was observed.

7. In every case the number of corpora lutea in the ovary equaled the number of embryos in the corresponding horn of the uterus.

LITERATURE CITED

Allen, E.

Ovogenesis during sexual maturity. Amer. Jour. Anat. 31:439-481. 1923.

Allen, E., Kountz, W. B., and Francis, B. F.

Selective elimination of ova in the adult ovary. Amer. Jour. Anat. 34:445-467. 1925.

- Asami, Goichi
Observations of the follicular atresia in the rabbit ovary. *Anat. Rec.* 18:323-343. 1920.
- Engle, E. T.
A quantitative study of follicular atresia in the mouse. *Amer. Jour. Anat.* 39:187-203. 1927.
- Engle, E. T.
Prepubertal growth of the ovarian follicle in the albino mouse. *Anat. Rec.* 48:341-350. 1931.
- Harman, Mary T.
Parthenogenesis in the ovaries of guinea pigs. *Kans. Acad. Sci., Trans.* 38:319-320. 1935.
- Kampmeir, O. T.
On the problem of "parthenogenesis" in the mammalian ovary. *Amer. Jour. Anat.* 43:45-76. 1929.
- Kingery, H. M.
So-called parthenogenesis in the white mouse. *Biol. Bull.* 27:240-258. 1914.
- Kramer, M. M., Harman, Mary T., and Brill, Alice K.
Disturbances of reproduction and ovarian changes in the guinea pig in relation to vitamin C deficiency. *Amer. Jour. Physiol.* 106:611-622. 1933.
- Lane, C. E.
The follicular apparatus of the ovary of the immature rat and some factors which influence it. *Anat. Rec.* 61:141-153. 1935.
- Loeb, L.
Factors in the growth and sterility of the mammalian ovary. *Sci.* 45:591-592. 1917.
- Loeb, L.
The parthenogenetic development of eggs in the ovary of the guinea pig. *Anat. Rec.* 51:373-409. 1932.
- Newman, H. M.
Parthenogenetic cleavage of the armadillo ovum. *Biol. Bull.* 25:52-78. 1913.

Pincus, G. and Enzmann, E. V.

The comparative behavior of mammalian eggs in vivo and in vitro. I. The activation of ovarian eggs. Jour. Exp. Med. 62:665. 1935.

Smith, Septima C.

Degenerative changes in the unfertilized uterine eggs of the opossum (Didelphis virginiana), with remarks on the so-called parthenogenesis in mammals. Amer. Jour. Anat. 35:81-103. 1925.

Swezy, Olive and Evans, H. M.

Ovarian changes during pregnancy in the rat. Sci. 71:46. 1930.

Walsh, L. S. N.

The growth of the ovarian follicle of the guinea pig under normal and pathological conditions. Jour. Exp. Med. 26:245-261. 1917.

APPENDIX

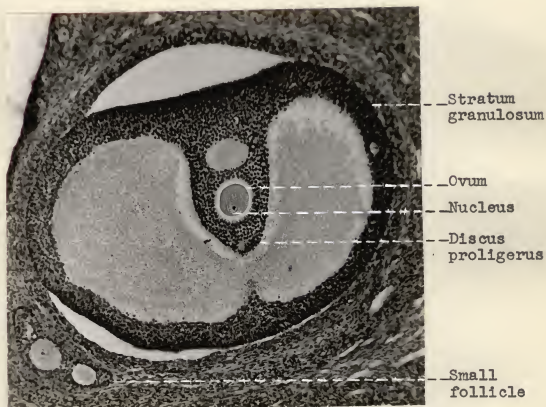


Fig. 1. Photomicrograph of a normal large follicle showing the ovum in the resting condition and the compact follicular cells of the stratum granulosum and discus proligerus. A normal small follicle is shown in the lower left corner.

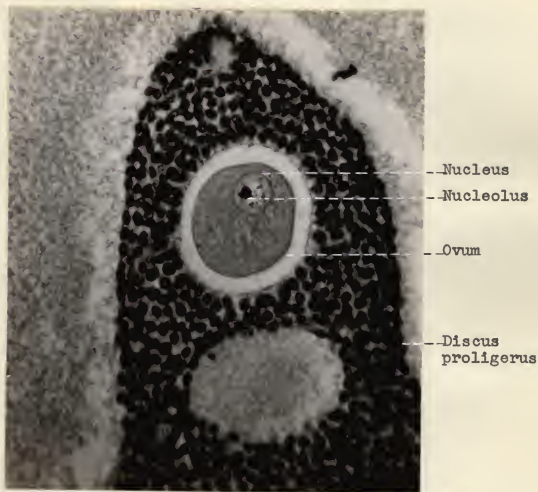


Fig. 2. Photomicrograph of the ovum of the normal large follicle of figure 1 (more highly magnified) showing the nucleolus and small particles of chromatin in the nucleus and the finely granular condition of the cytoplasm.

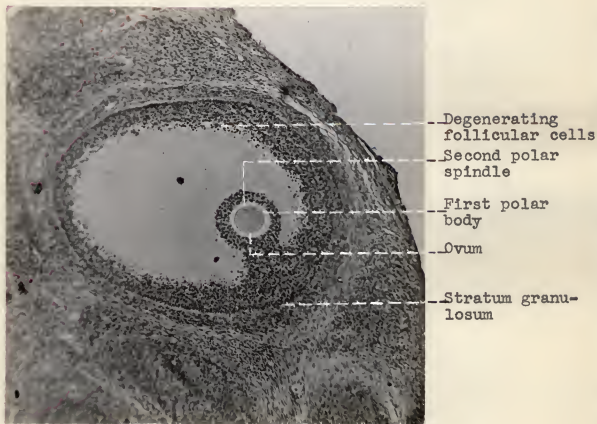


Fig. 3. Photomicrograph of a slightly atretic follicle showing the characteristic medium size, the degenerating follicular cells, the extruded first polar body and the second polar spindle.

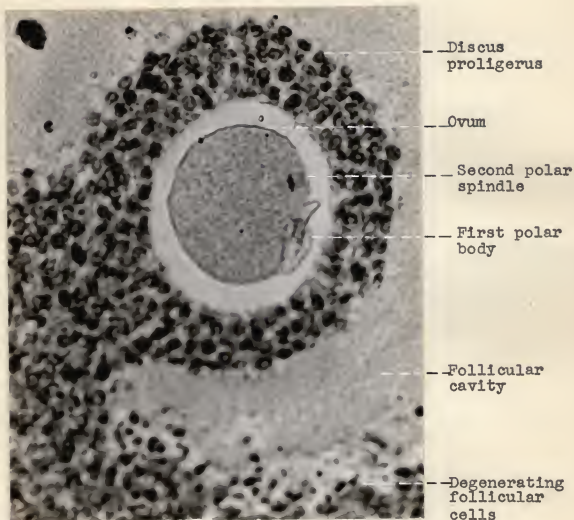


Fig. 4. Photomicrograph of the ovum of the slightly atretic follicle of figure 3 (more highly magnified) showing the first polar body, the second polar spindle and the degenerating follicular cells.




Fig. 5. Photomicrograph of the ovum of a slightly atretic follicle showing the first segmentation spindle, the two extruded polar bodies and the degenerating follicular cells.

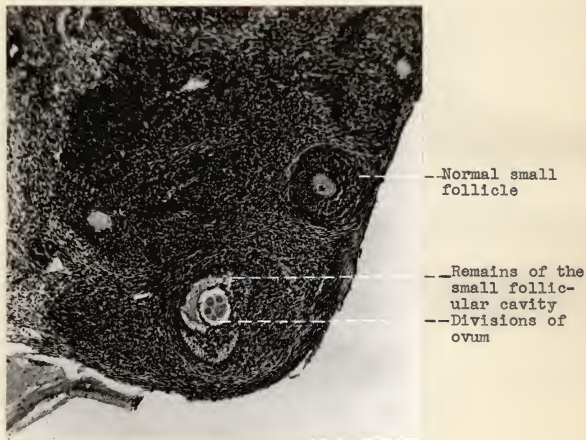


Fig. 6. Photomicrograph of a completely atretic follicle showing the characteristic small size of the follicle and the divisions of the ovum. A normal small follicle is shown above and to the right.

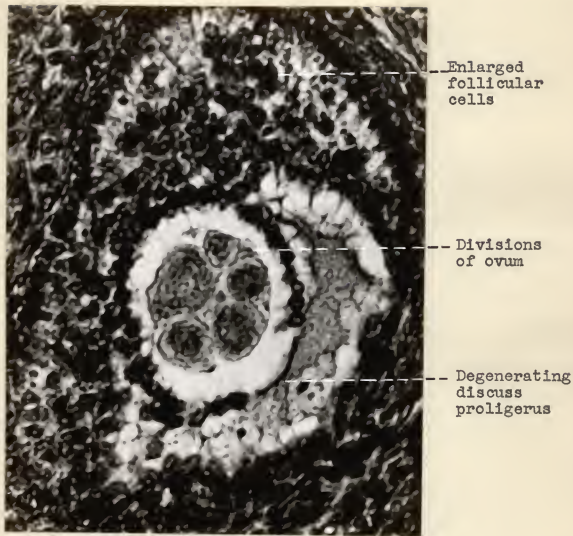


Fig. 7. Photomicrograph of a completely atretic follicle showing the divisions of the ovum and the enlarged follicular cells filling the follicular cavity.

