

THE DIAGNOSIS OF NOCARDIOSIS IN DOGS  
BY THE SKIN TEST AND THE COMPLEMENT FIXATION TEST

by

MOHAMED-TEWFIK FAWI ABDU

B.V.Sc., University of Khartoum (Sudan), 1957

---

A THESIS

submitted in partial fulfillment of the

requirements for the degree

MASTER OF SCIENCE

Department of Pathology

KANSAS STATE UNIVERSITY  
OF AGRICULTURE AND APPLIED SCIENCE

1960

LD  
266F  
T4  
1960  
A23  
C 2

Document

11

## TABLE OF CONTENTS

INTRODUCTION .....	1
REVIEW OF LITERATURE .....	1
Nocardiosis .....	1
Bacteriology of Nocardiosis .....	5
Pathogenicity in Laboratory Animals .....	6
Diagnosis .....	7
Inter-relationship Between Tuberculosis and Nocardiosis .....	8
MATERIALS AND METHODS .....	9
Cultivation of <u>Nocardia asteroides</u> .....	9
Animal Inoculation .....	12
Preparation of the Antigens .....	13
Skin Test in Guinea Pigs .....	15
The Complement Fixation Test in Guinea Pigs .....	17
Skin Test in Experimentally Infected Dogs .....	19
RESULTS AND DISCUSSION .....	20
Experimental Guinea Pigs .....	20
Experimental Dogs .....	30
SUMMARY AND CONCLUSIONS .....	42
ACKNOWLEDGMENTS .....	44
LITERATURE CITED .....	45

## INTRODUCTION

Nocardiosis in dogs produces nonspecific clinical signs. Diagnosis in living animals is therefore, difficult or sometimes impossible. The gross lesions found at necropsy most often simulate tuberculosis lesions (26).

Microscopic examinations of smears from the lesions, stained by the Ziel-Neelsen method often lead to conflict as to whether the organisms seen are tubercle bacilli or *Nocardia* species. This is due to the breakdown of the acid-fast branching filaments into rods by the purulent process (2).

Experimental animals inoculated with material obtained from cases of Nocardiosis give varied reactions (11). The encouraging results obtained by using skin tests and complement fixation tests as aids to the diagnosis of other bacterial, viral, mycotic, and parasitic diseases prompted this investigation to apply these tests to the diagnosis of Nocardiosis.

## REVIEW OF LITERATURE

### Nocardiosis

Nocardiosis is an acute or chronic infectious disease characterized by purulo-granulomatous swellings, affecting animals and man. The etiological agent is an aerobic Gram positive, inconsistently acid-fast bacterium belonging to the family Actinomycetaceae (3).

There is general agreement that the causative organism belongs to the genus *Nocardia*. Some research workers have identified the organism as *Nocardia asteroides*

Ginsberg and Little (14) reported a case of a four-month-old dog of Alsation breed showing loss of weight, loss of appetite, ulcerative lesions of lips, loss of hair, and great enlargement of the submaxillary lymph gland. After a few days the swelling in the submaxillary gland ulcerated. Smears from the exudate revealed Gram positive, inconsistent acid-fast branching filaments. Further bacteriological studies revealed that the organism isolated was *Nocardia asteroides*.

Bohl, et al. (4) described a case of a nine-month-old female terrier. Clinical examination revealed depression, hyperemia of the conjunctiva, chorea of the limbs, and a hot tender swelling on the right ventro-lateral aspect of the cervical region. Microscopic observation of smears from the swelling revealed beaded Gram positive filamentous organisms. Ziehl Neelsen's stained smears from the same material revealed inconsistent acid-fast filamentous organisms. Bacteriological classification of the organism placed it in the genus *Nocardia*.

A case of a three-year-old Cocker Spaniel was described by Cross and Nagao (9). The dog became ill during an outbreak of distemper. Symptoms manifested by the dog were pyrexia, anorexia, diarrhea, general weakness, emaciation, conjunctivitis, cough, and expiratory dyspnea. A tentative diagnosis of distemper complex was made. Necropsy revealed pneumonia with abscessations

and granulamatus bronchial lymph glands. Nocardia asteroides was isolated from the pus in the lungs.

In 1953, Thordal-Christensen and Clifford (25) observed a case in a seven-month-old German Shepherd. The dog has a history of being ill for two days. Clinical symptoms exhibited were vomition, diarrhea, anorexia, and fever. The dog died in the course of treatment. Necropsy revealed enlargement of all superficial lymph glands and caseation of all bronchial lymph glands. Nocardia asteroides was isolated.

Blake (3) described two cases, one involving a three-month-old male Cocker Spaniel. Clinical symptoms were dyspnea, soreness over the entire body, and pyrexia. The dog died. Necropsy revealed enteritis and nephritis. Organisms isolated proved to be Nocardia asteroides. The other case was a six-month-old collie. The dog was under tentative treatment for distemper complex. Clinical symptoms were dyspnea, anorexia, rhinitis, conjunctivitis, depression, and pyrexia. The dog died. Necropsy revealed hemorrhagic enteritis, focal areas of necrosis in the kidneys, pyothorax, and abscessation in the lungs. Nocardia asteroides was isolated.

Brodey and co-workers (5) reported a case in a nine-year-old pointer. The area involved was the subcutis of an extremity (Mycetoma). The dog showed persistent skin disorders involving the area of the foot below the right tibia. Green pus was exuding from the lesion. Skin in that region was reddened, moist, and showed alternative areas of crusts, scabs, and

exudates. Smears taken from the depth of the involved tissue and stained by Gram's method revealed Gram positive branching filamentous organisms. Microscopic observations of Ziehl Neelsen stain of the same material revealed partially acid-fast branching filamentous organisms. According to further bacteriological investigations, the organism was considered to belong to the genus *Nocardia*.

A case of a four-month-old puppy was considered by King, et al. (18). This puppy was vaccinated against distemper and rabies. Clinical symptoms were febrile reaction, anorexia, wobbly hind legs, swelling of the hock joints and stifle joints, and coughing. After euthanasia, necropsy was performed. The hock joints revealed bloody purulent exudate. The lungs were studded with single and confluent granulomata. Gram-stained smears from the lungs, and the exudate from joints revealed Gram positive beaded branching filamentous organisms. Further bacteriological studies classified the organism as *Nocardia asteroides*.

Two cases of Nocardiosis in dogs were described by Neal and Heath (20). The first case involved a four-month-old mongrel female with a history of being sick. Clinical examination revealed respiratory disturbances and abscessation in the subcutis. Post-mortem examination revealed abscesses in the subcutis, myocardium, spleen, lungs, liver, and kidneys. *Nocardia asteroides* was isolated from the pus. The second case was a one-year-old male dog which showed abscessation of the popliteal

lymph gland. Bacteriological investigations revealed Nocardia asteroides.

Johnson (17), in a study of Nocardiosis in dogs, observed two cases; one which was clinically diagnosed as pneumonia with no response to treatment. Euthanasia was performed. Necropsy revealed pyothorax and granulomatous lesions in the pleura and mediastinum. The other case was a generalized disease having paralyzed hind limbs and pus exuding from the sublaryngeal sinuses. Lesions also were found in the kidneys, liver, and pleura. Bacteriological examination of both cases revealed Gram positive beaded branching filamentous organisms, acid-fast but not acid alcohol fast. Classification placed these organisms in the group of Nocardia species.

In 1956, Sapegin and Cormock (23) reported a case of a five-week-old German Shepherd with a lesion of blisters on the ears which broke, exuding serous exudates. Condition of the patient deteriorated, with development of conjunctivitis, blepharitis, and the appearance of a number of swellings over the body. Bacteriological studies revealed the organism isolated to be Nocardia asteroides.

#### Bacteriology of Nocardiosis

Nocardia asteroides (Actinomyces asteroides), according to Wilson and Miles (26), was first isolated by Eppinger in 1891 from a brain abscess in a human patient. Threads showing true and false branchings and tiny rods were seen. The organisms



stained Gram positive and inconsistently acid-fast. Generally, it was resistant to decolorization by 1 percent  $H_2SO_4$  for five minutes, but not 25 percent  $H_2SO_4$  for one minute. It was an aerobic member of the Actinomycetes group which have characteristics intermediate between those of bacteria and molds. Growth occurs readily at  $37^{\circ} C.$  or at room temperature on a variety of simple media. It may be mistaken for tubercle bacilli in stained smears (26).

On solid media the colonies were usually glabrous, wrinkled, or granular and they closely resembled the growth of some acid-fast bacilli (8).

#### Pathogenicity in Laboratory Animals

Drake and Henrici (11) studied the pathogenicity of four strains of Nocardia asteroides in laboratory animals. They reported that pathogenicity varied greatly when using rabbits and guinea pigs. When they injected organisms subcutaneously, a local abscess developed which usually discharged pus, and healed spontaneously. When the organisms were inoculated intramuscularly, however, localized abscesses developed without rupturing. Organisms injected intraperitoneally caused military lesions in all parts of the body, and death occurred within 2 to 24 days.



## Diagnosis

Microscopic Diagnosis. Smears from abscesses, sinus walls, or biopsy specimens can be stained for microscopic study using either the Gram stain or the Ziehl-Neelsen stain (8). As noted previously, *Nocardia* species will be Gram positive and inconsistently acid-fast.

Cultural Methods. Conant and Rosebury (8) reported that growth can be obtained on blood agar plates or Sabouraud Glucose Agar. The incubation temperature was 37° C.

Serological Diagnosis. Complement Fixation Test. Henrici and Gardner (16) described an organism closely related to *Nocardia asteroides*, obtained from the sputum of a woman. An antigen from this strain was prepared by heating it at 60° C. for one hour and then under pressure of CO<sub>2</sub> until the mycelia disintegrated to form an even suspension. The suspension was passed through a porcelain bougie, and the filtrate collected. This filtrate was used as an antigen. It proved to be non-hemolytic and nonanticomplementary. Antigen mixed with the patient's serum gave a strong positive reaction.

The Skin Test. Drake and Henrici (11), in their study of allergic properties of *Nocardia asteroides*, infected rabbits and guinea pigs by injecting the oil suspension of *Nocardia asteroides* intratesticularly. This created a subacute or chronic infection in which it was possible to test for bacterial allergy.

The infected animals showed a specific delayed hypersensitivity reaction to a protein fraction and a polysaccharide

fraction of Nocardia asteroides. The animals also reacted feebly to an extract of the powdered organism. No reactions were observed in tuberculous guinea pigs, using the above three fractions.

#### Inter-relationship Between Tuberculosis and Nocardiosis

Henrici and Gardner (16) reported that acid-fast actinomycetes were closely related to tubercle bacilli in morphology, cultural characteristics, and even in their pathogenicity and serological reactions.

The human patient who was mentioned in their report, reacted positively to the Old Tuberculin.

Goyal (15), in his efforts to show the relationship between actinomycetes and mycobacteria, sensitized animals to Nocardia species. These animals proved to be sensitive to tuberculin.

Awad (2), in his survey of the relationship between Nocardia farcinicus infection in cattle and bovine tuberculosis, showed that both macroscopic and microscopic examinations were not sufficient to differentiate between them. His survey further showed that Nocardia farcinicus infection in cattle and guinea pigs might sensitize these animals to avian or mammalian tuberculin or both. This sensitivity may confuse the interpretation of the tuberculin tests.

## MATERIALS AND METHODS

Cultivation of Nocardia asteroides

The culture of Nocardia asteroides used in this project was obtained from the American Type Culture Collection and checked for purity, viability, and staining reactions. This strain was found to be Gram positive, and did not lose its acid-fast characteristics when decolorized with 10 percent  $H_2SO_4$  for five minutes. However, the acid-fast character of the organism was lost when decolorized by absolute alcohol or acid alcohol for five minutes.

Nocardia asteroides belongs to a group of micro-organisms intermediate between bacteria and molds (26). Therefore, subcultures were made on Sabouraud's Liquid Medium prepared according to the Difco Manual.

A loopful of the original culture was introduced into each tube, using aseptic procedures and the tubes incubated at  $37^{\circ}C$ . Growth appeared after two days incubation as faint white flakes floating on the surface of the media. These flakes soon coalesced, forming thick wrinkled surface pellicle. After a week of incubation the pellicle broke into thick flakes which fell to the bottom of the tube, resulting in no turbidity of the medium. Growth on the surface again occurred when incubated (Plate I).

#### EXPLANATION OF PLATE I

A seven-day culture of Nocardia asteroides on Sabouraud's Liquid Medium, showing pellicle formation on the surface of tube B, and sedimented flakes at the bottom of tubes A and C.

PLATE I



### Animal Inoculation

Guinea Pigs Inoculated with Nocardia asteroides. Sixteen guinea pigs were divided into four groups of four animals each. Three guinea pigs of each group were inoculated with Nocardia asteroides, and the fourth kept as an uninoculated control. These guinea pigs were obtained from the animal colony in the Pathology Department.

Five cc of a one-week-old growth of the organism in liquid Sabouraud's medium was checked for purity, centrifuged, and the sedimented organisms resuspended in 0.5 cc of aluminum hydroxide gel. This amount constituted one dose.

Each guinea pig inoculated received a biweekly dose intramuscularly until four doses were given. The skin test was performed one week after the last dose was administered.

Mycobacterium Tuberculosis Variety Human. Five guinea pigs were used in this experiment. Two animals were inoculated subcutaneously with a loopful of living human tubercle bacilli suspended in 0.5 cc normal saline. Two were inoculated with 0.25 cc of heat-killed human tubercle bacilli suspended in oil (supplied by U.S.D.A.). The fifth guinea pig was kept as a control.

Dogs Inoculated with Nocardia asteroides. A group of three mongrel dogs about seven-months-old were used for this study. Two of the animals were inoculated intra-thoracically with 5 cc of a culture of Nocardia asteroides. The organisms were grown in Sabouraud's liquid medium and incubated for seven days at

37° C. The third dog was kept as a control.

Temperature of the dogs was recorded daily.

#### Preparation of the Antigens

Frozen-thawed Antigen. *Nocardia* organisms were grown on Dubo's Albumin Medium (10) because this medium was reported to cause no sensitization nor to elicit nonspecific reactions in animals when injected intradermally (12). Five cc of the medium was distributed in each of two wide-surfaced flasks to provide a large surface for pellicle formation. The flasks were seeded with *Nocardia asteroides* and incubated at 37° C. Growth occurred as flakes on the surface after three days incubation, and these flakes fell to the bottom within a week, and new growth took place on the surface. The flasks were incubated for two weeks to obtain maximum growth of the organisms.

After the flasks were checked for purity, they were frozen and thawed twice a day. The organisms were checked for disintegration between periods of freezing and thawing. The majority of the organisms had disintegrated after 15 days of treatment from branching filamentous forms into minute coccoid forms.

The heated organisms were then centrifuged at a speed of 2500 rpm for one hour, and the supernatant fluid saved. Merthiolate was added to the supernatant to give an ultimate concentration of 1/1000. This constituted the frozen-thawed antigen.



The Heat-killed Antigen. Dubo's Albumin Medium (5 cc) was inoculated with the organism and incubated at 37° C. for two weeks. These flasks were then incubated at 56° C. for an additional three days. The organisms proved to be dead after this higher period of incubation, but the structural entity of the organisms was noted to be intact.

The tubes were centrifuged at a speed of 2500 rpm for one hour, and the supernatant fluid was treated in the same manner as in the frozen-thawed antigen.

The Phenol Extracted Antigen. A two-week-old pure growth of Nocardia asteroides in four tubes containing 5 cc each of Sabouraud's Liquid Medium was centrifuged. The supernatant was removed and the sedimented organisms were suspended in 5 cc of 0.85 percent saline containing 0.25 percent phenol. The suspension was refrigerated for seven days at 8° C. The suspension was agitated once daily during this storage.

The suspension was dialyzed in running water for 24 hours, and centrifuged at 5000 rpm for 30 minutes at the end of the seven days' storage. An adequate amount of 1/100 merthiolate was added to the supernatant fluid to bring the final concentration to 1/1000. This constitutes the phenol extracted antigen (22).

The Acid Alcohol Extracted Antigen. A two-week-old pure growth of Nocardia asteroides in four tubes containing 5 cc each of Sabouraud's Liquid Medium was centrifuged. The sedimented organisms were suspended in 5 cc of acid alcohol and incubated at 37° C. for one week. The suspension was shaken twice daily.

The suspension was again centrifuged at 2500 rpm for 30 minutes and the supernatant fluid was used as an acid alcohol extracted antigen.

Absolute Alcohol Extracted Antigen. A two-week-old pure growth of Nocardia asteroides in four tubes containing 5 cc each of Sabouraud's Liquid Medium was centrifuged. The sedimented organisms were suspended in 5 cc absolute alcohol and incubated at 37° C. for one week. The suspension was shaken twice daily during the period of incubation. The suspension was centrifuged at 2500 rpm for 30 minutes and the supernatant fluid constituted the absolute alcohol extracted antigen.

#### Skin Test in Guinea Pigs

Guinea Pigs Artificially Infected with Nocardia asteroides. The skin test was carried out a week after the last dose of Nocardia asteroides was given to the guinea pigs.

The first group of guinea pigs experimentally infected with Nocardia asteroides were used as a control for testing the Dubo's Albumin Medium used in the preparation of the heat-killed and the frozen-thawed antigen. The medium was not inoculated with the organism but contained the merthiolate. The technic used in preparing these animals for the skin test consisted of depilation of an area of the flank skin of each guinea pig. The thickness of the skin in that area was noted and the skin was then disinfected. One-tenth ml of the Dubo's Albumin Medium containing merthiolate (without the organism) was inoculated intradermally in the depilated area. Reactions at the site of

inoculation were observed at 24, 48, and 72 hours from the time of inoculation.

Two other groups of the infected guinea pigs were skin tested by the same technique, using heat-killed and frozen-thawed antigens extracted from Nocardia asteroides.

The animals were prepared in the same manner as stated above.

A 0.1 cc quantity of each of the two antigens was inoculated intradermally in a separate site in the depilated area of each of the eight guinea pigs. The distance between the two sites of injections was about an inch.

The areas were observed for reactions after 24, 48, and 72 hours. The last group of the infected guinea pigs, including the control, were used to check the cross reactivity of these infected animals to mammalian and avian tuberculins, using the skin reactions of the heat-killed and frozen-thawed antigens as control reactions.

Technic of preparing these animals consisted of depilating an area of the skin of each animal in both the right and the left flank. The disinfected depilated area in the right flank was used for the intradermal inoculation of the avian and mammalian tuberculins in an amount of 0.1 cc each. The depilated area in the left flank was used for the intradermal introduction of 0.1 cc each of the heat-killed and the frozen-thawed antigens. Readings of the reactions were recorded after 24, 48, and 72 hours.

Guinea Pig Sensitized to Human Tubercle Bacilli. This group was used to check the cross reactivity of such animals to heat-killed and frozen-thawed antigen extracted from Nocardia asteroides, using the skin reactions to the mammalian and the avian tuberculin as control reactions.

Technic of preparing these animals consisted of depilating an area of the skin in the region of the left and the right flanks of each animal. The depilated area in the right flank, after disinfection, was used for the intradermal inoculation of 0.1 cc of each of the heat-killed and the frozen-thawed antigens. Reading of the reaction was made after 24, 48, and 72 hours from the time of the inoculations.

#### The Complement Fixation Test in Guinea Pigs

Antigen dilutions of 1/10 in normal saline were made with the five antigens prepared. The five antigen dilutions were tested for pH values with bromthymol blue. Four antigen dilutions were found to be neutral, but the acid-alcohol extracted antigen was acid. It was brought to neutrality by adding a few drops of N/5 sodium hydroxide.

The complement fixation test was conducted according to the procedures mentioned in the Serological Tests for Syphilis Manual (24).

The hemolysin and the complement, in the presence of the antigens, were titrated each time the complement fixation test was conducted so as to determine the units of hemolysin and the units of complement to be used in the complement fixation test

with the sera.

Sera samples from four of the guinea pigs infected with Nocardia asteroides and two sera samples from control guinea pigs were used for the qualitative complement fixation test (Table 1).

Table 1. Protocol used in the qualitative complement fixation test.

Tube No.	: Anti-: : : : gen : Com- : : : 1/10 : ple- : : : Serum: dil. : ment*: Saline: : : (cc) :				Water : : : bath : Hemo- : Cells : at : lysin*: 2% : 37° C. : (cc) : for : : min- : : utes : :			Water bath at 37° C. for min- utes
1	0.1	0.5	1.0	0.0	30	0.5	0.5	30
2**	--	0.5	1.0	0.5	min-	0.5	0.5	min-
3**	0.1	--	1.0	0.5	utes	0.5	0.5	utes

\* 1 cc of complement used carries two full units, and 0.5 cc of hemolysin used carries two hemolytic units.

\*\* Tube No. 2 was an anticomplementary control of the antigen, and Tube No. 3 was the anticomplementary control of the serum.

Quantitative Complement Fixation Test. Four other sera from the guinea pigs infected with Nocardia asteroides, in addition to the six sera used in the qualitative complement fixation test (13) and the sera from the guinea pigs inoculated with both heat-killed and live human tubercle bacilli, were used in the quantitative complement fixation test (Table 2).

Table 2. Protocol used in the quantitative complement fixation test.

Tube No.	:Antigen: Com-:			Water bath	:Hemo-:Cells:		Incubate at
	:Serum:	:dil.:	:ple-ment:		:lysin:	:2%:	
	(cc)				(cc)		
1	0.1	0.5	1	37° C.	0.5	0.5	37° C.
2	0.25	0.5	1	for	0.5	0.5	for
3	0.5	0.5	1	30	0.5	0.5	30
4*	0.1	--	1	min-	0.5	0.5	min-
5*	0.25	--	1	utes	0.5	0.5	utes
6*	0.5	--	1		0.5	0.5	

\* Tubes No. 4, 5, and 6 were anticomplementary control of the sera.

#### Skin Test in Experimentally Infected Dogs

A skin test was made one month after the animals were inoculated with Nocardia asteroides.

Three dogs, including one control dog, were subjected to the skin test, using the two antigens extracted from Nocardia asteroides and the mammalian and avian tuberculins.

Technic of preparing these animals for the skin test consisted of depilating an area of the skin in the mid third of the neck on both sides. The depilated area in the right side of the neck was used for the intradermal inoculation of 0.1 cc each of the avian and the mammalian tuberculins. The depilated area in the left side of the neck was used for the intradermal inoculation of 0.1 cc each of the heat-killed and frozen-thawed antigens. Reactions at the sites of inoculations were observed at the end of 24, 48, and 72-hour periods.

## Quantitative Complement Fixation Test in Dogs

Sera from the three dogs inoculated with Nocardia asteroides were tested by the quantitative complement fixation test. The same protocol as that used on sera of the guinea pigs was employed.

Necropsy. At the end of the project, the two infected dogs were necropsied. Representative tissue sections from pleura, lungs, bronchial lymph glands, and kidneys were taken for histopathological study.

## RESULTS AND DISCUSSION

### Experimental Guinea Pigs

The Skin Test. Effect of Intradermal Inoculation of Dubo's Albumin Medium Without Growth of Nocardia asteroides but Containing Merthiolate in a Final Concentration of 1/1000 on Artificially Infected Guinea Pigs. Twenty-four hours after inoculation, the animals showed only a little localized edema and erythema at the site of injection. This reaction disappeared in 48 hours, which indicated that the inoculum did not elicit any reactions either in the experimentally infected or the control animals.

Assay of the Intradermal Inoculation of the Frozen-thawed and the Heat-killed Antigens from Nocardia asteroides on Guinea Pigs Experimentally Infected with Nocardia asteroides. Twenty-four hours after intradermal inoculation with antigens, the infected animals showed an inflammatory edema, erythema, and induration at the sites of the injections. The reaction appeared



to attain its climax 48 hours after inoculation when hemorrhagic areas appeared to be brownish red, surrounded by hyperemia. Edema and induration still were marked (Plate II). On the fourth day, the reaction began to subside and it disappeared within a week. There was no noticeable reaction in the control guinea pigs.

The extent of the reaction to the heat-killed antigen appeared to be less than the reaction to the frozen-thawed antigen.

The measurements of erythema and edema at the end of 48 hours, in response to intradermal inoculation of both the frozen-thawed and the heat-killed antigen, is shown in Table 3. The test was regarded positive when erythema and edema measured more than 1.0 cm, negative when less than 0.5 cm, and doubtful when between 0.5 and 1.0 cm in diameter at the end of the 48 hours.

Table 3. Results of intradermal inoculation of frozen-thawed antigen and heat-killed antigen on guinea pigs experimentally infected with Nocardia asteroides.

:Reaction to frozen-: : thawed antigens :				: Reaction to heat- : : killed antigen :		
Animal:	Erythema:	Edema :		: Erythema:	Edema :	
No. :	(cm)		: Results :	(cm)		: Results
1	1.5	2.5	Positive	1.0	1.5	Positive
2	1.3	2.6	"	0.8	1.4	"
3	2.0	3.1	"	1.2	1.8	"
4	1.7	3.0	"	1.0	1.7	"
5	1.2	2.3	"	0.7	1.2	"
6	1.8	3.2	"	1.0	1.6	"
7*	none	none	Negative	none	none	Negative
8*	"	0.2	"	"	0.1	"

\* Animals No. 7 and 8 were the control guinea pigs.

EXPLANATION OF PLATE II

Guinea pig sensitized to Nocardia asteroides

- A. Dermal reaction to the frozen-thawed antigen (0.1 cc).
- B. Dermal reaction to the heat-killed antigen (0.1 cc).

## PLATE II



Inter-relationship of the Dermal Reactions Caused by Avian and Mammalian Tuberculins to That Caused by the Injection of Frozen-thawed Antigen and Heat-killed Antigen in Guinea Pigs Infected with Nocardia asteroides. Table 4 shows the measurements of erythema and edema 48 hours after dermal introduction of mammalian and avian tuberculins and the two extracted antigens from Nocardia asteroides.

Table 4. Intradermal reactions to avian and mammalian tuberculins and to frozen-thawed and heat-killed antigens.

Guinea pig No.	: Reaction to : frozen-thawed: : antigen		: Reaction to : heat-killed : : antigen		: Reaction to : avian : tuberculin		: Reaction to : mammalian : tuberculin	
	Ery- : thema	:Edema	Ery- : thema	:Edema	Ery- : thema	:Edema	Ery- : thema	:Edema
	(cm)							
1	1.6	3.0	0.8	1.5	0.7	1.2	0.8	1.6
2	0.7	2.8	0.6	1.2	0.6	1.0	0.5	1.0
3	1.8	3.4	1.0	1.8	0.2	0.4	none	0.2
4*	none	none	none	none	none	0.1	"	none

\* Animal No. 4 was the control.

It can be seen from Table 4 that Nocardia asteroides did sensitize some of the guinea pigs to avian and mammalian tuberculins, but the response was irregular.

Assay of the Intradermal Inoculation of the Frozen-thawed and the Heat-killed Antigens on Tuberculous Guinea Pigs. Results of the skin reaction of the tuberculous guinea pigs to the two extracted antigens from Nocardia asteroides and to the avian and mammalian tuberculins were observed 48 hours after the intradermal

inoculation. The response to the heat-killed antigen was somewhat meager in comparison to the frozen-thawed antigen.

The measurements, at the end of 48 hours, of the erythema and edema from heat-killed and frozen-thawed antigens using the avian and the mammalian tuberculin as controls are shown in Table 5.

Table 5. Results of intradermal inoculation of frozen-thawed and heat-killed antigens on tuberculous guinea pigs.

	: Reaction to		: Reaction to		: Reaction to		: Reaction to	
	: frozen-thawed:		: heat-killed:		: avian		: mammalian	
	: antigen		: antigen		: tuberculin		: tuberculin	
Guinea	: Ery-	: Ery-	: Ery-	: Ery-	: Ery-	: Ery-	: Ery-	: Ery-
pig	: thema	: Edema	: thema	: Edema	: thema	: Edema	: thema	: Edema
No.	:	:	:	:	:	:	:	:
				(cm)				
1	0.7	1.2	0.5	1.0	0.5	0.9	2.5	3.3
2	0.4	0.7	0.2	0.4	0.6	1.0	2.0	3.0
3*	none	none	none	none	none	none	none	none
4*	"	"	"	"	"	"	"	"
5**	"	"	"	"	"	"	"	"

\* Animals No. 3 and 4 received a live human tubercle bacilli. Their failure to react to any of the antigens was thought to be due to desensitization by the previous infection.

\*\* Animal No. 5 was the control.

The Complement Fixation Test. In the process of titration of the complement, the absolute alcohol extracted antigen proved to be anticomplementary in a 1/10 dilution. The other four antigens extracted from Nocardia asteroides proved to be not anticomplementary in a 1/10 dilution in normal saline.

Qualitative Complement Fixation Test Using the Four Complementary Antigens Extracted From Nocardia asteroides Against

Sera From Guinea Pigs Infected With Nocardia asteroides. The results of the test are shown in Table 6. There were varying degrees of fixation when the frozen-thawed antigen and the heat-killed antigen in a 1/10 dilution were titrated against the sera from the infected guinea pigs. There was complete hemolysis in the sera obtained from the control animals. When the phenol extracted antigen and the acid alcohol extracted antigen were titrated against the same sera, complete hemolysis resulted. This showed that the frozen-thawed antigen and the heat-killed antigen were antigenic and nonhemolytic in a dilution of 1/10. The frozen-thawed antigen was superior to the heat-killed antigen. The other two antigens were nonantigenic in a dilution of 1/10.

Table 6. The results of the Qualitative Complement Fixation Test against six sera of guinea pigs infected with Nocardia asteroides.

Serum No.	: Frozen- : thawed : antigen	: Phenol : extracted : antigen	: Heat- : killed : antigen	: Acid : alcohol : extracted : antigen
1	++	0	+	0
2	+	0	0	0
3	++	0	+	0
4	+	0	+	0
5*	0	0	0	0
6*	0	0	0	0

\* Sera No. 5 and 6 were obtained from control animals.

0 = no fixation      + = 25% fixation      ++ = 50% fixation

The Quantitative Complement Fixation Test on the Sera of Guinea Pigs Injected with Nocardia asteroides. The frozen-thawed and heat-killed antigens in 1/10 silution were used. The results of the test are shown in Table 7. Positive reactions were obtained with the sera of the infected animals when frozen-thawed antigen was used, but inconsistent results were obtained when the heat-killed antigen was used.

Table 7 . Results of the Complement Fixation Test using the frozen-thawed antigen.<sup>1</sup>

Serum No.	: Tube 1 : : 0.1 cc :	: Tube 2 : : 0.25 cc :	: Tube 3 : : 0.5 cc :	: Tube 4 : : 0.1 cc :	: Tube 5 : : 0.25 cc :	: Tube 6 : : 0.5 cc :
1	++	++	+++	0	0	0
2	+	++	+++	0	0	0
3	++	+++	++++	0	0	+
4*	+	++	+++	0	0	0
5*	+	+++	++++	0	0	0
6*	+	++	+++	0	0	0
7	+	++	+++	0	0	0
8	++	+++	++++	0	0	+
9**	0	0	0	0	0	0
10**	0	0	0	0	0	0

<sup>1</sup> +++, ++, + = 100, 75, 50, and 25 percent fixation, respectively. 0 = no fixation.

\* Tubes 4, 5, and 6 are anticomplementary control of the sera.

\*\* Sera No. 9 and 10 were obtained from control guinea pigs.



Table 8. Results of the Complement Fixation Test, using the heat-killed antigen.<sup>1</sup>

Serum No.	Tube 1 : 0.1 cc	Tube 2 : 0.25 cc	Tube 3 : 0.5 cc	Tube 4 : 0.1 cc	Tube 5 : 0.25 cc	Tube 6 : 0.5 cc
1	0	+	++	0	0	0
2	0	+	++	0	0	0
3	+	++	+++	0	0	0
4*	+	++	+++	0	0	0
5*	0	+	++	0	0	0
6*	0	+	++	0	0	0
7	0	+	++	0	0	0
8	0	+	++	0	0	0
9**	0	0	0	0	0	0
10**	0	0	0	0	0	0

<sup>1</sup> +++, ++, + = 75, 50, and 25 percent fixation, respectively.  
0 = no fixation.

\* Tubes 4, 5, and 6 are anticomplementary control of the sera.

\*\* Sera No. 9 and 10 were obtained from control guinea pigs.

It appeared that 50 percent fixation of the complement by 0.25 cc of serum from experimentally infected animals should be considered as a positive reaction.

The Complement Fixation Test on Sera of Tuberculous Guinea Pigs. The heat-killed and the frozen-thawed antigens were used in a dilution of 1/10. The results of the test are shown in Tables 9 and 10.

The results showed that the sera from the tuberculous guinea pigs reacted in an inconsistent manner.

The correlation of the results of the quantitative complement fixation test and the skin test on artificially infected guinea pigs with Nocardia asteroides, using both the frozen-thawed and the heat-killed antigens are shown in Table 11.

Table 9. Results of the Complement Fixation Test on tuberculous guinea pigs' sera, using the frozen-thawed antigen.

Serum No.	: Tube 1 : : 0.1 cc :	: Tube 2 : : 0.25 cc :	: Tube 3 : : 0.5 cc :	: Tube 4 : : 0.1 cc :	: Tube 5 : : 0.25 cc :	: Tube 6 : : 0.5 cc :
1	0	+	++	0	0	0
2	0	+	++	0	0	0
3	+	+++	ac*	0	0	ac
4	0	0	+	0	0	0
5	0	0	0	0	0	0

Table 10. Results of the Complement Fixation Test on tuberculous guinea pigs' sera, using the heat-killed antigen.

Serum No.	: Tube 1 : : 0.1 cc :	: Tube 2 : : 0.25 cc :	: Tube 3 : : 0.5 cc :	: Tube 4 : : 0.1 cc :	: Tube 5 : : 0.25 cc :	: Tube 6 : : 0.5 cc :
1	0	0	0	0	0	0
2	0	+	++	0	0	0
3	0	++	ac	0	0	ac
4	0	0	0	0	0	0
5	0	0	0	0	0	0

\* ac = anticomplementary.

+++ , ++ , + = 75, 50, and 25 percent fixation, respectively;  
0 = no fixation.

Table 11. Results of the skin test and the Complement Fixation Test on guinea pigs injected with Nocardia asteroides.

Animal No.	: Skin test		: Complement Fixation test	
	: Frozen- : thawed : antigen	: Heat- : killed : antigen	: Frozen- : thawed : antigen	: Heat- : killed : antigen
1	+	+	+	±
2	+	+	+	±
3	+	+	+	+
4	+	+	+	+
5	+	+	+	±
6	+	+	+	±
7	+	+	+	±
8	+	+	+	+
9	-	-	-	-
10	-	-	-	-

+, ±, - = Positive, doubtful, and negative, respectively.

### Experimental Dogs

Four days after intrathoracic inoculation of Nocardia asteroides, the two injected dogs began to show symptoms of depression, anorexia, congested conjunctiva, and pyrexia. These were followed by dyspnea and coughing. The animals became lame in the hind legs with accompanying edema. Progressive loss of weight was noticed in both dogs.

Daily temperature records are shown in Plate III.

Skin Test. The Dermal Effects of the Avian Tuberculin, Mammalian Tuberculin, the Frozen-thawed, and the Heat-killed Antigens on Experimentally Infected Dogs with Nocardia asteroides. Twenty-four hours after the inoculation of the heat-killed and the frozen-thawed antigens, the infected dogs began to develop edematous erythematous swellings at the sites of inoculations. The reactions attained their maximum 48 hours after inoculation, began to subside by the fourth day, and disappeared within a week. In the control dog, there was no noticeable reaction.

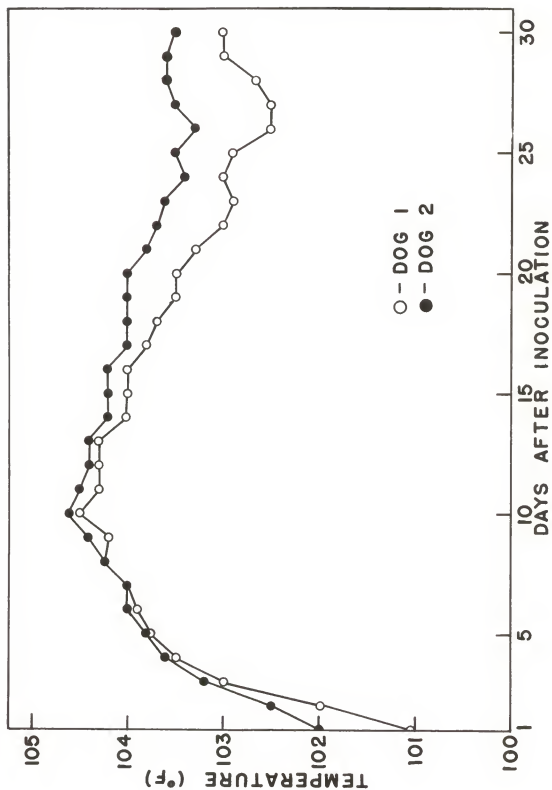
Dermal reactions to the tuberculins were in the form of nodular swellings but no edema or erythema was noted. Reactions to both tuberculins were not conspicuous in comparison to those from the two antigens prepared from Nocardia asteroides.

In comparing the reactions to both heat-killed and frozen-thawed antigens, it appeared that the frozen-thawed was more reliable than the heat-killed.

EXPLANATION OF PLATE III

Daily temperature recording of the two dogs  
infected with Nocardia asteroides during the course  
of the experiment.

PLATE III



The measurements obtained in response to both tuberculins, frozen-thawed, and heat-killed antigens, are shown in Table 12.

Table 12. Results of the dermal reactions to the frozen-thawed, heat-killed, avian tuberculin, and mammalian tuberculin in dogs experimentally infected with Nocardia asteroides.

		Measurements (mm)							
		:Frozen-thawed:		Heat-killed:		Avian		: Mammalian	
		: antigen		: antigen		: tuberculin		: tuberculin	
Animal	:	Readings							
No.	:	1st	: 2nd	: 1st	: 2nd	: 1st	: 2nd	: 1st	: 2nd
1		4	8	4	6	4	6	4	5.5
2		4	9	4	7	4	6	4	6
3*		5	6	5	5	5	6	5	5

\* Dog No. 3 was the control.

A test was considered positive when there was a difference of 3 mm or more between the 48-hour reading and the initial reading of the thickness of the skin.

The Quantitative Complement Fixation Test on Sera from the Dogs Experimentally Infected with Nocardia asteroides. The heat-killed and the frozen-thawed antigens were used in a dilution of 1/10 each. The results of the test are shown in Tables 13 and 14.

Correlation of the experimentally induced infection with the reaction of the sera in the complement fixation test suggested that 50 percent fixation, using 0.25 cc of the serum, was a positive titer.

Table 13. Results of the Quantitative Complement Fixation Test, using the frozen-thawed antigen against sera from dogs experimentally injected with Nocardia asteroides.

Serum No.	Tube 1 : 0.1 cc	Tube 2 : 0.25 cc	Tube 3 : 0.5 cc	Tube 4 : 0.1 cc	Tube 5 : 0.25 cc	Tube 6 : 0.5 cc
1	+	++	+++	0	0	0
2	++	+++	+++	0	0	0
3*	0	0	0	0	0	0

Table 14. Results of the Quantitative Complement Fixation Test, using the heat-killed antigen against sera from dogs experimentally infected with Nocardia asteroides.

Serum No.	Tube 1 : 0.1 cc	Tube 2 : 0.25 cc	Tube 3 : 0.5 cc	Tube 4 : 0.1 cc	Tube 5 : 0.25 cc	Tube 6 : 0.5 cc
1	+	+	++	0	0	0
2	+	++	+++	0	0	0
3*	0	0	0	0	0	0

++++, +++, ++, + = 100, 75, 50, and 25 percent fixation, respectively; 0 = no fixation.

\* No. 3 serum was obtained from the control dog.

Necropsy and Histopathology of the Two Injected Dogs. The two injected dogs were euthanised. Necropsy revealed that the two carcasses were emaciated and essentially showed the same gross lesions.

When the abdomen was opened, nothing abnormal was noted except the kidneys which showed focal cortical necrosis surrounded by hyperemia.

When the thorax was opened, the parietal and visceral pleura were hyperemic and covered with raised greyish nodules 2 to 5 mm in diameter. The bronchial lymph nodes were greatly enlarged.



Grey pin-point nodules were sporadically distributed in the substance of the lungs.

A crushed smear was made from one of the nodules on the pleura and stained with Ziehl-Neelsen stain. On microscopic examination, acid-fast branching filamentous organisms were seen which had the morphology of Nocardia asteroides. Organisms were isolated in pure culture from one of the nodules on Sabouraud Liquid Medium.

A histopathological study was made on hemotoxylin and eosin stained sections from a bronchial lymph node and the lung. The bronchial lymph node appeared to be hyperemic and showed the presence of granulomatous nodules at different stages of development. In the younger nodules, there was an infiltration of neutrophils and epithelioid cells with the former outnumbering the latter. Few foreign body giant cells were seen. In the older nodules the majority of the infiltrating cells were epithelioid cells and lymphocytes with some foreign body giant cells.

Some nodules also were seen with a bacterial colony in the center, encircled by an inner wall of neutrophils, and an outer zone infiltrated with polymorphs, lymphocytes, and epithelioid cells (Plate IV).

Microscopically, the section from the lung revealed a thick fibrous visceral pleura (Plate V). Hyperemia and a small degree of edema involving the alveoli were observed.

#### EXPLANATION OF PLATE IV

Fig. 1. Nodule from the bronchial lymph gland of one of the experimental dogs (Hemotoxylin and Eosin x95).

A. Capsule.

B. Bacterial colony.

C. Zone of neutrophils.

D. Zone of neutrophils, lymphocytes,  
and epitheloid cells.

Fig. 2. Nodule from the bronchial lymph gland of one of the experimental dogs (Hemotoxylin and Eosin x450).

A. Bacterial colony.

B. A zone of neutrophils.

C. A zone of neutrophils, lymphocytes,  
and epitheloid cells.

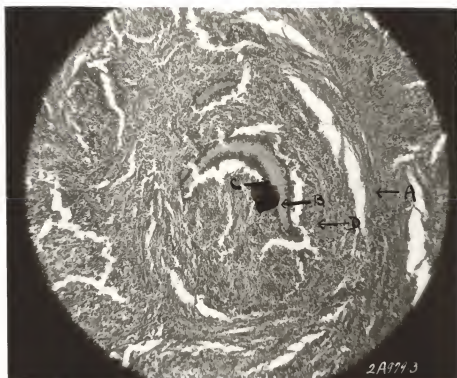


Fig. 1

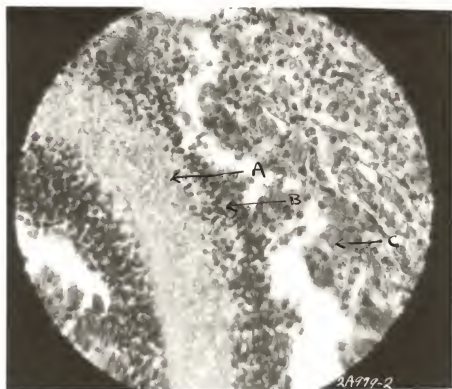
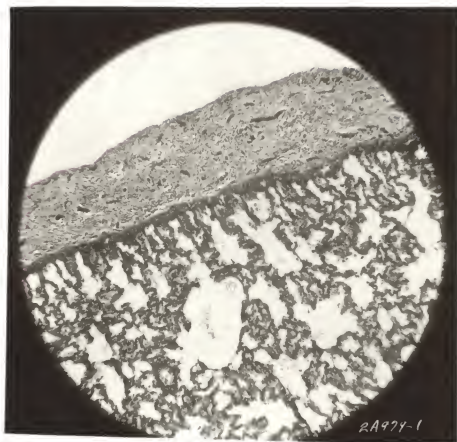


Fig. 2

EXPLANATION OF PLATE V

Lung from experimental dog. Visceral pleura is thickened and fibrous (Hemotoxylin and Eosin x95).

## PLATE V



According to the literature, Nocardiosis may affect dogs of all ages with no preference of sex or breed, but it may be more prevalent in young canines.

A common syndrome exhibited by the infected animals was a respiratory disturbance. This may lead to a tentative diagnosis of distemper complex when the animal is young (3, 9, 23), and to a diagnosis of tuberculosis when the animals are older (20).

Gross lesions found on necropsy were similar to those found in tuberculosis. The waxy materials responsible for the acid-fast characteristic in tubercle bacilli and *Nocardia* species appear to be similar chemically from the staining reaction and initiate similar tissue reactions.

Microscopic examinations of smears from the lesions stained by Ziehl-Neelsen method may sometimes give a false interpretation, due to the breaking down of the mycelia into rods similar in morphology to tubercle bacilli (2). Gram stain was of little value when these mycelia were broken down into rods.

Specimens suspected of containing actinomyces should be examined routinely for tubercle bacilli (18).

The frozen-thawed antigen of *Nocardia asteroides* yielded the most potent skin test antigen and complement fixing antigen both in the guinea pigs and in the experimental dogs, when the two kinds of animals were experimentally infected with *Nocardia asteroides*.

The reaction of the skin was of the delayed type, similar to those observed in tuberculin reactions. The same antigen,

when used as a complement fixing antigen, had no anti-complementary effects, and was specific when tested with sera from both experimentally infected guinea pigs and dogs.

A heat-killed antigen was prepared from Nocardia asteroides. Its potency, when used as a skin antigen, was somewhat inferior to that prepared by freezing and thawing. The heat-killed antigen, when used as a complement fixing antigen, was not anti-complementary. The results obtained in the Complement Fixation Test, using the sera of infected guinea pigs and dogs with Nocardia asteroides, were inconsistently positive.

In the experiments with guinea pigs, it was observed that Nocardia asteroides did sensitize these animals to avian and mammalian tuberculin. However, the experiments with dogs showed that the response of the infected animals was not constant.

The experiments with tuberculous guinea pigs showed that human tubercle bacilli may sensitize the animals to either the frozen-thawed antigen or the heat-killed antigen derived from Nocardia asteroides. These observations differ from the observations of Drake and Henrici (11) who observed that the protein extract and polysaccharide extract from Nocardia asteroides did not cause reactions in tuberculous guinea pigs.

## SUMMARY AND CONCLUSIONS

This study describes the possibility of using the skin test and the complement fixation test in the diagnosis of Nocardiosis in dogs.

A frozen-thawed antigen, a heat-killed antigen, a phenol antigen, an acid-alcohol extract, and an absolute alcohol extract antigen were prepared from Nocardia asteroides.

The frozen-thawed and the heat-killed antigens were used in the skin test. The frozen-thawed antigens gave the best results, while the heat-killed antigen gave fair results in infected dogs and guinea pigs.

The reactions obtained were of the tuberculin type.

In guinea pigs, the test was considered positive when erythema and edema measured 1 cm or more in diameter 48 hours after the introduction of the antigen.

In dogs, the test was considered positive when there was a difference of 3 mm or more between the 48-hour reading and the initial reading of the thickness of the skin at the site of inoculation.

Tuberculous guinea pigs reacted doubtfully to the frozen-thawed and the heat-killed antigens.

In the complement fixation test, the frozen-thawed and the heat-killed antigens proved to be nonhemolytic and antigenic, while the other three antigens proved to be either anticomplementary or nonantigenic.



The frozen-thawed extract yielded a potent complement fixing antigen, while the heat-killed antigen yielded an unreliable one, with guinea pigs and dogs infected with Nocardia asteroides.

The reactions of sera from tuberculous guinea pigs were inconsistently positive with both the heat-killed and the frozen-thawed antigen.

## ACKNOWLEDGMENTS

Grateful acknowledgment is given to Dr. M. J. Twiehaus, Major Instructor and Head of the Department of Pathology, for his criticism and advice; to Professor V. D. Foltz, Professor of Bacteriology, who kindly contributed his time, suggestions, and supervision; and to Dr. Dean S. Folse, Professor of Pathology, for his help and advice. Their understanding, patience, and guidance are deeply appreciated.

## LITERATURE CITED

- (1) Awad, F. I.  
The intradermal sarcocystin test. Am. J. Vet. Res. 18:  
703-4. 1957.
- (2) \_\_\_\_\_.  
Inter-relationship between tuberculosis and bovine farcy.  
J. Comp. Path. 68: 324-330. 1958.
- (3) Blake, W. P.  
Report of 2 canine cases of Nocardiosis. J. Am. Vet. Med.  
Assn. 125: 467-468. 1959.
- (4) Bohl, E. H., D. O. Jones, R. L. Farrell, D. M. Chamberlain,  
C. R. Cole, and L. C. Ferguson.  
Nocardiosis in the dog. J. Am. Vet. Med. Assn. 122: 81-85.  
1953.
- (5) Brodey, R. S., E. J. Cole, and Robert M. Sauer.  
Nocardial Mycetoma in dog. J. Am. Vet. Med. Assn. 127:  
433-34. 1955.
- (6) Carpenter, P. L.  
Immunology and serology, p. 86. Philadelphia: W. B.  
Saunders. 1956.
- (7) Coles, E. H.  
Personal communication.
- (8) Conant, N. P., and T. Rosebury.  
Bacterial and mycotic infections of man, pp. 576-586.  
New York: Lippincott. 1948.
- (9) Cross, R. F., and W. T. Nagao.  
Canine Nocardiosis. J. Am. Vet. Med. 123: 535-36. 1953.
- (10) Difco Manual.
- (11) Drake, C. H., and A. T. Henrici.  
Nocardia asteroides, its pathogenicity and allergic prop-  
erties. Amer. Rev. Tuberc. 48: 184-198. 1943.
- (12) Emmons, C. W., B. J. Olson, and W. W. Eldridge.  
Studies of the role of fungi in pulmonary diseases.  
Public Health Reports 60: 1383-1393. 1945.
- (13) Foltz, V. D.  
Personal communication.

- (14) Ginsberg, A. G., and A. C. W. Little.  
Actinomycosis in dogs. J. Path. Bact. 60: 563-572.  
1948.
- (15) Goyal, R. K.  
Immunological and microbiological studies of some  
Nocardia species. Ann. Inst. Past. 59: 94-128. 1937.
- (16) Henrici, A. T., and E. L. Gardner.  
Acid-fast actinomycetes. J. Infect. Dis. 28: 232.  
1921.
- (17) Johnson, K. G.  
Systemic Nocardiosis in the dog. J. Path. Bact. 71:  
7-14. 1956.
- (18) King, C. B., C. C. Sapp, Jr., and H. R. Seibold.  
Systemic Nocardiosis with bone lesions in a dog.  
Auburn Vet. 11: 115-117. 1955.
- (19) Kolmer, J., E. Spaulding, and H. Robinson.  
Approved laboratory technic, p. 638. New York: Apple-  
ton-Century-Crofts, Inc. 1957.
- (20) Neal, J. E., and M. K. Heath.  
Nocardiosis in dogs. Auburn Vet. 11: 115-117. 1955.
- (21) Riser, W. H.  
Canine medicine, p. 635. American Veterinary Publica-  
tions, Inc. 1959.
- (22) Roznowski, E. P., Jr., and V. D. Foltz.  
Flocculation tests for pullorum disease. Am. J. Vet.  
Res. 71: 478-482. 1958.
- (23) Sapegin, G., and G. R. Cormock.  
Canine Nocardiosis treated with hibitans. N. Amer. Vet.  
37: 385-388. 1956.
- (24) Serological tests for syphilis.  
Public Health Service. 1955.
- (25) Thordal-Christensen, A., and D. H. Clifford.  
Actinomycosis in a dog. Am. J. Vet. Res. 14: 298-306.  
1953.
- (26) Wilson, G. S., and A. A. Miles.  
Topley and Wilson's principles of bacteriology and  
immunology, p. 470. Baltimore: Williams & Wilkins,  
1959.

THE DIAGNOSIS OF NOCARDIOSIS IN DOGS  
BY THE SKIN TEST AND THE COMPLEMENT-FIXATION TEST

by

MOHAMED-TEWFIK FAWI ABDU

B.V.Sc., University of Khartoum (Sudan), 1957

---

AN ABSTRACT OF A THESIS

submitted in partial fulfillment of the

requirements for the degree

MASTER OF SCIENCE

Department of Pathology

KANSAS STATE UNIVERSITY  
OF AGRICULTURE AND APPLIED SCIENCE

1960

Dogs infected with Nocardiosis do not elicit specific signs of the disease. The animals infected are often tentatively diagnosed as either tuberculosis or distemper complex. Gross post-mortem lesions may sometimes simulate tuberculosis.

This study described the application of the skin test and the complement fixation test in the diagnosis of Nocardiosis in dogs. Guinea pigs and dogs were used in this study.

Sixteen guinea pigs were divided into four groups of four animals each. Three guinea pigs of each group were inoculated with Nocardia asteroides, while the fourth member of each group was kept as a control. Another five guinea pigs were used, four of which were inoculated subcutaneously with human tubercle bacilli while the fifth remained as a control.

A group of three seven-month-old mongrel dogs was used, two of which were inoculated intrathoracically with Nocardia asteroides and the third kept as a control.

The following five antigens were prepared from Nocardia asteroides:

1. A frozen-thawed antigen.
2. A heat-killed antigen.
3. A phenol extracted antigen.
4. An absolute alcohol extracted antigen.
5. An acid alcohol extracted antigen.

The frozen-thawed and the heat-killed antigens were used in the skin test in guinea pigs and dogs.

Twenty-four hours after the intradermal inoculation of the antigens, the infected guinea pigs showed an inflammatory erythema, edema, and induration at the sites of injections. The reaction appeared to attain its climax 48 hours after inoculation. By the fourth day the reaction began to subside and it disappeared within the week. The test was regarded positive when erythema and edema measured 1 cm or more in diameter, and negative when there was a slight erythema and a trace of edema measuring less than 0.5 cm in diameter at the end of 48 hours.

Guinea pigs infected with Nocardia asteroides reacted positively to both the frozen-thawed and the heat-killed antigens. The frozen-thawed antigen was superior to the heat-killed antigen.

The experiments with guinea pigs infected experimentally with Nocardia asteroides showed that they were sensitive either to the avian or the mammalian tuberculins or to both.

Meager and irregular responses were obtained when the frozen-thawed and the heat-killed antigens were injected intradermally in tuberculous guinea pigs.

Experimentally infected dogs were sensitized to dermal injections of the frozen-thawed and the heat-killed antigens. Twenty-four hours after the inoculation of the heat-killed and the frozen-thawed antigens, the infected dogs began to develop edematous erythematous swellings at the sites of the inoculations. The reactions attained their maximum by 48 hours. They began to subside by the fourth day after the injection, and disappeared within the week.

A test was considered positive when there was a difference of 3 mm or more between the 48-hour reading and the initial reading of the thickness of the skin at the site of the injection.

The frozen-thawed and the heat-killed antigens proved to be not anticomplementary and antigenic when they were used as complement fixing antigens, while the three other antigens extracted from Nocardia asteroides proved to be either anticomplementary or nonantigenic.

The frozen-thawed antigen yielded a potent complement fixing antigen, while the heat-killed antigen was unreliable. A 50 percent fixation using 0.25 cc of serum was regarded as a positive titer both in guinea pigs and dogs experimentally infected with Nocardia asteroides.

Inconsistent positive results were obtained when 0.25 cc of serum from tuberculous guinea pigs was used.