

SOME EFFECTS OF CORTISONE ON VITAMIN  
C-DEFICIENT GUINEA PIGS

by

BARBARA JANE WILSON

B. S., Kansas State Teachers College  
Emporia, Kansas, 1943

---

A THESIS

submitted in partial fulfillment of the

requirements for the degree

MASTER OF SCIENCE

Department of Zoology

KANSAS STATE COLLEGE  
OF AGRICULTURE AND APPLIED SCIENCE

1951

Q 12-17-51/4

Docu-  
ments  
LO  
2668  
T4  
1951  
W58  
c.2

TABLE OF CONTENTS

INTRODUCTION AND REVIEW OF LITERATURE	. . . . .	1
MATERIALS AND METHODS	. . . . .	4
EXPERIMENTAL RESULTS	. . . . .	8
DISCUSSION	. . . . .	16
SUMMARY	. . . . .	20
ACKNOWLEDGEMENT	. . . . .	22
LITERATURE CITED	. . . . .	23

## INTRODUCTION AND REVIEW OF LITERATURE

For many years biologists and chemists have studied the effects of vitamin deficiencies upon the tissues of animals in an attempt to establish relationships between hormones and vitamins. Harman and Miller (1939) found that guinea pigs have the best chance for normal growth and good physiological conditions if vitamin C is supplied liberally and regularly, that the degree of resistance to an attack of scurvy is an individual factor, and that although there is a chance for recovery from a pronounced case of scurvy in some animals there is a greater chance for death. Results of experiments of Dann and Cowgill (1935) indicate that the vitamin C requirement of the guinea pig is directly proportional to the body weight. There is no evidence from their work which would indicate that young, rapidly growing guinea pigs require a proportionately greater amount of this dietary factor than the adult.

Meer and McCormick (1928) report that scorbutic pigs show loss of weight, decreasing activity and drowsiness or in other guinea pigs marked nervousness and greatly heightened activity. In later stages, stiffness, weakness, and even complete helplessness may supervene in the hind quarters, especially of young animals.

Harman, Kramer and Kirgis (1938) found that in guinea pigs ranging in age from 1 day to 3 years placed on diets of

varying amounts of vitamin C there was resorption of bone at the bases of the cheek teeth and along the edge of the alveolar area. This occurred without respect to the age of the animal. Fish and Harris (1934) had previously reported that no apparent morphological change took place in hard tissues already formed.

Meer and McCormick (1928) report that in scorbutic guinea pigs degenerative changes were encountered in the costal cartilages and bone marrow and that the picture was one of destruction. The earliest worker to investigate experimentally the effect of scurvy on the regeneration of bone was Shinya in 1922 (Bourne, 1942) who showed that a graft of bone from a scorbutic to a normal guinea pig would not 'take' and that conversely the transplantation of a sound bone into a scorbutic animal was ineffective. Ferraris and Lewi, 1923; Hertz, 1936; Israel and Frankel, 1926; Hanke, 1935; Lexer, 1939 (Bourne, 1942) found delay in healing of fractures in scorbutic pigs. Howe (1922) has shown in his experiments with guinea pigs kept in a latent scorbutic acid condition for some time that the femur and tibia decalcify extensively and during dissection pull apart at the epiphyseal line. In addition, Howe has found that when these animals are fed a diet adequate in vitamin C that calcification occurs. He reports large areas of newly forming bone were found on the jaws and leg bones. He further found that the cartilage may calcify with ankylosis following.

A few workers have studied the effects of cortisone upon normal guinea pig bones, but no references could be found in

the literature with regard to the effect of cortisone upon C-deficient or C-free bone. Winter, Silber, and Stoerk (1950) examined sections of ribs and of tibia of animals receiving prolonged administration of cortisone and found striking reduction in the width of the epiphyseal cartilage, but no appreciable rarification of cortical or cancellous bone. Williams and Watson (1941) report that cortisone tends to decrease the amount of phosphatase in bone.

Studies have been made of the effects of vitamin C-deficiency upon the suprarenal glands of guinea pigs. McGarrison (Hoerr, 1931) reported that experimental scurvy caused an increase in size and weight of the adrenals, diminution of the epinephrine content, hemorrhagic infiltration and degenerative changes including vacuolation and disintegration of cells and loss of staining reactions of a portion of the nuclei. Iwabuchi (Hoerr, 1931) studied the effects of scurvy upon the cortex of the adrenal glands. He found that the outer and inner thirds of the zona fasciculata became very rich in lipid content, but that the middle third was almost lipid-free. The zona fasciculata showed degenerating cells, with swollen cell bodies and pyknotic nuclei. Iwabuchi also reported degeneration in the zona reticularis. The most marked changes were in increased lipid content; all the cells from the zona glomerulosa to the reticularis were quite fatty. Deane and Morse (1948) claimed, on the basis of histochemical evidence, that the cells of the cortex lose the power to secrete their steroids when vitamin C is

not present.

Woodbury and Sayers (Ingle, 1950) have demonstrated that cortisone acetate will cause a marked reduction in weight and in the concentration of ascorbic acid in the suprarenal cortex of the rat. Stebbins (1950) found that a dose of 3 mg per day caused atrophy of the inner zones of the cortex and depletion of the lipoid and ketosteroid material in these zones, but that the zona glomerulosa remained unchanged. Many investigators (Winter, Sieber and Stoerk, 1951; Antopol, 1950; Stebbins, 1950) report a return to normal of the cortex upon withdrawal of the injections of cortisone.

There is increasing evidence to indicate that a relationship exists between vitamin C and the recently isolated adrenal cortex hormone, 17-hydroxy-11-dehydrocorticosterone (cortisone). Since there is little in the literature concerning this relationship, the present study was undertaken to investigate the effects of cortisone upon the longevity, suprarenal glands, and bones and joints of vitamin C-deficient guinea pigs.

#### MATERIALS AND METHODS

This experiment was begun in October, 1950 and continued through July, 1951. All the work was done in the laboratories of the Departments of Zoology and Chemistry of Kansas State College, Manhattan, Kansas. The experimental animals used were twenty sexually mature male guinea pigs obtained from



the Gopher State Caviary of St. Paul, Minnesota. The average weight of the guinea pigs was 282 grams. Three guinea pigs were placed in each cage and kept at a temperature ranging from 68° to 73° Fahrenheit. All animals were weighed to the nearest gram before the experiment began, at regular intervals during the experiment, and again at the conclusion of the work. The animals were divided into three major groups for study.

The first group of eight guinea pigs was placed on a vitamin C-free diet. The diet contained the following ingredients: hulled oats, 75 pounds; soy bean meal, 25 pounds; Lederle Lortifeed supplement, 1/2 pound; APF which contained 2.5 grams of vitamin B<sub>12</sub> per pound, 1/4 pound; vitamin A, 56,000 IU; vitamin D, at least 1 1/2 times the amount for minimum maintenance. The feed was mixed as the basal ration in a large mixer for thirty minutes. It was then divided into four lots of approximately 25 pounds each and the proper supplements added. Then each lot was mixed again for at least thirty minutes and placed in tightly covered containers for storage until use. The guinea pigs were also given alfalfa pellets at the rate of six per pig per day. The pellets were heated and dried to destroy any possible vitamin C content.

The second group consisting of six guinea pigs was placed on an identical diet on October 20th. Five days later subcutaneous injections of 5 mg of cortisone acetate (Cortone) supplied by Merck and Company, Incorporated, Rahway, New Jersey, was given to each pig daily until it died or was killed. The third group of six pigs was placed on the C-free diet

plus an adequate amount of vitamin C. In addition, three drops of 10 mg/ml solution of ascorbic acid was administered orally every other day.

The animals of Group I died or were killed within twenty days (with one exception) after beginning the C-free diet. Those that were moribund were killed. Three of the guinea pigs of group two were killed when the number of days they were on the vitamin C-free diet corresponded to survival time of the scorbutic controls. The other animals in this group were kept as long as possible in order to obtain data on the length of survival of cortisone treated animals. The guinea pigs of Group III were killed at times which corresponded to the survival time of the C-free guinea pigs and to the survival time of the cortisone treated guinea pigs.

Each guinea pig was opened as soon after its death as possible. The adrenal glands, vertebro-chondral ribs, heel and toe joints were removed. The tissues were placed in Bouin's picro-formol fixing fluid. After approximately twenty-four hours the fixing solution was removed with two washings of 70% alcohol. The isopropyl alcohol method of Dextader was used for the paraffin infiltration. The method was as follows: 60% isopropyl alcohol for one hour, 99% isopropyl alcohol for one hour; 99% isopropyl alcohol for two hours; 99% isopropyl alcohol for three hours and kept at a temperature of 40-45° C.; melted Tissuemat (melting point of 50-52° C.) for one hour; melted Tissuemat (melting point of 50-52° C.) overnight; Tissue mat (melting point of



54-56° C.) for embedding and blocking. The adrenals were sectioned at six microns.

The bones were placed in a solution consisting of 95% water and 5% concentrated nitric acid for a period of twelve to twenty hours. The time was dependent upon the amount of calcification of the bone as indicated by the degree of difficulty of cutting the bone with a sharp knife. It was not necessary to decalcify the vitamin C-free bone for longer than twelve hours in any instance. Each bone and a small piece of paper containing the number of the guinea pig were placed in a short glass tube of 20 mm bore. The ends of the tubes were covered with cheese cloth to allow for circulation of running tap water into which the tubes were placed for a period of forty-eight hours to wash the bones free of acid. The bones were then subjected to the same method of infiltrating and embedding as were the adrenal glands. They were sectioned at 8-12 microns.

The sections of adrenal glands and of bone were stained with haematoxylin and counter stained with eosin by use of the following method:

Remove paraffin with xylol	5 minutes
Place in xylol	5 minutes
Place in absolute alcohol	1 - 2 minutes
Place in 95% alcohol	"
Place in 85% alcohol	"
Place in 70% alcohol	"
Place in 50% alcohol	"

Place in 35% alcohol	1 - 2 minutes
Place in distilled water	5 minutes
Stain in haematoxylin	2 minutes
Rinse in tap water until dark blue	
Destain in 2% solution of HCl in water	
Rinse in tap water until dark blue	
Rinse in distilled water	
Place in 35% alcohol	1 - 2 minutes
Place in 50% alcohol	"
Counter stain in eosin until cytoplasm is pink	
Rinse in 95% alcohol	1 - 2 minutes
Place again in 95% alcohol	"
Place in absolute alcohol	"
Rinse in carbol xylol	2 minutes
Place in xylol	5 minutes

The sections were mounted in Piccolite, covered with number one cover slips and allowed to dry. The sections were examined under low power, high power and oil immersion of a compound microscope.

#### EXPERIMENTAL RESULTS

All the Group I or C-deficient guinea pigs showed symptoms of scurvy after seven days on the C-free diet. All exhibited pain about the joints after eleven days on the diet and all but one were dead within twenty day. The animals showed

extremes of 12 to 19 days of life with an average of 16.2 days. The average body weight at the beginning of the C-free diet was 303 grams. The average weight at the time of death was 218 grams.

All the Group II or cortisone-treated guinea pigs lived a longer period of time except number 20 which survived seventeen days and number 22 which survived nineteen days. Number 19 was killed on the twenty-sixth day, number 21 survived 37 days, number 23 survived 43 days, and number 24 survived forty-five days. The guinea pigs showed extremes of 17 to 45 days of life with an average of 31.1 days. The guinea pigs of this group with the longest survival record gained weight for twenty-three days then rapidly lost until their average weight at the time of death was 294 grams.

All the guinea pigs of Group III or the control group (scorbutic diet with adequate vitamin C) remained in good health during the entire period of time. These animals weighed an average of 324 grams at the beginning of the experiment and an average of 336 grams at post mortem. They were killed at the various times indicated on Table 3.

The histological studies of the adrenal glands of the control or Group III guinea pigs revealed the information which follows. Zona glomerulosa: this zone contains small columnar cells arranged in oval groups and in arcs which cap the cell cords of the zona fasciculata. The nuclei are deeply stained and the cytoplasm is scanty. Many lipoidal vacuoles three to four times larger than the nuclei can be seen. Numerous

Table 1. Record of the body weights at the beginning and end of the experiment, maximum weights, and survival times of experimental animals on a vitamin C-free diet (Group I).

Animal number	Body weight in grams			Survival time in days
	Beginning	Maximum	Death	
13	365	365	235	15
14	285	285	225	19
15	245	245	185	19
16	280	280	188	29
17	245	245	196	16
18	225	225	188	15
37	405	405	280	18
38	375	375	250	19
Average	303	303	218	19

Table 2. Record of the body weights at the beginning and end of the experiment, maximum weights, and survival times of scorbutic cortisone-treated guinea pigs (Group II).

Animal number	Body weight in grams			Survival time in days
	Beginning	Maximum	Death	
19	280	365	365	26
20	250	294	291	17
21	245	306	206	37
22	325	386	386	19
23	285	380	261	43
24	235	377	252	45
Average	270	351	294	31

Table 3. Record of the body weights at the beginning and end of the experiment, maximum weights, and survival times of the control guinea pigs (Group III).

Animal number	Body weight in grams			Survival time in days
	Beginning	Maximum	Death	
31	315	315	478	45
32	270	305	280	26
33	305	371	367	29
34	246	367	367	26
35	265	330	310	45
36	240	245	216	29
Average	273	322	336	33

smaller lipoidal vacuoles are in evidence in most of the cells. The vacuoles show much variation in size, but within each individual cell they are of about equal size.

*Zona fasciculata*: this zone contains larger, many sided cells. Each cell appears highly vacuolated so that little cytoplasm is in evidence. The nuclei are centrally placed in each cell. Frequently one cell may contain two nuclei. The cells are arranged in cord-like strands separated by collapsed blood sinuses. The lipoidal content is greatest toward the outer part of the *zona fasciculata*.

*Zona reticularis*: this area consists of light and dark cells. The light cells are larger, more rounded and contain granular pale staining cytoplasm. The dark cells are smaller, stain more deeply and contain smaller shrunken nuclei. No large vacuoles are in evidence in this area (Plate II, Fig. 1).

The histological studies of the Group I or C-deficient adrenal glands show the following. *Zona glomerulosa*: this region contains large cells with greatly enlarged nuclei and many deeply staining cytoplasmic granules. One slide (animal 17) shows nuclei of many different sizes, however, for the most part they are larger than those of the control group. The nuclei of the glands of slide 16 exhibit many different shapes. Many lipoidal vacuoles are present in all slides of this group. The vacuoles of the *zona glomerulosa* vary in size from vacuoles much smaller than the nuclei to vacuoles nearly twice as large, but for the most part the lipoidal vacuoles are approximately



the same size as the nuclei. Slide 38 shows few vacuoles, and none is larger than the nuclei. Slide 17 shows evidence of cell disintegration.

*Zona fasciculata:* the nuclei of this area are large and filled with deeply staining granules. Only a few lipoidal vacuoles can be seen in this zone and for the most part they are smaller than the nuclei. Slides 16 and 18 contain a few vacuoles slightly larger than the nuclei. Slides 13 and 17 show several mitotic figures between the zona fasciculata and zona glomerulosa. Slides 14, 16, and 17 show evidence of disintegrating cells.

*Zona reticularis:* the nuclei are more enlarged than those of the corresponding zone in the normal guinea pigs, but are smaller than the nuclei of the outer two zones within this group. Lipoidal vacuolation is more marked than in the zona fasciculata but less marked than in the zona glomerulosa. The cells of this region of slide 37 show marked evidence of disintegration (Plate I, Fig. 1).

The results of the histological study of this group may be summarized by stating that the cells and nuclei are greatly enlarged, the number of lipoidal vacuoles and the number of mitotic figures has increased, and disintegration is evident in many cases. In addition, it was clear to the unaided eye that the adrenal glands of the vitamin C-deficient guinea pigs were considerable hypertrophied.

The histological studies of the suprarenal glands of the scorbutic cortisone treated guinea pigs show the following.

*Zona glomerulosa*: the cells and nuclei appear smaller than in either of the two previous groups. The cells are extremely shrunken in appearance. Few cytoplasmic granules can be seen. There are no large lipoidal vacuoles in any of the sections. Slides 20 and 22 contain the largest vacuoles of the group. It can be seen from the table that these guinea pigs received cortisone for the shortest period of time. Number 20 received cortisone for 17 days and number 22 received the hormone for 19 days as opposed to much longer periods for the other animals of this group.

*Zona fasciculata*: the cells and nuclei are small with well defined cell walls. Some very small lipoidal vacuoles are present.

*Zona reticularis*: more variation in size of cells occurs in this zone than in any other zone of this group. Slide 22 shows the largest nuclei of the group (which are smaller than those of any other group) and slide 23 shows extreme variation in the sizes of the nuclei of this zone (Plate I, Fig. 2).

The results of the histological study of this group may be summarized by stating that the cells and nuclei are small, shrunken, and deeply stained. The slides show few cytoplasmic granules and little evidence of vacuolation.

Longitudinal sections through the vertebro-chondral ribs of the Group III or control guinea pigs showed the following histological findings. These sections show the typical calcification of cartilage matrix. The zone of reserve cartilage and the zone of cell and lacunar hypertrophy are

strikingly similar in the three groups. However, the zone of calcification of cartilage matrix and the zone of disintegration and ossification show striking differences. This group of ribs shows the presence of well defined endochondrial as well as perichondrial bone (Plate III, Fig. 2).

Slides of Group I or C-deficient guinea pig ribs show the zone of reserve cartilage and the zone of cell and lacunar hypertrophy, but the zones of calcification of cartilage matrix and the zone of disintegration are poorly developed. Little bone exists other than of the perichondrial type. The picture is one of bone destruction (Plate II, Fig. 2).

Slides of Group II or cortisone-treated scorbutic guinea pig ribs show a condition of bone development inferior to that of the normal bone, but highly superior to that of the C-deficient bone. Several centers of ossification are present and both endochondrial and perichondrial bone can be seen (Plate III, Fig. 1).

Typical slides of sections through the heel joints of each group of guinea pigs reveal the following. Group III or controls: these slides show areas of well developed endochondrial and perichondrial bone. No evidence of break down of the bone can be seen.

Group I or vitamin C-deficient guinea pigs: these slides show break down of the bone. There is no evidence of formation of endochondrial bone. A few regions of perichondrial bone can be seen.

Group II or scorbutic cortisone-treated: these slides show bone formation similar to that of the control group. Both endochondrial and perichondrial bone can be seen.

#### DISCUSSION

This study confirms the previous work of Hyman, Ragan, and Turner (1950) and Schaffenburg, Masson, and Corcoran (Hyman, Ragan, Turner, 1950) that the administration of cortisone moderates the course of scurvy in the guinea pig. This is indicated by increased duration of life, decreased loss of body weight and delay in onset of overt symptoms of scurvy in animals that received cortisone.

The histological studies of the suprarenal glands of the scorbutic guinea pigs are in complete agreement with Hoerr (1931), Meer and McCormick (1928), and Morikawa (1920) who have reported that experimental scurvy caused in the adrenal glands an increase in size as indicated by the increase in size of the cells; degenerative changes, including vacuolation and disintegration of cells; and an increase in the lipid content particularly in the outer and inner thirds of the zona fasciculata. Iwabuchi (1922) observed many mitotic figures. The present study serves to confirm the presence of an increased number of mitotic figures at the junction of the zona glomerulosa and the zona fasciculata. Ingle, Higgins, and Kendall (1938); Winter, Silber, and Stoerk (1950); and

Stebbins (1950) showed that daily subcutaneous administration of cortisone acetate in the rat produced marked atrophy of the inner zones of the adrenal cortex, while the glomerulosa remained intact. Ingle, Higgins, and Kendall (1938) and Winter, Silber, and Stoerk (1950) found an almost complete loss of lipid from the cells of the fascicular and reticular zones, but the cells of the glomerulosa remained practically unaltered. In the present problem no study was made of the effects of cortisone on the suprarenal glands of guinea pigs on an ascorbutic diet, but the effects of cortisone on the suprarenal glands of scorbutic guinea pigs show results similar to those found in the studies of ascorbutic guinea pigs. The glands of the cortisone treated group revealed small cells with few granules and dark shrunken nuclei. This is in accord with the work of Hyman, Ragan, and Turner (1950). The effect of the cortisone is not only great enough to bring about reduction in cell and nuclei size of the hypertrophied scorbutic adrenal, but is great enough to bring about, in addition, considerable atrophy as can be noted from the entire group of slides of the cortisone-treated adrenal glands.

Winter, Silber, and Stoerk (1950) found that the histological changes produced in the adrenal glands of rats by the cortisone injections were essentially the same in their animals observed after 10 days of treatment as in those observed after 6 weeks of injections. The present experiment shows the same histological changes for cortisone-treated scorbutic guinea pigs from 17 days of injections to 6 weeks of injections.

The histological and gross studies of the vitamin C-free guinea pig ribs and heel joints are in complete agreement with studies of bones reported by Harman, Kramer, and Kirgis (1938); Howe (1922); Zilva and Wells (1919); and Dann and Cowgill (1935) who report degenerative, crumbly, soft bones typical of almost complete decalcification. The present experiment shows almost complete lack of endochondrial bone. Typical gross bone changes in scurvy are loosening of the attachment of the periosteum from the bone, prevalence of subperiosteal haemorrhages which often extend considerable distances along the shafts of the bones, and a general osteoporotic condition.

The histological studies of the bones of the scorbutic cortisone-treated guinea pigs reveal the presence of well defined endochondrial and perichondrial bone. In each case the bone closely resembles the appearance of normal bone. It is interesting to note in this connection that according to Wolbach, Howe and Chuck (1929) scorbutus is characterized by the inability of the supporting tissues to produce and maintain intercellular substances. Their studies of the teeth, bone and connective tissues led them to advance the theory that the failure of cells to produce intercellular substances in scorbutus is due to the absence of an agent common to all supporting tissues which is responsible for the setting or jelling of a liquid product. It may be that cortisone is such a common agent.



It has been assumed by many investigators that ascorbic acid is necessary for, and is actually utilized in the production of the corticosteroids. Lowenstein and Zwemer (1946) report the isolation of an actual corticosteroid-ascorbate adrenal product. Schaffenburg (Hyman, Ragan, and Turner, 1950) reported the possibility that some of the mesenchymal alterations in scurvy were not due to a deficiency of vitamin C, but were due, rather, to hypo-secretion of cortisone-like steroids. The effects, then, of cortisone on the bones and adrenal glands of the scorbutic guinea pig might be explained as follows: the decreased activity of the adrenal cortex which follows cortisone administration is accompanied by decreased utilization of vitamin C which is no longer needed for the production of a cortisone-like steroid. This, then, would release an amount of vitamin C from the adrenal gland (where it is stored) so it could serve to prolong the life of an animal on a scorbutic diet.

It is clear that the relation between vitamin C and the secretions of the adrenal cortex remain undiscovered. Many investigators feel that the corticosteroids must influence the metabolism of ascorbic acid in many tissues and perhaps reduce the requirement of the organism for vitamin C (Lockwood and Hartman, 1933; Long, 1947; Hyman, Ragan and Turner, 1950).

## SUMMARY

An experiment was performed for the purpose of studying the effects of daily subcutaneous injections of 5 mg of cortisone upon scorbutic guinea pigs. The guinea pigs were divided into three groups as follows: Group I, which received a diet known to be vitamin C-free; Group II, which received the C-free diet plus daily injections of 5 mg of cortisone acetate; and Group III, which received the C-free diet plus an adequate amount of vitamin C. The weight and longevity records of the guinea pigs were recorded.

The suprarenal glands, heel joints, and vertebro-chondral ribs were removed and placed in Bouin's picro-formol fixing fluid immediately following the death of each guinea pig. The tissues were fixed, infiltrated, embedded, sectioned and stained. The sections were studied under both low and high powers of the microscope. Photomicrographs were taken of significant histological findings of typical sections of suprarenal glands, ribs, and heel joints of each group. The results of the experiment were as follows:

1. Scorbutic sexually mature male guinea pigs given subcutaneous injections of 5 mg of cortisone per day exhibited less loss of body weight than did the scorbutic noninjected guinea pigs.

2. Cortisone administered to scorbutic guinea pigs increased the longevity of the animals on an average of 31.1 days.

3. Adrenal glands of cortisone-treated scorbutic guinea pigs showed atrophied cells with dark shrunken nuclei, few cytoplasmic granules, and decreased lipoidal vacuolation.

4. The rib bones and heel joints of cortisone-treated vitamin C-deficient guinea pigs appear histologically similar to that of normal guinea pig bone.

5. The results of this experiment indicate a relationship between vitamin C and cortisone, but exactly what this relationship is remains undetermined.

## ACKNOWLEDGEMENT

Indebtedness is expressed to Dr. E. H. Herrick for the suggestion of this problem as well as for the many constructive criticisms given throughout the entire progress of this work.

## LITERATURE CITED

- Antopol, W.  
Anatomic changes produced in mice treated with excessive doses of cortisone. *Proc. Soc. Exper. Biol. and Med.* 73: 262-265. 1950.
- Bourne, G.  
The effect of graded doses of vitamin C upon regeneration of bone in guinea pigs on a scorbutic diet. *Jour. Physiol.* 101(3):327-336.
- Dann, M., and G. R. Cowgill.  
The vitamin C requirement of the guinea pig. *Jour. Nutr.* 9:507-519. 1935.
- Deane, H. W., and A. Morse.  
The cytological distribution of ascorbic acid in the adrenal cortex of the rat under normal and experimental conditions. *Anat. Rec.* 100(1):127-141. 1948.
- Fish, W. E., and L. J. Harris.  
The effects of vitamin C-deficiency on tooth structure in guinea pigs. *Royal Soc., London, Phil. Trans., ser. B*, 223:489-510. 1934.
- Harman, Mary T., M. M. Kramer, and H. D. Kirgis.  
Lack of vitamin C in the diet and its effect on the jaw bones of guinea pigs. *Jour. Nutr.* 15:277-283. 1937.
- Harman, Mary T., and Abbie Miller.  
Some effects on guinea pigs of feeding vitamin C intermittently. *Trans. Kans. Acad. Sci.* 42:445-449. 1939.
- Hoerr, N.  
The cells of the suprarenal cortex in the guinea-pig. Their reaction to injury and their replacement. *Amer. Jour. Anat.* 48:139. 1931.
- Hyman, George A., Charles Ragan, and Joseph C. Turner.  
Effect of cortisone and adrenocorticotrophic hormone (ACTH) on experimental scurvy in the guinea pig. *Proc. Soc. Exper. Biol. and Med.* 75:470-475. 1950.
- Ingle, D. J.  
The effects of administering large amounts of cortin on the adrenal cortices of normal and hypophysectomized rats. *Amer. Jour. Physiol.* 124:369-371. 1930.

- Ingle, D. J.  
The biologic properties of cortisone: a review. Jour. of Endocrinol. 10(10):1312-1354. 1950.
- Ingle, D. J., G. M. Higgins, E. C. Kendall.  
Atrophy of the adrenal cortex in the rat produced by administration of large amounts of cortin. Anat. Rec. 71:363-379. 1938.
- Lockwood, Julia E., and Frank A. Hartman.  
Relation of the adrenal cortex to vitamins A, B, and C. Endocrinol. 17:501-521. 1933.
- Long, E. N. H.  
Production of corticosteroids in the absence of vitamin C. Fed. Proc. 6:461-471. 1947.
- Lowenstein, B. E., and R. L. Zwemer.  
The isolation of a new active steroid from the adrenal cortex. Endocrinol. (abstract). 39(1):63-64. 1946.
- Meer, A. W., and L. M. McCormick.  
Experimental scurvy in the guinea pig. Proc. Soc. Exp. Biol. and Med. 25:494-496. 1928.
- Morikawa, Y.  
Adrenal changes in experimental scurvy. Endocrinol. (abstract). 4:615. 1920.
- Stebbins, R. B.  
Cytochemical changes in the adrenal cortex of the rat following the administration of cortisone. Fed. Proc. 9:345. 1950.
- Williams, H. L., and E. M. Watson.  
Influence of hormones upon phosphatase content of rat femurs. I. Effect of adrenal cortical substances and parathyroid extract. Endocrinol. 29:250-257. 1941.
- Winter, C. A., R. H. Silber, and H. C. Stoerk.  
Production of reversible hyperadrenocortinism in rats by prolonged administration of cortisone. Endocrinol. 47(1): 60-72. 1950.
- Wolbach, S. B., P. R. Howe, and C. F. Chuck.  
The pathology of vitamin deficiencies. Amer. Jour. Phys. 90:560. 1929.
- Zilva, S. S., and F. M. Wells.  
Changes in the teeth of the guinea pig produced by scorbutic diet. Proc. Royal Soc., London, ser. B, 90:505. 1919.



EXPLANATION OF PLATE I

Fig. 1. Section cut through the adrenal gland of a guinea pig on a vitamin C-free diet, showing enlarged cells with enlarged nuclei, large lipoidal vacuoles, and evidences of disintegration.

Fig. 2. Section cut through the adrenal gland of a scorbutic cortisone-treated guinea pig, showing small, shrunken cells and nuclei, and few lipoidal vacuoles.

## PLATE I

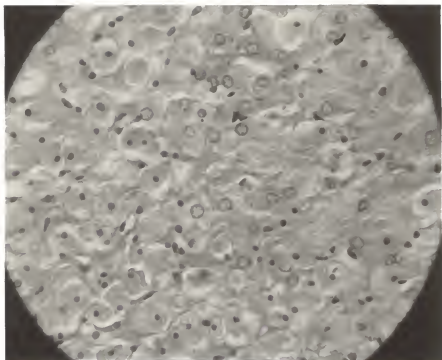


Fig. 1

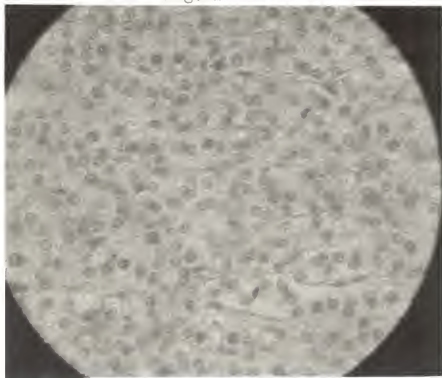


Fig. 2

EXPLANATION OF PLATE II

Fig. 1. Section cut through the adrenal gland of a guinea pig on a normal diet, showing usual size of cells and nuclei, and presence of lipoidal vacuoles.

Fig. 2. Section cut through a vertebro-chondral rib of a guinea pig on a vitamin C-free diet, showing little endochondrial and perichondrial bone.

## PLATE II




FIG. 1

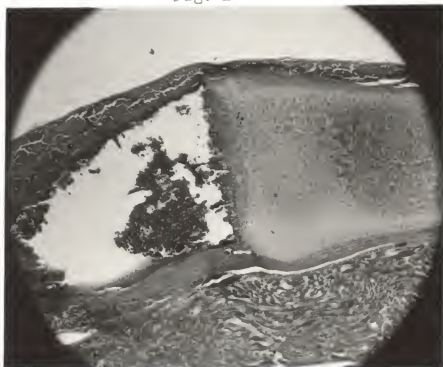


FIG. 2

### EXPLANATION OF PLATE III

Fig. 1. Section cut through a vertebro-chondral rib of a scorbutic cortisone-treated guinea pig, showing a condition of bone maintenance inferior to that of normal bone, but superior to that of vitamin C-deficient bone.

Fig. 2. Section cut through a vertebro-chondral rib of a guinea pig on a normal diet, showing the presence of well developed perichondrial and endochondrial bone.

## PLATE III

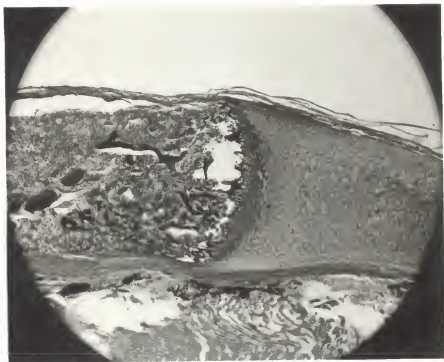


Fig. 1

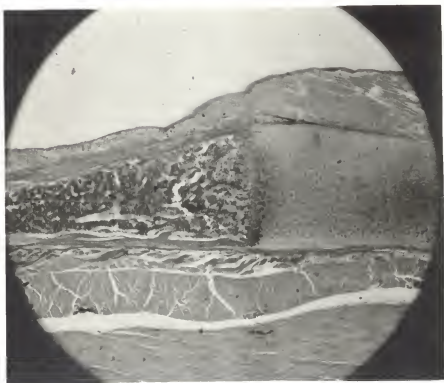


Fig. 2



SOME EFFECTS OF CORTISONE ON VITAMIN  
C-DEFICIENT GUINEA PIGS

by

BARBARA JANE WILSON

B. S., Kansas State Teachers College  
Emporia, Kansas, 1943

---

AN ABSTRACT OF A THESIS

submitted in partial fulfillment of the

requirements for the degree

MASTER OF SCIENCE

Department of Zoology

KANSAS STATE COLLEGE  
OF AGRICULTURE AND APPLIED SCIENCE

1951

The purpose of the study presented in this thesis was to investigate the effects of 17-hydroxy-11-dehydrocorticosterone (cortisone) upon the longevity, suprarenal glands, and bones and joints of vitamin C-deficient guinea pigs.

The experimental animals used were twenty sexually mature male guinea pigs obtained from the Gopher State Caviary of St. Paul, Minnesota. All animals were weighed to the nearest gram before the experiment began, at regular intervals during the experiment, and again at the conclusion of the work. The animals were divided into three major groups for study.

The first group of eight guinea pigs was placed on a vitamin C-free diet. The second group consisting of six animals was placed on an identical diet, but five days later subcutaneous injections of 5 mg of cortisone acetate (Cortone) were given to each animal daily until it died or was killed. The third group of six guinea pigs was placed on the vitamin C-free diet plus an adequate amount of vitamin C.

Each guinea pig was opened as soon after its death as possible. The suprarenal glands, vertebro-chondral ribs, heel and toe joints were removed. The tissues were placed in Bouin's picro-formol fixing fluid, washed, infiltrated, mounted, sectioned, and then stained with haematoxylin and eosin. The sections were examined under low power, high power, and oil immersion of a compound microscope. Photomicrographs were made of sections of representative tissues that were studied.

Sexually mature male guinea pigs that were kept on the C-free

all showed symptoms of scurvy after seven days. All the animals exhibited pain about the joints after eleven days on the diet and all but one were dead within twenty days. The average weight of these animals at the beginning of the experiment was 303 grams and at the time of death it was 218 grams. The guinea pigs that were deprived of vitamin C but given five milligrams of cortisone daily exhibited less loss in body weight. Their average weight at the time of death was 294 grams (Table 1, 2 and 3).

The guinea pigs on the vitamin C-free diet showed extremes of 12 to 19 days of life with an average of 16.2 days (excluding number 16 who received special treatment), while the scorbutic cortisone-treated animals showed extremes of 17 to 45 days of life with an average of 31.1 days. All of the guinea pigs on the scorbutic diet with adequate vitamin C (Group III) remained in good health during the entire period of time.

The suprarenal glands of the guinea pigs on the vitamin C-free diet were hypertrophied. The cells and nuclei were greatly enlarged. The lipoidal vacuoles were larger than the nuclei in many cases, and there was evidence of cellular disintegration. The suprarenal glands of the scorbutic cortisone-treated animals were atrophied. The cells and nuclei were small and many were shrunken. The few lipoidal vacuoles present were extremely small.

The bones of the animals on the vitamin C-free diet have zones of calcification of cartilage matrix and zones of

Table 1. Record of the body weights at the beginning and end of the experiment, maximum weights, and survival times of experimental animals on a vitamin C-free diet (Group I).

Animal number	Body weight in grams			Survival time in days
	Beginning	Maximum	Death	
13	365	365	235	15
14	285	285	225	19
15	245	245	185	19
16	280	280	188	29
17	245	245	196	16
18	225	225	188	15
37	405	405	280	18
38	375	375	250	19
Average	303	303	218	19

Table 2. Record of the body weights at the beginning and end of the experiment, maximum weights, and survival times of scorbutic cortisone-treated guinea pigs (Group II).

Animal number	Body weight in grams			Survival time in days
	Beginning	Maximum	Death	
19	280	365	365	26
20	250	294	291	17
21	245	306	206	37
22	325	386	306	19
23	285	380	261	43
24	235	377	252	45
Average	270	351	294	31

Table 3. Record of the body weights at the beginning and end of the experiment, maximum weights, and survival times of the control guinea pigs (Group III).

Animal number	Body weight in grams			Survival time in days
	Beginning	Maximum	Death	
31	315	315	478	45
32	270	305	280	26
33	305	371	367	29
34	246	367	367	26
35	265	330	310	45
36	240	245	216	29
Average	273	322	336	33

disintegration poorly developed. Little bone exists other than of the perichondrial type. The bones of the scorbutic cortisone-treated animals show a condition of bone maintenance inferior to that of the normal bone, but highly superior to that of the C-deficient bone. The sections through the vertebro-chondral ribs and through the heel joints showed similar conditions.

#### SUMMARY

1. Scorbutic sexually mature male guinea pigs given subcutaneous injections of 5 mg of cortisone per day exhibited less loss of body weight than did the scorbutic noninjected guinea pigs.
2. Cortisone administered to scorbutic guinea pigs increased the longevity of the animals on an average of 31.1 days.
3. Adrenal glands of cortisone treated scorbutic guinea pigs showed atrophied cells with dark shrunken nuclei, few cytoplasmic granules, and decreased lipoidal vacuolation.
4. The rib bones and heel joints of cortisone treated vitamin C-deficient guinea pigs appear histologically similar to that of normal guinea pig bone.
5. The results of this experiment indicate a relationship between vitamin C and cortisone, but exactly what this relationship is remains undetermined.