

PLACENTATION IN THE DOG

by

DEMOSTENE ROMANUCCI

B. S., Ohio University, 1948

A THESIS

submitted in partial fulfillment of the

requirements for the degree

MASTER OF SCIENCE

Department of Zoology

KANSAS STATE COLLEGE
OF AGRICULTURE AND APPLIED SCIENCE

1951

Docu-
ments
LD
2668
T4
1951
R66
c2

TABLE OF CONTENTS

INTRODUCTION	1
MATERIALS AND METHODS	2
RESULTS	3
Uterine Glands	4
Chorionic Villi	7
Blood Supply of the Placenta	9
Development of Placental Form	12
DISCUSSION	13
SUMMARY	17
ACKNOWLEDGMENTS	19
REFERENCES	20
APPENDIX A	21
Measurements Concerning Placentae Used	21
APPENDIX B	22

INTRODUCTION

Although work on canid placentation was done by Duval (1893), Bonnet (1897), Fleischmann (1893), Henricius (1889), and Strahl (1890) during the last century, a full comprehension of placentation in the carnivores and particularly in the Canidae has not been established. Recent work on placentation has added nothing but confusion to the already muddled picture.

Mossman (1937) reviewed the literature on placentation in "Comparative Morphogenesis of the Fetal Membranes and Accessary Uterine Structures", and added observations of his own. In this review, descriptions of selected material, couched in moot phraseology, contributed little to the picture of placentation in Canidae. There appears to be considerable conflict between his statements and the material studied for this thesis.

Mossman's characterization of placentation in the Canidae, based mainly on the domestic dog, follows:

Implantation:

Orientation (disc): Antimesometrial to irregular

Orientation (first attachment): Antimesometrial to zonary

Depth: Superficial

Yolk-sac:

Bilaminar omphalopleure: Temporary

Chorio-vitelline placenta: Well developed for a short time

Vascular splanchnopleure: Medium sized collapsed, permanent, bilobed, or T shaped sac attached by a strand at each arm of the T to the chorion

Chorio-allantoic placenta:

Shape: Annular or zonary

Type: Labyrinthine

Finer morphology: Endotheliochorial

Accessory placentae: Marginal hematoma of a villous hemochorial character

Location: Zonary

Allantoic vesicle: Large and permanent

Authorities: Bonnet; Duval; Mossman, etc.

The present report deals specifically with placentation in the domestic dog from the beginning of chorionic villi to completion of formation of the placenta. It is hoped that some clarification of the problem can be resolved.

MATERIALS AND METHODS

Mongrel dogs were, for the most part, maintained in the laboratory and bred under observation. At desired times, the dogs were anesthetized, and the uterus or part of it was removed surgically. Tabulation of the dogs used and time of removal of the uterus are given in Appendix A. The tissues

were fixed either in Bouins solution or in 10 per cent formalin. Each uterine swelling was treated as a unit. The small swellings, up to 20 mm, were embedded in paraffin and sectioned serially. The larger swellings were dissected, and only portions of the area of attachment were sectioned.

Sections were stained in Harris' hematoxylin, with or without eosin counterstain.

Measurements of villous bands, decidua, chorionic vesicles, and embryos were made on fixed material, concurrent with dissection, supplemented with sectioned material when needed.

As the work on placentation was done as one phase of the project on dog reproduction, other parts of the study were available for correlations. Aging of the embryos under consideration were taken directly from another part of the study, so will not be described here. Corresponding stages of development of the embryo are likewise omitted.

RESULTS

The non-pregnant uterus of the dog at the end of estrus measures 7 or 8 mm in diameter and 130 to 200 mm in length. During the first two weeks after ovulation, the diameter of the uterus increases only about one millimeter and the length increases about 25 per cent, by increasing convolutions. At about 15 days after fertilization, each blastocyst has

enlarged enough to cause a local swelling that is barely perceptible. Within another day, the uterine swellings are measurably larger than the uterus between swellings, and continue to increase throughout pregnancy. The increase in length of uterine swellings is shown graphically in Plate I, A. Increase in diameter is of the same order but somewhat less rapid.

Uterine Glands

The layers of the dog uterus are similar to those of the human uterus. The endometrium consists of a spongy layer in which the uterine glands are convoluted, and a compact layer next to the lumen in which the uterine glands are straight tubules. At the time the embryo reaches the uterus (about 7 days after ovulation) swellings of the uterine glands in the compact layer first become apparent. These swellings are detectable only by microscopic examination of sectioned material, and are illustrated by the photomicrograph of the uterus of Dog No. 13 (Plate II, A). The uterine glands at this stage are in a secretory condition and presumably secrete the lymph-like fluid which surround the early embryo. This fluid becomes a smooth coagulum after fixation, shown between the chorion and uterine wall of Dog No. 16 (Plate II, B).

By the 17th or 18th day (Dog No. 16 and 42R, Plate II, B, C) the swellings of the uterine glands have become flask-shaped enlargements about 200 to 350 microns in length and 100 to 140 microns in width.

The openings of the uterine glands into the lumen of the uterus are rather irregularly spaced, ranging from 75 to 175 microns apart. Each opening appears as a definite pit in the uterine epithelium when viewed from the lumen side. Reconstructions from drawings of serial sections showed secondary labyrinths connected to the main enlargements, but not opening into the lumen of the uterus and not continuous with any deep gland. These lesser labyrinths were apparently formed from branches of the main tube concurrent with the beginning of swelling.

By 21 days (Dog 42L, Plate II, D) the swellings of the uterine glands have become labyrinthine in character, averaging 1.3 mm wide (parallel to the length of the uterus) and 0.4 mm long (perpendicular to the length of the uterus). In a slightly later stage (Dog 40R, Plate II, E), the labyrinths have increased to an average of 1.5 mm in width, with no appreciable change in length. No uteri were obtained in the range of 21 to 27 days. During this time, however, the placenta has increased in length much more rapidly than the uterine wall, stretching the partitions between labyrinths into long, thin septae directed always toward the terminal sinuses, resulting in extreme elongation of the labyrinth,

while the stretching of the uterine wall has resulted in a less drastic increase in width of each labyrinth (Dog 9, Plate III, A). Further enlargement is of the same nature, but less pronounced. The general trend of increase in size of labyrinths is shown graphically in Plate I, B.

In the next few days, the chorionic mass becomes completed by progressive destruction of the maternal pads and completion of the glandular layer over the labyrinth (Dog 9, Plate III, B); the final stage in this development being reached at about 35 days. For a time, 28 to 34 days, the layer of chorionic cells fronting the labyrinth is a fairly smooth, continuous layer. The cells of this layer are highly vesicular and seem always to be filled with secretion droplets. At about 42 days, this glandular layer begins to wrinkle and sends protrusions into the space of the labyrinth, one protrusion into each space (Dog 25, Plate III, E, F).

A short time after beginning of enlargement of the uterine glands, the uterine epithelium, under the influence of the embryo, is stimulated to increased mitosis, resulting in a rapid increase of the cells in the necks of the uterine glands, as well as the epithelium proper. The neck of each gland thus becomes longer, and produces numerous side branches (Dog 40, Plate II, D; Dog 42L, Plate II, E), increasing the mass of tissue between the labyrinth and the uterine lumen, as shown by the photomicrographs on Plate II, D, E, and Plate

III, A, B, C, and illustrated graphically by the solid line in Plate I, Fig. 2. During the early period of thickening of the endometrium and enlargement of the labyrinths, the uterine wall is being stretched rapidly, and as the number of uterine glands is not increasing, the actual distance between the openings of glands increases proportionately with the stretch of the uterine wall, and relatively more space is available for the branching of the necks of the uterine glands.

Chorionic Villi

The early blastocyst floats free within the uterine cavity until it becomes large enough to be wedged firmly against the uterine epithelium. Such size is reached at about 14 days after ovulation with the blastocyst about 2.5 to 3.0 mm in diameter. In Dog 16 (Plate II, B), the blastocyst was 4 mm in diameter and 5.4 mm long and was still held in place only by pressure against the mucosa. The chorion was smooth, and the uterine epithelium was intact, penetrated only by the openings of the uterine glands. Approximately one day later (Dog 42R, Plate II, D), pseudopodia-like processes appear at intervals over the surface of the trophoderm, corresponding with the openings of uterine glands. These processes occur in clusters four or five cells across, first as elongations of the single cell layer of the trophoderm, but soon become two or three cells thick in contrast to the

trophoderm between villi which remains for a time a single cell layer.

The elongated cells of the trophodermic villi appear, even on the 18 day embryo (Dog 42R, Plate II, C) to be secretory, and they rather quickly begin digestion of the uterine epithelium in and around the openings of the uterine glands. As the epithelium is digested away, the chorion folds into the crypts so formed and little stub villi about twice as long as wide are formed (Dog 40, Plate II, E). Each villus has a mesenchymal core, and the yolk sac fits closely into the neck of each villus. A slightly older stage of development is shown in the photomicrograph of the uterus of Dog 42L (Plate II, F). The cells at the tip of each villus digest away the uterine gland around it, seeming always to follow the lumen of the gland. When the villus reaches a branch in the gland, a secondary villus is formed that follows the gland. Thus, the uterine glands next to the original uterine lumen are replaced progressively by chorionic villi. The uterine gland cells immediately around the tip of each villus show definite signs of degeneration; i.e., darkly staining granular cytoplasm, pycnotic nuclei, crenated or ruptured cell membranes.

By 28 days (Dog 33L, Plate III, C), the chorionic villi have become a chorionic mass about two millimeters thick by expansion, contact and fusion of the secondary villi throughout the mass. Individual villi have reached the labyrinth of

the uterine gland and the secretory cells of the villus tip have spread out over the labyrinth, replacing the original uterine gland epithelium except for a very short distance on each side of the septum between labyrinths. Maternal blood vessels enter the chorionic mass through the septae, which are the original uterine tissue between adjoining uterine glands.

Blood Supply of the Placenta

The endodermal sac becomes complete at 11 days, the mesodermal layer of both yolk sac and chorion is differentiated by 17 days, and the vitelline blood vessels are differentiated and functional on the 18th day as the chorionic villi get underway. For several days, the yolk sac, with its net work of vitelline vessels, lies in contact with the chorion, fitting well down into the villi, and in every way forming a very efficient system for the absorption of food from the chorion.

The allantois is first detectable at 21 days (Dog 42L) as a small outpocketing of the hind gut. Stages showing the growth of the allantois are lacking, but at 27 and 28 days (Dogs 9 and 33L) the allantoic sac has forced its way between the yolk sac and the chorion dorsal and lateral to the embryo and has limited the yolk sac to approximately one-half of the chorionic vesicle. As the allantois contacts the

chorion, allantoic mesoderm and chorionic mesoderm fuse into one mesenchymal mass, through which the allantoic blood vessels run. Branches of these blood vessels penetrate the mesenchymal cores of the chorionic villi, and quickly find their way into the smallest branches of the villi. Once the allantoic circulation is established in the chorioallantois (apparently about 25 days) it spreads progressively over the chorion and gradually replaces the vitelline circulation as the effective medium of transfer between embryo and mother (Dog 33L, Plate III, C, and Dog 9, Plate III, B).

The yolk sac is relegated by the 35th day to a relatively insignificant condition of a crumpled sac, almost as long as the chorionic vesicle, continuously occupying a position ventral to the embryo, in contact with the chorion for approximately one-twentieth the circumference of the chorion. Undoubtedly, the yolk sac continues to play some part in exchanges between the embryo and mother up to parturition.

The endometrium, at the time of onset of chorionic villous formation, has a relatively poor blood supply, and very few blood vessels go past the labyrinths of the uterine glands. With the rapid increase of the uterine gland mass between the labyrinths and the uterine cavity from the 16th to the 20th days, there is a decided increase both in size and numbers of blood vessels in this area, the blood vessels

generally being in direct contact with the glandular epithelium with very little connective tissue matrix. The chorionic villi seem to digest specifically the glandular tissue, with removal of connective tissue following more slowly. Digestion terminates completely as the villi contact the blood vessels. The result is that the maternal vessels, entering by way of the septae between labyrinths, become completely stripped of all supporting maternal tissue which is replaced by chorionic ectoderm. Maternal blood vessels can be readily identified in the chorionic mass by the thickness of their walls and the absence of a connective tissue matrix around them (Dog 33L, Plate III, C; Dog 37, Plate III, D).

Removal of supporting tissues from the maternal blood vessels may result in rupture of those vessels. This occurs regularly along the edges of the villous zone where there apparently is not enough embryonic tissue present to contain the maternal vessels, resulting in a slow leakage of maternal blood within the chorionic mass, and forming the "marginal haematoma" or "terminal sinus". Secondary haematoma may form any place within the placental mass. There seems to be no provision by the embryo for the utilization of this blood supply.

Development of Placental Form

At the beginning of placentation (18 days, Dog 42R, Plate II, C), the blastocyst is a lemon-shaped bladder about five millimeters in diameter and six millimeters long, with a one millimeter protrusion on each end, extending out into the unexpanded part of the uterine lumen. Chorionic villi develop over all the surface of the blastocyst except the end protrusions. For 10 days, enlargement of the vesicle is proportional, with all the surface except the tips still covered with villi, but at 28 days the ends of the chorionic vesicle begin to expand more rapidly than the part covered with villi. By this time, the placenta is well established, and apparently does not stretch under tension as much as the thinner ends. This differential terminal expansion results by 35 days in a foot-ball shaped vesicle with both ends smooth and the intermediate part involved in the placental mass. By 42 days (Dog 25) the placental mass has stretched to 40 mm from terminal sinus to terminal sinus. The vesicle at this time is a uniform oval ball 50 mm in diameter and 90 mm long. The proportions in a 25 pound female at parturition are regularly about 150 mm long and 60 mm in diameter, with the placental band 40 to 45 mm across. The placental band thus is seen to develop from its original 5 or 6 mm at 18 days (Dog 42R), 20 mm at 21 days (Dog 42L), to 40 mm at 42

days (Dog 25). The change from 21 days to 42 days comes about both by stretching and by cell increase. The wall of the uterus does not stretch longitudinally as rapidly as the chorionic vesicle, resulting in a differential growth, with the 40 mm placental mass attached by means of the elongated inter-labyrinthine septae to an area on the uterine wall about 30 mm wide.

DISCUSSION

The results of this work in general supplement and clarify the description of placentation in the dog given by Mossman (1937).

Mossman defined the term "placenta" as "any organ consisting of an intimate apposition or fusion of the foetal membranes with the uterine wall for the purpose of carrying out physiological processes destined for the well-being of the embryo". By acceptance of this definition, he and other embryologists are faced with the necessity of the acceptance of a broadening of usage of the term to include mere contact between trophoderm and uterine epithelium as well as later stages in which a more intimate connection is affected.

"Placentation" may well be defined as the formation of a placenta. "Implantation" has been thought of by many embryologists as being synonymous with "placentation". The term "implantation", applied to Primate embryology involves

the penetration of the endometrium by the embryo with subsequent closure of the point of entrance so that embryonic development and formation of the placenta occur within the wall of the uterus. Embryonic development in the dog, however, occurs entirely within the lumen of the uterus and nothing occurs comparable to "implantation" in the human. It is, therefore, considered best to differentiate between "implantation" and "placentation", limiting the application of "implantation" to the actual burying of the embryo in the endometrium.

Mossman considered attachment of the dog embryo to be circumferential, with the embryonic disc oriented anti-mesometrial. In this study, no correlation of embryonic disc to any part of the uterus could be established. Orientation seems to be strictly by chance. Attachment occurs, not strictly circumferential but over the entire surface of the blastocyst, then by subsequent stretching of the tips of the blastocyst, the villous area secondarily becomes a circumferential zone.

The yolk sac was found to develop rather early, with the vitelline circulation becoming functional about the 17th day. The yolk sac completely fills the chorionic vesicle and the vitelline circulation serves as the sole medium of exchange between the embryo and the uterine wall during the time in which the chorionic villi are becoming established. After the allantois becomes established, the yolk sac becomes

progressively less important, but remains large and in contact with the chorion until parturition.

Mossman described the dog placenta as "labyrinthine", but did not describe the condition or development of the labyrinths. The "labyrinths" of Mossman were found to be formed by enormous expansion of swellings of the uterine glands beginning in the compact zone. These swellings were first detectable at 7 days, and became progressively larger until a maximum size is reached at about 35 days. These labyrinths seem to be reservoirs for the secretions of the deeper part of the uterine glands, and probably function in this capacity until parturition. Factors involved in the early swelling of these glands are obscure since the neck of the gland is open directly into the uterine cavity for several days after swelling begins. With the formation of the chorionic villi, the openings of the glands are effectively closed, and further enlargement may come about because of accumulation of secretions in the labyrinths. As the chorionic villi reach these labyrinths, the chorionic ectodermal cells spread across the surface of the labyrinth and become highly vesicular as if filled with secretion droplets. Later this ectodermal layer forms a large villus, sometimes with an allantoic blood vessel in it that projects well down into each labyrinth. From the position and cell structure of this villus, it seems logical that it has a function in the digestion and absorption of the uterine milk contained

in the labyrinth.

The endothelio-chorial type placenta has never been adequately described. Any good section through the dog placenta shows uterine blood vessels within the chorionic mass. It was not understood, however, that the chorionic villi completely digest all the superficial layer of the endometrium except the blood vessels.

Probably the least understood part of the carnivore placenta is the "marginal haematoma" or "terminal sinus". This blood ring was found to be filled with maternal blood but to have no connection with the maternal circulation and to have no coverage of embryonic vessels. Furthermore, no villi of any sort are present in, on, or around this blood ring. It seems that this "marginal haematoma" is nothing more than an accumulation of maternal blood from capillaries ruptured during replacement of maternal tissue by embryonic tissue in the placental area.

The allantois of the dog develops much the same and probably functions the same as it does in the pig. However, allantoic development is slower than in most mammals, not beginning at all until the 20th day, and taking another 5 or 6 days to reach a functional stage. At the time the allantois reaches the chorion, chorionic villi are well established and food passage has been possible because of the close contact of the yolk sac. The allantoic sac is large and permanent as stated by Mossman.

SUMMARY

1. Swellings occur on the uterine glands in the compact layer, and enlarge to make large open labyrinths.

2. The embryo floats free within the uterus until 17 to 18 days of age.

3. Chorionic villi do not develop until 18 days of age and then ectodermal cells develop pseudopodia-like extensions.

4. Villus penetration is limited to the openings of the uterine glands.

5. Chorionic villi progressively digest away and replace the uterine glands, so that by 27 days the mass of uterine glands between the labyrinths and the uterine cavity have been almost completely replaced by a chorionic mass.

6. A yolk sac placenta functions in the dog from the 15th to the 35th day.

7. The allantois begins to make contact with the chorion at the 25th day and expands progressively until complete at about the 35th day.

8. The original diffuse-type placenta becomes "zonary" by excessive expansion of the non-villous tips of the blastocyst.

9. Maternal blood vessels remain intact as chorionic villi digest and replace the original endometrial cells from around them.

10. The "marginal haematoma" is not villous. It represents unusable leakage from ruptured maternal vessels.

ACKNOWLEDGMENTS

Acknowledgment is given to Dr. H. T. Gier for his instruction, supervision and patience which made this thesis possible; to Project 321 of the Kansas State College Agricultural Experiment Station under which the material for the thesis was obtained; to the Kansas State College Department of Zoology for working space and equipment; and to the various staff members of the School of Veterinary Medicine for suggestions and criticisms.

REFERENCES

- Bonnet, R.
Beitrag zur Embryologie des Hundes. Anat. Hefte,
9: 419-512. 1897.
- Duval, M.
Les placenta des carnassiers. Jour. de l'Anat. et
de la Physiol. 29: 249-340. 1893.
- Fleischmann, A.
Embryologische Untersuchungen. Die Morphologie der
Placenta bei Nagern und Raubtiern. Weisbaden: 3: 153-
213. 1893.
- Henricius, G.
Ueber die Entwicklung und structur der Placenta beim
Hunde. Arch. f. mikr. Anat. V. Entwicklungsgesch.
33: 419-440. 1889.
- Mossman, H. W.
Comparative morphogenesis of the fetal membranes and
accessory uterine structures. Carnegie Inst. Wash-
ington, Contr. to Embryology, No. 158. 1937.
- Strahl, H.
Untersuchungen über Der Bau der Placenta III: Der
Bau der Hundeplacenta. Arch. f. Anat. u. Physiol.,
Anat. Sec.: 185-202. 1890.

APPENDIX A

Measurements Concerning Placentae Used

Age : Dog days: no.	: Length of embryo	: Uterine swelling : Length:Thickness	: Villous area : width
7	13	2 cell	
17	16	1 somite 5.4 mm	10 mm 10 mm
18	42R	8 x 5 blct	
20	40		
21	42L	7 mm	30 mm 15 mm 20 mm, t.s.* 15 mm, z.a.**
27	9		50 mm 33 mm
28	37	18 mm	46 mm 30 mm 30 mm, t.s.* 25 mm, z.a.**
28	33L	31 mm	65 mm 40 mm 35 mm
42	25	90 mm	95 mm 60 mm 40 mm, t.s.* 26 mm, z.a.**

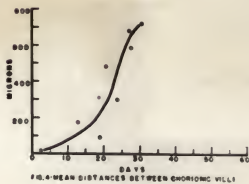
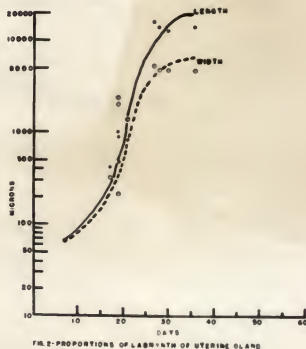
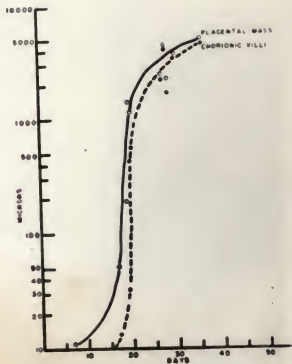
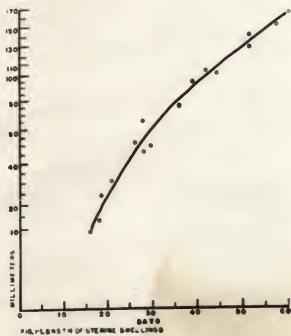
* t.s.= terminal sinus

** z.a.= zone of attachment

APPENDIX B

Plates I, II, III

PLATE I



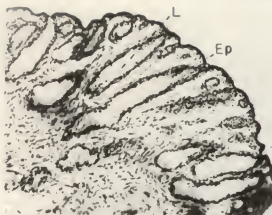
EXPLANATION OF PLATE II

All illustrations of Plates II and III are photomicrographs of sections of uterus stained with Harris' Hematoxylin. Key to abbreviations of Plates II and III.

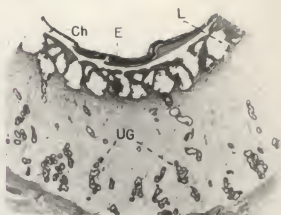
AV	allantoic vessel
CH	chorion
ChM	chorionic mass
ChSV	chorionic secretory villi
Ep	epithelium
E	embryo
En	endoderm
L	labyrinth
M	mesoderm
MP	maternal pad
MV	maternal vessel
S	septae
SC	secretory cells
SL	spongy layer
SCV	secretory cells of villi
TS	terminal sinus
UtEp	uterine gland epithelium
Ug	uterine gland
YS	yolk sac
V	chorionic villi

- A. Dog 13, 7 days after ovulation, uterine glands beginning to expand. 125X.
- B. Dog 16, 17 days after ovulation, X sec. showing embryo against the uterine epithelium. 45 X.
- C. Dog 42R, 18 days after ovulation, longitudinal section of uterine swelling to show orientation and formation of labyrinth. 15 X.
- D. Higher magnification of portion of C to show beginning of villi. 125 X.
- E. Dog 40, 20 days after ovulation, showing increase of labyrinths, branchings of uterine glands and penetration of villi. 40 X.
- F. Dog 42L, 21 days, shows condition slightly more advanced than E. 45 X.

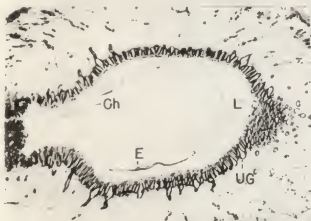
PLATE II



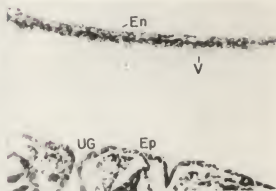
A



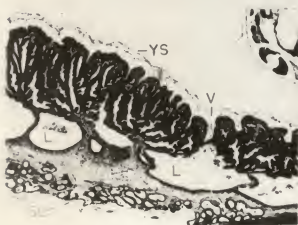
B



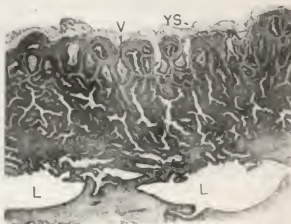
C



D



E

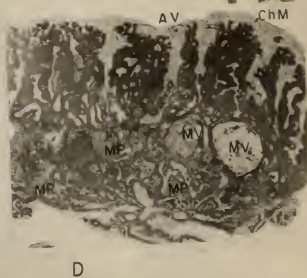

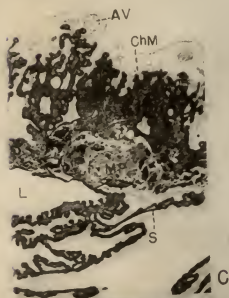
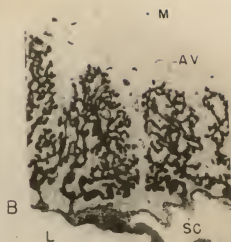
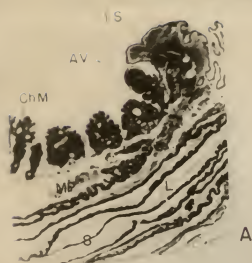


F

EXPLANATION OF PLATE III

- A. Dog 9, 27 days, shows the greatly elongated uterine gland labyrinths directed towards the marginal haematoma. 15 X.
- B. Higher magnification of portion of A to show the well established allantoic circulation, and the chorionic secretory cells. 45 X.
- C. Dog 33L, 28 days, shows allantoic vessels, chorionic mass and maternal pad. 45 X.
- D. Dog 37, same age as Dog 33L, shows the maternal vessels, chorionic mass and pycnotic uterine cells in contact with the chorionic mass. 45 X.
- E. Dog 25, 42 days, shows the relationship between the secretory tip of the chorionic villus and maternal labyrinths. 45 X.
- F. Higher magnification of portion of E, showing the cell structure of the chorionic secretory villus. 125 X.

PLATE III



PLACENTATION IN THE DOG

by

DEMOSTENE ROMANUCCI

B. S., Ohio University, 1948

AN ABSTRACT OF A THESIS

submitted in partial fulfillment of the

requirements for the degree

MASTER OF SCIENCE

Department of Zoology

KANSAS STATE COLLEGE
OF AGRICULTURE AND APPLIED SCIENCE

1951

Previous work on canid placentation was done mostly at the close of the last century in Europe. Many of the conclusions were arrived at with incomplete material and data and too many analogies were drawn. Practically no work has been done on dog placentation during the first half of the 20th century except an attempt at classification and this added nothing but confusion.

In this study uteri were removed from dogs at desired stages, fixed, sectioned and stained. Additional study of this material was supplemented by macroscopic dissection.

It was found that the uterine glands undergo great morphological changes. These glands in the non-pregnant uterus are single tubules which may or may not branch near the muscularis. Swellings first become apparent around the 7th day. Swelling continues until excessively large labyrinths are formed under the zone of attachment and orient themselves so that the long axis is directed toward the marginal hematoma.

Chorionic villi form as pseudopodia-like processes which orient themselves towards the lumen of the uterine glands. These villi, upon entrance, begin digestion of the epithelium replacing it with the chorionic cells. The villi gradually expand and fuse into a chorionic mass, rendering the original villi obscure.

The vitelline circulation becomes functional at 17 days,

and provides the entire medium until the allantoic circulation takes over gradually from 25 to 35 days. During the early stages of placentation, few maternal blood vessels are found in the uterus past the labyrinths of the glands, but as age increases so do the size of the vessels. The chorionic mass digests all maternal tissue, but digestion ceases when contact is made with a maternal blood vessel, leaving the maternal vessels completely surrounded by chorionic tissue.

The marginal haematoma is formed by rupture of the maternal blood vessels due to a general weakening of the vascular walls with digestion and, contrary to the present available literature, it is not of a villus-chorial nature.

The early placenta is of a diffuse type. The zone of attachment of the placenta at maturity represents the entire original area of contact. Once the original confines are established the zone of attachment increases eight times in width, but the chorion not involved in the placenta increases many fold, for it is not attached and is free to extend as far along the uterine lumen as it desires.