FUNCTIONAL DIVISION WITHIN THE LUMBOSACRAL PLEXUS

61
349 5839

by

JAMES WALT WILSON

B. S., Michigan State University, 1969
D. V. M., Michigan State University, 1970

A MASTER'S THESIS

submitted in partial fulfillment of the

requirements for the degree

MASTER OF SCIENCE

Department of Surgery and Medicine

KANSAS STATE UNIVERSITY
Manhattan, Kansas

1973

Approved by:

Hugh C. Butler
MAJOR PROFESSOR

THIS BOOK CONTAINS NUMEROUS PAGES WITH THE ORIGINAL PRINTING BEING SKEWED DIFFERENTLY FROM THE TOP OF THE PAGE TO THE BOTTOM.

THIS IS AS RECEIVED FROM THE CUSTOMER.

LD
2668
T4
1973
W525
c.2
Document

This thesis is dedicated to the
betterment of residency programs
in Veterinary Medicine and to those
doctors who make them possible.

TABLE OF CONTENTS

Page

LIST OF FIGURES AND TABLES iv

ACKNOWLEDGEMENTS v

INTRODUCTION 1

REVIEW OF THE LITERATURE 3

- Spinal Anatomy
- Lumbosacral Plexus Anatomy
- Peripheral Nerve Origin and Distribution
- Associated Anatomy
- Patellar Tendon Reflex
- Neurogenic Atrophy of Muscle
- Neurologic Examination

RESEARCH DESIGN AND METHODOLOGY 21

- Design
- Methodology
  - Surgical Approach
  - Study Groups

RESULTS 39

- Surgical Approach
- Study Groups

DISCUSSION 54

CONCLUSION 66

BIBLIOGRAPHY 67

LIST OF FIGURES AND TABLES

Figure Page

1 Cross-sectional view of the spinal column 4

2 Illustrations of the most common relationship of the spinal cord to the vertebrae 6

3 Lumbosacral plexus 8

4 Lateral views of three canine lumbosacral plexuses 8

5 Myotome distribution in the canine pelvic limb 10

6 Relationship of the lumbosacral plexus and the spinal column . .12

7 Associated anatomy 13

8 Major intra-abdominal structures 14

9-20 Surgical approach to the lumbosacral plexus 23-29

21-28 Surgical approach to the spinal roots of L_5 35-38

29 Removed lumbosacral plexus 51

30-31 Neurogenic atrophy of muscle 52

32 Histologic scar at site of ventral ramus transection 53

33 Ventral horn cell changes associated with ventral ramus transection 53

Table

I Results of group I 47

II Results of group II 48

III Clinical results of group III 48

IV Weights of muscles removed from group IV 49

V Neurogenic atrophy of muscle 49

VI Results of group V 50

ACKNOWLEDGEMENTS

The author would like to thank the faculty of Dykstra Veterinary Hospital for their contributions to the Small Animal Surgical Residency Program and especially to Dr. Jacob E. Mosier for his administrative support of this study.

I would like to thank my committee together for their guidance and direction. Dr. Horst Leipold's freely given aid and advice, both in the planning phases of my study and in the actual post-mortem and histopathologic examinations was invaluable. A very warm "bon appetite" is due Dr. Stanley G. Harris for furthering my knowledge in Cardiology and cultivating my interest in Enology. Dr. Hugh C. Butler, the director of my residency program, served as my major advisor. His interest in me made this degree program possible.

Don Holman deserves special recognition. His interest in Veterinary Medicine and his financial support of a very deserving student, Tom McCoy, made the completion of this study possible. Tom's assistance during surgery and with postoperative animal care was gratefully received.

INTRODUCTION

The lumbosacral plexus is thought by many to be an anatomic and functional entity by itself. Reflexes mediated through this plexus are therefore said to test the integrity of the whole plexus or a major portion thereof. The patellar tendon or knee jerk is such a reflex. It is a common reflex used in both human and veterinary medicine. In veterinary medicine it is by far the easiest reflex to elicit and the one most often tested. It is considered to test the integrity of both the femoral nerve and the lumbar spinal cord segments 3, 4, 5 and 6 (3 being questionable) and also to act as an indicator of the continuity of the entire spinal cord.

The possibility of there being a more defined functional division to the lumbosacral plexus first presented itself as a clinical observation.

Case 1

A dog was presented to Dykstra Veterinary Hospital with a history of being struck by an automobile. Examination of the rear legs revealed bilateral pain perception in the medial toes (2nd phalanges), bilateral absence of the patellar tendon reflex and bilateral anesthesia of the lateral toes (5th phalanges). Pain perception was not present on the tail nor on the anal spincter.

Radiographs revealed a fracture of the 4th lumbar vertebra.

Final diagnosis was transection of the lumbar spinal cord.

Case 2

A dog was presented to Dykstra Veterinary Hospital with a history of being struck by an automobile. Examination of the rear legs revealed bilateral absence of pain perception in both the medial and lateral toes and bilaterally exaggerated patellar tendon reflexes. No pain perception was evident on the tail nor anal spincter.

Radiographs revealed a severe luxation between lumbar vertebral bodies 3 and 4.

Final diagnosis was transection of the lumbar spinal cord.

If the patellar tendon reflex is indicative of the integrity of several lumbar spinal segments (McGrath, 1960), why would lesions millimeters apart change the patellar tendon reflex so dramatically; considering that both lesions involved those spinal segments that contribute to the femoral nerve (Miller *et al*., 1964)? To prove or disprove the hypothesis that there is functional division within the lumbosacral plexus, the following study was conducted.

REVIEW OF THE LITERATURE

Spinal Anatomy

Excellent detailed descriptions of the spinal anatomy are available (Hoerlein, 1971; Jenkins, 1972; Miller et al., 1964; Rugh et al., 1965). The classic representation of a transverse section through the spinal cord is illustrated in figure 1. The short spinal nerve, which is made up of contributions from the dorsal and ventral roots, divides into a small dorsal and a large ventral ramus. The dorsal ramus supplies motor innervation to the epaxial musculature and sensory innervation to the dorsolateral and sacral skin. The ventral ramus, either alone or together with other ventral rami, supplies all the sensory and motor fibers that make up the large peripheral nerves; i.e., sciatic n., femoral n., obturator n.

The dorsal root is classified as the afferent or sensory root while the ventral root is classified as the efferent or motor root. This is because the afferent neurons, whose cell bodies are located in the dorsal root ganglia, relay information from the periphery to the central nervous system via the dorsal root. The efferent neurons, whose cell bodies are located in the ventral horn of the spinal cord gray matter, transmit impulses to the periphery via the ventral root.

Miller et al. (1964) have a full chapter on the anatomy of the spinal cord. They devote separate sections to the spinal cord segments and external landmarks. From the text one can infer that no variation to the described pattern exists. Certain spinal cord segments are found within certain vertebral bodies. Large detailed illustrations of the

THIS BOOK CONTAINS NUMEROUS PAGES WITH DIAGRAMS THAT ARE CROOKED COMPARED TO THE REST OF THE INFORMATION ON THE PAGE.

THIS IS AS RECEIVED FROM CUSTOMER.

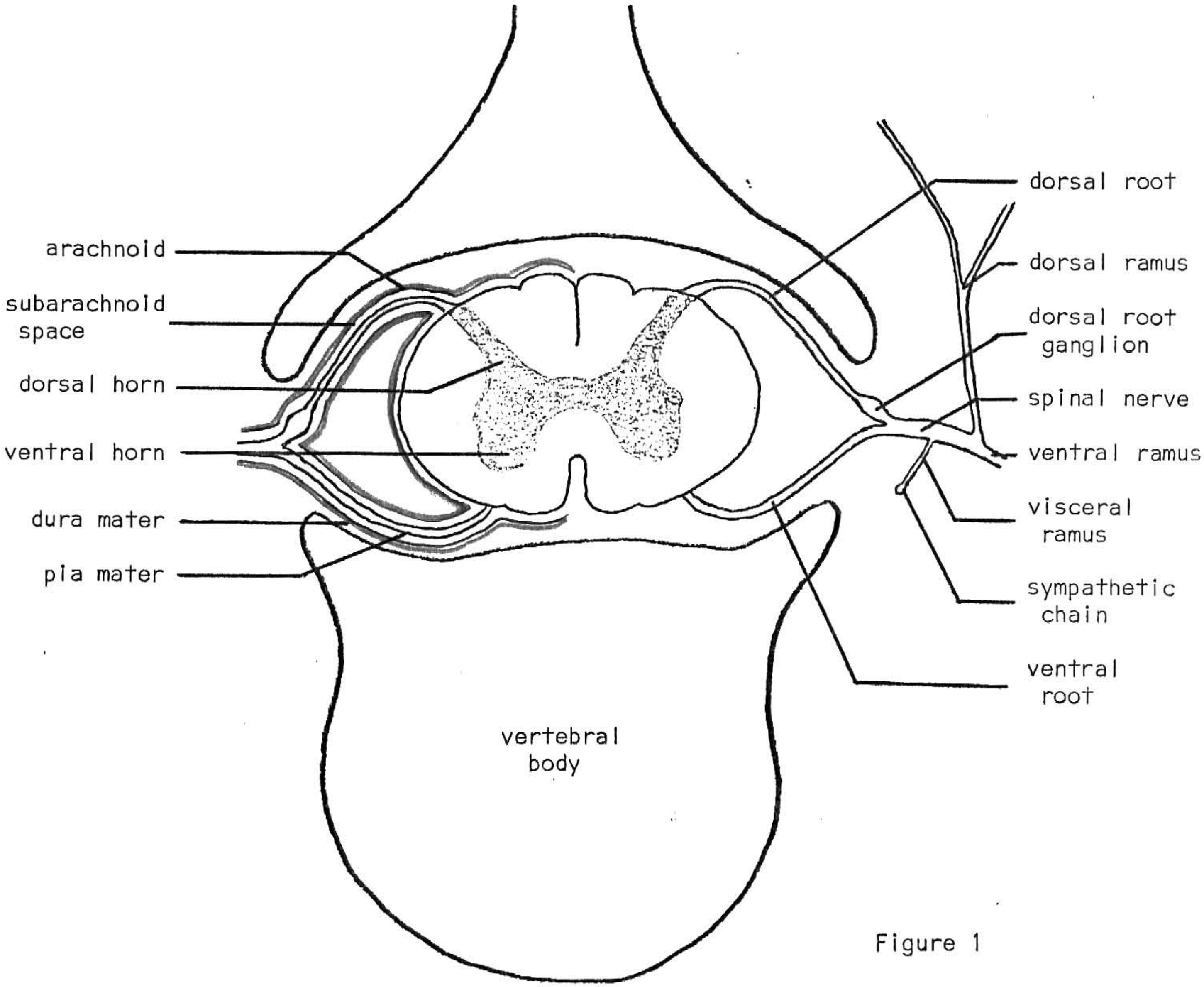
arachnoid
subarachnoid space
dorsal horn
ventral horn
dura mater
pia mater
dorsal root
dorsal ramus
dorsal root ganglion
spinal nerve
ventral ramus
visceral ramus
sympathetic chain
ventral root
vertebral body

Figure 1

spinal cord within the vertebral column are presented to clarify the text.

Fletcher and Kitchell (1966) studied the anatomic relationships between the location of the spinal cord segments with respect to the bodies of the vertebrae. In their dissection of twenty-five dogs of various size and breed, they found very few spinal cord segments to lie entirely within their numerically corresponding vertebrae. Most cord segments were positioned craniad to their corresponding vertebrae.

Two regions of the spinal cord, the caudal cervical through the cranial thoracic and the caudal lumbar through the coccygeal region, had shorter segments than the other areas. These two areas corresponded to the brachial enlargement and the lumbar enlargement. Because of the shortened spinal segments, these segments were shifted more craniad with respect to their numbered vertebrae, and hence, longer roots were necessary to reach the appropriate vertebral foramina.

With regard to their illustration (figure 2) they say they "represents a guide . . . in locating a spinal cord segment by means of vertebral landmarks; however, the inherent variability among subjects must be considered"! "Generally, a spinal cord differed along its length from the illustrated pattern for only a few segments, but occasionally most of the cord segments would deviate."

Lumbosacral Plexus Anatomy

Miller et al. (1964) describe the anatomy of the lumbosacral plexus. They consider the plexus to consist of the intercommunication of the ventral rami of the last five lumbar and the first three sacral nerves (figure 3). They then divide the plexus into a lumbar plexus consisting

THIS BOOK
CONTAINS SEVERAL
DOCUMENTS THAT
ARE OF POOR
QUALITY DUE TO
BEING A
PHOTOCOPY OF A
PHOTO.

THIS IS AS RECEIVED
FROM CUSTOMER.

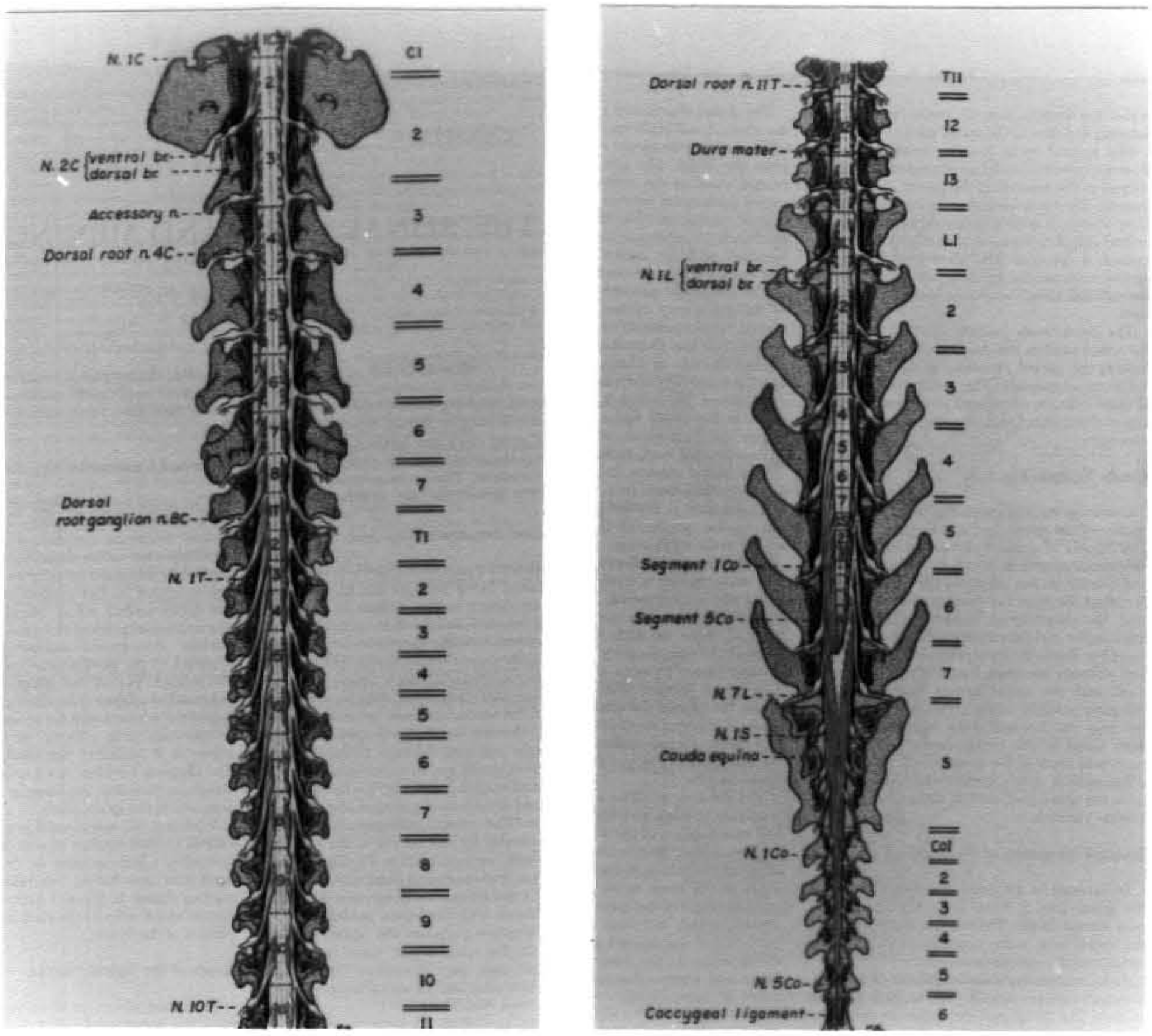
N. 1C
N. 2C {ventral br. / dorsal br.
Accessory n.
Dorsal root n. 4C
Dorsal root ganglion n. 8C
N. 1T
N. 10T
C1
2
3
4
5
6
7
T1
2
3
4
5
6
7
8
9
10
11
Dorsal root n. 11T
Dura mater
N. 1L {ventral br / dorsal br
Segment 1Co
Segment 5Co
N. 7L
N. 1S
Cauda equina
N. 1Co
N. 5Co
Coccygeal ligament
T11
12
13
L1
2
3
4
5
6
7
S
Co1
2
3
4
5
6

Figure 2: Illustrations of the most common relationship of the spinal cord to the vertebrae. (From Fletcher and Kitchell, 1966)

of contributions from lumbar spinal cord segments 3, 4 and 5 (L_3, L_4, L_5) and a sacral plexus consisting of contributions from lumbar spinal cord segments 6 and 7 (L_6, L_7) and sacral spinal cord segments 1, 2 and 3 (S_1, S_2, S_3). This they say is purely division due to location and not origin.

Fletcher (1970) examined the lumbosacral plexus of thirty dogs. These patterns were then correlated with a corresponding study of limb myotomes and three general types of plexus arrangement arrived at: prefixed, postfixed and median fixed (figure 4). Because the variability of the plexus was a continuum, these were not the only patterns seen but solely representatives of the two extremes and the median.

Peripheral Nerve Origin and Distribution

Miller *et al*. (1964) describe the origins of the peripheral nerves and their muscle innervation. "The femoral nerve arises primarily from the fifth segment of the lumbar plexus with a strong root of origin also coming from the fourth. A smaller branch of origin may come from the third, but rarely does one come from the sixth segment." The sciatic nerve "arises primarily from the sixth and seventh lumbar nerves with a small contribution from the first and occasionally the second sacral nerves."

The femoral nerve sends muscular branches to the iliopsoas (psoas major) muscle. The saphenous nerve, arising from the femoral nerve, innervates both the cranial and the caudal bellies of the sartorius muscle. The terminal extent of the femoral nerve then passes into the quadriceps femoris muscle and supplies all four heads (rectus femoris, vastus lateralis, vastus medialis and vastus intermedius).

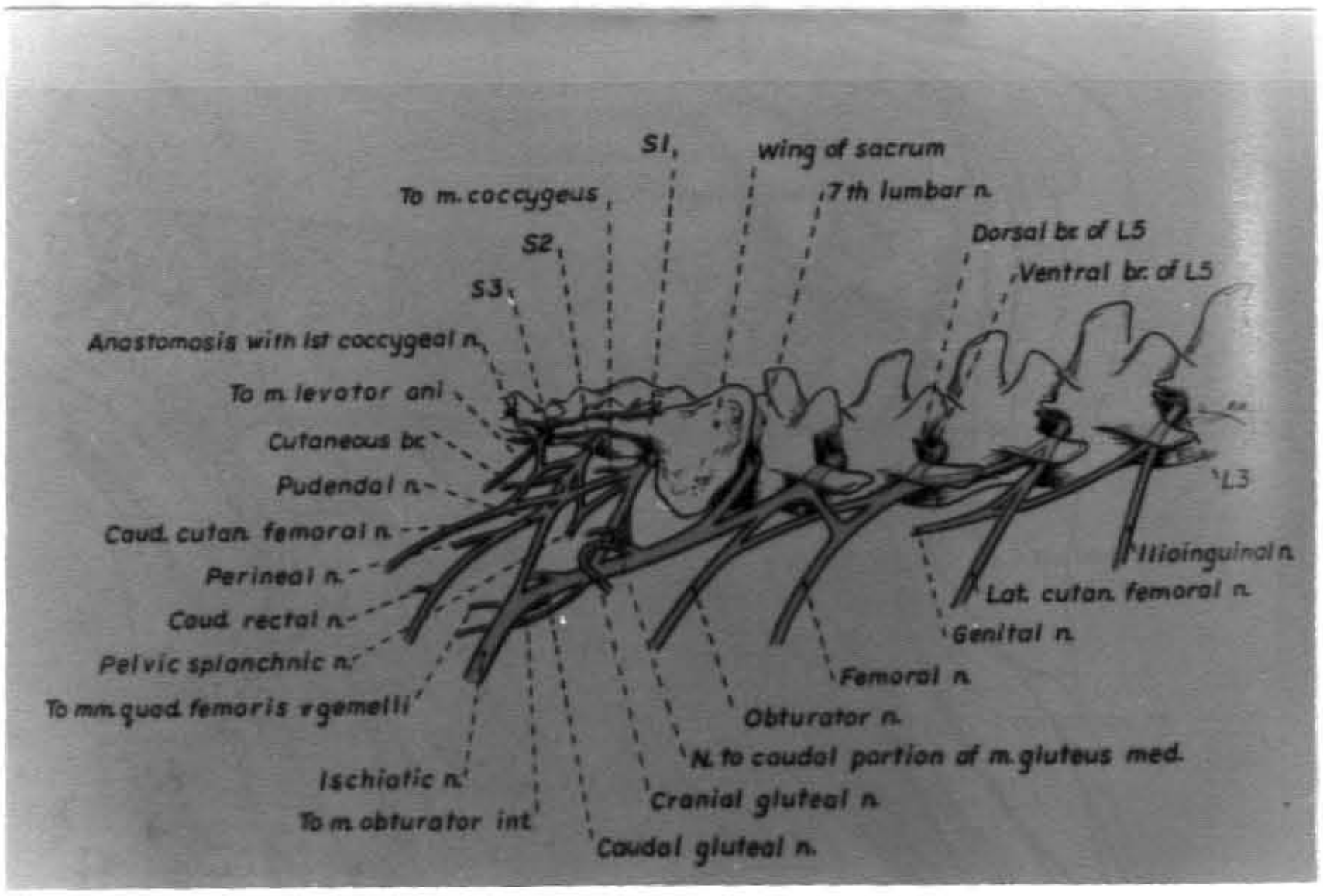
S1
wing of sacrum
To m. coccygeus
7th lumbar n.
S2
Dorsal br. of L5
S3
Ventral br. of L5
Anastomosis with Ist coccygeal n.
To m. levator ani
Cutaneous br.
Pudendal n.
L3
Caud. cutan. femoral n.
Ilioinguinal n.
Perineal n.
Lat. cutan. femoral n.
Caud. rectal n.
Genital n.
Pelvic splanchnic n.
Femoral n.
To mm. quad. femoris + gemelli
Obturator n.
N. to caudal portion of m. gluteus med.
Ischiatic n.
Cranial gluteal n.
To m. obturator int.
Caudal gluteal n.

Figure 3: Lumbosacral plexus. (From Miller et al., 1964)

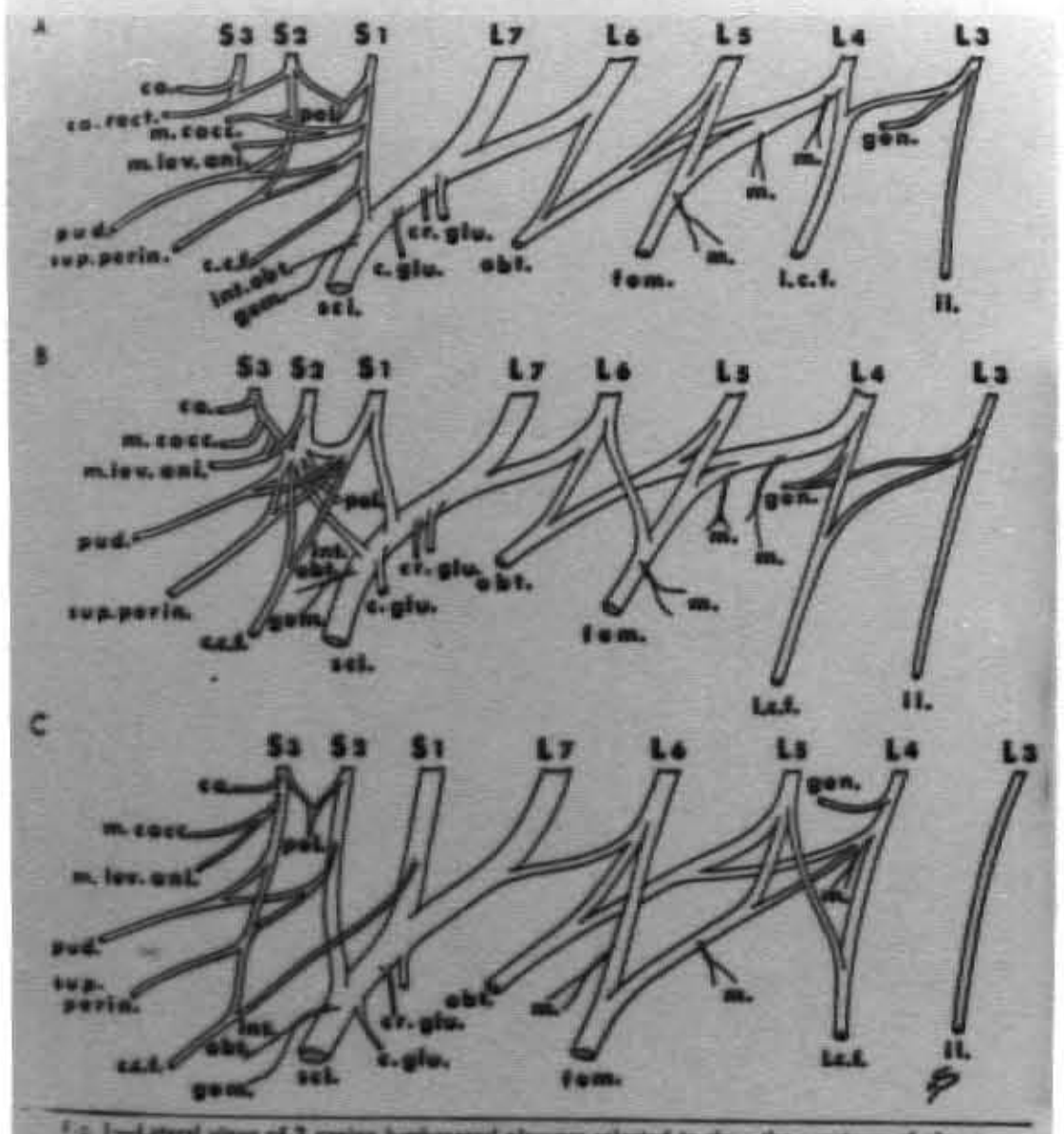
A
S3 S2 S1 L7 L6 L5 L4 L3
co.
co. rect.
m. cocc.
m. lev. ani
pel.
gen.
m.
pud.
sup. perin.
c.c.f.
int. obt.
gem.
cr. glu.
c. glu.
obt.
sci.
fem.
l.c.f.
il.
B
S3 S2 S1 L7 L6 L5 L4 L3
co.
m. cocc.
m. lev. ani
pel.
gen.
pud.
sup. perin.
int. obt.
cr. glu.
obt.
c. glu.
c.c.f.
gem.
sci.
fem.
m.
l.c.f.
il.
C
S3 S2 S1 L7 L6 L5 L4 L3
co.
gen.
m. cocc.
pel.
m. lev. ani
pud.
sup. perin.
obt.
m.
int.
cr. glu.
c.c.f.
obt.
c. glu.
gem.
sci.
fem.
l.c.f.
il.

Fig. 1—Lateral views of 3 canine lumbosacral plexuses selected to show the spectrum of plexus variability: (A) prefixed plexus, (B) median fixed plexus, (C) postfixed plexus. In comparing the pre- and postfixed types, notice the distributions of ventral rami L_4 and S_3 and the nerve origins generally. For each regional nerve in plexus B, the origin which occurred most frequently is illustrated. Abbreviations: L_3 to S_3 = ventral rami; il. = ilioinguinal; l.c.f. = lateral cutaneous femoral; gen. = genitofemoral; m. = muscular branches to iliopsoas muscle; fem. = femoral; obt. = obturator; cr. glu. and c. glu. = cranial and caudal gluteal; sci. = sciatic; int. obt. and gem. = branches to internal obturator, gemelli, and quadratus femoris muscles; c.c.f. = caudal cutaneous femoral; sup. perin. = superficial perineal; pud. = pudendal; m. lev. ani and cocc. = branches to levator ani and coccygeus muscles; co = branch to ventral coccygeal trunk; pel. = pelvic nerve.

Figure 4: Lateral views of three canine lumbosacral plexuses. (From Fletcher, 1970)

The sciatic nerve gives rise to the cranial gluteal nerve which supplies the deep and middle gluteal muscles and the tensor fascia lata muscle. It also gives rise to the caudal gluteal nerve which supplies the superficial and maybe the middle gluteal muscles and the piriformis muscle. The sciatic sends muscular branches to the abductor cruris caudalis, biceps femoris, semitendinosus and semimembranosus muscles before it divides to form the tibial and fibular (peroneal) nerves. These two terminal nerves then go on to supply innervation to all the muscles of the lower limb.

Fletcher (1970) undertook a study to determine contributions by embryologic myotomes to the pelvic limb muscles. Using electrophysiological means on ten dogs he arrived at a myotome distribution (figure 5). He found that each ventral ramus that contributed to a specific peripheral nerve generally innervated every muscle supplied by that nerve. In addition most pelvic limb muscles were usually innervated by three spinal segments and never less than two.

The "L_3 myotome", that myotome connected with innervation from the third lumbar spinal cord segment, did not contribute to the formation of pelvic limb muscles except for the iliopsoas. The myotomes for L_4 and L_5 were identical. They contributed to the quadriceps femoris, sartorius and capsularis coxae muscles via the femoral nerve and to the gracilis, pectineus, adductor longus and adductor magnus et brevis muscles via the obturator nerve. The myotome for L_6 contributed to all the muscles of the hindlimb except for the internal obturator, gemelli and quadratus femoris muscles and its innervation was found with the femoral, obturator and sciatic nerves. L_7 myotome uniformly supplied much hindlimb



Muscle	Innervating ventral roots	Regional nerve
Sartorius	[illegible]	Femoral
Rectus femoris	[illegible]	Femoral
Vastus lateralis	[illegible]	Femoral
Vastus intermedius	[illegible]	Femoral
Vastus medialis	[illegible]	Femoral
Capsularis coxae	[illegible]	Femoral
Gracilis	[illegible]	Obturator
Adductor magnus et brevis	[illegible]	Obturator
Adductor longus	[illegible]	Obturator
Pectineus	[illegible]	Obturator
Tensor fasciae latae	[illegible]	Cranial gluteal
Middle gluteal	[illegible]	Cranial gluteal
Deep gluteal	[illegible]	Cranial gluteal
Superficial gluteal	[illegible]	Caudal gluteal
Biceps femoris	[illegible]	Sciatic
Abductor cruris caudalis	[illegible]	Sciatic
Semitendinosus	[illegible]	Sciatic
Semimembranosus	[illegible]	Sciatic
Cranial tibial	[illegible]	Peroneal
Long digital extensor	[illegible]	Peroneal
Lateral digital extensor	[illegible]	Peroneal
Fibularis longus	[illegible]	Peroneal
Extensor hallucis longus	[illegible]	Peroneal
Fibularis brevis	[illegible]	Peroneal
Gastrocnemius	[illegible]	Tibial
Superficial digital flexor	[illegible]	Tibial
Deep digital flexor	[illegible]	Tibial
Caudal tibial	[illegible]	Tibial
Popliteus	[illegible]	Tibial
Plantar muscles of pes	[illegible]	Tibial
Internal obturator	[illegible]	Sciatic
Gemelli	[illegible]	Sciatic
Quadratus femoris	[illegible]	Sciatic
Bulbocavernosus	[illegible]	Pudendal
Ischiocavernosus	[illegible]	Pudendal
Coccygeus	[illegible]	Sacral plexus
Levator ani	[illegible]	Sacral plexus
External anal sphincter	[illegible]	Caudal rectal

Figure 5: Myotome distribution in the canine pelvic limb. (From Fletcher, 1970)

musculature but did not overlap with the uniform distribution of the L_4 and L_5 myotomes nor was its innervation found within the femoral nerve.

The anatomic distribution of pelvic limb nerves to the skin has been described (Miller et al., 1964). A review of and electrophysiologic study for lumbar, sacral and coccygeal tactile dermatomes has been performed in the canine (Fletcher and Kitchell, 1966). They found that most areas were innervated by three dorsal roots, generally, and that dermatome boundaries displayed an inherent variability around an area of maximal response.

Associated Anatomy

Excellent anatomy texts are available showing the anatomic structures surrounding the lumbosacral plexus (Miller et al., 1964; Popesko, 1970?).

The lumbosacral plexus is in an extremely well protected position. Medially it is supported by the osseous vertebral column. The numbered ventral rami originate from the intervertebral foramina immediately caudad to that numbered vertebral body and then run for a distance of only a few millimeters before they form the lumbosacral plexus. In addition, osseous protection is provided dorsally by each transverse spine of the vertebrae (figure 6).

Dorsal soft tissue protection is multitude. Immediately under the skin is variable amounts of adipose tissue. Next is encountered a sheath of lumbodorsal fascia. Immediately under this lies the extensive epaxial musculature consisting of the iliocostalis system laterally, the longissimus system and finally the transversospinalis system deep medially. The

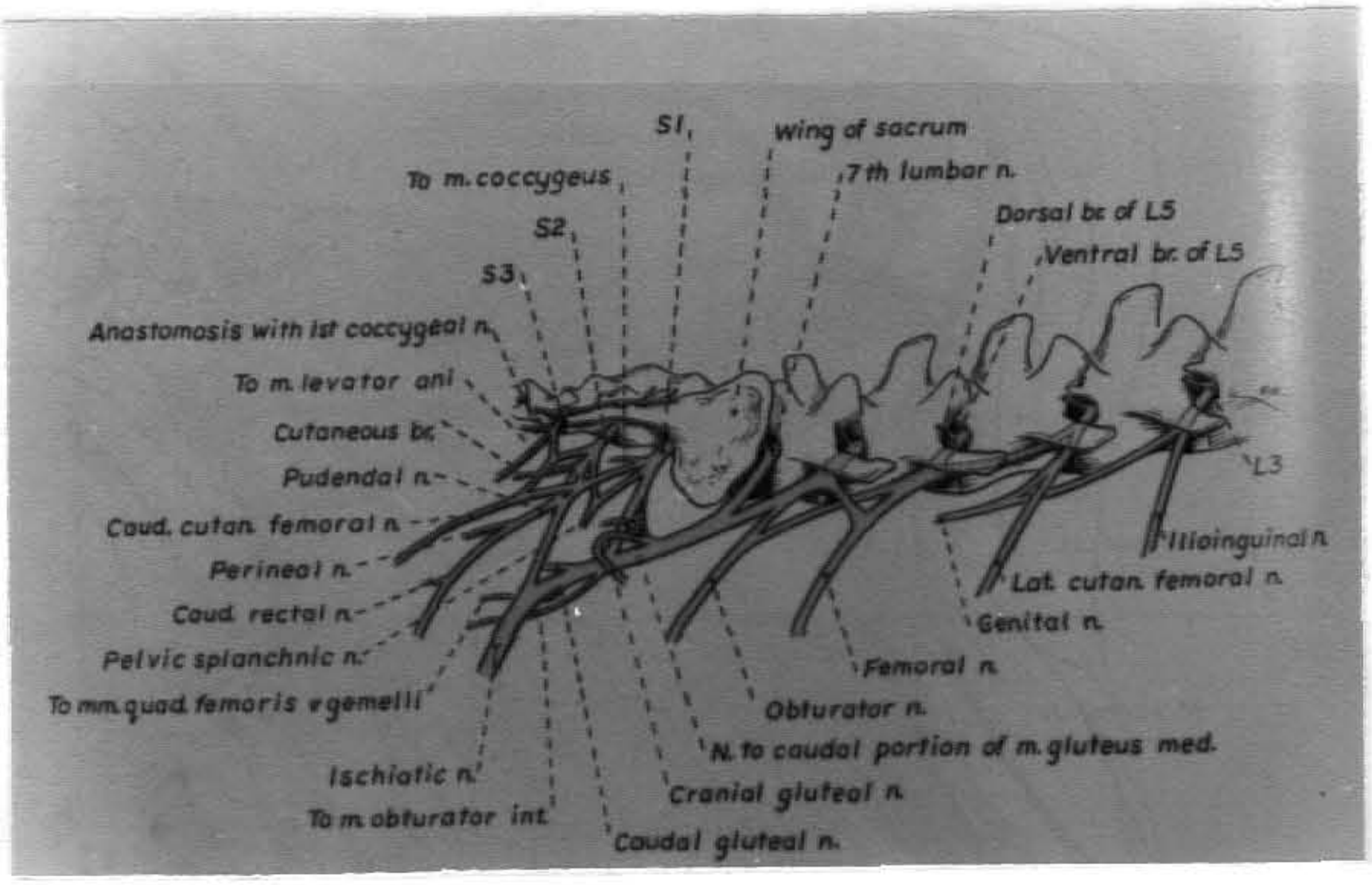
S1
Wing of sacrum
To m. coccygeus
7th lumbar n.
S2
Dorsal br. of L5
S3
Ventral br. of L5
Anastomosis with 1st coccygeal n.
To m. levator ani
Cutaneous br.
Pudendal n.
L3
Caud. cutan. femoral n.
Ilioinguinal n.
Perineal n.
Lat. cutan. femoral n.
Caud. rectal n.
Genital n.
Pelvic splanchnic n.
Femoral n.
To mm. quad. femoris & gemelli
Obturator n.
N. to caudal portion of m. gluteus med.
Ischiatic n.
Cranial gluteal n.
To m. obturator int.
Caudal gluteal n.

Figure 6: Relationship of the lumbosacral plexus and the spinal column. (From Miller _et al._, 1964)

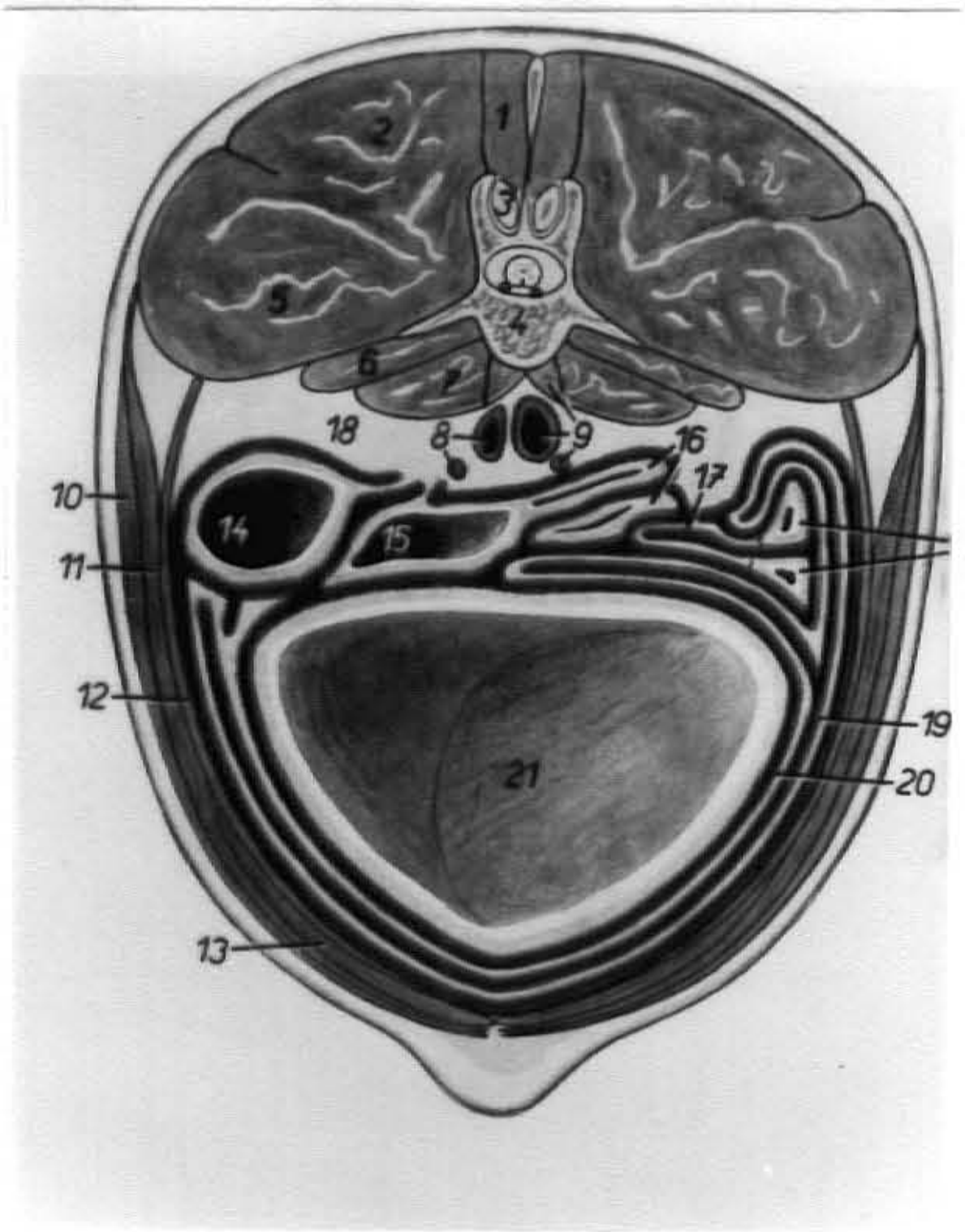
1
2
2
3
5
4
6
7
18
8
9
16
17
10
14
15
11
12
19
20
21
13

Figure 7: Associated anatomy. (1) transversospinalis m., (2) longissimus m., (3) articular process, (4) vertebral body, (5) iliocostalis m., (6) quadratus lumborum m., (7) iliopsoas m., (8) aorta, (9) vena cava, (10) external abdominal oblique m., (11) internal abdominal oblique m., transversus abdominis m., (13) rectus abdominis m., (14) colon, (15) jejunum, (21) urinary bladder. (From Popesko, 1970?)

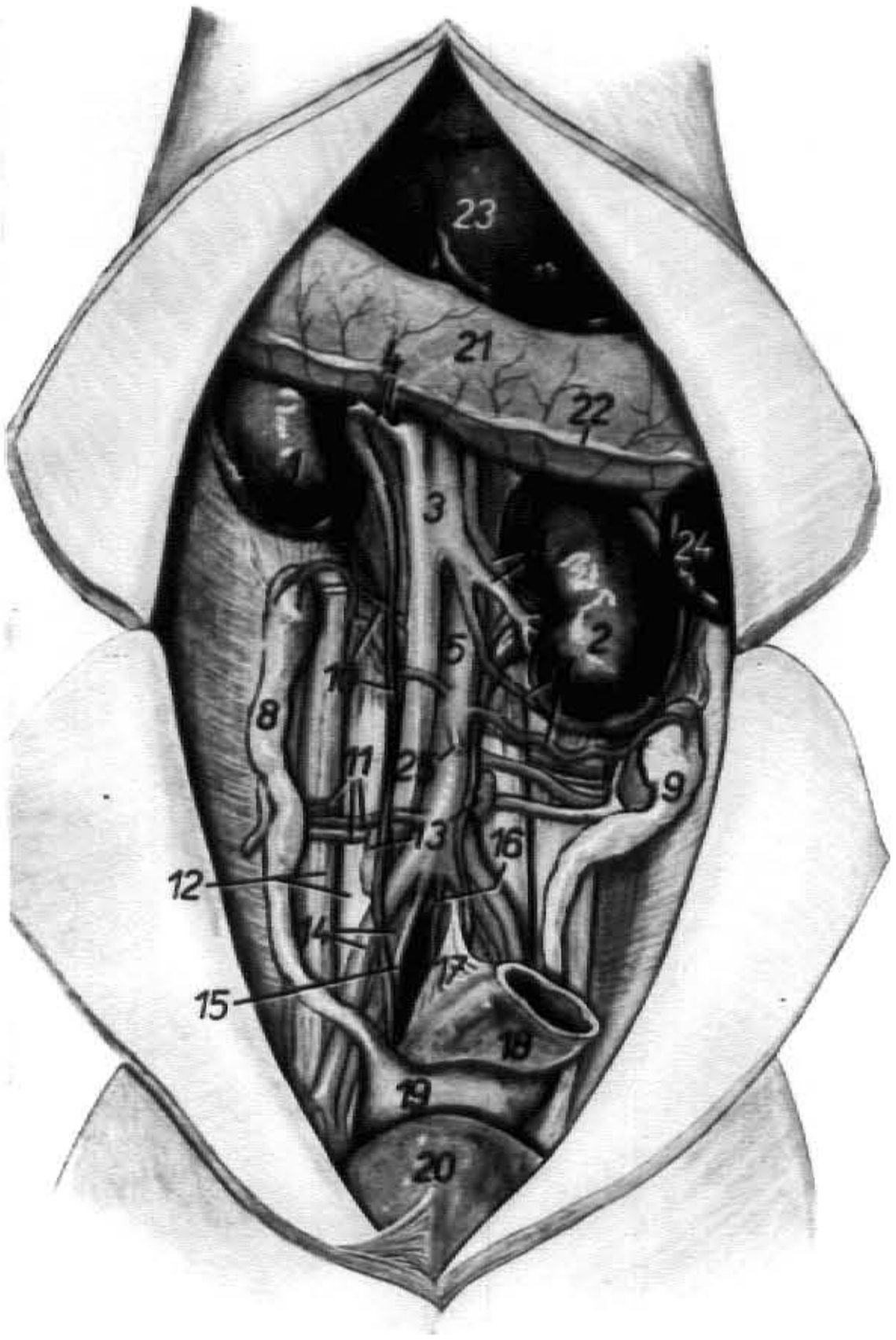
23
21
4
22
3
24
2
5
10
8
11
21
13
16
9
12
14
15
17
18
19
20

Figure 8: Major intra-abdominal structures. (3) vena cava, (5) aorta, (8 and 9) uterine horns, (10) ureter, (11) circumflex iliac artery and vein and accompanying ilioinguinal nerve, (12) iliopsoas m. and quadratus lumborum m., (13) lymph nodes, (14) femoral artery and vein, (18) colon, (20) urinary bladder, (24) spleen. (From Popesko, 1970?)

transverse spines of the vertebrae then present an osseous barrier. Under these spines lies the quadratus lumborum muscle which lies over the iliopsoas muscle which contains the plexus.

Laterally the protection is again extensive. Variable amounts of abdominal musculature may or may not be encountered depending upon the position of the dissection plane ventrally. Once again the extensive epaxial musculature is encountered consisting mostly of the iliocostalis system. Once again the plexus is protected to some extent by the transverse spines. Directly under these spines again lies the quadratus lumborum muscle and under it, deep within the iliopsoas muscle, the plexus.

Ventrally the area is protected by the entire abdominal musculature and contents. Major structures lying close to the plexus consist of the aorta, iliac bifercation, vena cava, urinary bladder, ureters and spermatic cord or uterus. Variable amounts of adipose tissue overlie these structures. Under all this the plexus lies under the psoas minor muscle, deep within the iliopsoas muscle (figures 7 and 8).

Patellar Tendon Reflex

The patellar tendon reflex is elicited by positioning the stifle such that slight tension is placed upon the tendon of the quadriceps femoris muscles (the patellar tendon). This tendon is then tapped with a suitable instrument. The result should be a twitch-like contraction of the quadriceps muscles and an extension kick of the lower leg (Hoerlein, 1971; Rugh et al., 1965). This reflex is a fractional and somewhat artificial manifestation of the myotatic or stretch reflex, a mechanism for upright posture.

The role of this myotatic reflex in posture was first examined by Sherrington (1898, 1915). Animals which were subjected to transection of the brain stem at the midcollicular level exhibited an immobile exaggerated extension of specific muscles. This could be abolished by division of the dorsal roots supplying those muscles. Sherrington concluded that this ridigity was an overactivity of a spinal reflex that normally maintained posture. Later Sherrington (1924) deduced, by the process of exclusion, that the receptors for this reflex lay within the muscles themselves and that the stimulus for the receptors was muscle stretch. Sherrington termed these receptors "proprioceptors".

The "fall table" was a device for studying this reflex quantitatively. From it Liddell and Sherrington (1924, 1925) proved that the quadriceps muscles actively resisted elongation and that this resistance was not due solely to the elastic properties of muscle. They also demonstrated several ways in which this reflex could be inhibited; stretching of an antagonistic flexor muscle or stimulation of an ipsilateral cutaneous nerve trunk.

Lloyd (1943) studied the electrophysiologic characteristics of this myotatic reflex. He recorded the velocity of the afferent nerve impulse generated by muscle stretch and was able to determine the time of central delay before an efferent impulse was generated. He concluded that, for the velocity of the afferent impulse, the central time lag was within the range expected for a single synapse.

Magladery *et al*. (1952) confirmed the monosynaptic nature of this reflex in man. By using recording electrodes inserted into the lumbar spinal column, they were able to record two major deflections, the afferent and the efferent nerve impulses. The time lag between the registered deflections allowed for only one single synapse.

Neurogenic Atrophy of Muscle

The subject of neurogenic atrophy of muscle has been extensively reviewed by Adams, Denny-Brown and Pearson (1962); Sunderland and Ray (1950); and Tower (1939). The following is an accumulation of these reviews.

The first signs of muscular change occur by the end of one week. These changes may occur earlier in some fibers than others. In general, though, the sarcolemmal nuclei lose their flattened appearance and become more rounded and plump while their nucleoli become more prominent. By the second week, enlargement of the nucleoli and hyperchromatism begins to appear. The nuclei appear to take a more central position in the muscle fibers and often show a halo of sarcoplasm around them. In these first two weeks no numerical increase in muscle nuclei occurs, both transverse and longitudinal striations are well preserved and there is no increase in the number and size of fibroblasts.

At the end of a month the overall uniformity of muscle fiber diameters begins to disappear. There is a noticeable reduction in the diameter of some muscle fibers with many taking on a more rounded than polygonal shape. The supporting connective tissue begins to be more evident. After two months this fiber diameter decrease is more dramatic, occurring in most fibers. Some fascicles appear more affected than others giving the general picture a very marked lack of uniformity.

By four months the process is beginning to slow down. No fibroblastic increase is evident nor is there any evidence of fatty change. The sarcolemmal nuclei are now becoming clumped into groups as the degeneration of isolated muscle fibers becomes more pronounced. These degenerating fibers first become granular and basophilic with rows of nuclei and then thin and finally disintegrate into small clumps or tubes of muscle nuclei with scant cytoplasm. The tubes then fragment leaving behind only a string of darkly staining rounded nuclei.

The overall degree of reduction in size and weight of particular muscles (using the opossum as a model) was studied by Sunderland and Ray (1950). They found a 30 per cent loss of weight in the first twenty-nine days. This was followed by a 50 to 60 per cent loss by sixty days. By one hundred twenty days and thereafter a steady state loss of 60 to 80 per cent had occurred.

Denny-Brown (Adams, Denny-Brown and Pearson, 1962) found that following section of the femoral nerve in cats, atrophy of the sartorius muscle had been more rapid and profound than in the quadriceps muscle group. In other cats, however, this rapid change was not evident and the sartorius and quadriceps muscles atrophied uniformly.

In further studies, Denny-Brown (Adams, Denny-Brown and Pearson, 1962) observed the outcome of denervated muscle after eight months. He found that various parts of the muscle were in greatly different phases of atrophy and degeneration. While the lateral aspect of the sartorius muscle showed changes equivalent to those observed elsewhere after only two months, no intact fibers remained in the medial aspect. Although the lateral aspect of the vastus lateralis muscle was severely degenerated, the medial aspect showed only moderately severe atrophy. At an even later stage fat cells accumulated in long rows and broke the cellular remnants of the muscle fibers into columns. In areas of the most severe degeneration, the formed muscle was represented by columns of fat interspersed with strands of inert fibrous tissue.

He concluded that "fragmentation is a stage in the process of neural atrophy, and that the small chains of pyknotic nuclei in late atrophy represent, not whole muscle fibers, but the remnants of the larger fragments of the final stage." "At some stage of neural atrophy, therefore, the atrophic process gives way to changes of a degenerative kind, which occur much earlier in some animals and some muscles than others." He did not observe any transitional stage between muscle fibers and either fibroblasts or fat cells, and therefore concluded that "the progressive replacement by adipose tissue that ultimately occurs appears to result from undifferentiation of mesenchymal cells."

Neurologic Examination

McGrath (1960) indicates that the patellar tendon reflex involves the lumbar spinal cord segments 4, 5 and 6 (occasionally 3). He states that if the reflex is absent or depressed the lesion is localized in the lower lumbar area. Unilateral depression suggests involvement of just that side. Exaggerated reflexes indicate involvement of the higher (more anterior) cord, the response being a type of release phenomena. He alludes to the fact that the impulses are transmitted through the femoral nerve.

Hoerlein (1971) has a short explanatory statement as to how a person is to go about eliciting the patellar tendon reflex. No description of specific pathways involved in this reflex are given except that the femoral nerve is the peripheral nerve transmittor. A reference is made, however, to McGrath (McGrath, 1960). The particular clinical findings involving this reflex may then be described in his separate chapters on specific clinical syndromes; but this is not always the case.

RESEARCH DESIGN AND METHODOLOGY

Design

If the spinal components of the lumbosacral plexus could be approached surgically, selected lesions could then be made and the resulting functional losses examined. Depending upon the resulting deficits or upon the functions remaining, division of the plexus into functional units could then be attempted. To approach this the methodology was divided into a search for a surgical approach and next the performance and evaluation of selected lesions.

Methodology

Surgical Approach

Several mongrel dogs of undetermined age, sex and weight were used. In each, a surgical exposure was attempted from one of three planes: dorsal, ventral and lateral. Each attempt was evaluated as to: 1) approach possible 2) ease of surgery 3) actual exposure afforded.

The ventral approach was chosen for reasons to be given in Results.

An entrance to the caudal abdominal cavity is performed through a routine linea alba incision. The specifics of the entrance and the differences in approach between the sexes are described in several surgery texts (Annis and Allen, 1967; Archibald, 1965; Leonard, 1968). A balfour-type abdominal retractor is then used to agrandize the incision. Before insertion, saline-soaked gauze sponges are used to pad the contact between the abdominal wall and the rectractor blades. To approach the right lumbosacral plexus, the abdominal contents are retracted to the left side of the abdominal cavity by way of mesoduodenum. For approaching the left side, these contents are retracted to the right side by using the colonic mesentery. The circumflex iliac artery and vein are next identified and divided between ligatures. The psoas musculature lies immediately under the adipose tissue in this area and is easily isolated by blunt dissection. This adipose tissue can then be retracted towards the midline along with the ureter and major vessel (the aorta on the left and the vena cava on the right) using a hand retractor. These structures can safely and easily be retracted far enough that the ventral surfaces of the vertebral bodies are seen.. At this point the iliopsoas muscle is easily visualized. On top of it lies a tight band, the tendon of the psoas minor muscle. This tendon can be sufficiently retracted laterally to negate the need for severing it. Blunt dissection into the body of the iliopsoas muscle exposes the plexus. With practice, certain cleavage lines are recognizable that overlie specific areas of the plexus. This approach and the exposure of the lumbosacral plexus gained are illustrated in figures 9 through 20.

This surgical approach was used exclusively in the study. It will be referred to as the "standard surgical approach". All animals subjected to this approach were held off food for twelve hours prior to surgery. They were premedicated with .04mg/lb. atropine sulfate administered subcutaneously, induced intravenously with sodium thiamylal[a], intubated and maintained on either halothane[b] or methoxyflurane[c] via a semi-closed inhalation anesthetic system. The ventral abdomen was prepared in a

THIS BOOK
CONTAINS
NUMEROUS
PICTURES THAT
ARE ATTACHED
TO DOCUMENTS
CROOKED.

THIS IS AS
RECEIVED FROM
CUSTOMER.

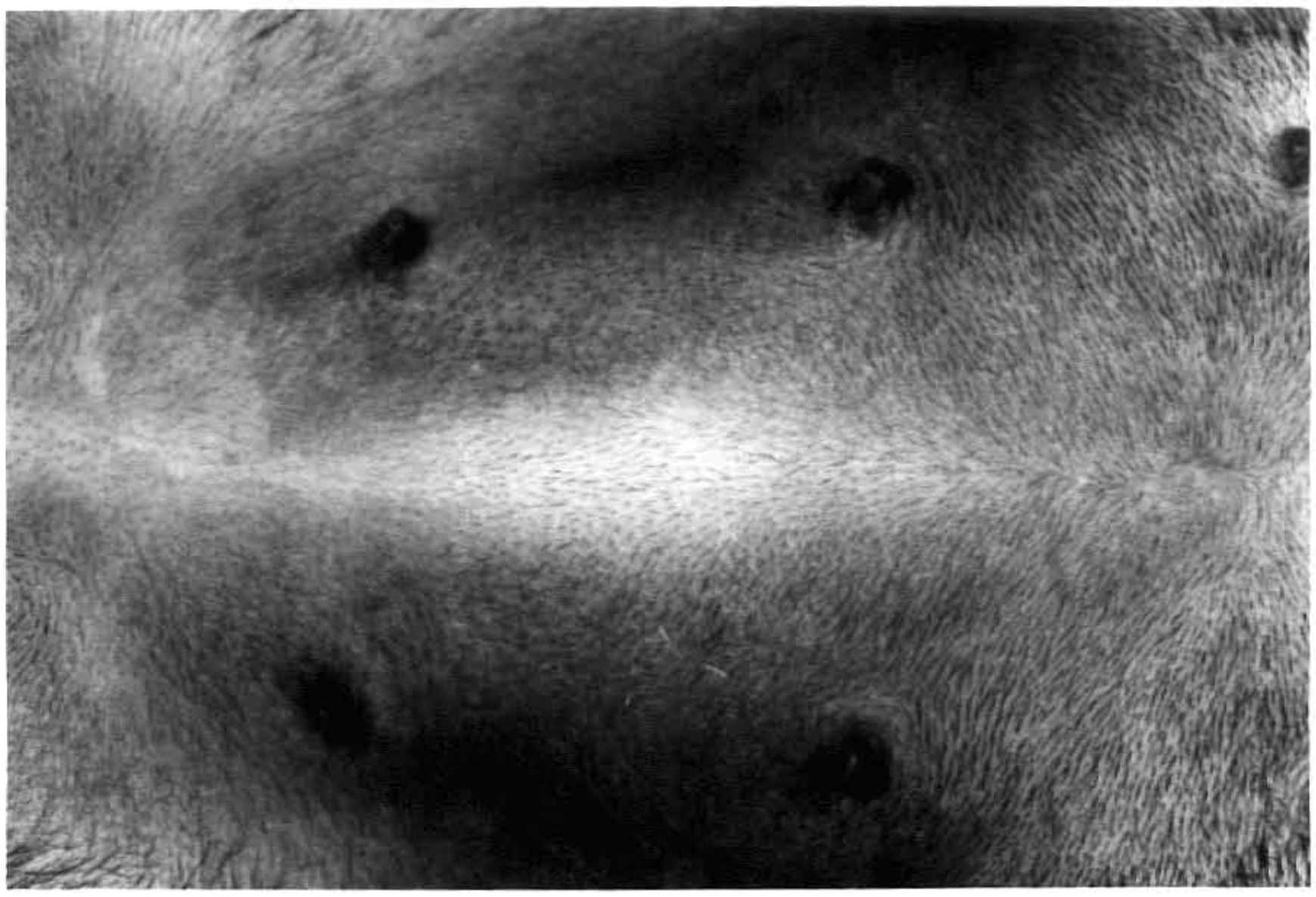

Figure 9: The surgical field is caudal ventral midline.

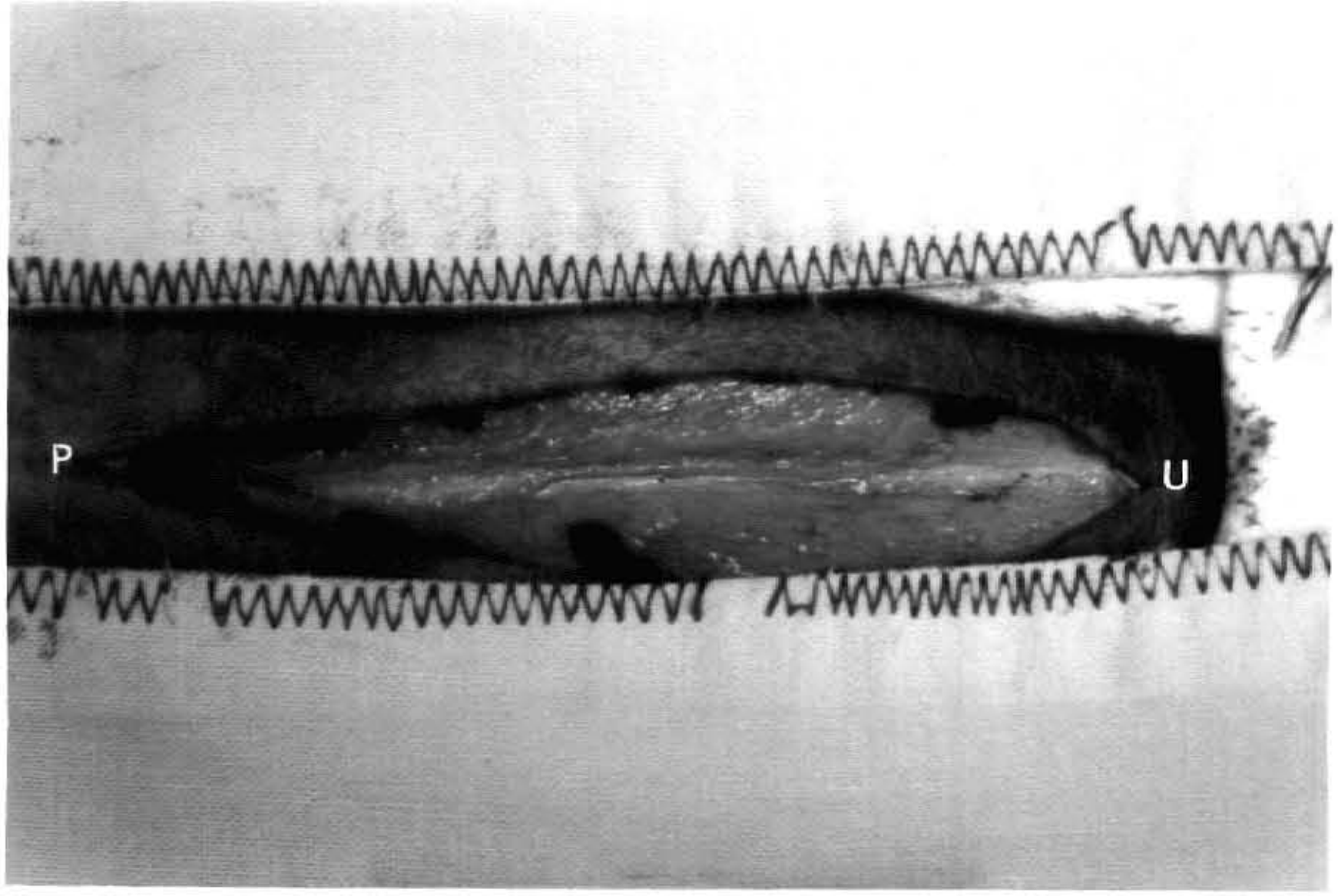

Figure 10: Incision from umbilicus (U) to pubic brim (P).

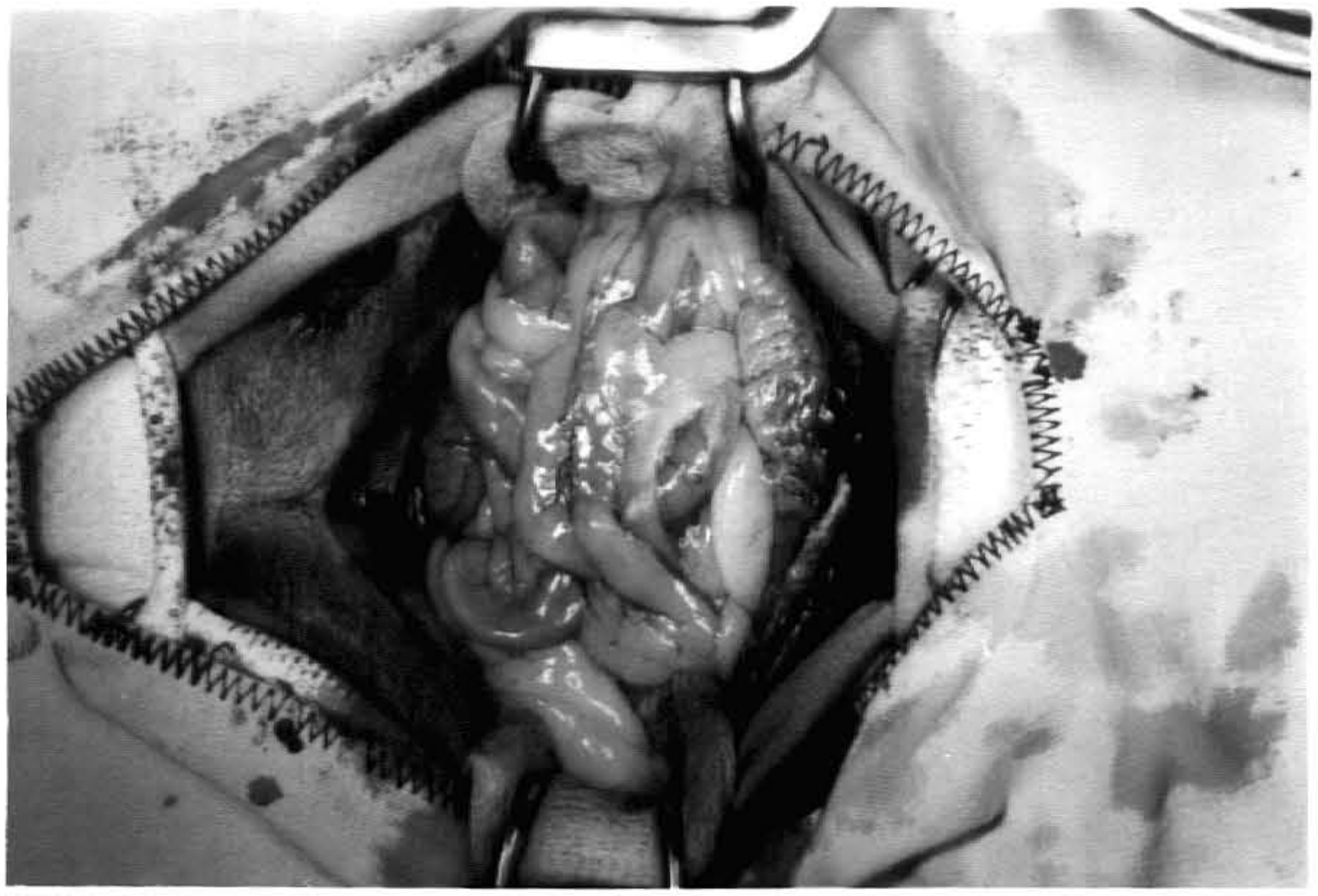

Figure 11: Abdominal entrance with Balfour retractor in place.

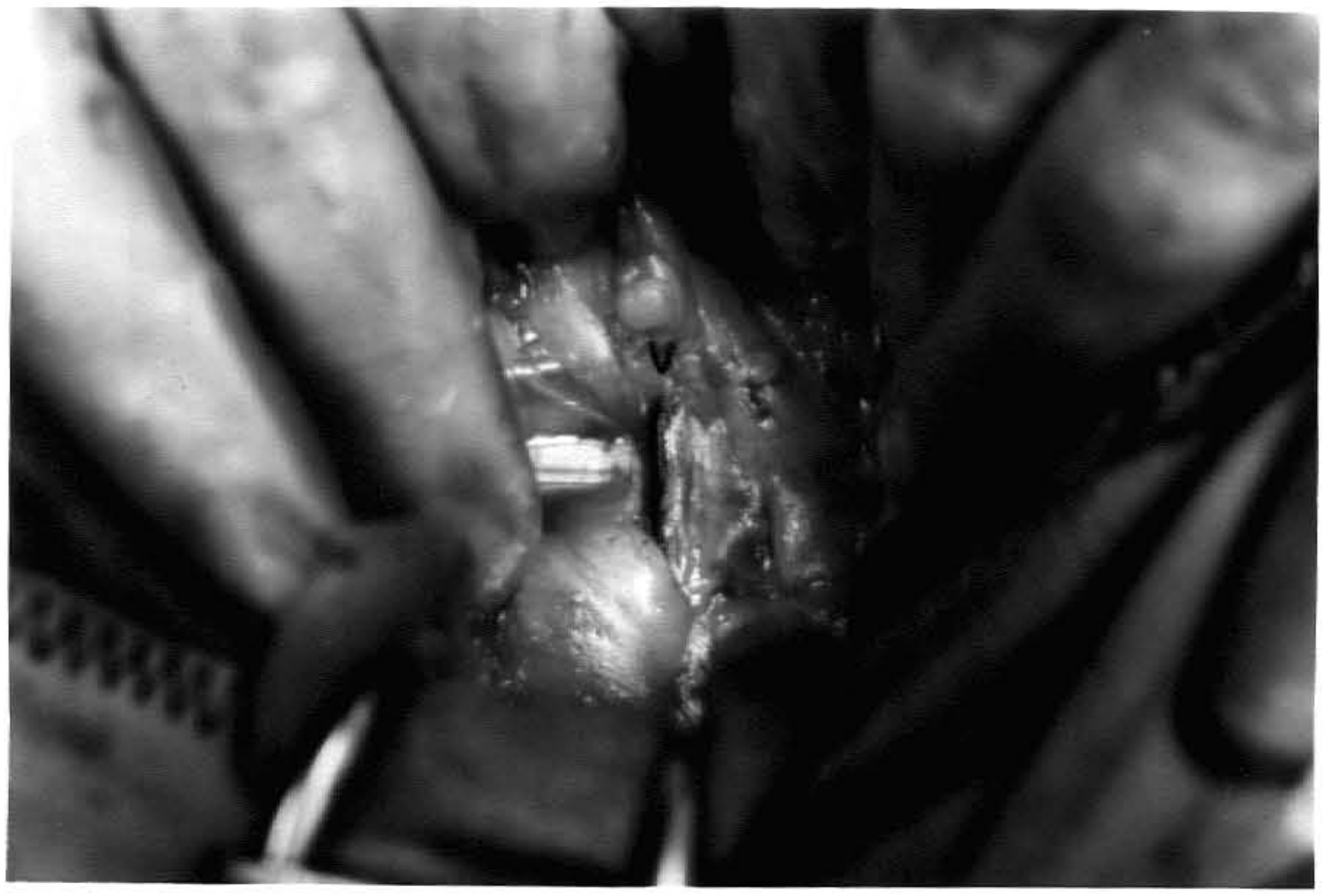

Figure 12: Circumflex iliac artery and vein (V).

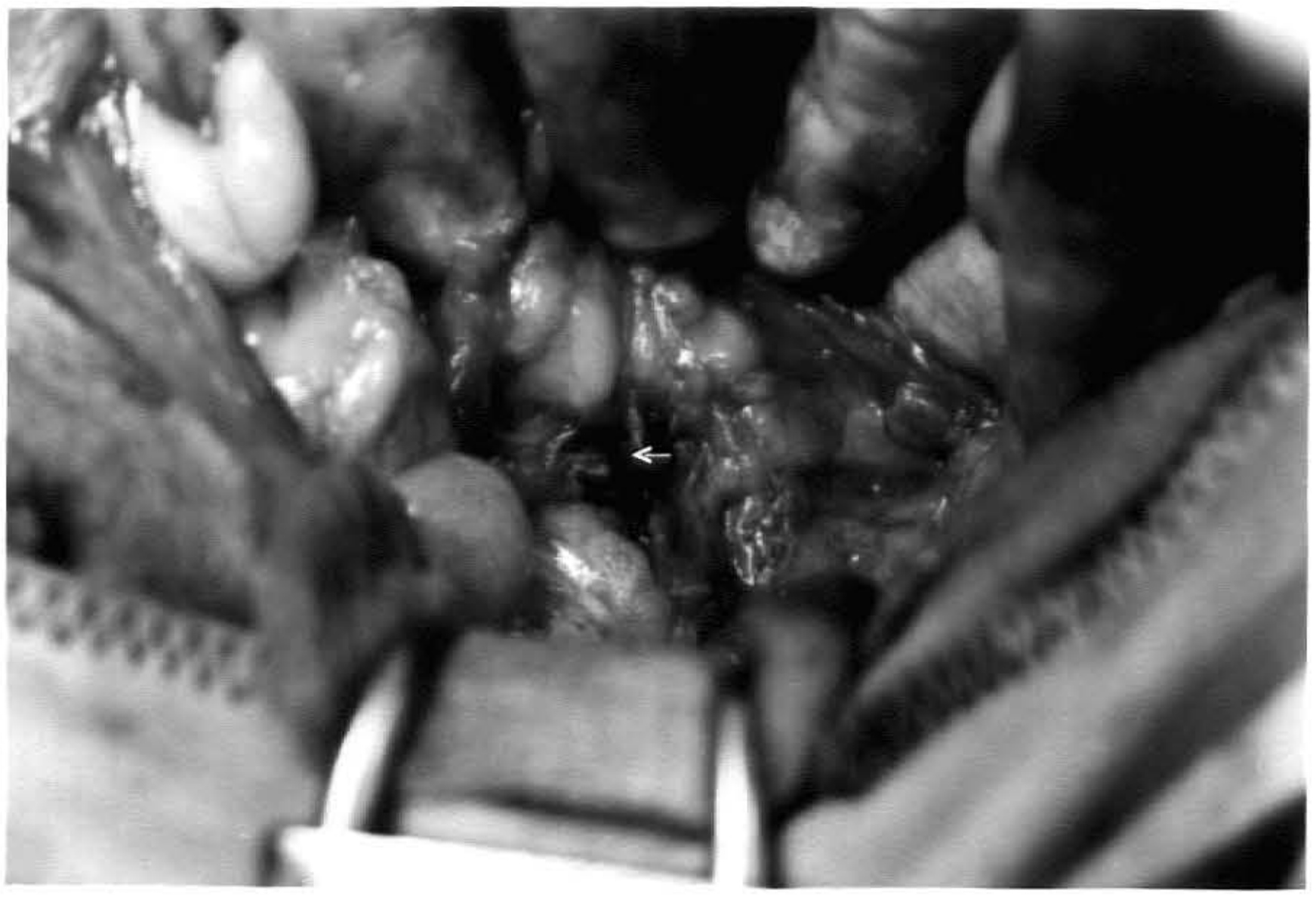

I

Figure 13: Ligated circumflex vessels (arrow).

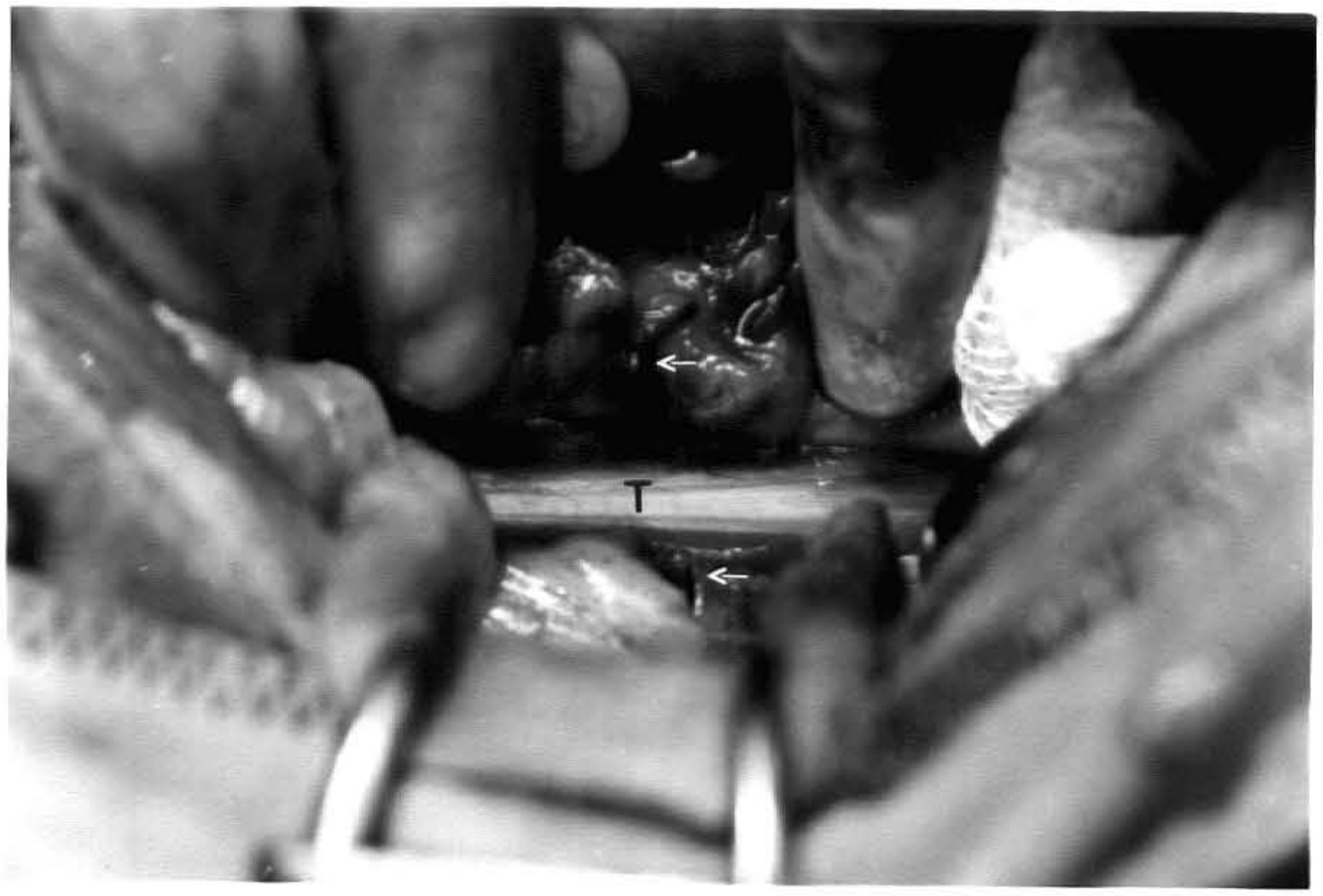

I

Figure 14: Severed ends of the circumflex vessels (arrows) exposing the tendon of the psoas minor muscle (T).

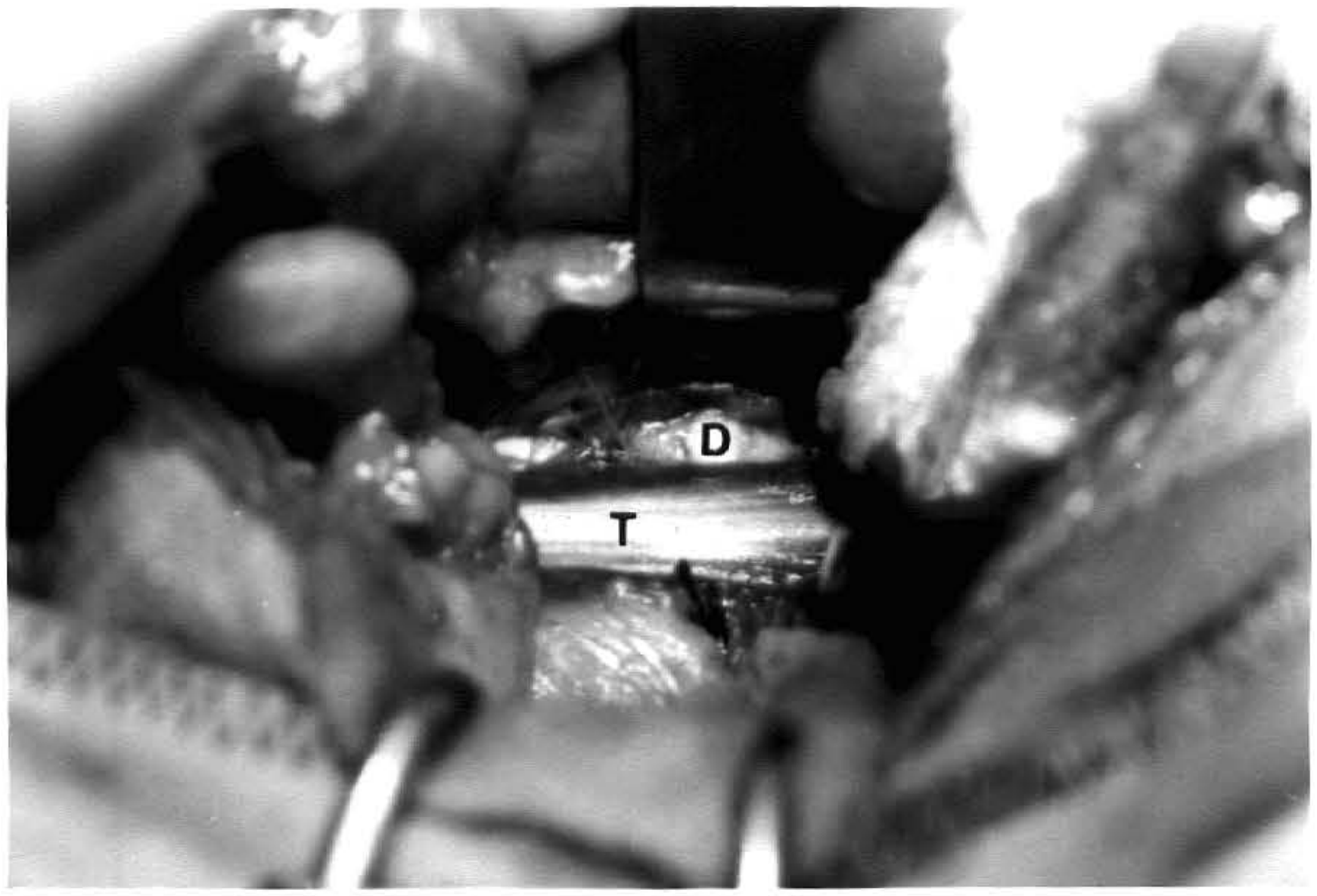

Figure 15: Tendon of the psoas minor muscle (T); ventral surface of an intervertebral disc (D).

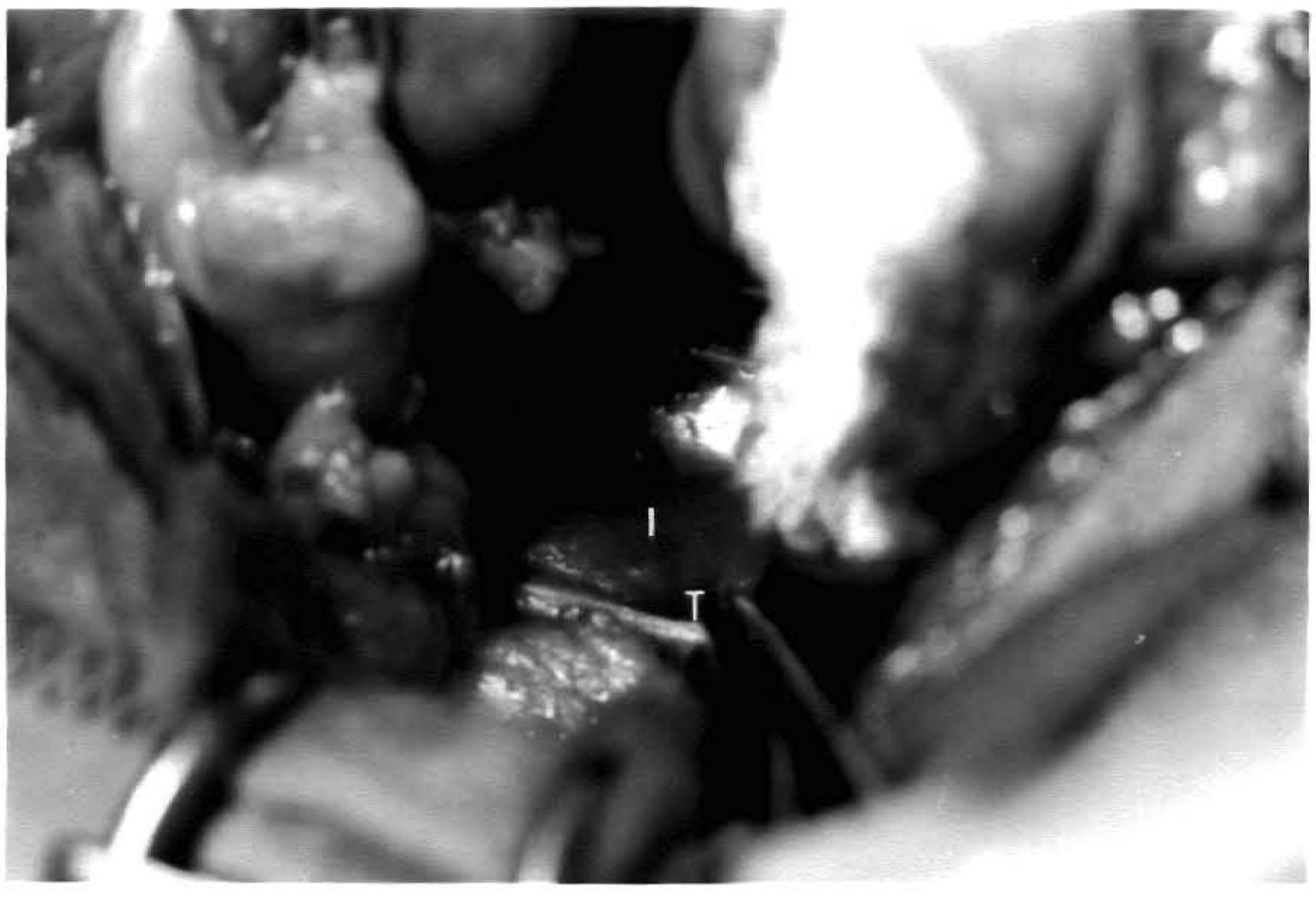

Figure 16: Tendon of psoas minor muscle retracted laterally (T) to expose the body of the iliopsoas muscle (I).

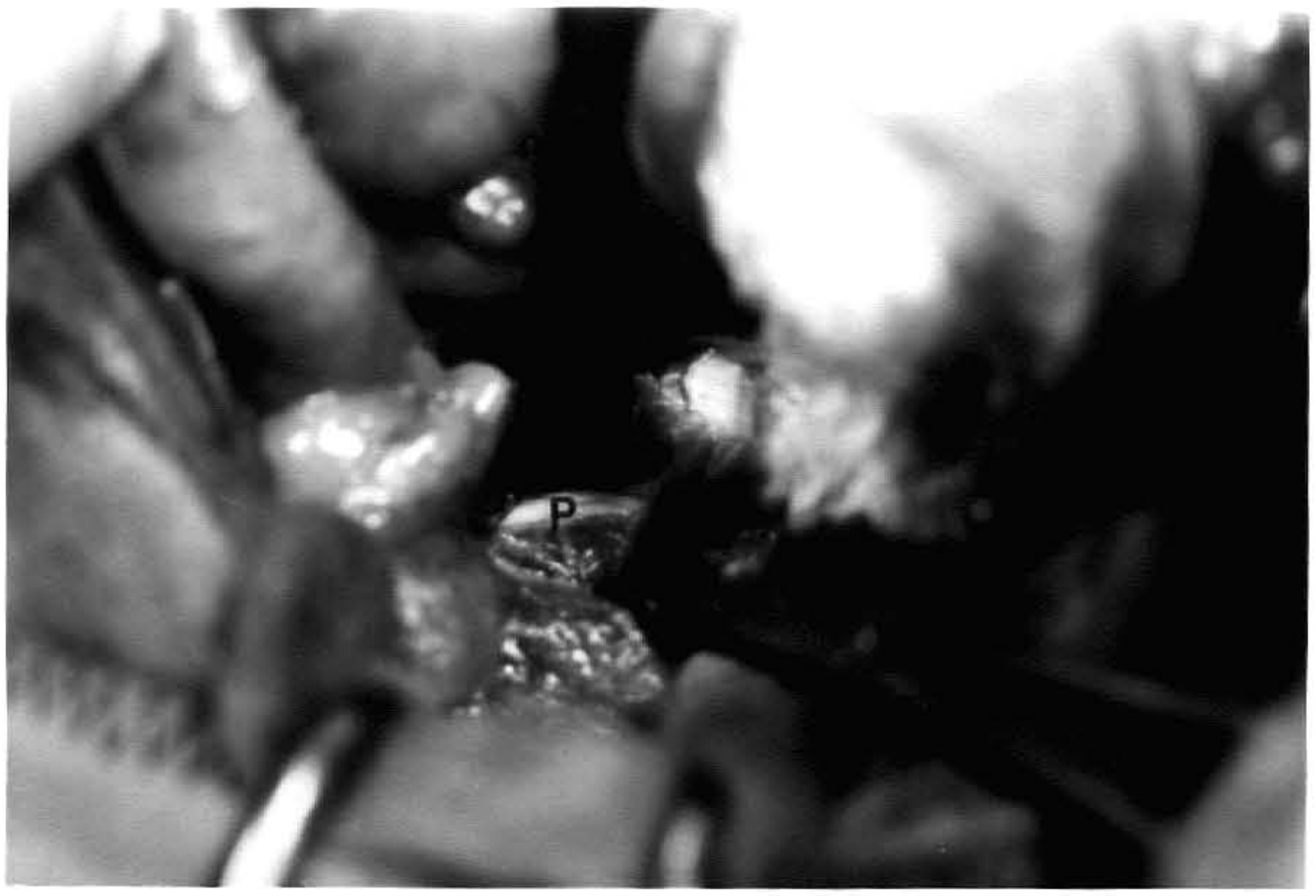

Figure 17: Beginning dissection down to the lumbosacral plexus (P).

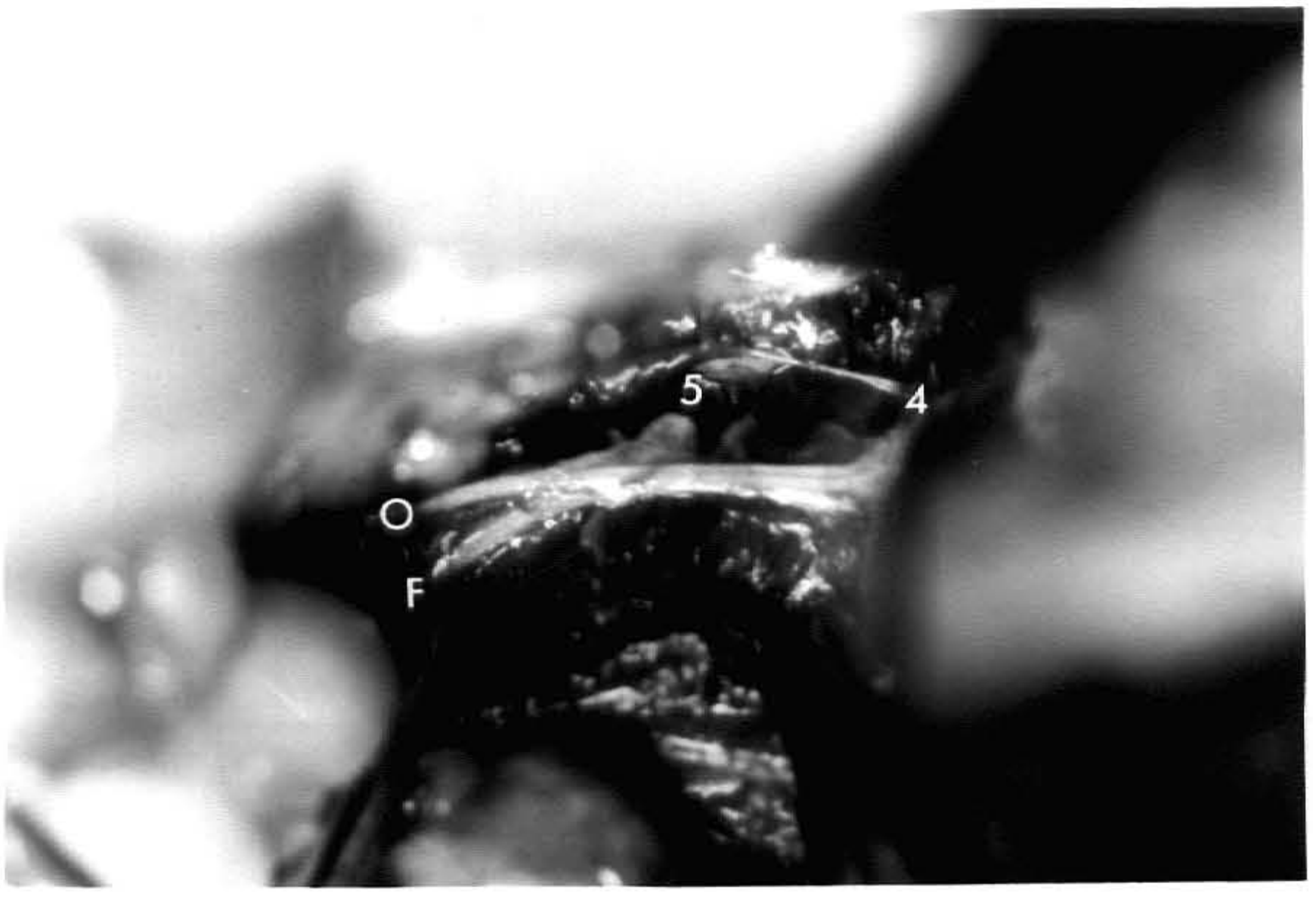

Figure 18: Resultant exposure: Ventral ramus of L_4 (4), ventral ramus of L_5 (5), femoral nerve (F), obturator nerve (O).

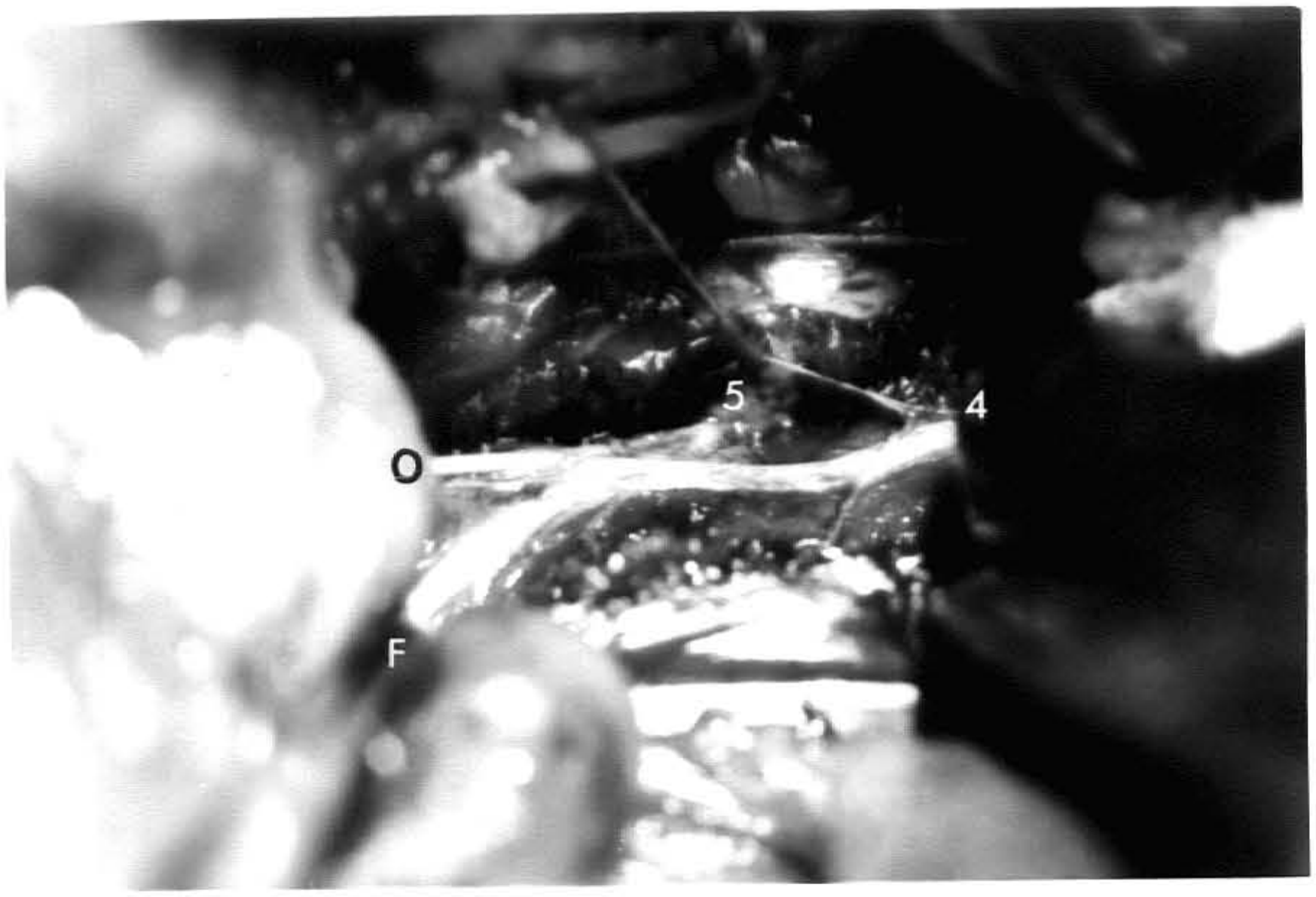

Figure 19: Resultant exposure: Ventral ramus of L_4 (4), ventral ramus of L_5 (5), femoral nerve (F), obturator nerve (O).

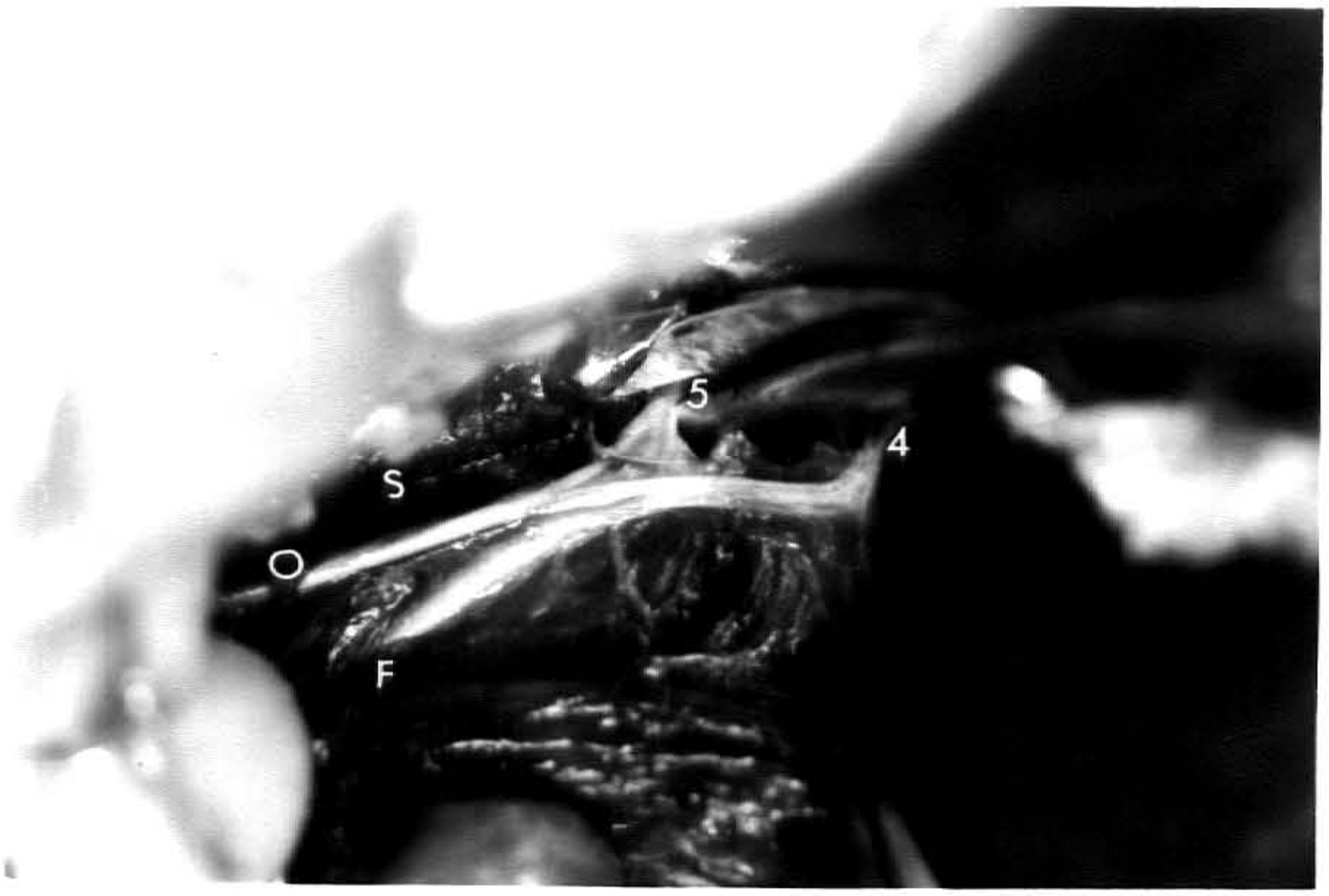

Figure 20: Resultant exposure: Ventral ramus of L_4 (4), ventral ramus of L_5 (5), femoral nerve (F), obturator nerve (O), position of sciatic nerve (S).

routine manner for aseptic surgery. Surgical position was dorsal recumbency. The surgical procedure previously described as the ventral approach was then performed. A routine abdominal closure followed (Annis and Allen, 1967; Archibald, 1965; Leonard, 1968).

Study Groups

A total of twenty-seven dogs of mixed age, breed, sex and weight was used in this phase of the study. The specific number of dogs used in each group was as follows: group I, the pilot group, eight dogs; group II, four dogs; group III, six dogs; group IV, five dogs; and group V, four dogs. Each successive group used the data gained from the previous group as a basis and either confirmed the results seen using a different method or added more specific data to the observed results. The actual design for each successive group depended completely upon the results of the preceeding group.

Group I was the initial pilot study group. It consisted of eight dogs of random breed, age, sex and weight. It was divided into two subgroups, the purpose of which will be explained when the actual surgical protocol is described.

The group that was denoted I_A consisted of one-half of the number of dogs from group I. Each dog was subjected to the standard surgical approach and the bilateral lumbosacral plexuses exposed. The contribution

---

[a] Surital, Parke Davis & Co., Detroit, Michigan

[b] Fluothane, Ayerst Laboratories Inc., New York, New York

[c] Metofane, Pitman-Moore, Inc., Washington Crossing, New Jersey

of one ventral ramus to the lumbosacral plexus was then severed bilaterally: dog I_A1, L_4; dog I_A2, L_5; dog I_A3, L_6; dog I_A4, L_7. Group I_A would therefore evaluate what, if any, deficit would result from loss of the nervous supply of a single ventral ramus to the lumbosacral plexus.

The group that was denoted I_B consisted of the remaining dogs from group I. Each dog was subjected to the standard surgical approach and the bilateral lumbosacral plexuses exposed. In these dogs the contributions of all ventral rami to the lumbosacral plexus were severed bilaterally except for the contribution of one ventral ramus: dog I_B1, all except L_4; dog I_B2, all except L_5; dog I_B3, all except L_6; dog I_B4, all except L_7. Group I_B would therefore evaluate what, if any, functions would remain with only that ventral ramus intact.

Examination of group I was identical and consisted of evaluation of the following over a sixty hour period: 1) muscle strength 2) gait 3) stance 4) muscle fasciculations 5) the patellar tendon and achilles tendon reflexes 6) flexor reflexes. After the final examination the dogs were euthanized and the severed and intact ventral rami confirmed by gross dissection.

Group II consisted of four dogs of random breed, age, sex and weight. All the dogs in this group were subjected to the standard surgical approach and the bilateral lumbosacral plexuses exposed. In each dog the ventral ramus of L_5 was severed on one side and the ventral rami of L_4 and L_6 severed on the opposite.

The patellar tendon reflex was examined bilaterally on all dogs twelve, thirty-six and sixty hours after surgery. Following the last examination the dogs were euthanized and the severed ventral rami confirmed by gross dissection.

Group III consisted of six dogs of random breed, age, sex and weight. Three dogs had the identical procedure performed as the dogs in group II. The remaining three dogs were subjected to the standard surgical approach; only in these one lumbosacral plexus was exposed but no nerve transections were performed. These dogs were then denoted as the sham surgical procedures.

The patellar tendon reflex was evaluated bilaterally throughout the holding period of these dogs. At the end of seven, twenty-one and forty-two days, one sham surgical procedure and one dog in which nerve transections were performed were euthanized. The ventral rami severed and intact were confirmed at necropsy. Both lumbosacral plexuses, the lumbar spinal cord and the following muscles from each dog were removed for histologic examination: tensor fascia lata; quadriceps femoris, sartorius; biceps femoris; semimembranosus; semitendinosus; adductor magnus et brevis; and gracilis.

All muscles were removed in entirety and stored in a humid chamber at room temperature for six hours. A one-centimeter square section was then taken in the direction of the muscle fibers and placed in 10 per cent neutral buffered formalin to fix for several days. Samples were then embedded in paraffin and slides prepared of both longitudinal and cross sections taken at six microns.

The dura of the lumbar spinal cord was incised the full length to afford better penetration of the fixative and then it, together with both lumbosacral plexuses, was placed in 10 per cent neutral buffered formalin to fix. After two days, one-half centimeter thick cross sections were made of all nervous tissue and these were then allowed to fix for an additional five days. Following this seven day fixative period they were embedded in paraffin and slides prepared of sections taken at six microns.

All prepared slides were stained with hematoxylin and eosin. Examination was under the light microscope.

Group IV consisted of five dogs of random breed, age, sex and weight. All dogs were subjected to the identical surgical procedure as followed in group II. Euthanasia was then performed on all dogs after a set postoperative time: two dogs at sixty-one days; two dogs at fifty-four days; and one dog at forty-six days. The ventral rami severed and intact were confirmed by gross dissection at the time of necropsy. Both lumbosacral plexuses, the lumbar spinal cord, and the following muscles were removed from each dog: tensor fascia lata; biceps femoris; quadriceps femoris; and cranial and caudal bellies of the sartorius. Weights were taken of all muscles separately except for the four heads of the quadriceps femoris and the cranial and caudal bellies of the sartorius, which were each weighed as a combined muscles group; i.e. quadriceps femoris or sartorius. All removed tissues were then saved for histologic examination and handled as were those taken from the dogs in group III.

Group V consisted of four dogs of random breed, age, sex and weight. All food was withheld twelve hours prior to study. The animals were then premedicated with .04 mg/lb. atropine sulfate administered subcutaneously and induced with sodium pentobarbital[d], given to effect. To insure a patent airway intubation was performed. The dorsal area over the lumbar vertebrae was then prepared in a routine manner for surgical approach. To insure exact knowledge of the numbering of the lumbar vertebrae, a small diameter pin was placed through a selected dorsal spinous process. A lateral radiograph confirmed the exact placement of the pin. This pin was then used as a reference point in vertebral identification. The animal was positioned in ventral recumbency and a patent intravenous route maintained for administration of additional sodium pentobarbital as the surgical plane of the animal warranted (figures 21 through 28).

---

[d] Nembutal, Aboott Laboratories, North Chicago, Illinois

The lumbar spinal cord within lumbar vertebral bodies 4, 5 and 6 was exposed using technique A as described by Funkquist and Schantz (1962). The dorsal and ventral roots of L_5 were isolated bilaterally. The patellar tendon reflex was examined, the dorsal root on one side and the ventral root on the opposite side severed and the patellar tendon re-examined.

Euthanasia was performed on all dogs immediately after the surgical procedure and the level of the severed roots confirmed by gross dissection.



Figure 21: Surgical position.

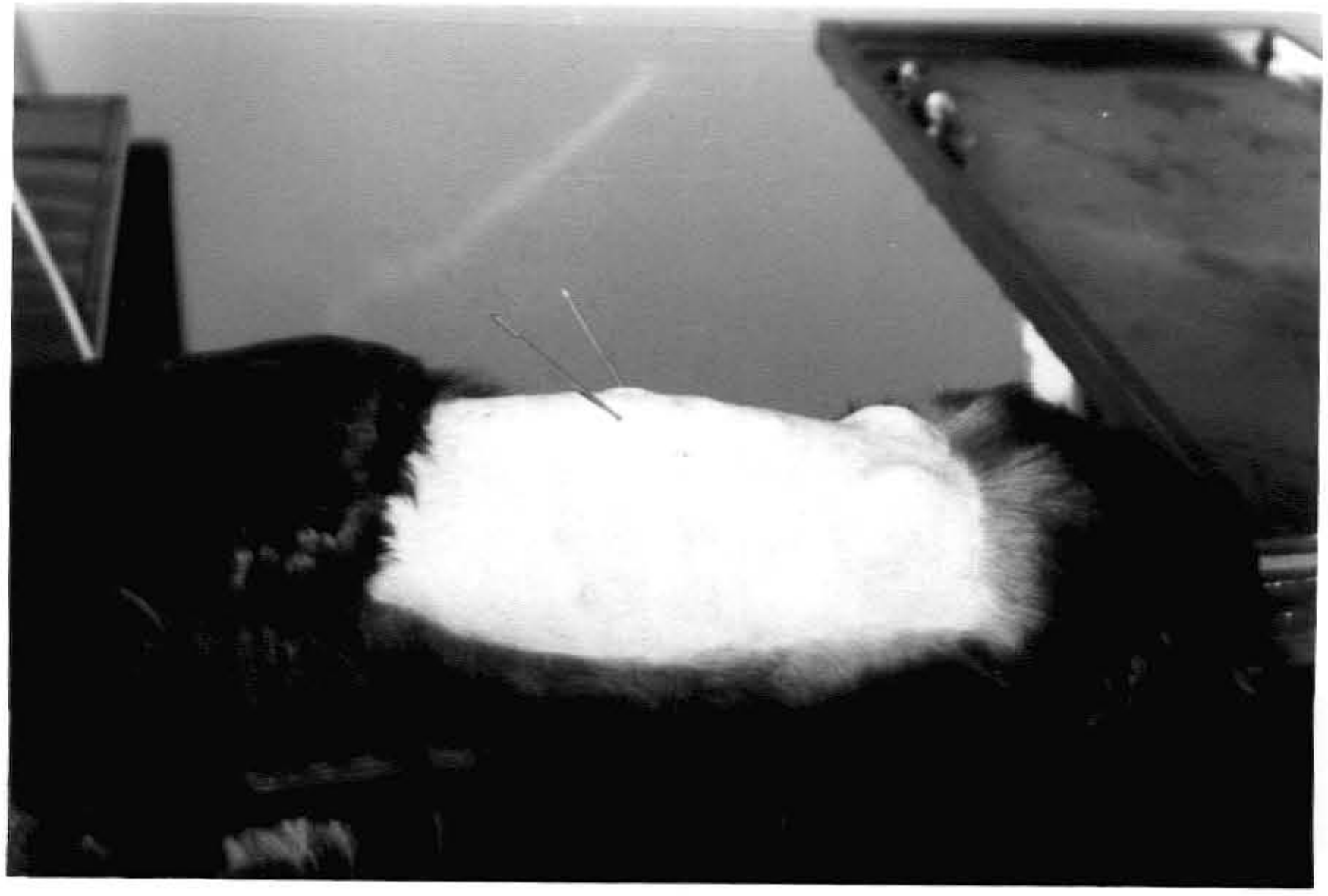

Figure 22: Prepared area.

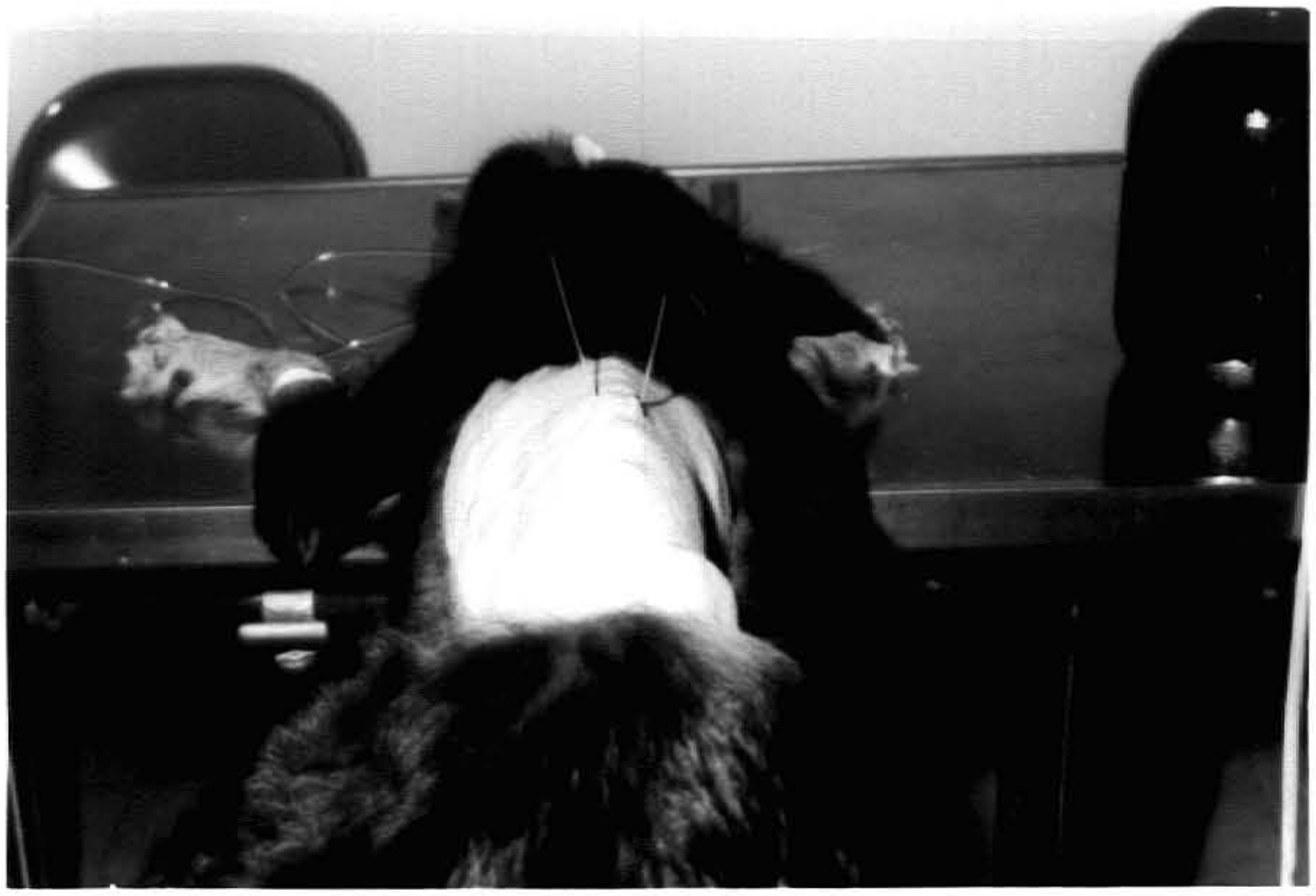

Figure 23: Note marker pin through dorsal spinous process.

Figure 24: Reflexes easily tested even during surgical procedure.



Figure 25: Severed dorsal root (arrow); intact ventral root (V).



Figure 26: Close-up of figure 25.

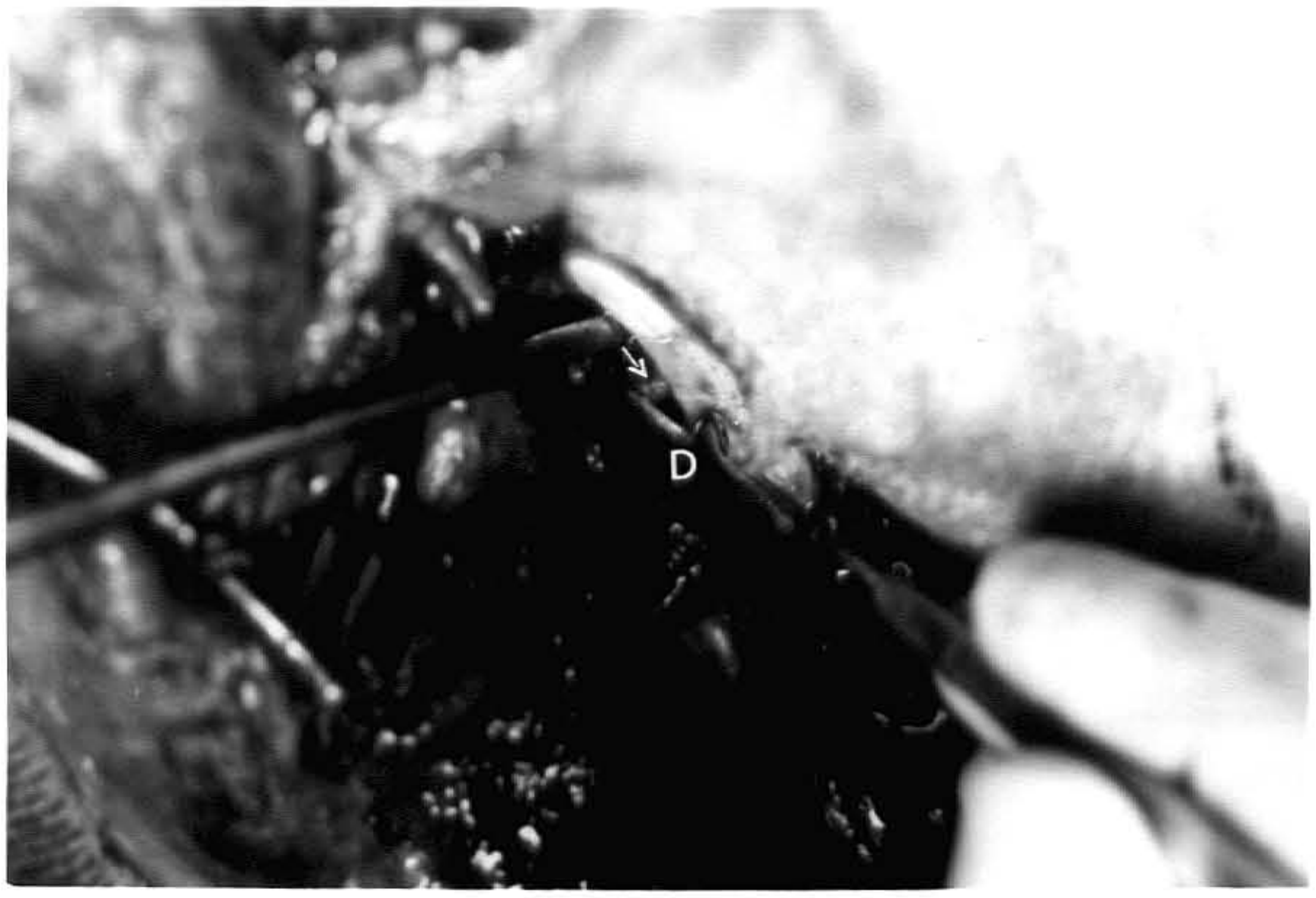

Figure 27: Severed ventral root (arrow); intact dorsal root (D).

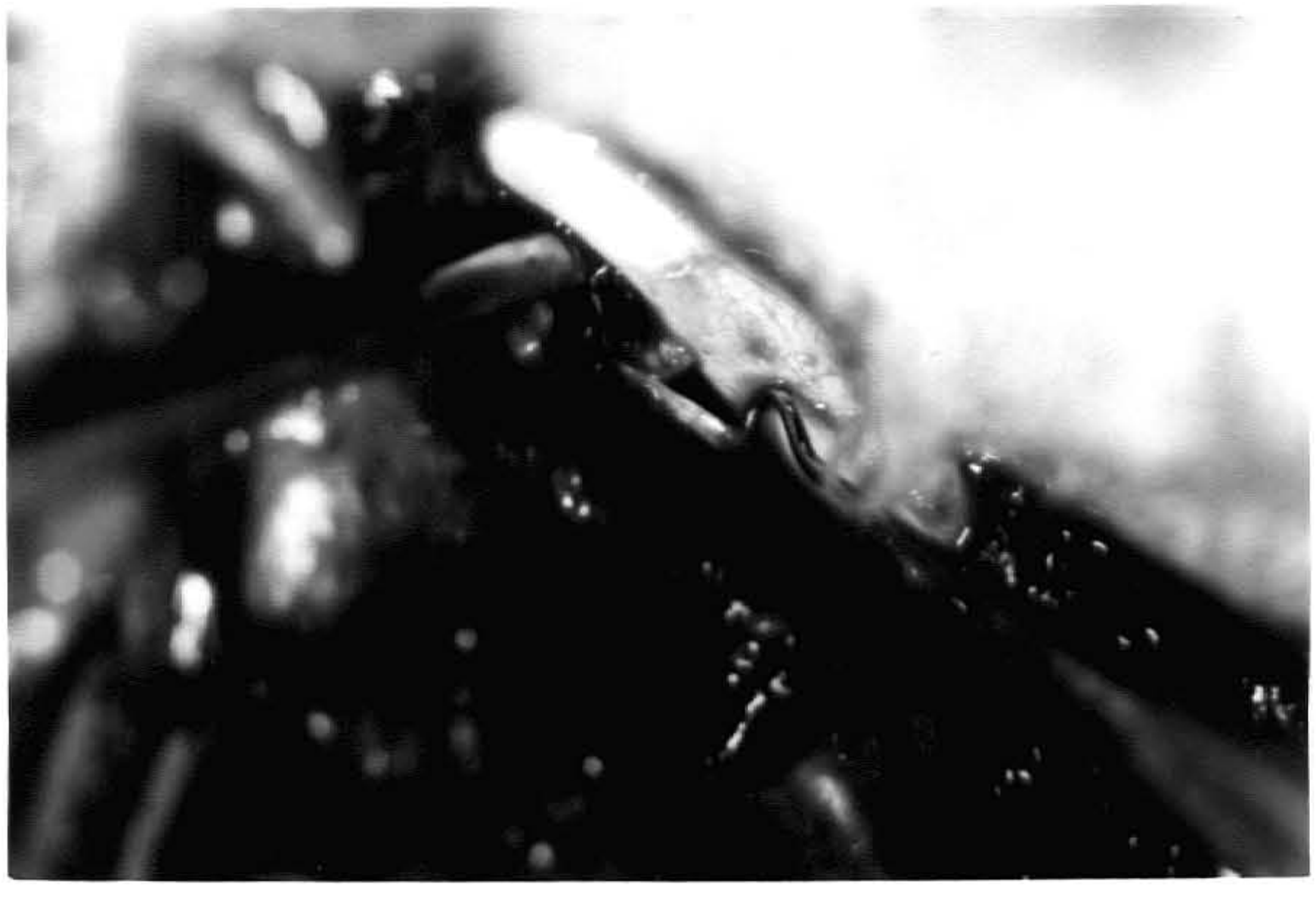

Figure 28: Close-up of figure 27.

RESULTS

Surgical Procedure

Attempts to surgically approach the lumbosacral plexus through a dorsal or a lateral incision were equally met with failure. The surgical procedure in either case was extremely difficult, large muscle masses required retraction, excessive hemorrhage was a constant problem, surgical trauma was severe, visibility of the plexus proved to be poor and identification of exact ventral rami levels was difficult. Specific problems encountered with each approach will not be dwelt with.

The ventral approach proved to be an excellent exposure. The major abdominal organs retracted easily. Only one major vascular bundle (circumflex iliac artery and vein) was encountered and this was easily divided between ligatures. Dissection into the belly of the iliopsoas muscle was simple since the muscle fibers run essentially parallel to the major nerve trunks. Resulting exposure was phenomenal. The entire plexus from the ventral rami of L_4 to that of L_7 including the femoral, obturator and sciatic nerves could then be visualized altogether at one time. Identification of exact spinal levels was precise allowing for accurate selective transection of individual ventral rami.

Study Groups

Group I was the initial pilot study. In it, the achilles tendon reflex proved to be a poor criteria to evaluate because its elicitation was not consistent among normal dogs nor was it consistent among the dogs of group I examined before being surgically approached. The examination for muscle fasciculations postsurgically was also unrewarding; none ever being noted. The findings of the remaining criteria examined are given in Table I.

Changes in muscle strength and gait or stance were noted in all dogs. Varying degrees of extensor weakness resulting in a more flexed position to the stifles were noted in those dogs in which L_4 or L_5 ventral ramus was severed. Severing L_6 or L_7 resulted in weakness in the flexor muscles with the dogs showing a straighter, more extended stifle. Severe muscle weakness with no ability to bear weight, knuckling over of the rear paws, inability to initiate stepping motions and general uselessness of the legs was seen when all ventral rami except L_4 or L_7 were severed. This was not true, however, when L_5 or L_6 was the only intact ventral ramus. That dog in which all rami except L_5 were severed still retained some weight bearing. Although the stifles were extremely over extended and no stepping motions were ever noted, the legs would support the body if supported laterally. The dog in which all rami except L_6 were severed was the best animal clinically. Although its stance was extremely crouched, actual walking was possible. A very noticeable fact was that the dog was able to "dig in" with its claws when it attempted to get a good footing.

Evaluation of the flexor reflex was difficult but several things were noted. Single ventral ramus deletions never affected the ability to withdraw the limb to any noticeable degree. Loss of L_5, L_6 and L_7 ventral rami severly reduced this response. With only L_6 or L_7 present, the flexor reflex was still strong, with the possibility of hock flexion being lost when only L_7 was intact. With only L_5 intact, the dog responded to noxious stimulation with flexion of the hip and extension of the stifle.

In all those dogs in which the ventral ramus of L_5 was intact, either alone or together with other rami, the patellar tendon reflex was present. All those dogs in which L_5 was severed, even in that animal in which only L_5 had been severed, had no patellar tendon reflex.

Group II was designed to test the possible connection of the ventral ramus of L_5 with the patellar tendon reflex. The results of the four dogs in which the ventral ramus of L_5 was severed on one side and L_4 and L_6 on the opposite side are presented in Table II. The findings of all dogs were identical. The side in which L_5 had been severed had no patellar tendon reflex while the side in which L_4 and L_6 had been severed still exhibited this reflex. If the reflex was absent, it was completely absent. If present, it was so in a normal fashion. At no time was hyper- or hyporeflexia noted. All findings were consistent over the three examinations for each dog.

Group III was a long term examination of the effect of the procedure used in group II on the patellar tendon reflex. In conjunction, all dogs were examined for evidence of neurogenic muscle pathology. Sham surgical procedures served as controls. The clinical findings of the dogs used in this group are presented in Table III. The patellar tendon reflex was never affected at any time in the sham surgical procedure dogs. Those dogs which had surgery performed as in group II showed loss of patellar tendon reflex on that side on which the ventral ramus of L_5 had been severed and a normal reflex on that side on which L_4 and L_6 were severed. At no time was hypo- or hyperreflexia noted in those reflexes present. They were the same at the time of euthanasia as they were immediately after surgical recovery. And if the reflex was absent, it was completely so and did not improve on a dog even up to the maximum holding period of fifty-one days.

All nerve transections were confirmed at the time of euthanisia by gross examination and removal of the lumbosacral plexus. A typical removed lumbosacral plexus is illustrated in figure 29. On short term postoperative examinations, the physical separation of the rami was visible. After a considerable holding period, it was possible to identify those rami severed by the intense reaction present at the transection sites. All necropsy findings were identical to the intended surgical transections.

Signs of neurogenic atrophy were never noted in the muscles removed from the sham surgical procedure dogs at five, twenty-three and forty-two days postoperative. Neither were signs of neurogenic atrophy noticeable in muscles removed from that dog that had surgical nerve transections performed eight days prior to euthanasia. In that dog examined twenty-five days after surgery, histologic findings compatible with neurogenic atrophy were seen in the semimembranosus and adductor magnus et brevis muscles removed from the side on which the ventral rami of L_4 and L_6 had been severed, and, in the sartorius and gracilis muscles removed from the side on which L_5 had been severed. This atrophy was most noticeable in cross sections. There was a lack of uniformity in the fibers. Some fibers appeared larger, more rounded than polygonal while other fibers appeared shrunken, such that a vacant halo surrounded the fiber. The degree and number of fibers showing these signs were extremely variable from fascicle to fascicle. In longitudinal section, the signs of atrophy were more subtle. Again certain fibers appeared swollen or shrunken in size. Further neurogenic atrophy was seen in that dog examined fifty-one days after surgical nerve transections. Histologic findings of neurogenic atrophy were seen in the tensor fascia lata and sartorius muscles removed from the side on which L_4 and L_6 had been severed and in the gracilis, quadriceps femoris and sartorius muscles removed from the side on which L_5 had been severed. The cross sectional lack of uniformity was more severe than that seen in the twenty-five day specimens. Many swollen and shrunken fibers were seen. Unlike the samples taken at twenty-five days, these atrophic fibers were easily seen in the longitudinal sections. In addition, many areas were seen in which the sarcolemmal nuclei were clumped together with little accompanying sarcoplasm. This gave the muscle a histologic appearance of being "stripped" or "banded".

Examination of the lumbosacral plexus and of the lumbar spinal cord was inconclusive. Peripheral nerve axonal degeneration and degenerative changes in the central alpha motor neurons were seen, however, identification of specific peripheral nerves, ventral rami or spinal cord levels was not accurate enough to correlate observed changes with the performed surgical procedures.

Group IV had one drop-out. The dog that was denoted as IV_4 developed chorea and was therefore removed from the study. Clinical evaluation of the patellar tendon reflexes was identical as seen previously except for the dog denoted as IV_1. In this dog the reflex on the side in which L_5 was severed was still present and normally so. At necropsy, however, it was found that L_5 had mistakenly not been severed as planned. All the remaining transections were confirmed.

Weights were taken of four specific removed muscle masses: the quadriceps femoris, the biceps femoris, the sartorius and the tensor fascia lata. These results are tabulated in Table IV. In all dogs, the weights of the biceps femoris, sartorius and tensor fascia lata muscles from one leg were identical to the weights from the opposite leg. The weight of a specific muscle did vary from dog to dog but never from one leg to the opposite. In two dogs this also held true for the quadriceps femoris muscles, however, in two dogs there was a difference. IV_1 had a 15 mg. heavier muscle mass on the right side (the L_5 transection which mistakenly was not made) as compared to the left side (severed L_4 and L_6). IV_5 had a 15 mg. heavier muscle mass on the right side (severed L_4 and L_6) as compared to the left side (severed L_5).

The combined bellies of the quadriceps femoris, the tensor fasica lata, the biceps femoris, the caudal belly of the sartorius and the cranial belly of the sartorius muscles were examined individually for histologic signs of neurogenic atrophy. The presence or absence of recognized atrophy in each muscle is tabulated in Table V. Muscles from the L_5 denervated side in which neurogenic atrophy was noted were as follows: All the quadriceps femoris muscles (except dog IV_1), all the cranial bellies of the sartorius muscles, and the biceps femoris muscle from dog IV_5. Those from the L_4 and L_6 denervated side were: All the tensor fascia muscles except dog IV_2, the biceps femoris muscle from dogs IV_1 and IV_2, all the caudal bellies of the sartorius muscles except dog IV_3, and the cranial bellies of the sartorius muscles from IV_1 and IV_5. The remaining muscles did not show these changes.

With regards to the ventral ramus(i) transected, time since transection and particular muscle involved, these results could be presented another way.

L_5 Atrophy was seen in the quadriceps femoris and the cranial belly of the sartorius muscles.

Quadriceps femoris muscles.

1) Uniform stages of atrophy were seen from forty-six to sixty-one postoperative days.
2) The most prominent feature was swollen fibers. There was little degeneration and little fat.
3) Changes seemed to be confined to certain areas of the muscle. They definitely were not uniformily distributed.

Cranial belly of the sartorius muscles.

1) Changes appeared to be progressive and localized.
2) Many swollen fibers and some degeneration were seen at forty-six days. At fifty-four days one large area of degeneration and extensive fat deposits was seen. At sixty-one days swollen fibers were again seen while degeneration and fat were less prominent.

L_4 and L_6 Atrophy was seen in the tensor fascia lata, biceps femoris and both bellies of the sartorius muscles.

Tensor fascia lata muscle.

1) Changes were either progressive or localized.
2) At forty-six days atrophy and degeneration were seen of the left side of the slide. Extensive atrophy, degeneration and fat deposits were seen throughout the muscle at fifty-four days. At sixty-one days, atrophy and fat were minimal.

Biceps femoris muscle.

1) Atrophy was not seen until sixty-one postoperative days.
2) Changes consisted of random but sparse swollen fibers, minimal degeneration and no fat.

Sartorius muscle.

1) Changes were seen in both bellies.
2) Changes in the cranial bellies were less severe than those seen in the caudal. Random swollen fibers were seen in two dogs at forty-six and sixty-one days but not in the other two dogs at fifty-four and sixty-one days.
3) Changes in the caudal bellies consisted of atrophy, degeneration and fat seen at forty-six days and moderate degeneration and fat seen in one dog at sixty-one days but only very little seen in the other dog.

The histologic appearance of the variation in fiber diameter seen in the early phases of neurogenic atrophy is shown in figure 30. Once fat infiltration began it appeared as shown in figure 31.

The lumbosacral plexuses showed extensive histologic evidence of fibrous tissue invasion and "scar" formation at the site of the ventral rami transections (figure 32). This was not seen at those rami left intact. Axonal degeneration as seen under H & E staining was not remarkable in the individual peripheral nerves. The spinal cord showed signs of degeneration within the large -motor neurons on that side associated with a ventral ramus transection. The cells effected characteristically stained heavier, the Nissel substance within the cell body became less distinct while the nucleus stained more intensely with accompanying loss of the enclosed nucleoli. Around these dying neurons congregated an increased number of glial cells (figure 33).

Group V was the final group of dogs studied. After the spinal cord was surgically approached through a dorsal laminectomy, the individual dorsal and ventral roots of L_5 were isolated bilaterally and the dorsal root severed on one side and the ventral root severed on the opposite side. The resulting effect upon the patellar tendon reflex is tabulated in Table VI. Severing the dorsal root of L_5 abolished the reflex as far as could be determined under the examining conditions while severing the ventral root produced hyporeflexia. This held true in all four dogs except in dog V_3 in which the dorsal root of L_5 was avulsed while attempting to sever the ventral root. This dog had no reflex present on that side as could be expected.

TABLE I

RESULTS OF GROUP I

Ventral Ramus(i) Severed	Patellar Tendon Reflex	Flexor Reflex	Evaluation of Gait, Stance and Muscle Strength
4	Normal	Normal	Slightly flexed at the stifles; legs mildly weak.
5	Absent	Normal	Walks and stands in severely flexed position at the stifles; extreme difficulty bearing weight on extended stifles; stifles tend to rotate out.
6	Normal	Normal (may be out in hock)	Walks and stands with overly extended stifles; legs cross occasionally when walking; no knuckling over of the rear paws.
7	Normal	Normal	Tends to toe out slightly; mild muscle weakness; no knuckling over of the rear paws.
5, 6, 7	Absent	Only in hip.	No ability to bear weight; biceps and quadriceps muscles are flaccid; rear paws will knuckle over.
4, 6, 7	Normal	Flexion of hip; extension of stifle	Over extension of the stifles; can bear weight if supported laterally; no stepping; paws will knuckle over.
4, 5, 7	Absent	Strong	Walks in an extremely flexed position with the stifles rotated out; no knuckling over of the rear paws; uses claws.
4, 5, 6	Absent	Present in hip and stifle; not in hock.	Cannot support weight; no stepping; no use of the claws; drags legs; knuckles over on rear paws.

TABLE II

RESULTS OF GROUP II

Subject	Procedure	Patellar Tendon Reflex
II_1	R5 * L4, 6	Absent Normal
II_2	R4, 6 L5	Normal Absent
II_3	R4, 6 L5	Normal Absent
II_4	R5 L4, 6	Absent Normal

*R or L denotes right or left plexus
4, 5 or 6 denotes ramus(i) severed

TABLE III

CLINICAL RESULTS OF GROUP III

Subject	Procedure	Length of Observation	Patellar Tendon Reflex
III_1	RS * LN	5 days	Normal Normal
III_2	L5 R4, 6	8 days	Absent Normal
III_3	LS RN	23 days	Normal Normal
III_4	L5 R4, 6	25 days	Absent Normal
III_5	LS RN	42 days	Normal Normal
III_6	R4, 6 L5	51 days	Normal Absent

*R or L denotes right or left plexus
S denotes sham surgical procedure
N denotes not approached surgically
4, 5 or 6 denotes ramus(i) severed

TABLE IV

WEIGHTS OF MUSCLES REMOVED FROM GROUP IV

Subject	Procedure	Quadriceps Femoris	Sartorius	Biceps Femoris	Tensor Fascia Lata
IV$_1$	R5 *	140 mg.	40 mg.	120 mg.	40 mg.
	L4, 6	125	40	120	40
IV$_2$	R4, 6	120	40	100	40
	L5	120	40	100	40
IV$_3$	R5	150	60	150	40
	L4, 6	150	60	150	40
IV$_5$	R4, 6	95	20	90	20
	L5	80	20	90	20

*R or L denotes right or left plexus
4, 5 or 6 denotes ventral ramus(i) severed

TABLE V

NEUROGENIC ATROPHY OF MUSCLES

Subject	Procedure	Quadriceps Femoris	Sartorius	Biceps Femoris	Tensor Fascia Lata
IV$_1$	R5 *	Normal	Cranial	Normal	Normal
	L4, 6	Normal	Both	Atrophy	Atrophy
IV$_2$	R4, 6	Normal	Caudal	Atrophy	Normal
	L5	Atrophy	Cranial	Normal	Normal
IV$_3$	R5	Atrophy	Cranial	Normal	Normal
	L4, 6	Normal	Normal	Normal	Atrophy
IV$_5$	R4, 6	Normal	Both	Normal	Atrophy
	L5	Atrophy	Cranial	Atrophy	Normal

*R or L denotes right or left plexus
4, 5 or 6 denotes ventral ramus(i) severed

TABLE VI

RESULTS OF GROUP V

Subject	Procedure	Patellar Tendon Reflex
V_1	RD * LV	Absent Weak
V_2	RD LV	Absent Weak
V_3	-- ** LD	 Absent
V_4	RV LD	Weak Absent

*R of L denotes right or left side
D denotes severed dorsal root
V denotes severed ventral root

**The dorsal root was avulsed in attempting to isolate the ventral root.

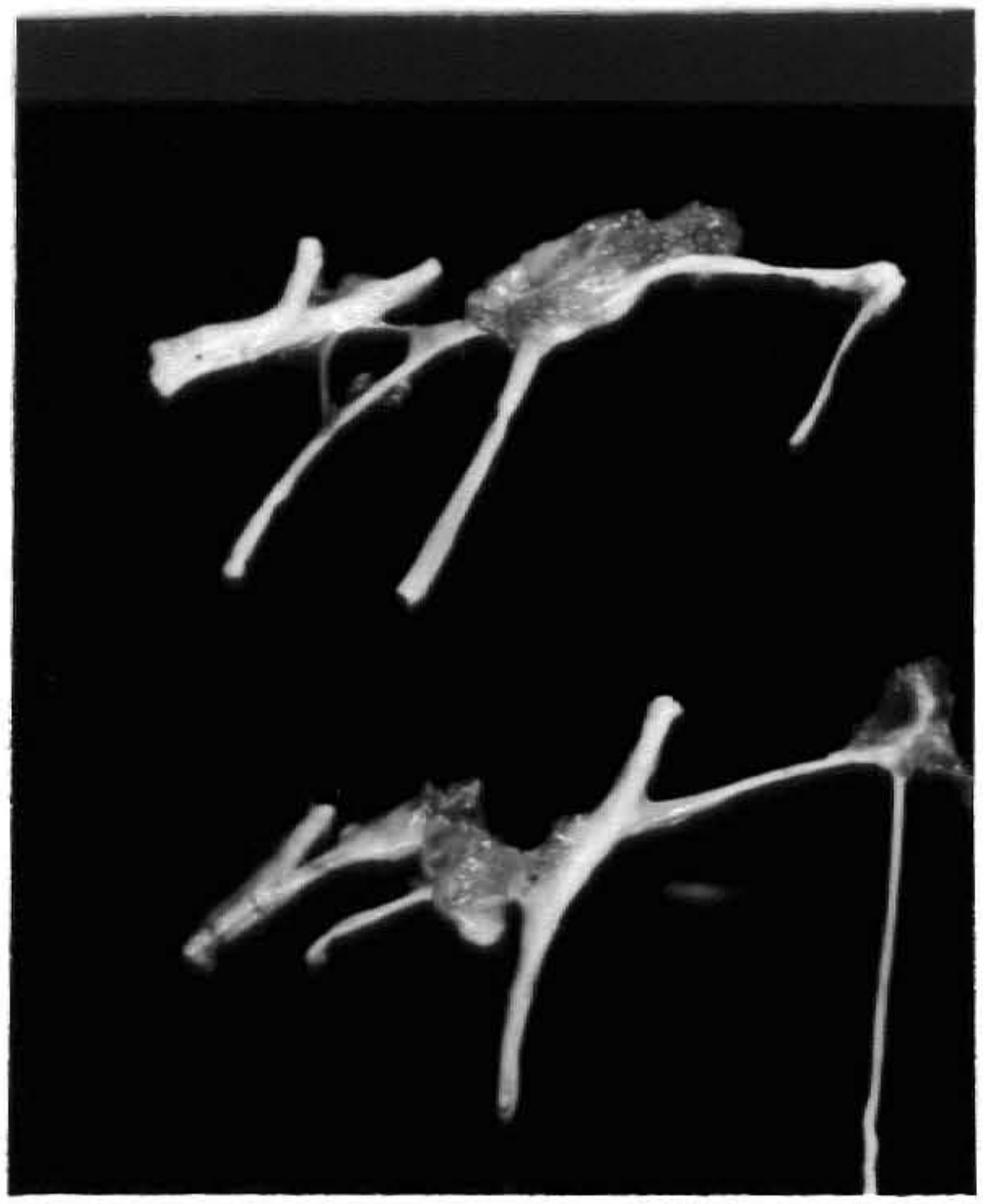

Figure 29: Bilateral plexuses removed from a dog 25 days after nerve transections. Notice the intense reaction around the severed ventral ramus of L_5 on the top plexus and around the rami of L_4 and L_6 on the bottom plexus.

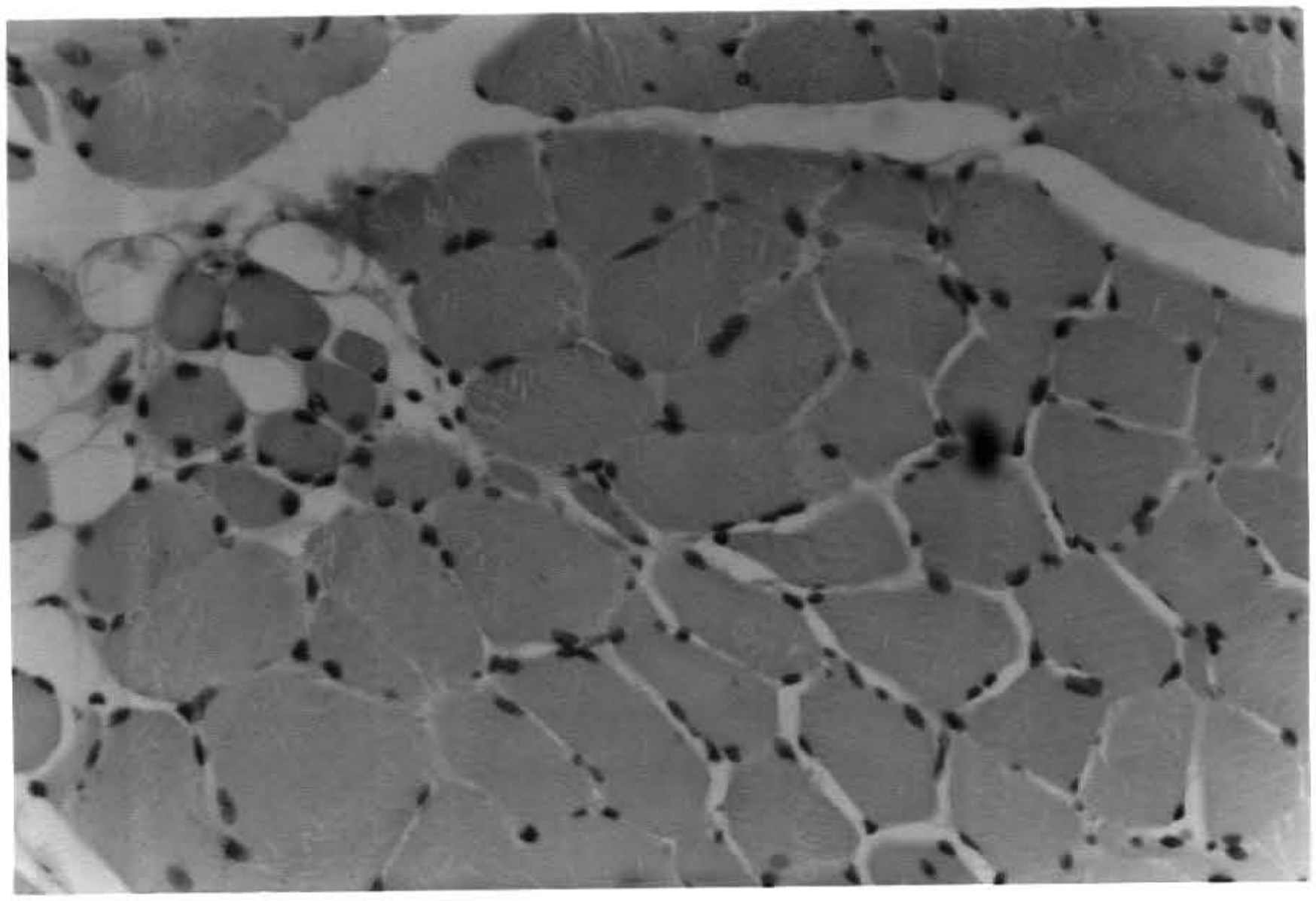

Figure 30: Note the small muscle fibers in the upper right seen in neurogenic atrophy.

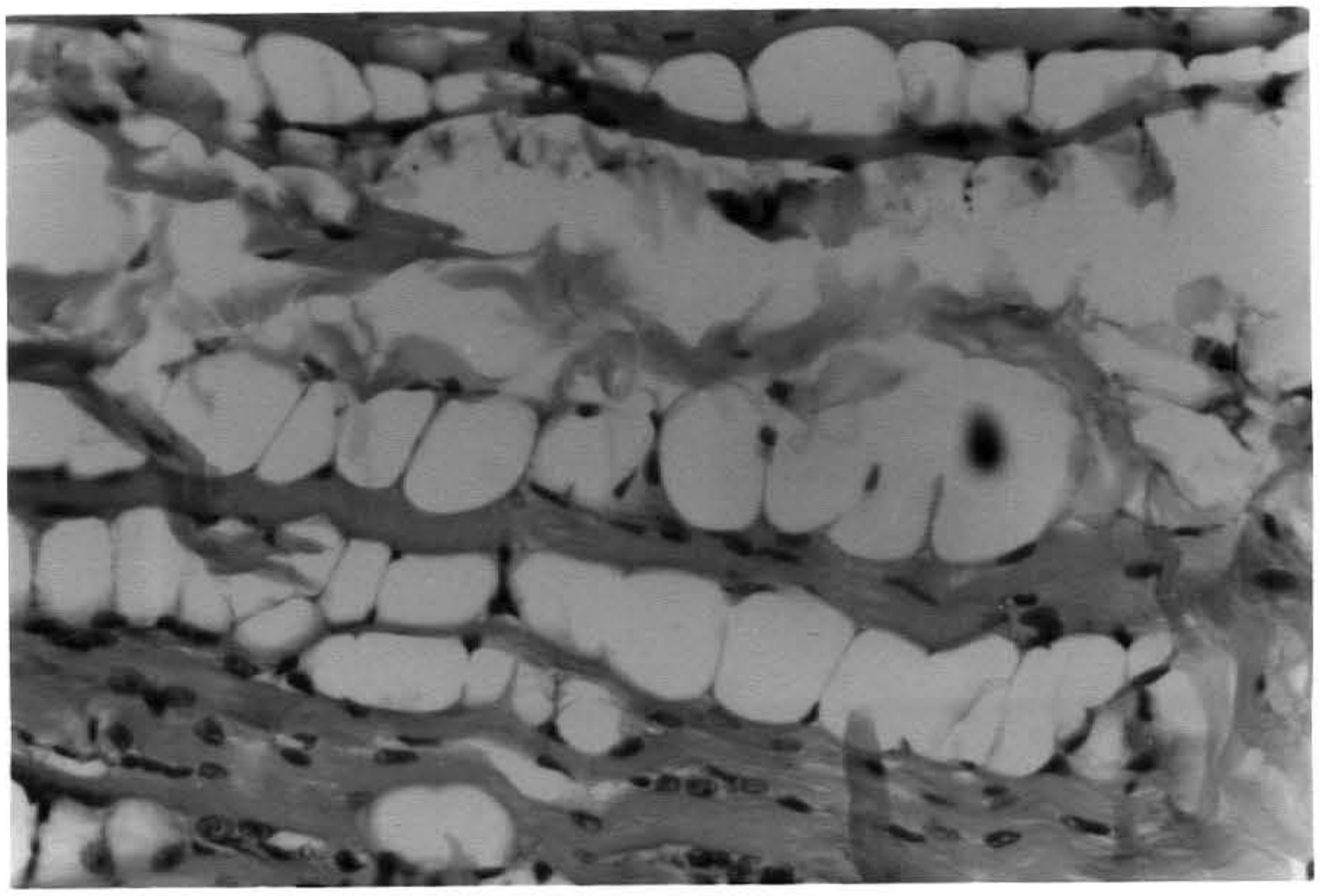

Figure 31: Appearance of fat deposits in neurogenic atrophy.

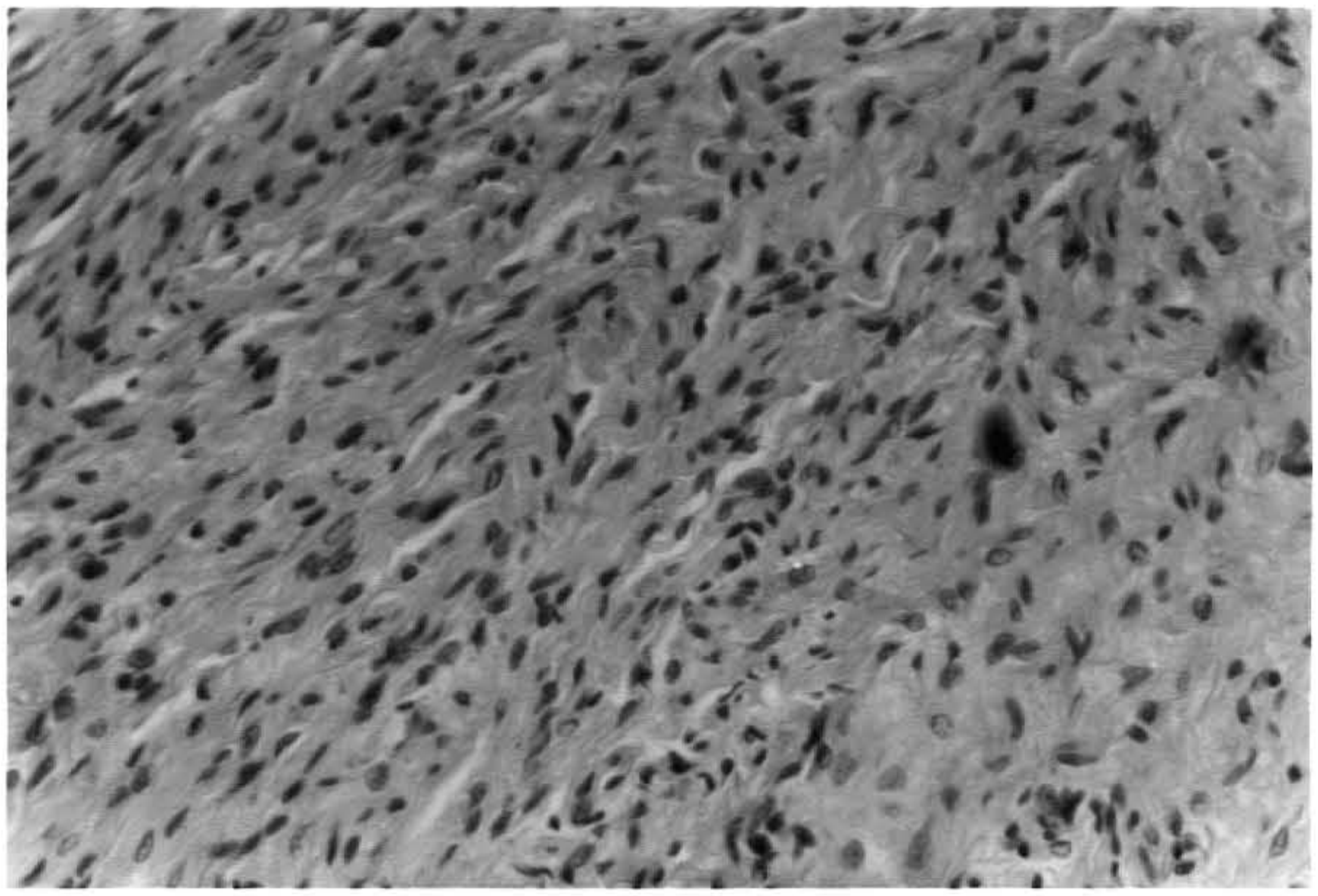

Figure 32: Histologic scar at the site of a ventral ramus transection after forty-six days.

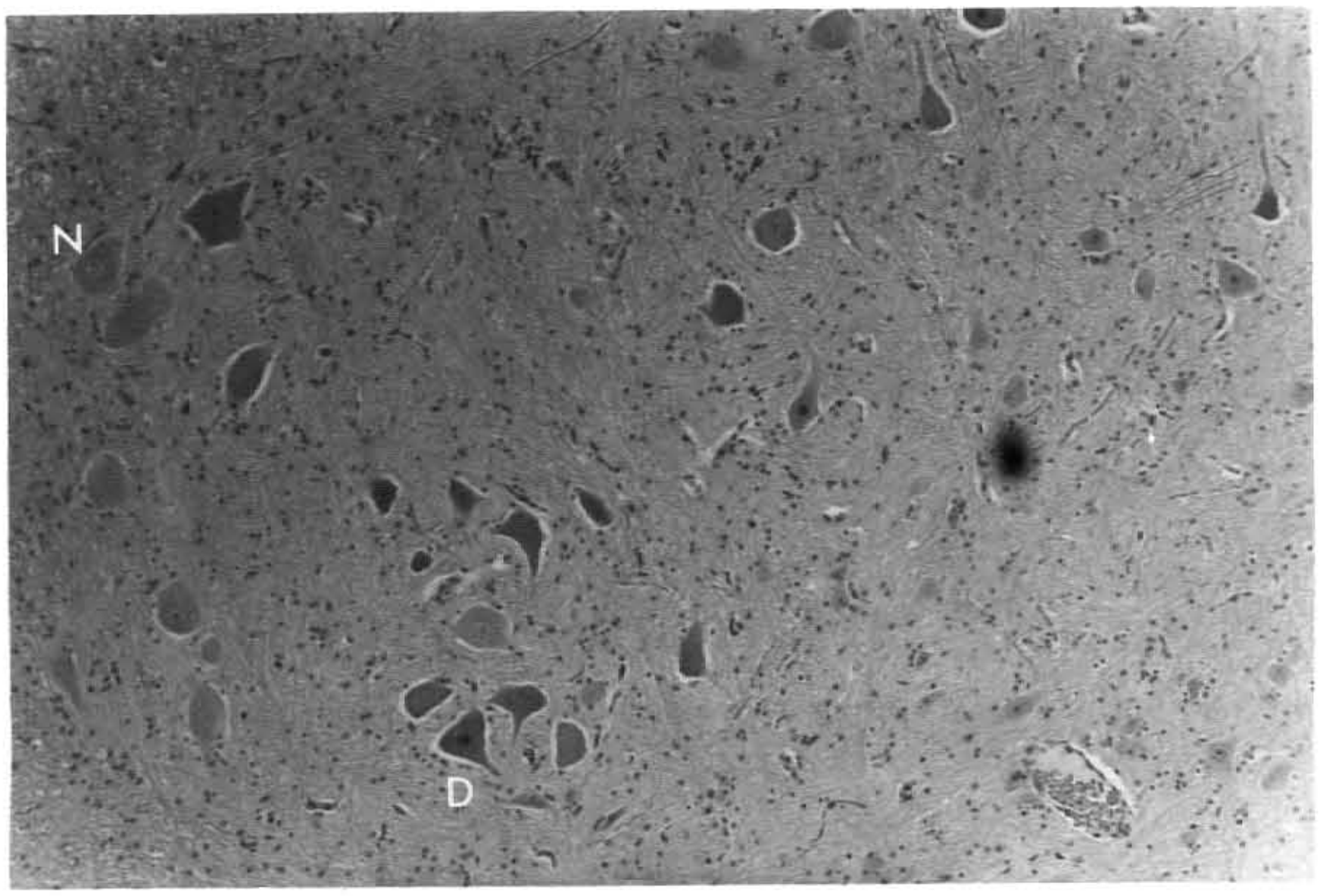

Figure 33: Ventral horn cells associated with a ventral ramus transection after forty-six days. (N) normal, (D) degenerating.

DISCUSSION

Fletcher and Kitchell (1966) state that there is variability to the intravertebral position of specific spinal cord segments and supply statistical evidence to back their statement. The "Bible" of canine anatomy (Miller _et al_., 1964) does not indicate this variability. They, however, quote the work of Fletcher and Kitchell and, in fact, use diagrams from that work to illustrate spinal positioning. The existence of this variability will therefore be taken as fact and considered an oversight on the part of Miller _et al_.

Arey (1965) is a valuable source of basic knowledge concerning embryology. He confirms that myotomes are specific masses of mesodermal origin that lie near the embryonic midline and have a very definite somatic (pertaining to the embryonic somites) orientation. Several very basic principles underlie the transition from myotomes to specific muscles:

a) myotomes tend to migrate from their original somatic orientation.

b) myotomes tend to fuse to form a composite muscle belly.

c) myotomes may split tangentially or longitudinally into separate muscle bellies.

d) myotomes may morphologically change to form tendons, ligaments, aponeuroses or fasciae.

e) with only few exceptions, myotomes retain their embryonic source of innervation throughout all the other changes. This is true whether the myotome is of somatic or branchial-arch origin (Haines, 1935).

Two examples should clarify and illustrate the above points. The skeletal muscle of the diaphram originates from myotomes that once were positioned in the low cervical somites. In the adult animal, this muscle still retains embryonic derived innervation from the low cervical spinal cord. Also, the myotome from one branchial arch divides to form the adult trapezius and sternomastoideus muscles. This time adult innervation is supplied by the same nerve which supplied the embryonic somite, the spinal accessory. It is therefore reasonable to assume that muscles that are formed from multiple myotome contributions would show adult innervation from multiple spinal origins.

The same cannot be said of dermatomes. A dermatome is a skin segment that is innervated by a specific segmental nerve. Arey (1965) states that "the implication, however, that all of the dermis derives from portions of paired somites and that each girdling dermatome carries with it a sensory nerve, just as myotomes maintain their original motor innervation, is not at all secure."

Fletcher and Kitchell (1966) studied the peripheral zones that sent afferent impulses, induced by a light brush to the skin, to the individually numbered spinal cord segments; i.e. dermatomes. They found that the dermatome boundaries, which were determined in relation to palpable skeletal landmarks, displayed an inherent variability from subject to subject, around an area of maximal response (a bell-shaped distribution curve). They found that most areas were innervated by three dorsal roots, although this number could range from two to four. Although the areas of maximal response exhibited minor degrees of overlap and could therefore be analogous to those areas found in man, clinical variability of pain perception would obscure this difference.

Jenkins (1971) reminds us that even in man there is an extreme overlap to the dermatomes found and that most areas receive inneration from three dorsal roots. This is more than confirmed by the fact that more than one dermatome chart exists for man and that differences as to the size and shape of dermatomes vary between charts. Because of these inherent variabilities found in both man and animals and the stated weak embryonic basis, the search for areas of anesthesia, analgesia or hyperalgesia were not attempted in the present study.

Fletcher (1970) also studied the myotome distribution to the musculature of the pelvic limb. These, not surprisingly, were found to be extremely consistent from dog to dog. A particular muscle was generally innervated by fibers from three spinal segments and never less than two. Certain myotomes and identical distribution, others never contributed to the same muscle while still others seemed to be ubiquitous. One can refer back to figure 5 to check the individual patterns.

If we compare the anatomic variation of the lumbosacral plexus as seen by Miller et al. (1964) with the three plexus arrangements as illustrated by Fletcher (1970) and then compare both to the myotome distribution arrived at by Fletcher (1970), certain assumptions seem feasible. Fletcher's myotome patterns easily fit any of the several published anatomic variations. The L_4 and L_5 myotomes always send fibers to the muscles innervated by the femoral nerve and each pattern shows anatomic contributions by these rami to that nerve. The same is true of the other myotomes. In other words, regardless whether the plexus is prefixed or postfixed, those ventral rami that supply innervation to specific muscles always do so by one particular peripheral nerve and therefore always contribute to its formation within the lumbosacral plexus.

If this innervation is so consistent, then why the anatomic variation?

Remembering the variability of dermatomes, the majority of this anatomic variation could well be explained by sensory variability. The L_3 myotome was not found to contribute to any of the major muscles of the pelvic limb, however, some report it contributes to the formation of the femoral nerve. It could do both if the joining fibers only carried general sensory afferents and possibly sudomotor, pilomotor and vasomotor efferents.

If the peripheral musculature formed by the L_4, L_5 and L_6 myotomes receives motor innervation solely from spinal cord segments L_4, L_5 and L_6 by way of the femoral nerve, then as much innervation to those muscles as desired could be removed by severing any or all of those ventral rami alone, regardless of the anatomic character of the actual plexus. This would not be true if any variation as to the peripheral nerve supplying particular muscles was found. Fletcher's myotomes, however, were found to consistently correspond to the anatomy presented by Miller et al. Barring an embryonic mishap, then, no variation should occur.

A dorsal approach to the individual spinal cord segments contributing to the lumbosacral plexus for the purpose of removing selected spinal cord contributions was deemed unfeasible. First of all, the approach to all spinal segments contributing to the lumbosacral plexus would necessitate the invasion of five vertebral bodies. The variable positioning of specific spinal cord segments within the vertebral canal might even make this more extensive. Because individual ventral and dorsal roots would need to be identified and severed, an extensively deep laminectomy would be necessary. Funkquist and Schantz (1962) warn that this type of procedure is very susceptible to secondary problems that lead to neurologic deficit. Clinical findings of animals held for even moderate lengths of time could, therefore, be drastically affected. The long exposure, extensive laminectomy, need to carefully identify individual nerve roots and small physical space within the vertebral canal would drastically increase the chances of iatrogenic neurologic deficits. Although Trotter (1973) has reported on a procedure to minimize iatrogenic factors in spinal surgery, it had not been substantiated, as yet, by others. He reports that even when his technique is used, deficits are still seen and may clinically last up to one week.

An extra-spinal cord approach would alleviate most of the problems associated with the laminectomy approach. Since such an extra-spinal cord surgical approach to the spinal cord segments that contribute to the lumbosacral plexus had not been described previously, an attempt to find a suitable approach was made. Approach from either the dorsal or lateral aspect seemed hopeless from the beginning. The muscle masses encountered were large, hemorrhage was excessive, surgery was tedious, visualization of the plexus was poor and exact identification of the spinal level of the ventral rami was impossible. The ventral approach, however, was remarkably easy. Visualization of the entire plexus was afforded from the ventral rami of L_4 to that of L_7 along with the beginnings of the femoral, sciatic and obturator nerves. Identification of exact ventral rami became easy and their transection quick. Hemorrhage was non-existent; the surgery easily performed.

The dogs that were used in group I confirmed the value of the ventral approach. The specific manner in which group I was set up required that the entire lumbosacral plexus be exposed on each dog. The ventral rami of L_4, L_5, L_6 and L_7 and the femoral, sciatic and obturator nerves were identified. Ventral rami were then severed (either all but one ramus or just one). This was done bilaterally. A total of eight dogs were used, making a total of sixteen plexuses exposed. At no time was exposure impossible, visualization poor or there a problem such that the rami needing to be severed could not be.

Examination of group I revealed one very striking item. In every dog in which L_5 had been severed, either alone or together with other rami, the patellar tendon reflex was lost. However, those dogs, in which L_5 was intact, retained this reflex. Even that dog in which L_5 was the only rami left intact (L_4, L_6 and L_7 had been severed) exhibited a patellar tendon reflex.

Was this a consistent happening or just a coincidental one? Group II was an attempt to prove which. In this group, all dogs had the ventral ramus of L_5 severed on one side and the rami of L_4 and L_6 severed on the other. In other words, one leg had all components of the femoral nerve removed except L_5 while the other leg had all function intact except L_5. The findings of group I held true. No patellar tendon reflex could be elicited on that side which had the ventral ramus of L_5 severed. It was still possible, however, to elicit a reflex on the opposite side which had the ventral rami of both L_4 and L_6 severed. Never was there a weak reflex, a modified reflex or an abnormal reflex. It was all or none.

Was this only a transient effect? Did the reflex return once gone or slowly disappear if initially present? One of the objectives of group III was to find this out. Once again the reflex was absent on those procedures that removed the innervation of the ventral ramus of L_5. This reflex loss was evident from immediately after surfical recovery until the last holding period at fifty-one days. In those procedures in which the ventral rami of L_4 and L_6 were severed, the reflex stayed and was normal from immediate postoperative recovery until the last holding period forty-two days later. Never was the reflex effected on those dogs that had sham surgical procedures performed unilaterally.

Since innervation to the pelvic limb musculature is partially destroyed by surgical transection of selected ventral rami, the histologic search for signs of denervation atrophy in the muscles is feasible. Three factors could be investigated by such a search: Is there a histologic difference between loss of innervation by ventral rami transection as compared to complete peripheral nerve transection; Is there a quantative difference between the innervation by different roots; And do denervative changes seen correspond to the pelvic limb myotomes? As stated earlier, denervation atrophy of muscle exhibits several distinct phenomena: a) atrophy with reduction in fiber size; b) degeneration of scattered but progressively numerous muscle fibers; c) ultimate replacement by fat cells; d) variable but distinct loss of muscle mass. These changes occur at different time intervals in different muscles and different animals.

The handling of muscle for histologic examination is slightly different. Tearing, crushing or twisting should be avoided because artifacts are easily produced. To prevent this, specimens should be laid on a piece of cardboard, straightened out and permitted to dry. By doing this, the muscle sample sticks to the cardboard and thereby insures minimal distortion during fixation. Also, formalin causes shrinkage of the sarcomeres. This is avoided to some extent by allowing the muscle to adhere to the cardboard before fixation. The samples should then be placed in a humid chamber for a set period of time. This allows the stored muscle glycogen to be utilized. If placed in formalin immediately, the acid nature of the fixative causes the still living muscle fibers to contract. Slow relaxation follows. Fixation of living muscle in this contracted state is virtually impossible. After adequate fixation, sections should be taken in both the longitudinal and cross sectional planes (Adams, Denny-Brown and Pearson, 1962).

What muscles should be examined? Fletcher (1970) stated that the ventral roots of L_4 and L_5 spinal segments innervate the sartorius and quadriceps femoris muscles via the femoral nerve and the adductor magnus et brevis, gracilis and pectineous muscles via the obturator nerve. L_6 fibers innervate most of the muscles of the pelvic limb and in particular, the sartorius and quadriceps femoris muscles via the femoral nerve; the gracilis, adductor magnus et brevis and pectinous muscles via the obturator nerve; the tensor fascia late muscle via the cranial gluteal nerve; and the semimembranosus, semitendinosus and biceps femoris muscles via the sciatic nerve. L_7 innervates all those muscles that L_6 innervates except those innervated by L_4 and L_5. S_1 innervates all those muscles innervated by L_7 except for those muscles receiving innervation via the cranial gluteal nerve (tensor fascia lata, middle and deep gluteal muscles). This maximum number of muscle biopsies possible was limited by the physical task of processing large quantities of tissue and was therefore limited to those mentioned previously.

Neurogenic atrophy was not identified until twenty-five days after nerve transections. It occurred in the semimembranosus and adductor magnus et brevis muscles associated with the L_4 and L_6 transections and in the sartorius and gracilis muscles associated with the L_5 transection. Fifty-one days after surgery, neurogenic atrophy was identified in the tensor fascia lata and the sartorius muscles associated with the L_4 and L_6 transections and in the gracilis, sartorius and quadriceps femoris muscles associated with the L_5 transection. There was a progressive increase with time in the changes seen. Moderate signs of atrophy denoted by variable sizes of fibers, loss of polygonal shape and very distinct shrunken fibers surrounded by vacant halos were seen after twenty-five days. By fifty-one days changes had progressed such that further and more frequent signs of atrophy and some signs of degeneration, represented by the clumping of sarcolemmal nuclei in areas of very minimal sarcoplasm (the typical "banded" histologic appearance), were seen.

Neurogenic atrophy did occur, was recognizable histologically and did correspond to the myotomes preposed by Fletcher (1970). Further qualitative studies needed to be performed. Group IV was devised to do just that. Five dogs were surgically prepared as in group II and euthanasia performed on one dog at forty-six postoperative days, on two dogs at fifty-four postoperative days and on two dogs at sixty-one postoperative days. The cranial and caudal bellies of the sartorius, biceps femoris, tensor fascia lata and combined bellies of the quadriceps femoris muscles were removed. Weights of the combined sartorius, combined quadriceps femoris, biceps femoris and tensor fascia lata muscles were taken and comparisons drawn between those from the side on which the ventral ramus of L_5 had been severed to those from the side on which the ventral rami of L_4 and L_6 had been severed. All muscles were then processed for histologic examination as in group III.

A comparison can be drawn between the weights of muscles removed from this study and those obtained by Sunderland and Ray (1950). Although two dogs did show weight differences between quadriceps muscle groups, these changes were not found in other dogs nor in other muscles studied. They were neither great enough that they could be looked at as outstanding nor could the method of removal or individual differences within dogs be ruled out as causative factors. It also would be reasonable to assume that a 15 mg difference between 100 mg. muscles would be difficult to pick up clinically. The dogs in this group very definitely did not show the tremendous loss of muscle mass as did the opposums studied by Sunderland and Ray. This may be accounted for by species differences but more likely by the fact that at no time was there complete denervation of the muscles removed from these dogs. Partial denervation appears not to cause grossly visible muscle atrophy as does total denervation, and, would not be detectable clinically. It also appears as though a critical amount of nervous supply, not obtained in this study, must be lost before grossly obvious muscle changes occur.

Several things can be said about neurogenic muscle atrophy as seen in group IV. Histologic changes did not occur uniformily within peripheral muscles supplied by the same myotomes. Some muscles showed massive changes while others showed minimal ones. Some muscles degenerated rapidly while others did so slowly. This is in complete agreement with those results seen by Denny-Brown (Adams, Denny-Brown and Pearson, 1962). Removal of innervation from L_5 caused slow, rather localized neurogenic atrophy in the quadriceps femoris muscles from forty-six to sixty-one days. However, wide spread but localized and rapidly progressing atrophy, seeming to peak at forty-six to fifty-four days, occurred within the cranial belly of the sartorius muscles. Removal of L_4 and L_6 innervation did cause changes within the biceps femoris muscles but these did not show up until sixty-one days and were rather sparse but randomly distributed. Opposite to the L_5 transection, comparative changes occurred in the caudal belly of the sartorius muscles while only minimal changes occurred in the cranial belly. Very massive changes appeared in the tensor fascia lata muscles by forty-six days.

Because of the small number of dogs studied, only several useful conclusions can be arrived at. Atrophy definitely is not uniform. It does not progress at the same rates between particular muscles nor even between bellies of the same muscle. If a problem of neurogenic origin is expected within the L_5 spinal cord segment or the ventral ramus, the preferable muscle to expect changes in would be the cranial belly of the sartorius, not the quadriceps femoris. Likewise, if L_6 is the suspected level of injury, the tensor fascia lata, not the biceps femoris, would be the muscle to expect changes in.

If the nerve fibers involved in the function of the patellar tendon reflex are localized in the ventral ramus of L_5, are these necessary fibers afferent, efferent or both? Group V sought the answer to that question. Extensive dorsal laminectomies were performed under sodium pentobarbital anesthesia on four dogs. Barbiturate anesthesia effects the "reticular activating system" in the medulla and spares the nerve cell bodies within the spinal cord to a great degree. Soma (1971) states that in stage 3, plane 1 anesthesia, the "patellar tendon reflex . . . is still present." In stage 3, plane 2, there is "absence of the . . .

reflexes with the possible exception of the patellar." Personal experience has also confirmed the fact that with sodium pentobarbital anesthesia the patellar tendon reflex is intact during surgical planes of anesthesia. Thus, surgery could be performed and the resulting effects upon the patellar tendon reflex tested immediately, negating waiting for postoperative recovery.

The bilateral dorsal and ventral roots of L_5 were isolated and opposite roots transected on opposite sides. Results of paired transections showed that the patellar tendon reflex was completely abolished with dorsal root (afferent) transection and moderately depressed with ventral root (efferent) transection. These findings are easily explained. Severing just the ventral root of L_5 did nothing more than decrease the number of muscle fibers receiving an efferent nerve message telling them to twitch in response to the afferent stimulation of tapping the patellar tendon and made for a weaker response. The complete absence of a reflex response after dorsal root transection suggests that no, or at least not enough, α-motor neurons received afferent information indicating the tendon had been tapped and thus there was no need for them to respond.

CONCLUSIONS

It appears that the afferent signal transmitted in response to tapping the patellar tendon passes up through the femoral nerve, up through the ventral ramus of L_5, up through the dorsal root of L_5 and into the spinal cord. From here it disseminates out to those α-motor neurons directly connected to the quadriceps femoris muscles and the twitch-like knee jerk is elicited. Either no or, at least, not enough of the initial signal passes up through the dorsal roots of L_4 and/or L_6 to elicit this reflex. A very distinct functional division within the lumbar spinal cord and the lumbosacral plexus thus exists. The lumbosacral area is, therefore, in at least one instance, not a composite entity but a very divisible one. More such functional divisions may exist.

Although partial denervation caused histologic evidence of neurogenic muscular atrophy, it did not cause grossly visible muscle atrophy as does total denervation. In fact, the changes were so minimal that clinical detection would be difficult.

Neurogenic muscular atrophy definitely is not uniform. It does not progress at the same rates between particular muscles supplied by the same myotomes nor even between bellies of the same muscles. Histologic signs of L_5 denervation were best seen and the most severe within the cranial belly of the sartorius muscle, not the quadriceps femoris. Signs of L_6 denervation were best seen and the most severe within the tensor fascia lata, moderately evident within the caudal belly of the sartorius muscle and poorly seen within the biceps femoris muscle.

BIBLIOGRAPHY

Adams, R. D., Denny-Brown, D. and Pearson, C. M.: Diseases of Muscle: A Study in Pathology. 2nd Ed. Harper and Row, Publishers, New York, New York, (1962): 138-157, 710-717.

Annis, J. R. and Allen, A. R.: An Atlas of Canine Surgery. Lea and Febiger, Philadelphia, Penn., (1967): 42-53.

Archibald, J., ed.: Canine Surgery. American Veterinary Publications, Inc., Santa Barbara, Calif., (1965): 17-56, 95-109, 467-472.

Arey, L. B.: Developmental Anatomy. 7th Ed. W. B. Saunders, Co., Philadelphia, Penn., (1965): 426-437, 442.

Fletcher, T. F.: Lumbosacral Plexus and Pelvic Limb Myotomes of the Dog. Am. J. Vet. Res., 31, (1970): 35-41.

Fletcher, T. F. and Kitchell, R. L.: Anatomical Studies on the Spinal Cord Segments of the Dog. Am. J. Vet. Res., 27, (1966): 1759-1767.

Fletcher, T. F. and Kitchell, R. L.: The Lumbar, Sacral and Coccygeal Tactile Dermatomes of the Dog. Journ. Comp. Neuro., 128, (1966): 171-180.

Funkquist, B. and Schantz, B.: Influences of Extensive Laminectomy on the Shape of the Spinal Cord. Acta Ortopaedica Scandinavica, supp. 56, (1962): 7-50.

Haines, R. W.: Consideration of the Constancy of Muscular Nerve Supply. J. Anat., 70, (1935): 33-55.

Hoerlein, B. R.: Canine Neurology. 2nd Ed. W. B. Saunders, Co., Philadelphia, Penn., (1971): 9-52, 65.

Jenkins, T. W.: Functional Mammalian Neuroanatomy. Lea and Febiger, Philadelphia, Penn., (1971).

Leonard, E. P.: Fundamentals of Small Animal Surgery. W. B. Saunders, Co., Philadelphia, Penn., (1968): 139-147.

Liddell, E. G. T. and Sherrington, C. S.: Further Observations of Myotatic Reflexes. Proc. Roy. Soc., 97B, (1925): 267-283.

Liddell, E. G. T. and Sherrington, C. S.: Reflexes in Response to Stretch (Myotatic Reflexes). Proc. Roy. Soc., 96B, (1924): 212-242.

Lloyd, D. P. C.: Conduction and Synaptic Transmission of Reflex Response to Stretch in Spinal Cats. J. Neurophysiol., 6, (1943): 317-326.

McGrath, J. T.: Neurologic Examination of the Dog. Lea and Febiger, Philadelphia, Penn., (1960): 69-73.

Magladery, J. W., Park, A. M., Porter, W. E. and Teasdall, R. D.: Spinal Reflex Patterns in Man. Res. Publ. Ass. Nerv. Ment. Dis., 30, (1952): 118-151.

Miller, M. D., Christensen, G. C. and Evans, H. E.: Anatomy of the Dog. W. B. Saunders, Co., Philadelphia, Penn., (1964): 164-175, 595-610.

Popesko, Peter: Atlas of Topographical Anatomy of the Domestic Animals. Trans. By R. Getty with the assistance of J. Brown. W. B. Saunders, Co., Philadelphia, Penn., (1970?): 186-187.

Rugh, T. C., Patton, H. D., Woodbury, J. S. and Towe, A. L.: Neurophysiology. 2nd Ed. W. B. Saunders, Co., Philadelphia, Penn., (1965): 181-206.

Sherrington, C. S.: Decerebrate Rigidity and Reflex Coordination of Movements. J. Physiol., 22, (1898): 319-332.

Sherrington. C. S.: Problems of Muscular Receptivity. Nature, 113, (1924): 732, 892-894, 929-932.

Soma, L. R.: Textbook of Veterinary Anesthesia. Williams and Wilkins Co., Baltimore, Maryland, (1971): 269.

Sunderland, S. and Ray, L. J.: Denervation Changes in Mammalian Striated Muscle. J. Neurol. Neurosurg. and Psychiat., 13, (1950): 159-177.

Tower, S. S.: The Reaction of Muscle to Denervation. Physiol. Rev., 19, (1939): 1-48.

Trotter, E. J.: Surgical Therapy of Intervertebral Disc Disease with Severe Paresis or Paraplegia. Proc. A. A. H. A., 40, (1973): 524-532.

FUNCTIONAL DIVISION WITHIN THE LUMBOSACRAL PLEXUS

by

JAMES WALT WILSON

B. S., Michigan State University, 1969
D. V. M., Michigan State University, 1970

AN ABSTRACT OF A MASTER'S THESIS

submitted in partial fulfillment of the

requirements for the degree

MASTER OF SCIENCE

Department of Surgery and Medicine

KANSAS STATE UNIVERSITY
Manhattan, Kansas

1973

Two clinical cases of spinal cord trauma seen by the author suggested the possibility of a functional division within the lumbosacral plexus. A surgical approach was devised so that the spinal cord contributions to the lumbosacral plexus could be severed without invading the vertebral canal. This was done through a ventral midline incision and blunt dissection into the iliopsoas muscle. The ventral rami of L_3, L_4, L_5, L_6 and L_7; the lumbosacral plexus; and the ilioinguinal, femoral, sciatic and obturator nerves could then be identified. A pilot study was performed in which the loss of the innervation of each specific ventral ramus (L_4, L_5, L_6 and L_7) was clinically evaluated through its surgical transection bilaterally. This was correlated with the retained function after the other three rami were surgically transected leaving only one intact. The result was that the patellar tendon reflex was abolished whenever the ventral ramus of L_5 was severed and was spared whenever the ventral ramus of L_5 was intact.

Group II confirmed this finding by performing a transection of L_5 on one side and of L_4 and L_6 on the opposite side. The patellar tendon reflex was spared on the side in which both L_4 and L_6 were severed and was abolished on the side in which L_5 was severed. The long term effects were checked in group III using sham surgical procedures as controls. In addition, muscle samples were taken at necropsy and examined histologically for neurogenic atrophy. Once again, the relationship between L_5 and the patellar tendon reflex held true, even for as long as 51 days. Neurogenic atrophy was recognized in muscles taken from these dogs starting at 25 postoperative days. Group IV further evaluated the muscular atrophy in four specific muscles. Comparisons of muscle weights were made at necropsy before histologic preparation. Neurogenic atrophy was definitely not uniform. It progressed at different rates between muscles and even between bellies of the same muscle. The cranial belly of the sartorius was the muscle most severely effected by L_5 denervation while the tensor fascia lata was the muscle most severely effected by L_6 denervation. This was in strong contrast to expected changes in the quadriceps femoris and biceps femoris muscles respectively. The final group evaluated the L_5 relationship with the patellar tendon reflex by isolating the dorsal and ventral roots of L_5 and severing opposite roots on opposite sides. The patellar tendon reflex was abolished whenever the dorsal root of L_5 was severed but only diminished when the ventral root was severed.

It thus appears as though the signal initiated by tapping the patellar tendon is transmitted via the ventral ramus of L_5 to the dorsal root of L_5 and into the spinal cord. From here it is disseminated to the neurons innervating the quadriceps femoris muscles group and a reflex knee jerk is elicited. Apparently no or, at least, not enough of the initial signal passes up through the dorsal roots of L_4 and/or L_6 to elicit this reflex. A very distinct functional division within the lumbar spinal cord and the lumbosacral plexus thus exists. The lumbosacral area is, therefore, in at least one instance, not a composite entity but a very divisible one.